

Contents lists available at [ScienceDirect](http://www.sciencedirect.com)

# American Journal of Ophthalmology Case Reports

journal homepage: <http://www.ajocasereports.com/>

## Case report

# Unilateral surgically induced Necrotizing Scleritis after trabeculectomy with Ologen in a patient with pigmentary glaucoma<sup>☆</sup>

Usama Shalaby, Mohamed Amin Heikal<sup>\*</sup>

Benha University, Department of Ophthalmology, Benha, Qalyubia, Egypt

## ARTICLE INFO

### Article history:

Received 29 January 2016

Accepted 13 June 2016

Available online 27 June 2016

### Keywords:

Necrotizing Scleritis

Ologen

Pigmentary glaucoma

Trabeculectomy

## ABSTRACT

**Purpose:** In this report we record the first surgically induced Necrotizing Scleritis case related to trabeculectomy with the use of Ologen Collagen Matrix Implant.

**Observations:** Surgically induced Necrotizing Scleritis is a rare pathological entity that complicates ocular (sclera) surgery.

**Conclusions and importance:** Prompt management of surgically induced Necrotizing Scleritis related to trabeculectomy with the use of Ologen and close follow up is very important to prevent its destructive nature on the globe.

© 2016 The Authors. Published by Elsevier Inc. This is an open access article under the CC BY-NC-ND license (<http://creativecommons.org/licenses/by-nc-nd/4.0/>).

## 1. Introduction

Necrotizing Scleritis is a potentially destructive inflammatory process that may be the presenting sign of severe systemic disease, previous ocular trauma, or ocular infection.<sup>1</sup> Surgically Induced Necrotizing Scleritis (SINS) is a severe form of scleritis with a real risk of globe distortion and ocular structure complications. Pigment dispersion syndrome and pigmentary glaucoma are characterized by accumulation of pigment on the central corneal endothelium as well as trabeculum epithelium.<sup>2</sup> Management of pigmentary glaucoma is either by topical antiglaucoma drops, laser trabeculoplasty and trabeculectomy. Ologen is a porcine extracellular matrix made of atelocollagen cross-linked with glycosaminoglycan.<sup>3</sup> It is a new alternative to traditional antimetabolites in glaucoma filtration procedures. The biodegradable scaffolding matrix induces a regenerative wound healing process without the need for anti-fibrotic agents.<sup>3</sup>

## 2. Case report

A 39 years old woman was discovered recently to have bilateral advanced glaucoma due to pigment dispersion syndrome. She was planned to have bilateral trabeculectomy due to advanced optic

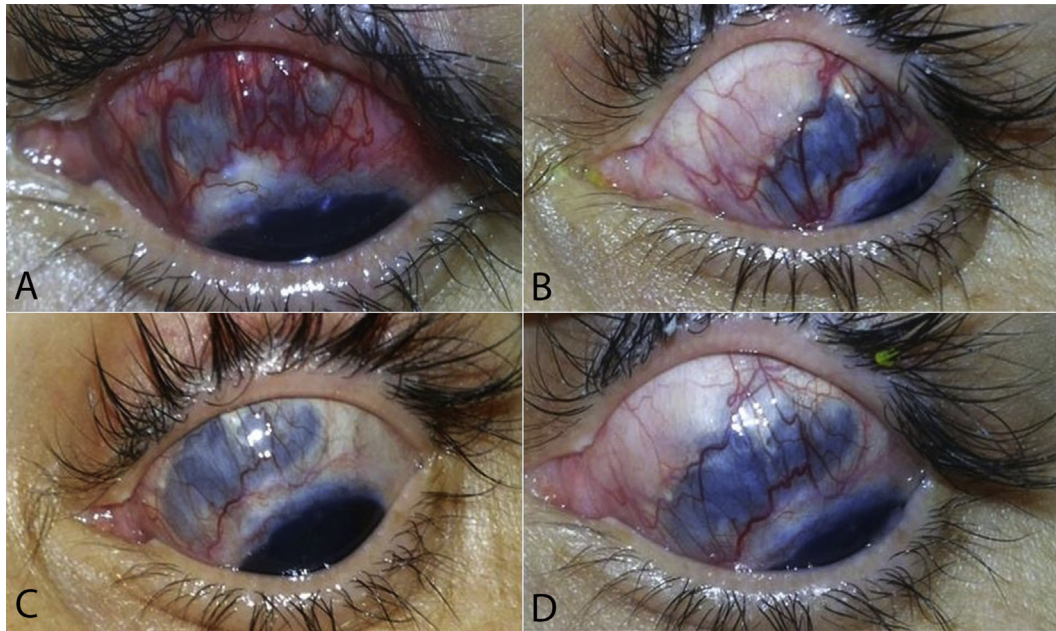
nerve head cupping and marked visual field constriction. Subscleral trabeculectomy with intraoperative mitomycin-C (MMC) application was performed to right eye. Left eye was followed after one week with trabeculectomy surgery with insertion of Ologen<sup>TM</sup> (Optous, Roseville, California).

Postoperatively intraocular pressure (IOP) went down to 8 mmHG (OD) and 6 mmHG (OS) and best corrected visual acuity was 6/18 (OD) and 6/12 (OS). The vision was low and nearly tubular with advanced visual field loss due to the delay in presentation of the case. Three weeks later the lady developed sudden and severe agonizing pain in her left eye (prevented the patient from sleeping). The vision decreased to 6/36 with photophobia and difficulty in opening her left eye. IOP was 10 mmHg (OS) and there was marked injection and vascularization involving sclera, episclera and conjunctiva in the trabeculectomy site. Ologen disappeared with an area of 11 × 6 mm of sclera partially dissolved and choroid has shown through (Fig. 1A). The left pupil was peaked up and refraction has markedly changed from −3.5 DC to −10 DC. There was no conjunctival discharge and the anterior chamber was clear as well as the cornea. There was no fundus changes (clear vitreous and no retinal or choroidal exudations). Left conjunctival swabs were taken for gram staining and cultures. Conjunctival and Tenon debridement were taken for histopathology. Serological tests for autoimmune diseases were done (RF, ANCA, ANA and anti-phospholipid antibodies). SINS was given as a Provisional diagnosis for the case based upon the certainty of being scleritis in the scene of surgical trauma and the absence of signs of infection. Intra venous methyl prednisolone (MP) pulse dose was given

<sup>☆</sup> The study was performed in Benha Ophthalmic Centre, Benha University, Benha, Egypt.

<sup>\*</sup> Corresponding author.

E-mail address: [mohammedheikel@gmail.com](mailto:mohammedheikel@gmail.com) (M.A. Heikal).



**Fig. 1.** A: View of Surgically Induced Necrotizing Scleritis (OS) 3 weeks Post Trabeculectomy, showing hyperemia, vascularity & choroidal exposure 11 mm \*4 mm. B: Sclera, 2 weeks post treatment with diminution of inflammatory signs. C: Quitter eye with starting of healing process. D: About 50% of sclera covered with new collagen.

immediately (1 gm MP slow IV infusion over 1 h, then it was repeated for another two days). The patient started to feel a rapid improvement and she managed to sleep in the first post infusion night. Topical cyclopentolate 1% T.I.D; oral tetracycline and vitamin C both of 1 gm daily dose were given as an adjunctive for the treatment. After finishing MP doses, oral prednisolone (1 mg/kg body weight) and cyclosporin-A (5 mg/kg body weight) were added to the treatment regimen (CBC with differential, kidney function tests and FBS and postprandial were done before commencing the treatment). Serological tests for autoimmune diseases were negative. Gram stains were negative for bacterial growth. The histopathology yielded no growth as well as the cultured materials the second week of incubation. Pain has disappeared on the second post-treatment day and vision started to improve (reached the early postoperative level, 6/12, after 3 weeks) and refraction decreased to  $-5$  DC. Slit lamp examination revealed marked reduction in scleral vascularization and translucency and healing started to be noticed as about 50% of the ulcerated sclera was covered with new collagen and other extracellular matrices (Fig. 1; B, C and D). Follow up plan is to stay on oral prednisolone and cyclosporine but with gradual withdrawal of the former and observation of sclera response. Scleral defect will be assessed after complete subsidence of inflammation and deciding if the defect needs graft or not. No evidence of scleritis was present in the right eye at the same time.

### 3. Discussion

Necrotizing scleritis (NS) is a severe form of scleral inflammation which causes scleral necrosis, ulceration and exposure of the underlying uvea. NS is frequently associated with, autoimmune diseases (such as poorly controlled RA or a systemic vasculitis), infectious diseases and post ocular surgeries (SINS).

SINS have been recognized in post retinal detachment (RD), strabismus, pterygium, penetrating keratoplasty and glaucoma surgeries.<sup>4</sup> The chance of scleritis increases with the use of anti-metabolites, such as MMC and 5-FU in pterygium excision and

subscleral trabeculectomy operations. It appears that the scleritis is initiated by surgical trauma to the sclera which in turn releases circulating immune complexes that become precipitated in and around the vessel walls in the area of insult.<sup>3</sup> The diagnosis of SINS in our case was mainly based on the following findings: 1- Development of necrotizing scleritis in the scene of previous surgical injury in the presence of foreign material (Ologen). 2- Absence of signs (clinical or serological) of systemic autoimmune disease. 3- Absence of signs (clinical or bacteriological) of infection. We preferred to take a sample from the edge of the bleb for bacteriological studies to exclude the infectious etiology in vicinity of exposed intraocular tissues and we were on verge of giving systemic steroids. In addition to the conjunctival swab, we took a very small sample from the conjunctiva and from the episcleral tissues with utmost care to avoid producing more insult to the already inflamed sclera. Scleritis in this case could be due either directly to surgical scleral injury or to the adverse reaction of Ologen. There is a theoretical risk of increased inflammation in eyes with Ologen implant as the implant is nonhuman (porcine) in origin.<sup>3</sup> The dissolution of Ologen in the case could be explained by, being targeted by the inflammatory process and its exposure to proteolytic enzymes, or its role as a foreign antigen that initiated the immune reactions. No evidence of scleritis was present in the right eye at the same time.

Reports in reconstructive surgery have shown an increased inflammation with signs of foreign body reaction related to the porcine cross-linked collagen implants when used in the repair of experimental incisional hernia.<sup>5</sup> There are no such reactions reported when Ologen used in glaucoma surgeries.<sup>3</sup> To the best of our knowledge, this is the first SINS case related to trabeculectomy with the use of Ologen. More histopathological studies of the incised sclera, episclera and conjunctiva in the presence of Ologen are useful before a wide use of this material in the eye.

### Conflict of interest

No conflicts of interest.

## Funding

This work was self-funded by the authors.

## Acknowledgment

We thank all residents, nurses and paramedical staff, in ophthalmology department Benha university hospital, who took part in management of this patient.

Written informed consent was obtained from the patient to publish the details.

## References

- [1] P.G. Watson, S.S. Hayreh, Scleritis and episcleritis, *Br J Ophthalmol* 60 (1976) 163–191.
- [2] C.V. Migliazzo, R.N. Shaffer, R. Nykin, S. Magee, Long-term analysis of pigmentary dispersion syndrome and pigmentary glaucoma, *Ophthalmology* 93 (1986) 1528.
- [3] A. Rosentreter, et al., A prospective randomized trial of trabeculectomy using mitomycin C vs an ologen implant in open angle glaucoma, *Eye* 24 (2010) 1449–1457.
- [4] E.K. Akpek, et al., Evaluation of patients with scleritis for systemic disease, *Ophthalmology* 111 (2004) 501–506.
- [5] A.H. Petteer-Puchner, et al., Adverse effects associated with the use of porcine cross-linked collagen implants in an experimental model of incisional hernia repair, *J Surg Res* 145 (2008) 105–110.