

Case Report

A case of ventricular fibrillation not detected by an automated external defibrillator

Shigetoshi Sakabe MD, Atsunobu Kasai MD, Yuichi Sato MD,
Takashi Omura MD, Takashi Yamanaka MD, Morimichi Setsuda MD

Department of Cardiology, Yamada Red Cross Hospital

We report a case of ventricular fibrillation (VF) which an automated external defibrillator (AED) could not detect. A 13-year-old girl collapsed just after playing basketball. Cardio pulmonary resuscitation (CPR) was started immediately and 5 minutes later an AED was applied by a rescue team. The monitor of the AED displayed typical VF, but the AED did not detect it as VF. The VF was not detected during 2 more attempts. Detection occurred on the fourth attempt, and counter-shock was successfully delivered, but the process took an extra 9 minutes. After the event, the girl was diagnosed with a latent type of prolonged QT syndrome. We analyzed the reason why the VF was not detected by the AED and found that the ECG detected by the AED fell outside the device's parameters for ventricular tachycardia (VT) or VF. We emphasize that the AED is an excellent device, but we should also be aware of its limitations.

(J Arrhythmia 2008; 24: 166–169)

Key words: Automated external defibrillation, Ventricular fibrillation, Identification

Introduction

Automated external defibrillators (AEDs) have been used to treat sudden cardiac arrest due to ventricular fibrillation (VF) and pulseless ventricular tachycardia (VT) out of hospital. In Japan, AEDs are available for public use for countershock delivery to people who are pulseless and breathless. But even the paramedics of rescue teams, who are not licensed physicians, are not permitted to use manual defibrillators at their own discretion. A study to analyze the performance of AEDs reported that their ability to sense shockable VF/VT rhythm was 81%.¹⁾ We report a case of a 13-year-old girl in whom an AED could not detect the VF during three attempts to deliver countershock. The device, model TEC-22213

manufactured by Nihon Koden Corporation, is used by paramedics. We analyzed the reason why the device could not detect the VF. The AED programming was the cause of the problem, and it was not attributable to human error.

The AED is an excellent device, but we should be aware of its limitations in order to use it effectively.

Case Report

A 13-year-old girl collapsed just after playing basketball at a junior high school in December 2006. She was not breathing and her pulse was not palpable. A teacher who had received training in basic life support started performing cardio pulmonary resuscitation (CPR) immediately, with chest

Received 29, February, 2008; accepted 6, October, 2008.

Address for correspondence: Shigetoshi Sakabe MD, Department of Cardiology, Yamada Red Cross Hospital, Takabuku 810, Misono-cho, Isehara city, Mie Pref. 516-0805, Japan. Tel: +81-596-28-2171 E-mail: yrch2nai@yamada.jrc.or.jp

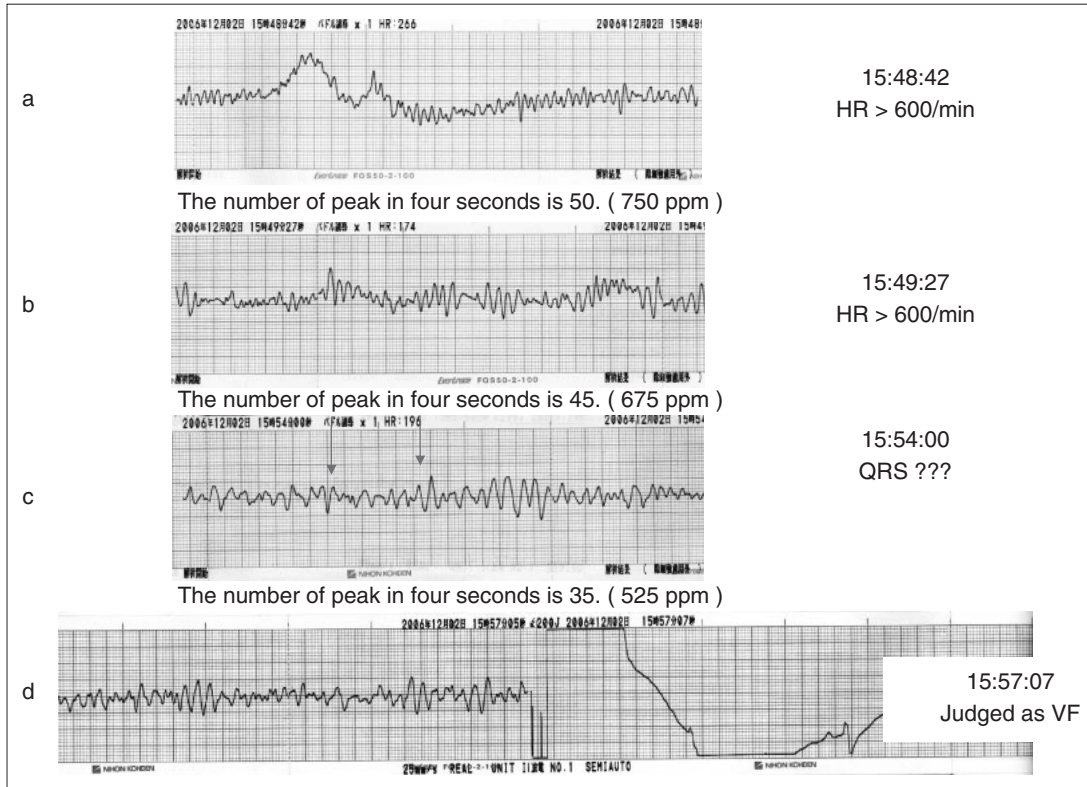


Figure 1 The monitor electrocardiograms of the AED. VF a–c were not detected. Only VF d was detected.

compression and ventilation. There were no AEDs available at the school, so CPR was continued for 5 minutes until the rescue team arrived. When the ambulance arrived, an AED (TEC-2213, Nihon Kodan Corporation) was immediately employed. The monitor of the AED displayed typical VF (Figure 1), but the AED program determined that it was not VF/VT. She was obviously near cardiac death and in need of countershock. The leader of the rescue team was not permitted to deliver countershock by switching the device to manual mode. CPR was continued, and an attempt was made to analyze her arrhythmia with the AED. During two further trials, the AED was not able to detect any rhythms which would require shock delivery. On the fourth attempt, the AED succeeded in detecting VF and a counter-shock was delivered successfully. The girl's pulse immediately recovered and she began to breathe on her own, but it took 9 minutes from the arrival of the rescue team.

She was transported to our hospital, where we examined and treated her. When she arrived at our emergency room her vital signs were stable but her consciousness was drowsy. A 12-lead ECG (Figure 2) showed sinus rhythm and a prolonged QT interval (QTc: 540 msec); echocardiography revealed a struc-

turally intact heart and wall motion. We implanted an implantable cardioverter defibrillator the following week. Non-induced VF has not recurred after the incident. Her medical history was unremarkable with no episodes of syncope or palpitation and her family had no history of sudden death or syncope. Before entering junior high school, she had received a routine health examination, including a 12-lead ECG, which was normal (Figure 3). Our examination revealed a prolonged QT interval during exercise and epinephrine load testing (Figure 4). She had no mutation of cardiac sodium channel gene phenotypes which are related to QT syndromes. VF did not occur with right ventricular program stimulation. She did not show any signs of typical prolonged QT syndrome under the Schwartz criteria²⁾ but had a latent type of prolonged QT syndrome.

She recovered enough to go back to school, but was handicapped in her ability to study because of the 14 minutes of cerebral ischemia she suffered.

We analyzed the reason the AED could not detect her VF. The AED was not out of order and was used correctly. Her height was 160 cm and weight was 55 kg. Therefore, neither patient physique nor operator skill can be considered as causes for the non-detection. The recorded data of the AED was sent to

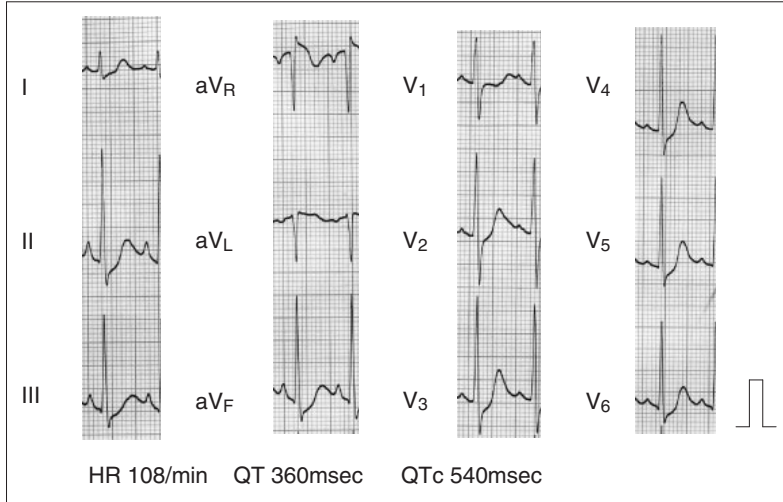


Figure 2
The 12 lead electrocardiograms 3 hours after VF was terminated. The QT interval was prolonged.

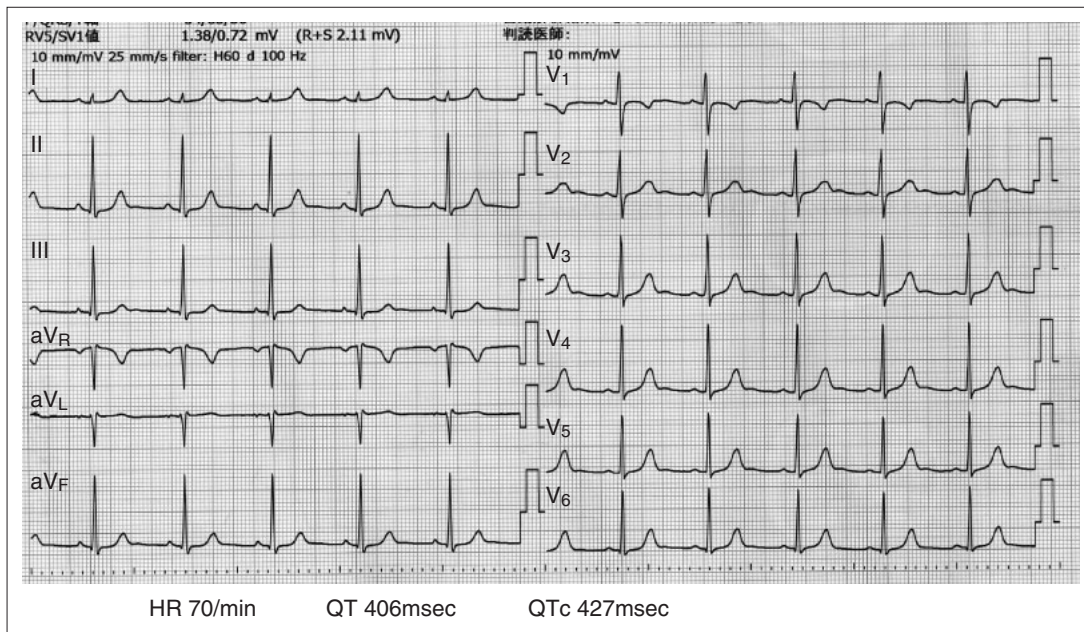


Figure 3
The 12 lead electrocardiograms on the 6th hospital day

NIHON-KODEN to analyze. The reason that the AED could not detect the VF is that the signal was outside of the VF/VT parameters as defined by the AED program. The TEC-2213 analyzes the ECG for 4 seconds using its own criteria. Data recorded during the first 3 attempt did not conform to the parameters. During the first 2 attempts, the VF was so fast that the AED program judged that the signal was electromagnetic interference. The AED model defines VF/VT as waves of less than 600/min, and the signals detected were greater than that value. In the third attempt the AED showed a “normal” ECG

because it detected a spike-like QRS. Finally, in the fourth attempt, the AED correctly detected the VF.

Discussion

We report a case of a 13-year-old girl who collapsed during an episode of VF, but an AED could not detect her VF. Finally it was detected, and she recovered with the delivery of counter-shock. But it took 14 minutes after her cardiac arrest until the delivery of the counter-shock, and she became handicapped.

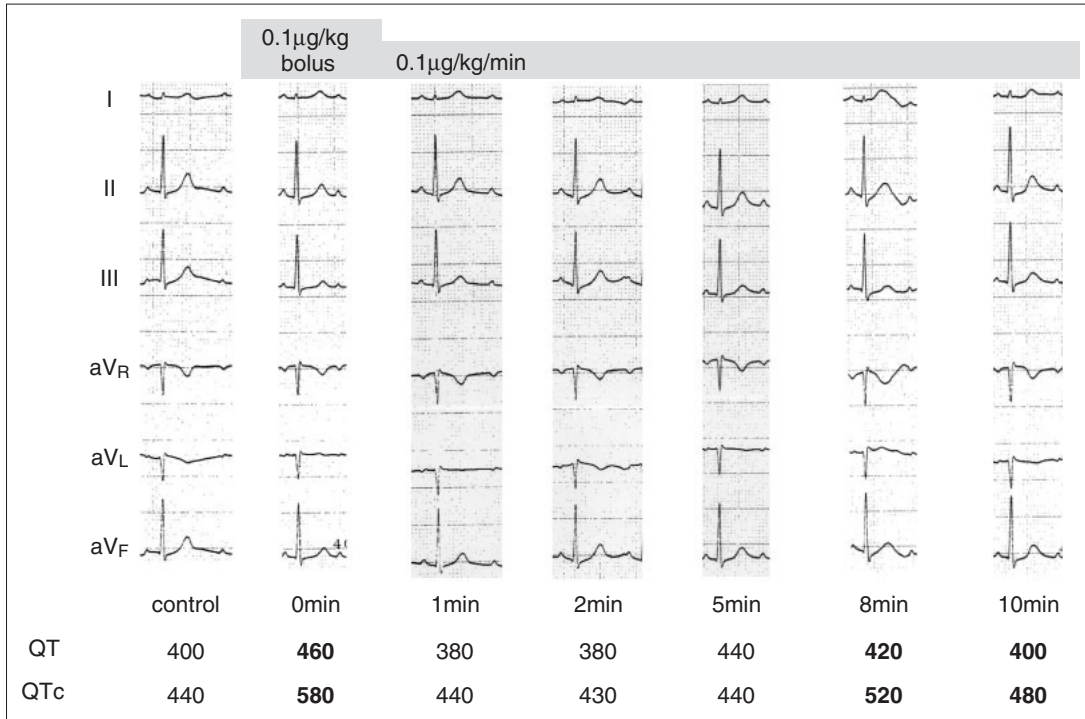


Figure 4 Epinephrine loading test
Prolonged QT interval was detected.

The AED was normal and it was used correctly, but the problem was due to the programming of the device. Because an AED requires high specificity to avoid delivering unnecessary and dangerous electric shock, special criteria are used to detect typical VF/VT. A study to determine AED performance was made in 2001. A total of 3,448 AED rhythms were analyzed; sensitivity and specificity for appropriate AED management of shockable rhythm were 81% and 99.9%, respectively.

We believe that the AED is an effective device. Since the incidence of sudden death during athletics appears to be in the range of 1:2,000,000 per year for young people of high school age,³⁾ we recommend that all schools should have an AED ready. We are not claiming that the AED device is deficient in its ability to detect, but we emphasize the importance of

professionals being aware that the AED is not a perfect device and sometimes cannot detect VF/VT. Well-trained professional paramedics should be allowed to use defibrillators in the manual mode when necessary. This change will allow the AED device to be used more effectively.

References

- 1) MacDonald RD: Performance and error analysis of automated external defibrillator use in the out-of-hospital setting, *Ann Emerg Med* 2001; 38:3 262–267
- 2) Schwartz PJ, Moss AJ, Vincent GM, et al: Diagnostic criteria for long QT syndrome: An update. *Circulation* 1993; 8: 782–784
- 3) Maron BJ, Gohman TE: Prevalence of sudden cardiac death during competitive sports activities in Minnesota high school athletes. *J Am Coll Cardiol* 1998; 32: 1881–1884