

Effects of Aggressive Versus Conventional Lipid-Lowering Therapy by Simvastatin on Human Atherosclerotic Lesions

A Prospective, Randomized, Double-Blind Trial With High-Resolution Magnetic Resonance Imaging

Roberto Corti, MD,*† Valentin Fuster, MD, PhD, FACC,† Zahi A. Fayad, PhD,† Stephen G. Worthley, MD,*† Gerard Helft, MD, PhD,*† William F. Chaplin, PhD,† Jörg Muntwyler, MD, Juan F. Viles-Gonzalez, MD,*† Jesse Weinberger, MD,‡ Donald A. Smith, MD,† Gabor Mizsei, MSEE,† Juan J. Badimon, PhD, FACC*†

New York, New York

OBJECTIVES	This study sought to compare the effects of aggressive and conventional lipid lowering by two different dosages of the same statin on early human atherosclerotic lesions using serial noninvasive magnetic resonance imaging (MRI).
BACKGROUND METHODS	Regression of atherosclerotic lesions by lipid-lowering therapy has been reported. Using a double-blind design, newly diagnosed hypercholesterolemic patients (n = 51) with asymptomatic aortic and/or carotid atherosclerotic plaques were randomized to 20 mg/day (n = 29) or 80 mg/day (n = 22) simvastatin. Mean follow-up was 18.1 months. A total of 93 aortic and 57 carotid plaques were detected and sequentially followed up by MRI every six months after lipid-lowering initiation. The primary MRI end point was change in vessel wall area (VWA) as a surrogate for atherosclerotic burden.
RESULTS	Both statin doses reduced significantly total cholesterol (TC) and low-density lipoprotein cholesterol (LDL-C) versus baseline (p < 0.001). Total cholesterol decreased by 26% versus 33% and LDL-C by 36% versus 46% in the conventional (20 mg) versus aggressive (80 mg) simvastatin groups, respectively. Although the simvastatin 80-mg group had significantly higher baseline TC and LDL-C levels, both groups reached similar absolute values after treatment. A significant reduction in VWA was already observed by 12 months. No difference on vascular effects was detected between the randomized doses. Post-hoc analysis showed that patients reaching mean on-treatment LDL-C ≤100 mg/dl had larger decreases in plaque size.
CONCLUSIONS	Effective and protracted lipid-lowering therapy with simvastatin is associated with a significant regression of atherosclerotic lesions. No difference in vessel wall changes was seen between high and conventional doses of simvastatin. Changes in vessel wall parameters are more related to LDL-C reduction rather than to the dose of statin. (J Am Coll Cardiol 2005;46:106–112) © 2005 by the American College of Cardiology Foundation

Lipid-lowering by statins is the cornerstone of therapy for primary and secondary prevention of atherosclerotic disease. A clear reduction in the incidence of coronary events, both among patients with and without a previous history of coronary heart disease (CHD), has been shown in several large randomized controlled studies with different statins. The major mechanism of action of statins is the inhibition of de novo cholesterol synthesis and increased expression of low-density lipoprotein cholesterol (LDL-C) receptors, resulting in significant reductions of total cholesterol (TC) and LDL-C plasma levels. Whether this is the only mech-

anism of action responsible for the observed benefits remains controversial.

Experimental (1) and clinical (2,3) evidence supports the notion that statins stabilize high-risk (vulnerable) lesions by reducing the lipid content and inflammation of atherosclerotic plaque, thereby increasing the fibrous-muscular/lipid tissue ratio. It has been postulated that statins may reduce atherosclerotic burden, and by stabilizing the atherosclerotic plaques reduce the risk of plaque disruption. Plaque disruption is considered the leading mechanism responsible for the thrombotic complications of atherosclerotic disease (4). On the other hand, it also has been postulated that statins may exert their clinical benefits via lipid-lowering independent or pleiotropic mechanisms (5–7).

The availability of high-resolution imaging modalities has significantly facilitated the possibility of performing in vivo regression studies. Cross-sectional magnetic resonance imaging (MRI) has emerged as the most promising noninvasive technique for longitudinal in vivo studies of large atherosclerotic arteries (8). Its usefulness in studying plaque progression, stabilization, and even regression has been

From the *Cardiovascular Biology Research Laboratory, the †Cardiovascular Institute, and the ‡Department of Neurology, Mount Sinai School of Medicine, New York, New York. This study was supported by grants from the National Institutes of Health (HL54469, Drs. Fuster and Badimon); the National Heart, Lung, and Blood Institute (HL61801, Dr. Fuster); The Swiss National Research Foundation (Dr. Corti); The National Heart Foundation of Australia (Dr. Worthley); The French Federation of Cardiology (Dr. Helft); and Merck and Co, Inc. Merck and Co. was partially responsible for the funding of the project. Mount Sinai authors are fully responsible for data acquisition, evaluation, and writing the manuscript without any interference from the funding sources.

Manuscript received November 1, 2004; revised manuscript received March 18, 2005, accepted March 22, 2005.

Abbreviations and Acronyms

CHD	= coronary heart disease
HDL	= high-density lipoprotein
IVUS	= intravascular ultrasound
LA	= lumen area
LDL-C	= low-density lipoprotein cholesterol
MRI	= magnetic resonance imaging
TC	= total cholesterol
TE	= echo time
TR	= repetition time
TVA	= total vessel area
VWA	= vessel wall area
VWT	= vessel wall thickness

shown in several animal models by several groups. Recently, MRI has been used to image human atherosclerotic lesions in several vascular territories and its accuracy and reproducibility in measuring atherosclerotic plaques has been reported (9).

We have previously reported that despite an early hypo-lipidemic effect, at least 1 year of treatment was needed to detect significant changes in plaque size in clinically asymptomatic patients (10). Our preliminary results were recently confirmed in a case-control study reporting smaller plaque size, a smaller lipid core, and reduced lipid content in patients treated with an aggressive lipid-altering regimen for 10 years (3). More importantly, prospective angiographic studies showed that simvastatin halted the progression of stenotic coronary lesions (11) and the combination of simvastatin and niacin has the potential to reduce the degree of stenosis (12).

The purpose of this single-center, prospective, randomized trial was to investigate the long-term effect of lipid lowering by simvastatin on early atherosclerotic lesions in humans and to compare the effects of aggressive versus conventional therapy by means of two different dosages of the same statin.

METHODS

Experimental design. The study involved newly diagnosed hypercholesterolemic (LDL \geq 130 mg/dl and triglycerides \leq 445 mg/dl) and clinically asymptomatic patients. Recruitment started in March 1999, and the study was terminated in March 2002.

Inclusion criteria were based on the pre-existence of atherosclerotic plaques (thoracic aortic wall \geq 4.0 mm and/or carotid wall \geq 2.0 mm thick) detected by carotid B-mode ultrasound, echocardiography, or MRI. Serial MRI studies of the thoracic aorta and carotid arteries were performed at baseline and every 6 months after therapy initiation. This study design allowed each patient to serve as his or her own control, hence offering the opportunity to study progression or regression of the same (or individual) atherosclerotic lesions using MRI.

Exclusion criteria were heart failure, renal or hepatic disease, significant carotid disease, or a clinically significant medical or surgical event within 3 months before study entry. Of 110 patients screened, 51 patients fulfilled the inclusion criteria and were enrolled after providing written consent. Patients were randomized in a double-blind fashion to conventional (simvastatin 20 mg) or aggressive (simvastatin 80 mg) lipid-lowering interventions.

The patient characteristics are summarized in Table 1. Clinical follow-up was done at 6, 12, 24, and 48 weeks and blood samples were drawn at baseline, 6, 12, 24, 48, 72, and 96 weeks to determine lipid levels and safety parameters. The local institutional review board approved the protocol. **MRI protocol.** Imaging was performed on a 1.5-T whole-body MRI system (Signa CV/i, GE Medical Systems, Milwaukee, Wisconsin; 40 mT/m; SR150) as previously described (10,13). In brief, four-element phased-array coils were used for carotid and aortic imaging. After localization with a fast-gradient-echo sequence, all images were obtained with a double-inversion recovery (i.e., black-blood) fast-spin-echo

Table 1. Patient Characteristics According to the Treatment Group

	Range	Simvastatin 80 mg (n = 22)	Simvastatin 20 mg (n = 29)	p Value†
Age (yrs)	41.4–82.9	62.6 ± 7.6	62.3 ± 10.0	NS
BMI (kg/m ²)	18.8–34.8	26.5 ± 3.2	25.1 ± 3.7	NS
TC (mg/dl)*	193–356	257 ± 38	241 ± 39	.0089
LDL-C (mg/dl)*	110–226	173 ± 33	154 ± 31	.0005
HDL-C (mg/dl)*	26–126	57.0 ± 19.5	55.6 ± 20.7	NS
TG (mg/dl)	41–600	164 ± 84	163 ± 116	NS
Aortic lesions				
Lumen (mm ²)	251–1,092	464 ± 170	425 ± 149	NS
TVA (mm ²)	417–1,790	749 ± 236	744 ± 267	NS
VWA (mm ²)	145–884	285 ± 80	319 ± 176	NS
Carotid lesions				
Lumen (mm ²)	9.2–73.6	32 ± 11	33 ± 14	NS
TVA (mm ²)	43.0–151.6	79.1 ± 20.2	80.4 ± 26.1	NS
VWA (mm ²)	26.5–86.9	48.6 ± 12.6	47.8 ± 16.4	NS

*To convert values to millimoles per liter, multiply by 0.02586. †Significant differences between the treatment groups (20 mg vs. 80 mg) are tested by unpaired t test. Data are given as mean ± SD.

BMI = body mass index; HDL-C = high-density lipoprotein cholesterol; LDL-C = low-density lipoprotein cholesterol; TC = total cholesterol; TG = triglycerides; TVA = total vessel area; VWA = vessel wall area.

sequence with electrocardiographic gating during free breathing (14). Twenty-five to 30 transverse images centered at the carotid bifurcation were taken.

Imaging parameters were: repetition time (TR), 2 R-R intervals; echo time (TE), 12/45 ms (proton density-weighted/T2-weighted); field of view, 12 cm; slice thickness, 3 mm; no interslice gap, acquisition matrix, 256×256 ; 512 zero filling; no phase wrap; number of signal averaged 1/2 (proton density-weighted/T2-weighted); echo-train length, 32; receiver bandwidth, ± 64 kHz. A chemical shift suppression pulse was used to suppress the signal from perivascular fat. For the aorta, 25 to 30 transverse images from the origin of the left subclavian artery to the level of the diaphragm were obtained. For the aortic arch, 10 to 12 cross-sectional oblique images (perpendicular to the vessel wall) were acquired. The imaging parameters were similar as for carotid imaging, except: 20-cm field of view and 5-mm slice thickness.

The in-plane resolution was $780 \times 780 \mu\text{m}$ for the aorta and $469 \times 469 \mu\text{m}$ for the carotid artery. The total examination lasted 60 to 90 minutes.

Morphometric analysis. The MR images were transferred to a Macintosh computer for further planimetric analysis. Special attention was given to match images of the same patient at different follow-up time points, using several anatomic landmarks (i.e., carotid bifurcation, top of the aortic arch, origin of the coronaries, pulmonary artery bifurcation, and pulmonary veins) as previously described (9,14). To minimize sub-millimeter errors in the matching of the images at different time points, at least five contiguous MR images per plaque were analyzed and their average was considered for statistical analysis. Computer-assisted morphometric analysis of cross-sectional MR images was used to measure vessel wall dimensions by semiautomatic tracing (Image Pro-Plus, Media Cybernetics, Carlsbad, California). The tracing tool works by following an edge (i.e., boundary) of significant contrast. Lumen area (LA); total vascular area (TVA); minimal, maximal, and mean vessel wall thickness (VWT); and vessel wall area (VWA = TVA - LA) were calculated. The measurements were performed blinded to the patient's identity and image order. The reproducibility of the VWA measurement has been previously reported (9,10,14). We reported an image-specific error (standard deviation between matched images) of 6 mm^2 for aortic and 2 mm^2 for carotid images. If the average values of five contiguous images were considered, the error was reduced at 4.5 mm^2 for aortic and 1.5 mm^2 for carotid images. This corresponds to an error of 2.6% for aortic and 3.5% for carotid plaques. Based on our reproducibility data, we calculated that changes in plaque size of more than 5.2% for aortic and more than 7% for carotid lesions are likely to be accurately measured by MRI (10).

The effects of the lipid-lowering intervention on atherosclerotic lesions were assessed as changes in vessel dimensions versus baseline. A direct effect of simvastatin on normal vessel wall (no plaque visually detectable, maximal

VWT < 3 mm for aortic and < 2 mm for carotid segments) has been previously ruled out by analyzing 28 non-atherosclerotic arterial segments (17 aortic and 11 carotid segments) after 12 months of treatment (10). The difference in VWA was 2.4% ($p = 0.8$) for aortic and 3.9% ($p = 0.3$) for carotid segments.

Statistical analysis. Data are presented as mean \pm SD. Statistical analysis was performed using analysis of variance for repeated measures or Student's *t* test (StatView 4.1, 2002, ABACUS Inc., Cary, North Carolina). A value of $p < 0.05$ was considered significant.

RESULTS

Baseline characteristics. Demographic characteristics, plasma lipid levels, and vessel wall dimensions at baseline are reported in Table 1. The average age of the patients was 62 years, with a mean body mass index of 25.7 kg/m^2 . Fifty-one patients were included in the study; 40% female patients, 31% hypertensive patients, 33% previous smokers, 30% current smokers, and 19% with diabetes. All patients were clinically asymptomatic. A total of 93 aortic and 57 carotid plaques were identified and followed up by MRI. Twenty-nine patients were assigned randomly to 20 mg/day simvastatin (conventional treatment group) and 22 patients to 80 mg/day simvastatin (aggressive treatment group). No significant differences were observed between the treatment groups, with the exception of TC and LDL-C, which were significantly higher in the patients assigned to simvastatin 80 mg.

The mean follow-up was 18.1 ± 6.3 months. An MRI follow-up was performed in 40 patients at 12 months, in 33 patients at 18 months, and in 20 patients at 24 months.

One patient was lost to follow-up during the first 6 months: a 52-year-old man with no previous episode of angina died suddenly during exercise 3 weeks after starting in the conventional treatment group.

Effect on plasma lipid levels. As expected, simvastatin therapy was associated with a significant reduction in both TC and LDL-C (Fig. 1). For the conventional treatment group, receiving simvastatin 20 mg, the reduction was 25% for TC and 36% for LDL-C. The aggressive treatment group, receiving simvastatin 80 mg, showed an additional 7% reduction in TC, corresponding to a total decrease of 32% versus baseline values. For LDL-C the additional reduction was 10%, corresponding to a total reduction of 46% versus baseline. Simvastatin 80 mg induced a significantly higher percent decrease in TC and LDL-C than simvastatin 20 mg (Fig. 1).

The maximal hypolipidemic effect was already achieved within the first 6 weeks of treatment, and a further decrease was not shown throughout the duration of the study. Although the group of patients assigned randomly to simvastatin 80 mg had significantly higher baseline levels of TC and LDL-C, both treatment groups reached similar absolute values after treatment (Fig. 1). After treatment, the average TC was 181 mg/dl for the conventionally and 175

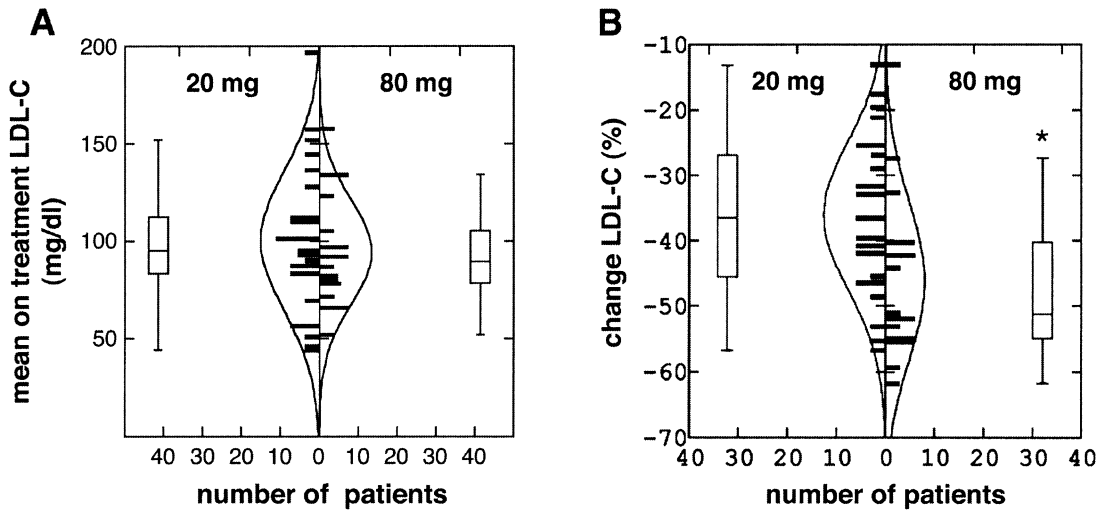


Figure 1. Bar graph showing the effect of statin treatment on plasma low-density lipoprotein. Mean value of low-density lipoprotein cholesterol (LDL-C) during treatment and the pre-treatment value were used to calculate the changes. The bars describe the number of patients for a mean LDL-C at the end of treatment (A) and for the percent change in LDL-C (B). The line describes the distribution of the data. A significant decrease in LDL-C as compared with baseline was seen for both 20-mg and 80-mg simvastatin doses (A). The 80-mg simvastatin group is associated with a significantly greater 10% decline in LDL-C (B). Because of significantly higher baseline LDL-C values in the high-dose group, both groups ended in similar absolute values.

mg/dl for the aggressively treated group, respectively. Mean levels of LDL-C on-treatment were 98 and 93 mg/dl, respectively.

Effect on plaque size. The effects of both lipid-lowering treatments on carotid and aortic atherosclerotic lesions throughout the study are shown in Figure 2. Overall, statin administration was associated with a significant decrease in VWA over time (analysis of variance $p < 0.001$) for both aortic and carotid atherosclerotic lesions. At least 12 month of treatment was required before any statistically significant change in VWA could be detected. Aortic VWA decreased by 10% at 12 months and by 15% at 24 months. Carotid VWA decreased by 14% and 18% at 12 and 24 months, respectively. Similar trends were seen for change in maximal VWT, confirming that the changes take place in the thickened areas of the vascular wall, because normal wall did not show any change. The decrease in VWT was 9% at 12 months and 15% at 24 months in aortic lesions. In carotid lesions, VWT decreased by 10% at 12 months and by 17% at 24 months. Aortic lumen increased by 5% and 6% at 18 and 24 months, respectively. Carotid artery lumen increased by 4% and 5%, respectively. No change in lumen size was detected at 6 and 12 months. Similar trends in change over time were seen for both statin dosages. In fact, no difference was seen between the two treatments for any of the vascular measurements.

A representative MRI follow-up at the level of the carotid bifurcation in the same patient at baseline and at 24 months on statin is shown in Figure 3. The optimal matching of the images can be appreciated by the similar pattern of the vein flowing into the internal jugular vein.

Relationship between changes in lipid levels and plaque. No direct relationship was observed between the two regimens at either the systemic or the vascular level. The two doses of simvastatin had similar changes on plaque

parameters. When vascular changes were correlated with effect on systemic lipid levels, independently of the statin dose, no direct relationship was observed between LDL lowering and absolute changes in plaque characteristics. Interestingly, LDL lowering did have a significant impact on the time required for the changes to occur.

The post-hoc analysis of the vascular effects according to the median split of the lipid-lowering effect, independently of the treatment group assignment, showed that the group that reached lower LDL-C levels had the faster decrease in VWA (slope $r = -0.62$ vs. $r = -0.53$). Accordingly, the group with the larger percent decrease in LDL-C had a larger decrease in VWA (slope $r = -0.58$ vs. $r = -0.57$).

More interesting were the observations when the effects of therapy were analyzed based on the efficacy in achieving the National Cholesterol Education Program (NCEP) goals of LDL-C plasma levels of 100 mg/dl independent of the treatment received. Patients that reached an LDL-C ≤ 100 mg/dl showed a larger decrease in plaque size compared with those that did not achieve this cholesterol goal. Patients that reached LDL-C ≤ 100 mg/dl had a 17% reduction in aortic VWA, versus a 12% in the group with on-treatment levels of >100 mg/dl LDL-C. This difference was statistically significant ($p = 0.027$). Similar trends were seen for lesions in the carotid arteries (Fig. 4). An average VWA decrease of 16.5% in patients with LDL-C ≤ 100 mg/dl versus a 12% decrease in patients with LDL-C >100 mg/dl was seen ($p = 0.36$).

DISCUSSION

This long-term in-vivo human study shows that effective and protracted lipid-lowering therapy by simvastatin is associated with a significant regression of atherosclerotic lesions (10,13). Interestingly, in this cohort of asymptomatic

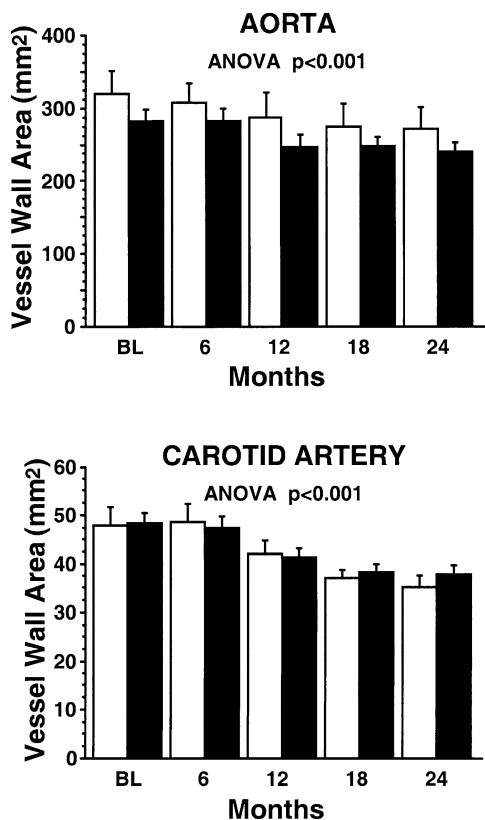


Figure 2. Effect of statin treatment on plaque size. Bar graphs showing data on vessel wall area at baseline, 6, 12, 18, and 24 months for aorta (upper panel) and carotid artery (lower panel) for the 20 patients who reached the 24-month follow-up. Data are displayed according to the statin dose: simvastatin 20 mg (white bars) and 80 mg (black bars). Data are given as mean \pm SEM.

patients presenting with untreated hypercholesterolemia and atherosclerotic lesions of the aorta or carotid artery, similar regression was noticed in both vascular territories. In addition, the group of patients with a more aggressive hypolipidemic effect achieved an earlier and more marked reduction of the asymptomatic atherosclerotic lesions. Other investigators using combined surface and transesophageal MRI in the thoracic aorta have confirmed this observation (15).

Recently, Jensen et al. (16) reported similar results in the coronary circulation in patients with hemodynamically non-significant coronary stenoses (<50% stenoses) after 15 months of simvastatin treatment. This intravascular ultrasound (IVUS) study showed that statin treatment induces coronary vessel shrinkage without affecting the lumen during the first year of treatment, which confirms our findings that statin treatment may reverse some of the compensatory enlargement seen in early atherosclerotic lesions (13). More recently, Nissen et al. (17) showed that aggressive lipid-lowering therapy by atorvastatin reduces lesion progression in patients with more severe coronary disease and partial statin pretreatment. These findings confirm our hypothesis that atherosclerotic plaque regression is possible by lipid-lowering interventions. These effective interventions, by

removing the intravascular lipid deposition, would lead not only to plaque reduction but also to its stabilization. These observations reinforce our hypothesis that early lipid-lowering treatment before the atherosclerotic disease progresses to clinically manifest lesions would render faster and more efficient benefits. Further efforts should be made to provide early detection of atherosclerosis, better patient risk stratification, and clearer definition of the optimal time point at which to intervene with the most adequate treatment. In fact, little is known about the natural history of atherosclerosis and the rate of progression of stable disease, crucial information for better interpretation of the available results of different interventions in atherosclerosis. The availability of the new non-invasive imaging modalities may make a significant impact on these unanswered questions.

Surprisingly, we found similar trends on plaque size effect in patients treated with 20 mg and 80 mg simvastatin, without any substantial difference between the groups. A possible explanation for these unexpected results lies in the difference between the baseline lipid levels for the two groups. In fact, patients assigned to the aggressive intervention had significantly higher LDL-C levels at baseline. Although the 80-mg dose had a higher relative hypolipidemic effect than the 20-mg dose (LDL-C reduction of 46% vs. 36%, $p < 0.01$, Fig. 1B), both groups reached similar lipid levels after treatment (Fig. 1A).

The results of our study support the hypothesis that the observed clinical benefits of statins seem to be mediated predominantly via their hypolipidemic effect. In fact, the stratification of the results in a post-hoc analysis, according to the LDL-C, showed that patients who reached an LDL-C ≤ 100 mg/dl (≤ 2.6 mmol/l) had greater regression of atherosclerotic lesions (Fig. 4). These data support the LDL-C goal defined by the NCEP Adult Treatment Panel (ATP)-III guidelines for secondary prophylaxis in CHD and CHD risk equivalents and should further stimulate the medical community to increase the effort toward this goal. Our data support the increasing consensus that “lower is better” and raise the question of whether stricter new guidelines, with lower lipid levels, are required to further reduce the socioeconomic impact of cardiovascular diseases.

Interestingly, despite the early maximal hypolipidemic effect (obtained after 6 weeks of treatment), at least 12 months of treatment is needed before detecting significant changes in lesion characteristics. In the recently published Heart Protection Study, a significant benefit of simvastatin in a dose of 40 mg was shown independently of the baseline lipid levels (18). Similar to previous prevention trials, the clinical benefit of statin treatment became evident only after 12 months of treatment (18). The changes in plaque size shown in our study are potentially expressive of the transformation in plaque composition leading to a stabilization of the lesion. This hypothesis is supported by several experimental and observational studies showing lipid depletion in atherosclerotic lesions after prolonged lipid lowering either by statin or by diet (1,9,12,19). An important question that

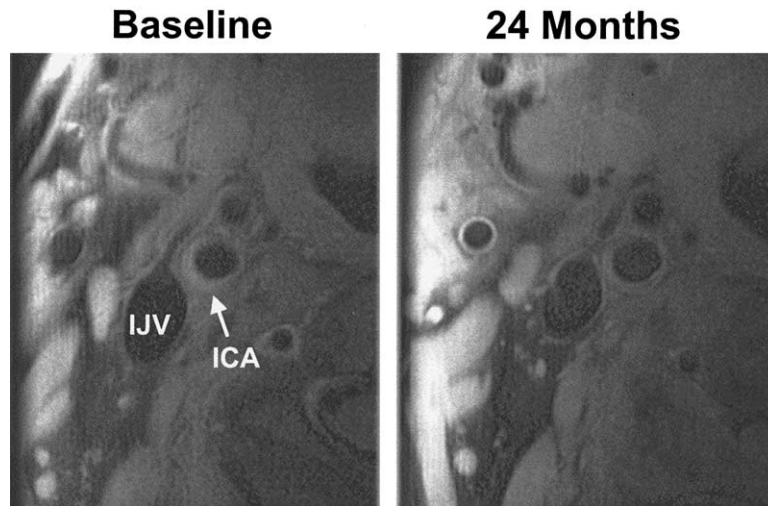


Figure 3. Representative cross-sectional magnetic resonance image of the same patient at baseline and at 24 months of statin treatment showing plaque regression at the level of the right carotid artery bifurcation. ICA = internal carotid artery; IJV = internal jugular vein.

could not be addressed by this study is whether the observed plaque regression could be achieved at an earlier time in patients with more advanced atherosclerotic lesions.

The degree of LDL-C reduction seems a good predictor for plaque regression. Three recently published studies investigated the effects of aggressive versus conventional lipid-lowering interventions in a population with more advanced atherosclerosis. The IVUS-based Reversal of Atherosclerosis with Aggressive Lipid Lowering (REVERSAL) trial (17) established the benefits of a more aggressive hypolipidemic intervention in coronary lesions, whereas the Pravastatin or Atorvastatin Evaluation and Infection Therapy (PROVE-IT) trial (20), an event-based study in patients with acute coronary syndromes, showed a significant reduction in the number of cardiovascular events by an aggressive lipid-lowering strategy compared with a conventional approach. Surprisingly, disappointing results from the Phase Z of the A to Z trial (21) were more recently reported. This large, multicenter, double-blind study in 4,497 acute coronary syndrome patients did not confirm the benefit of an early initiation of an aggressive

simvastatin regimen and resulted only in a favorable trend toward reduction of major cardiovascular events.

The hypolipidemic effect of statins and lipid removal from the atherosclerotic lesions are probably the major mechanisms responsible for the clinical benefits observed in these trials. A possible explanation for the different results between our study and the REVERSAL study rests in the different patient characteristics and the fact that we used two dosages of the same statin, whereas the REVERSAL study used two different statins. This observation, added to the contrasting results of the PROVE-IT trial (20) and Phase Z of the A to Z trial (21), also raises concerns regarding whether all of the statins are equal. Our goal was to study early-stage atherosclerotic lesions. Therefore, we selected a cohort of asymptomatic and newly diagnosed hypercholesterolemic, statin-naïve patients, who are more likely to have smaller and less fibrotic lesions.

Further studies should be performed to define the ideal “cholesterol level threshold” and the real benefits of aggressive versus conventional lipid-lowering therapy

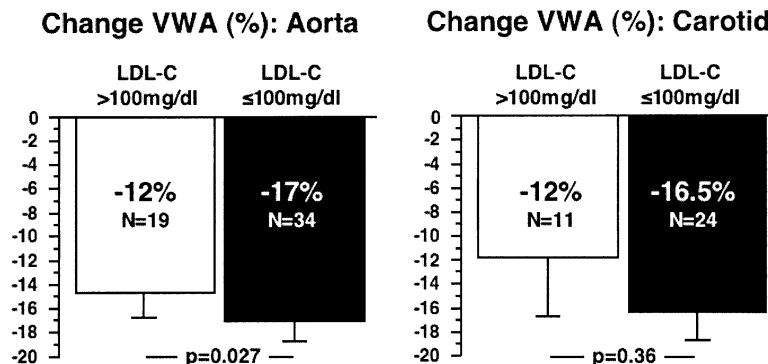


Figure 4. Effect of lipid lowering on plaque size according to the 100 mg/dl low-density lipoprotein cholesterol (LDL-C) goal. Changes in vessel wall area (VWA) are displayed according to the goal of 100 mg/dl (2.6 mmol/l). On treatment, LDL-C ≤100 mg/dl is associated with larger regression. Patients who reached the goal had a significantly higher regression in aortic lesions (**left panel**). A similar trend was seen for carotid lesions (**right panel**). The values of the last available magnetic resonance imaging examination and the baseline value were used to calculate percent changes in VWA.

when using the same drug. Several ongoing clinical trials (Incremental Decrease in End Points through Aggressive Lipid Lowering [IDEAL], Treating to New Target [TNT], Study of Effectiveness of Additional Reductions in Cholesterol and Homocysteine [SEARCH]) will probably provide an answer for this dilemma. The potential of other lipid-modifying therapies as well as approaches aimed at modifying plaque composition should be further elucidated. In 1990, Badimon et al. (22) described the anti-atherogenic effects of the administration of homologous high-density lipoprotein (HDL) in an experimental model of atherosclerosis. Spieker et al. (23) recently reported rapid normalization of endothelium-dependent vasodilation by increasing nitric oxide bioavailability after infusion of reconstituted HDL infusion in hyperlipidemic patients. Regression of human atherosclerotic lesions has been shown by IVUS after five weekly infusions of recombinant apolipoprotein A-I Milano (24). These observations raise the question of whether a combination of an LDL-lowering and HDL-raising approach could be the most effective intervention for regressing atherosclerotic lesions. The potential effectiveness of combining two interventions with different mechanisms of action has been recently investigated by our group at the preclinical level by combining a statin with a selective peroxisome proliferator-activated receptor- γ agonist (25).

In conclusion, effective and protracted lipid-lowering therapy by simvastatin is associated with a significant regression of atherosclerotic lesions. Our data strongly support the efficacy and potential clinical benefits of an effective and aggressive lipid-lowering intervention on atherosclerotic disease. Plaque regression was more related to the degree of LDL-C reduction rather than to the dose of statin, because no difference between high- and moderate-dose simvastatin was detected.

Acknowledgments

We are grateful for the technical assistance of Frank Macaluso, Paul Wisdom, Karen Metroka, and Stella Palencia.

Reprint requests and correspondence: Dr. Juan J. Badimon, Cardiovascular Biology Research Laboratory, Mount Sinai School of Medicine, One Gustave Levy Place, P.O. Box 1030, New York, New York 10029. E-mail: juan.badimon@mssm.edu.

REFERENCES

1. Aikawa M, Rabkin E, Sugiyama S, et al. An HMG-CoA reductase inhibitor, cerivastatin, suppresses growth of macrophages expressing matrix metalloproteinases and tissue factor in vivo and in vitro. *Circulation* 2001;103:276-83.
2. Crisby M, Nordin-Fredriksson G, Shah PK, Yano J, Zhu J, Nilsson J. Pravastatin treatment increases collagen content and decreases lipid content, inflammation, metalloproteinases, and cell death in human carotid plaques: implications for plaque stabilization. *Circulation* 2001;103:926-33.
3. Zhao XQ, Yuan C, Hatsukami TS, et al. Effects of prolonged intensive lipid-lowering therapy on the characteristics of carotid

- atherosclerotic plaques in vivo by MRI: a case-control study. *Arterioscler Thromb Vasc Biol* 2001;21:1623-9.
4. Libby P. Inflammation in atherosclerosis. *Nature* 2002;420:868-74.
5. Vaughan CJ, Murphy MB, Buckley BM. Statins do more than just lower cholesterol. *Lancet* 1996;348:1079-82.
6. Gotto AM Jr, Farmer JA. Pleiotropic effects of statins: do they matter? *Curr Opin Lipidol* 2001;12:391-4.
7. Takemoto M, Liao JK. Pleiotropic effects of 3-hydroxy-3-methylglutaryl coenzyme A reductase inhibitors. *Arterioscler Thromb Vasc Biol* 2001;21:1712-9.
8. Fayad ZA, Fuster V. Clinical imaging of the high-risk or vulnerable atherosclerotic plaque. *Circ Res* 2001;89:305-16.
9. Yuan C, Beach KW, Smith LH, Jr., Hatsukami TS. Measurement of atherosclerotic carotid plaque size in vivo using high resolution magnetic resonance imaging. *Circulation* 1998;98:2666-71.
10. Corti R, Fayad ZA, Fuster V, et al. Effects of lipid-lowering by simvastatin on human atherosclerotic lesions: a longitudinal study by high-resolution, noninvasive magnetic resonance imaging. *Circulation* 2001;104:249-52.
11. Effect of simvastatin on coronary atheroma: the Multicentre Anti-Atheroma Study (MAAS). *Lancet* 1994;344:633-8.
12. Brown BG, Zhao XQ, Chait A, et al. Simvastatin and niacin, antioxidant vitamins, or the combination for the prevention of coronary disease. *N Engl J Med* 2001;345:1583-92.
13. Corti R, Fuster V, Fayad ZA, et al. Lipid lowering by simvastatin induces regression of human atherosclerotic lesions: 2 years' follow-up by high-resolution noninvasive magnetic resonance imaging. *Circulation* 2002;106:2884-7.
14. Fayad ZA, Nahar T, Fallon JT, et al. In vivo magnetic resonance evaluation of atherosclerotic plaques in the human thoracic aorta: a comparison with transesophageal echocardiography. *Circulation* 2000;101:2503-9.
15. Lima JA, Desai MY, Steen H, Warren WP, Gautam S, Lai S. Statin-induced cholesterol lowering and plaque regression after 6 months of magnetic resonance imaging-monitored therapy. *Circulation* 2004;110:2336-41.
16. Jensen LO, Thayssen P, Pedersen KE, Stender S, Haghfelt T. Regression of coronary atherosclerosis by simvastatin: a serial intravascular ultrasound study. *Circulation* 2004;110:265-70.
17. Nissen SE, for the REVERSAL Investigators. Comparison of intensive versus moderate lipid lowering on the progression of coronary atherosclerosis measured by intravascular ultrasound: a randomized controlled trial. *Circulation* 2003;108:2723.
18. Heart Protection Study Collaborative Group. MRC/BHF Heart Protection Study of cholesterol lowering with simvastatin in 20,536 high-risk individuals: a randomised placebo-controlled trial. *Lancet* 2002;360:7-22.
19. McConnell MV, Aikawa M, Maier SE, Ganz P, Libby P, Lee RT. MRI of rabbit atherosclerosis in response to dietary cholesterol lowering. *Arterioscler Thromb Vasc Biol* 1999;19:1956-9.
20. Cannon CP, Braunwald E, McCabe CH, et al. Comparison of intensive and moderate lipid lowering with statins after acute coronary syndromes. *N Engl J Med* 2004;350:1495-504.
21. de Lemos JA, Blazing MA, Wiviott SD, et al. Early intensive vs a delayed conservative simvastatin strategy in patients with acute coronary syndromes: phase Z of the A to Z trial. *JAMA* 2004;292:1307-16.
22. Badimon JJ, Badimon L, Fuster V. Regression of atherosclerotic lesions by high density lipoprotein plasma fraction in the cholesterol-fed rabbit. *J Clin Invest* 1990;85:1234-41.
23. Spieker LE, Sudano I, Hurlimann D, et al. High-density lipoprotein restores endothelial function in hypercholesterolemic men. *Circulation* 2002;105:1399-402.
24. Nissen SE, Tsunoda T, Tuzcu EM, et al. Effect of recombinant ApoA-I Milano on coronary atherosclerosis in patients with acute coronary syndromes: a randomized controlled trial. *JAMA* 2003;290:2292-300.
25. Corti R, Osende JI, Fallon JT, et al. The selective peroxisomal proliferator-activated receptor- γ agonist has an additive effect on plaque regression in combination with simvastatin in experimental atherosclerosis: in vivo study by high-resolution magnetic resonance imaging. *J Am Coll Cardiol* 2004;43:464-73.