

Upper septal transformation of verapamil-sensitive idiopathic left ventricular tachycardia during catheter ablation: Wolf in sheep's clothing?



Girish M. Nair, MBBS, MSc, FRCPC, FHRS, Vinod Thomas, MD, Nik Stoyanov, MD, Pablo B. Nery, MD, Mouhannad M. Sadek, MD, FRCPC, Martin S. Green, MD, FRCPC

From the Arrhythmia Service, Division of Cardiology, University of Ottawa Heart Institute Ottawa, Ontario, Canada.

Introduction

Verapamil-sensitive fascicular ventricular tachycardia (VT) is the commonest form of idiopathic left ventricular tachycardia (ILVT).¹ The characteristic diagnostic features of fascicular ILVT include: (i) induction with atrial pacing, (ii) right bundle branch block (RBBB) with left-axis deviation morphology during VT, (iii) absence of structural heart disease, and (iv) verapamil sensitivity.^{2,3} Fascicular ILVTs are classified according to the QRS morphology into 3 subtypes: (i) left posterior fascicular (LPF) VT, exhibiting an RBBB with left-axis deviation electrocardiogram (ECG) pattern (90% of all fascicular ILVT); (ii) left anterior fascicular VT, exhibiting an RBBB with right-axis deviation ECG pattern (10% of all fascicular ILVT); and (iii) upper septal (US) fascicular VT, exhibiting a narrow QRS pattern with normal or right-axis deviation (very rare; <1% of all ILVT).^{1,4,5}

The US variant of ILVT can be mistaken for supraventricular tachycardia (SVT), and in certain situations it can be incessant, resulting in tachycardia-induced cardiomyopathy.^{6,7} In a multicenter registry of 193 verapamil-sensitive ILVT subjects, 12 subjects (6.2%) were found to have the US variant, of whom 6 (50%) had previously undergone catheter ablation for the common LPF variant. We present an interesting and hitherto unreported case of fascicular ILVT

with transformation from the common LPF variant to the US variant during catheter ablation.

Case report

A 35-year-old man presented with a 5-year history of recurrent episodes of symptomatic palpitations requiring multiple emergency department visits. ECGs recorded during these episodes demonstrated a wide complex tachycardia with a QRS width of 130 milliseconds and RBBB with a left-axis deviation pattern (Figure 1). Verapamil infusion was successful in terminating the tachycardia on multiple occasions, and the differential diagnoses included the LPF variant of ILVT and SVT with aberrant conduction. An echocardiogram revealed a structurally normal heart.

The subject underwent an electrophysiological study with the intent to perform catheter ablation. Standard multielectrode catheters were positioned in the high right atrium, the His-bundle region, the right ventricular apex, and the coronary sinus. Baseline electrophysiological parameters were found to be within normal limits. No evidence of dual atrioventricular (AV) nodal physiology, manifest preexcitation, or concealed accessory pathway conduction was found. The clinical tachycardia could be reproducibly induced by burst pacing from the right ventricular apex and spontaneously during isoprenaline infusion at 3 µg/min.

The induced tachycardia was regular, and the measured cycle length (CL) was 290 milliseconds. The QRS duration during tachycardia measured 135 milliseconds with an RBBB-left-axis pattern on the surface ECG. There was 1:1 ventriculoatrial (VA) association during the tachycardia with central VA activation (earliest atrial activation noted close to the His-bundle region), and the HV interval was negative. Atrial pacing at a CL much shorter than the tachycardia CL dissociated the atrium from the ventricle, indicating that the atrium was not part of the arrhythmia circuit. However, atrial overdrive pacing at a CL of 30 milliseconds less than the tachycardia CL was able to demonstrate constant and progressive fusion consistent with entrainment and suggested a reentrant mechanism for the arrhythmia. Based on these electrophysiological findings, the absence of manifest

KEYWORDS Idiopathic verapamil-sensitive left ventricular tachycardia; Variants of ILVT; Upper septal transformation; Electrophysiological features; Catheter ablation

ABBREVIATIONS AV = atrioventricular; CL = cycle length; ECG = electrocardiogram; ILVT = idiopathic left ventricular tachycardia; IVS = interventricular septum; LIVS = left ventricular aspect of the interventricular septum; LPF = left posterior fascicular; LV = left ventricular; RBBB = right bundle branch block; RF = radiofrequency; SVT = supraventricular tachycardia; US = upper septal; VA = ventriculoatrial; VT = ventricular tachycardia (Heart Rhythm Case Reports 2016;2:101-106)

Conflicts of interest: The authors have no conflicts of interest to declare.

Address reprint requests and correspondence: Dr Girish M. Nair, H-1285-B University of Ottawa Heart Institute, 40 Ruskin Ave, Ottawa, Ontario, Canada K1Y 4W7. E-mail address: gnair@ottawaheart.ca.

KEY TEACHING POINTS

- Upper septal verapamil-sensitive idiopathic left ventricular tachycardia is a rare variant that may be mistaken for supraventricular tachycardia.
- Damage to the left posterior fascicle of the Purkinje system may be responsible for the development of this arrhythmia.
- The upper septal variant may be responsible for recurrences after catheter ablation of the common variants of verapamil-sensitive idiopathic left ventricular tachycardia, and this variant rarely can present with incessant episodes leading to tachycardia-induced cardiomyopathy.
- The site for catheter ablation of this arrhythmia is distal to the proximal left bundle, at the intersection of the proximal and midsegments of the anterior interventricular septum.
- Catheter ablation should be performed cautiously in this region to avoid damage to the conduction system.

preexcitation of the ventricular myocardium, consistent termination with overdrive right ventricular pacing and verapamil infusion, a diagnosis of the LPF variant of ILVT was made.

An octapolar deflectable catheter (1.0-mm tip electrode and 2-10-2-2-5-2-mm interelectrode spacing, Biosense Webster, Diamond Bar, CA) was positioned via the retrograde aortic approach to map the left ventricular (LV) aspect of the interventricular septum (IVS) during tachycardia. An electroanatomic map of the LV and aorta was created using CARTO (version 3; Biosense Webster) via the trans-septal and retrograde aortic approaches. Image integration was performed with a previously acquired 3-dimensional computed tomography reconstruction of the LV and aorta. The location of the AV node and the course of the His bundle and the posterior and anterior fascicles of the left bundle were identified and marked on the electroanatomic map (Figure 2). During tachycardia, Purkinje potentials in the region of the left posterior fascicle were identified on the ablation catheter (Thermocool SMARTTOUCH, Biosense Webster) and the octapolar recording catheter. Presystolic Purkinje potentials were noted 28 milliseconds ahead of the earliest surface QRS complexes in the distal third of the left posterior apical septum (Figure 2A). Radiofrequency (RF) energy (power of 30–35 W; 60–120 second duration) was applied to create a linear lesion set transecting the posterior region of the IVS at the intersection of the mid- and apical segments of the LV (Figure 2).

During delivery of RF energy in the region of the LPF, the wide complex tachycardia (QRS width 135 milliseconds; CL -299 milliseconds) abruptly transitioned to a narrow complex tachycardia (QRS width 85 milliseconds; CL -281

milliseconds) (Figure 3A). The narrow complex tachycardia had a 1:1 VA relationship with a relatively short VA time and a concentric atrial activation pattern. The narrow complex tachycardia showed the following ECG characteristics: a right-axis deviation ($>90^\circ$ during tachycardia vs 60° during sinus rhythm), poor progression of R waves, lack of precordial transition, lack of R wave in lead V_1 and an RS ratio in lead V_6 consistent with VT (Figure 1). The HV interval during the narrow complex tachycardia of 21 milliseconds was significantly shorter than that of the HV interval of 42 milliseconds during sinus rhythm (Figures 3A and 3B). Maneuvers to distinguish an SVT from VT were performed to confirm the fact that the narrow complex tachycardia was in fact a US variant of ILVT. The diastolic Purkinje potential of the septal Purkinje network was mapped during the US ILVT, close to the hypothetical “upper turnaround point” at the left basal septum just distal to the left main bundle.^{1,5} RF ablation was continued along the previous linear ablation set to transect the entire IVS in its midsegment, so as to avoid damage to the main left bundle and AV node (Figure 2). The US ILVT terminated during RF delivery and subsequent programmed stimulation and isoprenaline infusion were unable to induce the LPF and US variants of ILVT. The subject has completed 16 months of follow-up without VT recurrence.

Discussion

Our case report highlights a rare variant of verapamil-sensitive ILVT—the US variant. Very little is known about the surface ECG and electrophysiological characteristics of this rare arrhythmia. In a series of 12 subjects with the US variant of ILVT, the ECG findings in sinus rhythm included Q waves in the inferior leads and/or an S wave in leads I and aVL. In 6 of these subjects, the ECG findings developed after previous catheter ablation, in the region of the left posterior fascicle for common LPF variant of ILVT. However, in the other 6 subjects, the ECG findings described previously were not related to prior catheter ablation or structural heart disease.⁵ In our case, the ECG during US ILVT, after transitioning from the LPF variant of ILVT during catheter ablation, and the sinus rhythm ECG after successful completion of the procedure demonstrated the previously described ECG findings. These observations seem to suggest that the US ILVT variant develops in subjects with damage to the left posterior fascicle and the adjacent IVS muscle either spontaneously or as a result of catheter ablation.

Our case is unique in that the US ILVT transitioned from the LPF variant of ILVT during the index catheter ablation procedure, while the left posterior fascicular region of the IVS was being ablated. This phenomenon has not been previously described and lends credence to the theory that damage to the left posterior fascicle possibly alters the ILVT reentrant circuit, resulting in the transformation to US ILVT.

It is hypothesized that the antegrade limb of the VT circuit of the LPF variant of ILVT penetrates the distal third of the posterior apical LV septum via the verapamil-sensitive,

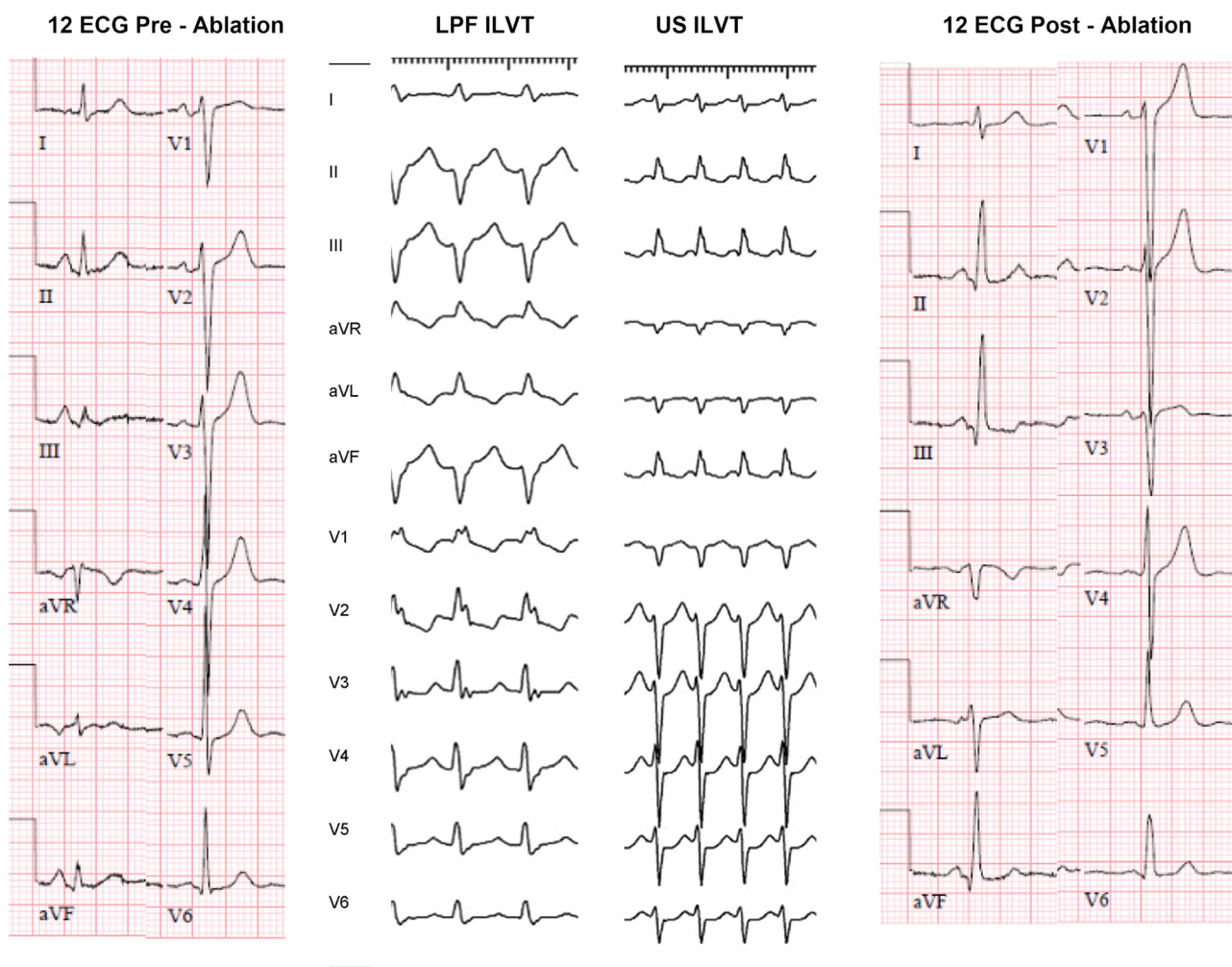


Figure 1 Figure showing electrocardiogram in sinus rhythm (both preablation and postablation), left posterior fascicular idiopathic left ventricular tachycardia (LPF ILVT) and upper septal idiopathic left ventricular tachycardia (US ILVT). The preablation 12-lead electrocardiogram is within normal limits.

“abnormal,” left septal Purkinje network (zone of slow conduction) to the “lower turnaround point,” where 2 diverging wave fronts meet in the posterior apical septum. The retrograde limb of the reentrant circuit is thought to be the posterior fascicle of the “normal” Purkinje system (zone of fast conduction). Nogami,¹ using multielectrode catheters during electrophysiological testing, demonstrated the presence of the arrhythmia circuit in the form of 2 distinct series of Purkinje potentials that converged near the apex, representing the antegrade and retrograde limbs of the reentrant circuit. The “upper turnaround point” of this macroreentrant circuit is thought to be in the vicinity of the left main bundle, at a relatively more basal location than that of the LPF variant of ILVT.^{1,4,5,8–12}

Talib and colleagues⁵ performed electrophysiological studies in a series of 12 subjects with US ILVT. The ECG morphology during VT and sinus rhythm were identical in 6 subjects, and in the rest they noticed an incomplete RBBB pattern. The QRS width during US ILVT was slightly wider than that in sinus rhythm (104 ± 18 milliseconds vs 90 ± 18 milliseconds), and the HV interval was always shorter than that during sinus rhythm (27 ± 5 milliseconds vs 47 ± 10

milliseconds). The electrophysiological findings during the narrow complex tachycardia in our case were consistent with those described by Talib and colleagues,⁵ confirming that our case was an US ILVT. In US ILVT, there is reversal of the reentrant arrhythmia circuit, with the “normal” Purkinje fibers in the region of the left posterior fascicle constituting the antegrade limb and the “abnormal” Purkinje fibers the retrograde limb of the arrhythmia circuit. In addition, the “upper turnaround point” is reversed in this case, and the convergence of the 2 limbs occurs at the anterior portion of the IVS in the vicinity of the left bundle, at a relatively more basal location than that of the LPF ILVT reentrant circuit^{5,13} (Figures 2A and 2B).

The most likely explanation for the change in frontal QRS axis from the left superior quadrant to the right inferior quadrant during transition from the LPF variant to the US ILVT is probably related to the previously mentioned “reversal” of conduction in the reentry circuit. Engagement of the His–Purkinje system at a more proximal level (relative to that of the LPF ILVT circuit) is probably the reason for the narrowing of the QRS width during US ILVT compared with that during the LPF variant. Catheter ablation in this region,

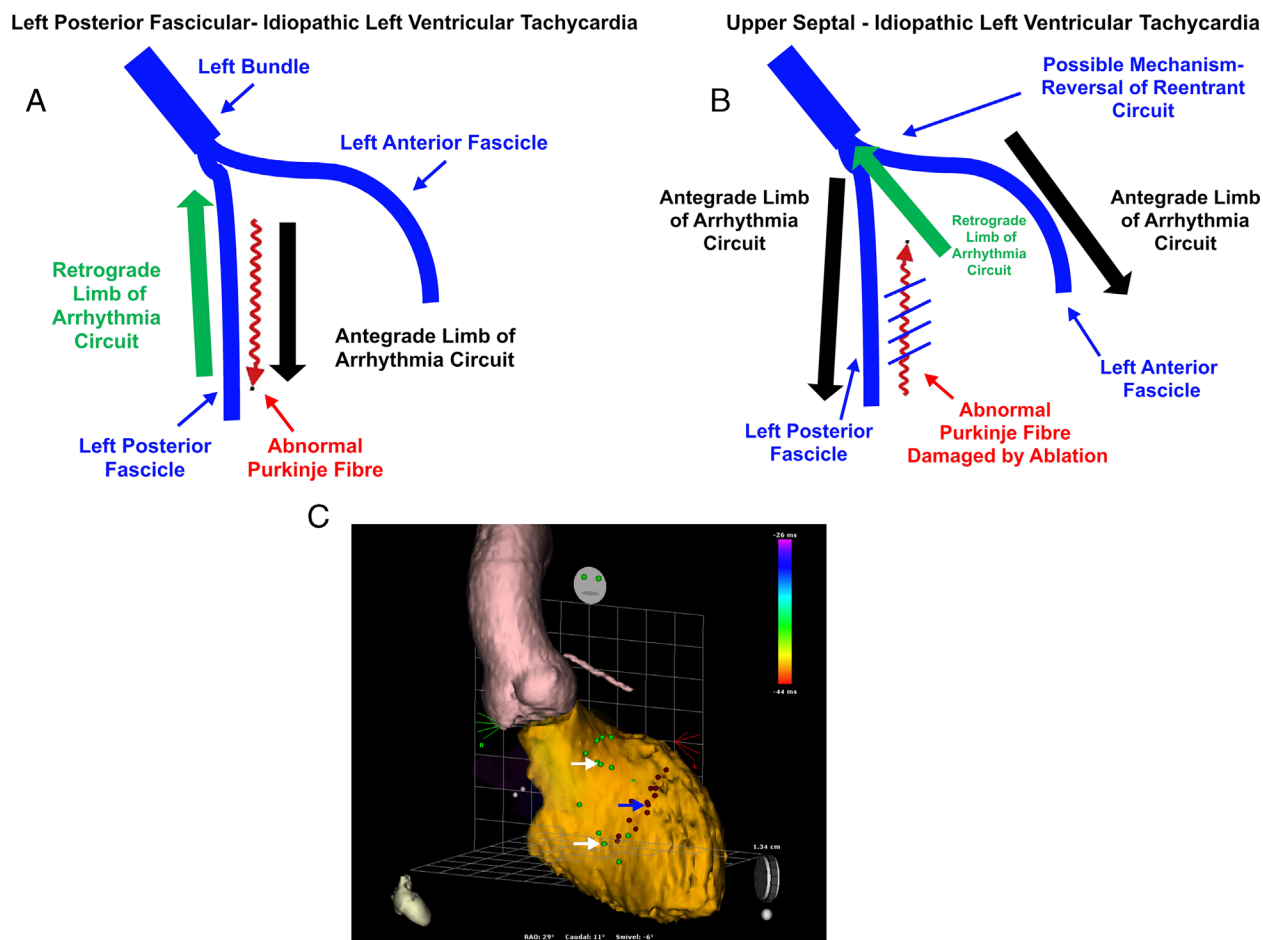


Figure 2 A: An illustration of the currently postulated mechanism of left posterior fascicular idiopathic left ventricular tachycardia. B: An illustration of the possible mechanism of transformation of the left posterior fascicular variant to the upper septal idiopathic left ventricular tachycardia variant. C: A view of the interventricular septal aspect of the left ventricle showing the ablation lesion set (blue arrow; maroon dots), the location of the atrioventricular node, the proximal left bundle, and the anterior and posterior fascicles (white arrows; green dots). The ablation line extends along the entire width of the interventricular septum and was created in the midportion to avoid the proximal left bundle and atrioventricular node.

such as that in our case, successfully interrupts the arrhythmia circuit and terminates US ILVT. However, RF energy should be delivered with caution and along the midanterior portion of the IVS to avoid injury to the left bundle and AV node.

We hypothesize that RF ablation or other forms of damage to the region of the left posterior fascicle probably alters the conduction and refractory properties of the verapamil-sensitive left septal Purkinje network, resulting in reversal of the “slow-fast” LPF variant of ILVT to a “fast-slow” US ILVT. However, it is possible that the differences noted in the electrophysiological characteristics of US ILVT may represent an altogether different reentrant circuit, especially in subjects without previous catheter ablation for LPF ILVT.

Conclusions

It is important to be aware of the US variant of verapamil-sensitive ILVT, as it can cause recurrent ILVT after catheter

ablation of the common variants.⁵ In addition, US ILVT may be incessant and lead to tachycardia-induced cardiomyopathy. The electrophysiological features and mechanism of US ILVT are different from the common variants of verapamil-sensitive ILVT. It is important that interventional electrophysiologists recognize these features in order to be able to perform effective catheter ablation, without causing collateral damage to the AV node or the proximal left bundle.^{5,13} Finally, US ILVT may mimic supraventricular arrhythmias such as AVNRT, and an incorrect diagnosis in this situation may result in RF energy delivery to the region of the AV node, with the possibility of damage to the conduction system.^{5-7,14} Our subject was fortunate that the US ILVT occurred during the index catheter ablation for the clinical LPF variant of ILVT and that we were able to successfully ablate both ILVTs during the same session.

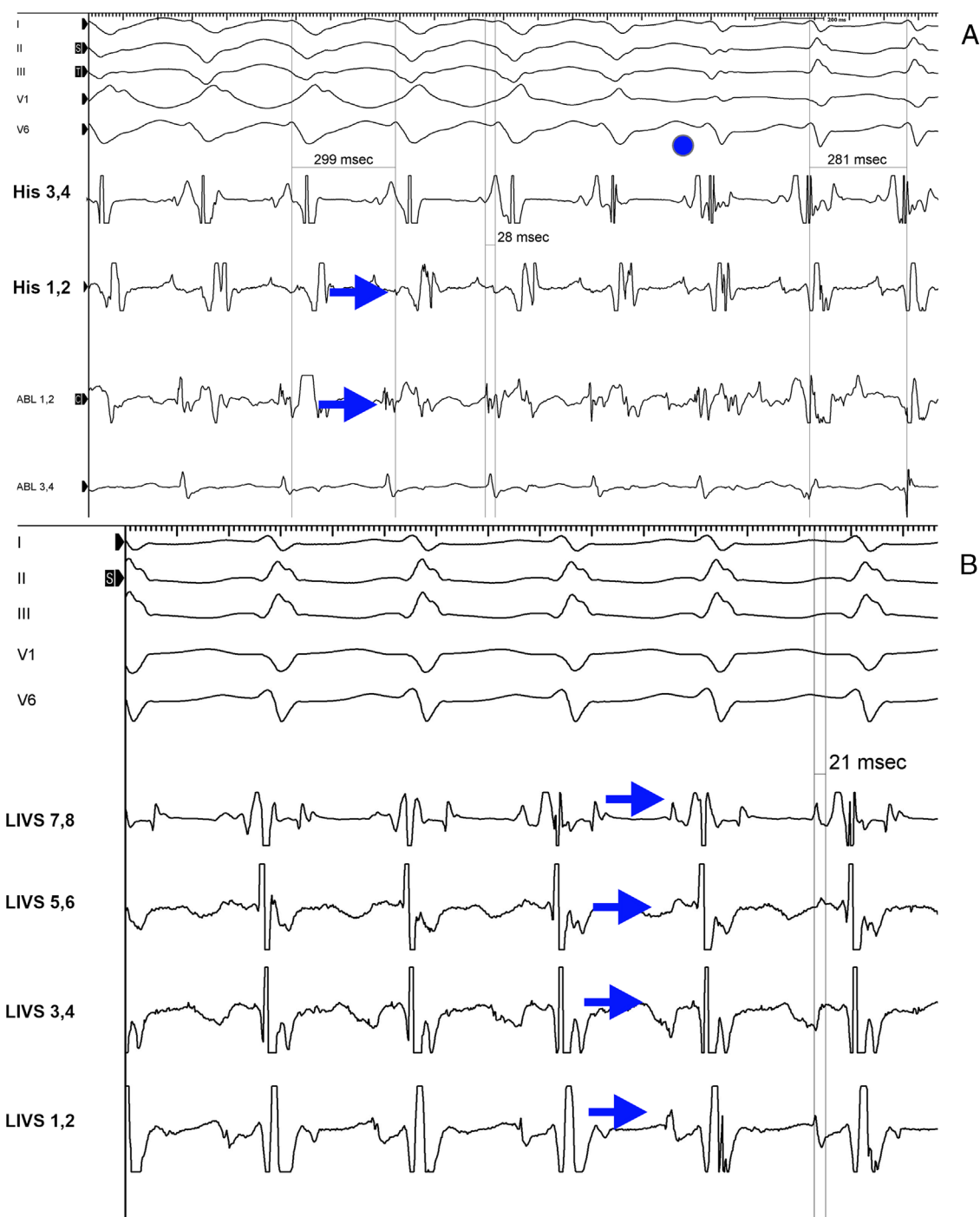


Figure 3 **A:** This illustration shows the transition of the left posterior fascicular variant of idiopathic left ventricular tachycardia (ILVT) to upper septal ILVT during catheter ablation. The transition point has been marked with a blue dot. **B:** This illustration shows the octapolar catheter recording (labeled LIVS 1–8 in pairs) during upper septal ILVT. The octapolar catheter has been positioned along the left ventricular aspect of the interventricular septum (LIVS). The distal-most electrodes (LIVS 1,2) are positioned at the apex, and the proximal-most electrodes (LIVS 7,8) are at the level of the proximal left bundle. The Purkinje potential to the earliest surface QRS interval was 21 milliseconds (compared with 42 milliseconds during sinus rhythm). Purkinje potentials are indicated by the blue arrows.

References

1. Nogami A. Purkinje-related arrhythmias part I: monomorphic ventricular tachycardias. *Pacing Clin Electrophysiol* 2011;34(5):624–650.
2. Zipes DP, Foster PR, Troup PJ, Pedersen DH. Atrial induction of ventricular tachycardia: reentry versus triggered automaticity. *Am J Cardiol* 1979;44(1):1–8.
3. Belhassen B, Rotmensch HH, Laniado S. Response of recurrent sustained ventricular tachycardia to verapamil. *Br Heart J* 1981;46(6):679–682.
4. Ohe T, Shimomura K, Aihara N, Kamakura S, Matsuhisa M, Sato I, Nakagawa H, Shimizu A. Idiopathic sustained left ventricular tachycardia: clinical and electrophysiologic characteristics. *Circulation* 1988;77(3):560–568.
5. Talib AK, Nogami A, Nishiuchi S, et al. Verapamil-sensitive upper septal idiopathic left ventricular tachycardia: prevalence, mechanism, and electrophysiological characteristics. *JACC Clin Electrophysiol* 2015;1(5):369–380.
6. Abdelwahab A, Sapp JL, Gardner M, Basta MN. A case of narrow complex tachycardia. *J Cardiovasc Electrophysiol* 2008;19(3):330–331.

7. Namboodiri N, Bohora S, Ajitkumar VK, Tharakan JA. Narrow complex tachycardia with ventriculoatrial dissociation—what is the mechanism? *Pacing Clin Electrophysiol* 2011;34(6):756–759.
8. Nogami A, Naito S, Tada H, Taniguchi K, Okamoto Y, Nishimura S, Yamauchi Y, Aonuma K, Goya M, Iesaka Y, Hiroe M. Demonstration of diastolic and presystolic Purkinje potentials as critical potentials in a macroreentry circuit of verapamil-sensitive idiopathic left ventricular tachycardia. *J Am Coll Cardiol* 2000;36(3):811–823.
9. Ouyang F, Cappato R, Ernst S, Goya M, Volkmer M, Hebe J, Antz M, Vogtmann T, Schaumann A, Fotuhi P, Hoffmann-Riem M, Kuck KH. Electroanatomic substrate of idiopathic left ventricular tachycardia: unidirectional block and macroreentry within the Purkinje network. *Circulation* 2002;105(4):462–469.
10. Thakur RK, Klein GJ, Sivaram CA, Zardini M, Schleinkofer DE, Nakagawa H, Yee R, Jackman WM. Anatomic substrate for idiopathic left ventricular tachycardia. *Circulation* 1996;93(3):497–501.
11. Tsuchiya T, Okumura K, Honda T, Honda T, Iwasa A, Yasue H, Tabuchi T. Significance of late diastolic potential preceding Purkinje potential in verapamil-sensitive idiopathic left ventricular tachycardia. *Circulation* 1999;99(18):2408–2413.
12. Nakagawa H, Beckman KJ, McClelland JH, et al. Radiofrequency catheter ablation of idiopathic left ventricular tachycardia guided by a Purkinje potential. *Circulation* 1993;88(6):2607–2617.
13. Shimoike E, Ueda N, Maruyama T, Kaji Y. Radiofrequency catheter ablation of upper septal idiopathic left ventricular tachycardia exhibiting left bundle branch block morphology. *J Cardiovasc Electrophysiol* 2000;11(2):203–207.
14. Vora AM, Tang AS, Green MS. Idiopathic left ventricular tachycardia: what is the mechanism? *Pacing Clin Electrophysiol* 1997;20(11):2855–2856.