



Contents lists available at ScienceDirect

## International Journal of Surgery Case Reports

journal homepage: [www.casereports.com](http://www.casereports.com)

# Inflammatory myofibroblastic tumor of the small-bowel mesentery: A case report of nonspecific clinical presentation and a review of the literature



Ali Koyuncuer\*

Department of Pathology, Antakya State Hospital, Hatay, Turkey

## ARTICLE INFO

## Article history:

Received 8 August 2014

Received in revised form

14 November 2014

Accepted 15 November 2014

Available online 20 November 2014

## Keywords:

Bowel

Inflammatory

Mesentery

Myofibroblastic

Small

Tumor

## ABSTRACT

**INTRODUCTION:** Inflammatory myofibroblastic tumor (IMT) is a rare neoplasm of various anatomical sites, which is histopathologically characterized by spindle-shaped cells with myofibroblastic proliferation and inflammatory infiltration.

**PRESENTATION OF CASE:** In this case report, a 37-year-old man presented with nonspecific systemic symptoms, including abdominal pain and weakness, which was diagnosed by multislice computed tomography and ultrasonography. An 8 cm × 5 cm × 5 cm nodular gray-white firm noninfiltrative mass, which was well localized in the mesentery tissues of small bowel, was observed and the patient underwent surgical resection.

**DISCUSSION:** A review of the literature on IMT of the small-bowel mesentery yielded a small number of previously described cases. This tumor most frequently involves the lungs and arises most commonly in extrapulmonary locations such as the mesentery and omentum. The etiopathogenesis and the clinical course of the disease are unclear. The histological and clinical differential diagnosis of IMT also includes reactive processes and mesenchymal tumors of the gastrointestinal tract. Follow-up after surgical removal documented local recurrence and metastasis.

**CONCLUSION:** The preferred primary treatment is complete surgical excision, and patients require close clinicoradiological follow-up. In general, cases treated with complete surgical resection have a good prognosis.

© 2014 The Author. Published by Elsevier Ltd. on behalf of Surgical Associates Ltd. This is an open access article under the CC BY-NC-ND license (<http://creativecommons.org/licenses/by-nc-nd/3.0/>).

## 1. Introduction

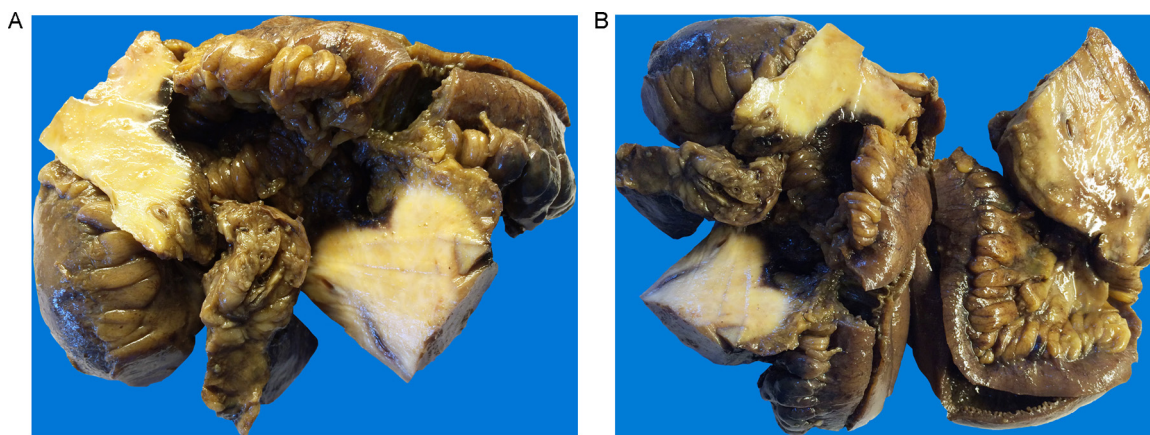
Inflammatory myofibroblastic tumors (IMTs) were originally termed by Bunn in 1939.<sup>1</sup> Alternative names including plasma cell granuloma, inflammatory pseudotumor, and myxoid hamartoma have all been used for this lesions. IMT occurs in children and young adults in soft tissues and viscera in various anatomical regions<sup>2</sup> and shows a benign clinical course. Local recurrence or distant metastasis can develop during the course of intra-abdominal and retroperitoneal disease.<sup>3</sup> This tumor most frequently arises from the lung and the most common extrapulmonary locations in descending order are the abdomen (including the retroperitoneum and pelvis), head/neck, upper respiratory tract, trunk, extremities,<sup>4</sup> and uterine.<sup>5</sup> There are a very small number of IMT in the small intestine mesentery cases reported in the literature.<sup>6</sup>

## 2. Presentation of case

### 2.1. Clinical data and presentation

A 37-year-old man presented with nonspecific systemic symptoms, such as abdominal pain, fever, weight loss, and weakness, to the emergency department of a state hospital. On admission revealed clinical sign of pain in the around the epigastric, periumbilical region and abdominal palpable masses, rigidity. Laboratory tests on admission showed: WBC: 11.000/mm<sup>3</sup>, Hb: 14.7 g/dl, Hct: 45.6% and normal ALT, AST levels, hepatitis B, HCV, HIV viral markers. Case had presented to the emergency department with suspicious for a malignancy, hence a preoperative biopsy was not performed. Abdominal ultrasonography and computer tomography (CT) imaging showed a solid mass in the right intra-abdominal region. The clinical impression was that the lesion represented tumor. Intraoperatively, a large tumor was found involving the small bowel mesentery and no extension or pressure to adjacent organs. No intraoperative complications were observed. Our patient underwent an without any complications postoperative

\* Tel.: +90 506 3819352; fax: +90 326 2272440.  
E-mail address: [alikoyuncuer@hotmail.com](mailto:alikoyuncuer@hotmail.com)



**Fig. 1.** (A, B) Gross features: the macroscopic appearance of inflammatory myofibroblastic tumor in the small bowel specimen.

course, the patient was discharged on the 7th postoperative day. The patient underwent segmental small intestine resection.

## 2.2. Histopathological findings

### 2.2.1. Macroscopic appearance

The specimen was collected from the small bowel and consisted of a segment of intestine measuring 20 cm in length  $\times$  2.5 cm in average diameter (2 cm circumference proximal margin, 1.5-cm circumference distal margin) after fixation in 10% neutral buffered formalin. A serial section of the small bowel specimen of patient did not reveal infiltrative tumors in the intra-luminal compartment. Gross findings of the nonperitonealized perimuscular tissue or mesentery tissues showed nodular features and gray-white firm noninfiltration, and a well-localized, well-demarcated smooth discrete mass measuring 8 cm  $\times$  5 cm  $\times$  5 cm. The cut surface section of the lesion had a diffuse gray or yellow appearance. Macroscopic tumor perforation, necrosis, hemorrhage, calcification, and ulceration were not identified (Fig. 1A and B).

### 2.2.2. Microscopic features

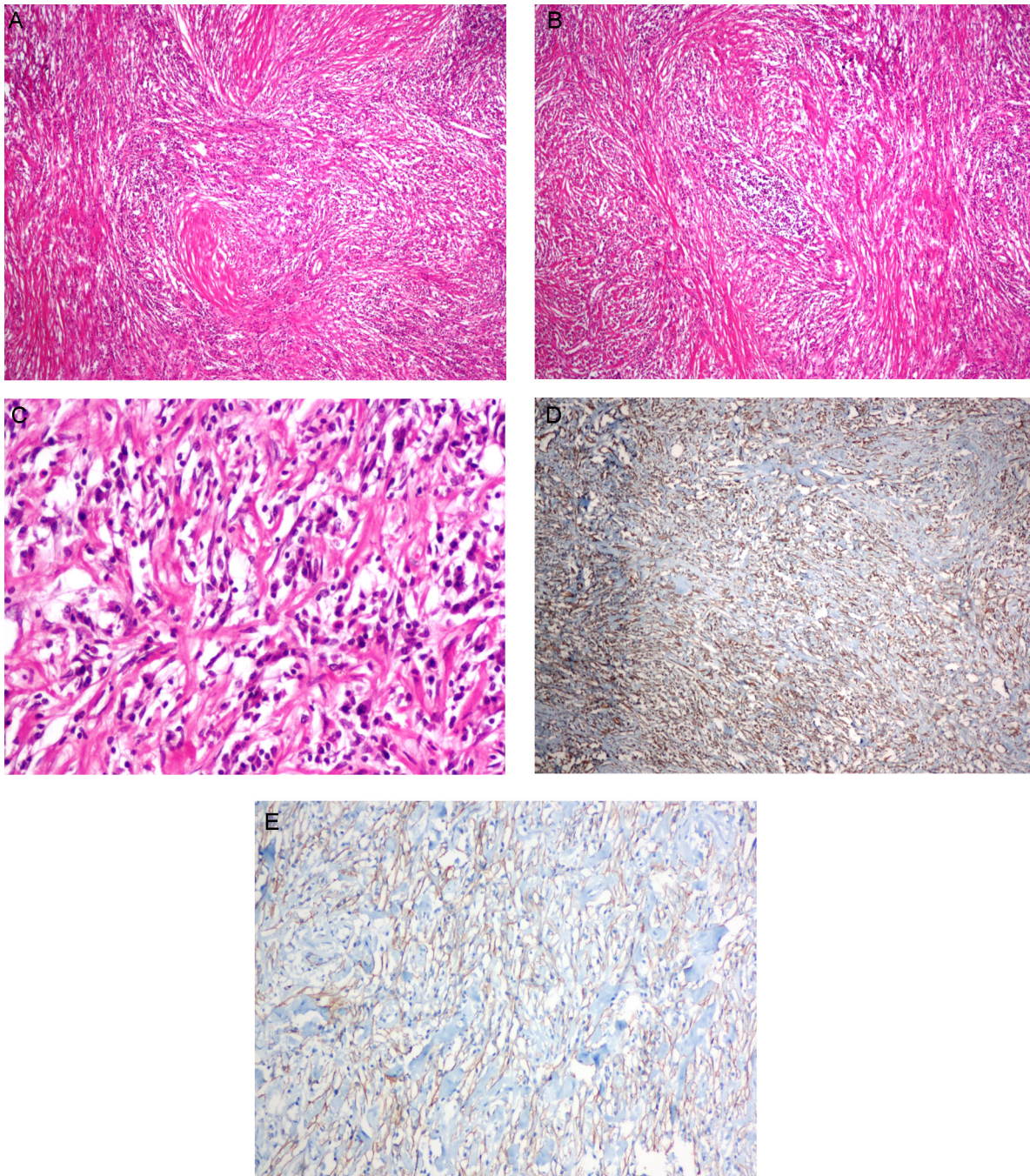
Histologically, the tumor appeared to predominantly consist of plasma cells, lymphocytes, and plump- or spindle-shaped cells of myofibroblasts. The tumor had a prominent storiform and fascicular pattern with collagenized areas and lymphocytes; plasma cells formed small aggregates or nodules of lymphoid background. Mitosis, necrosis, and myxoid background were not present. The tumor cells were positive for smooth muscle actin and vimentin and negative for antibodies to CD117, S100, CD34, desmin, CD30, and Ki-67 (Fig. 2A–D).

## 3. Discussion

Previously described in the literature as inflammatory pseudotumor, the current term for the condition is IMT.<sup>7</sup> IMT lesions are composed entirely of spindle cells with characteristic of cells of myofibroblastic origin.<sup>8</sup> In this setting, IMT occurs in various age groups, and is slightly more common in women than in men.<sup>2</sup> Coffin et al.<sup>4</sup> reported a mean age of 9.7 years (range, 3 months–46 years) for IMT patients. The disease appears to result from diverse etiologies, including Epstein–Barr virus, human herpes virus 8, elevated levels of cytokines (i.e., interleukin-6),<sup>9</sup> reparative, postoperative, and mycobacterial infections,<sup>2</sup> and post-traumatic injury, to name a few.<sup>10</sup> IMT occurred in our case even without a history of abdominal trauma or surgery. Using immunocytochemical techniques, Freeman et al.<sup>11</sup> reported anaplastic lymphoma kinase

(ALK) 1 in the urinary bladder of IMT patients (eight/nine cases). Whereas, molecular studies have demonstrated rearrangements in chromosome 2p23, and ALK gene rearrangements has been identified in approximately 33–67% of IMT cases. Fluorescence in situ hybridization analysis was performed to accurately identify ALK rearrangements.<sup>12</sup> The clinical presentation differs depending on the anatomical regions examined. Clinically, intra-abdominal or retroperitoneal tumors present as palpable masses, with symptoms of abdominal pain and weight loss that can be obstructive,<sup>13</sup> and diarrhea in children.<sup>10</sup> Moreover, lung tumors present as dyspnea, pain, fever, and cough.<sup>14</sup> Ntloko et al.<sup>10</sup> reported that the most common symptoms/signs of IMT are abdominal pain and change in intestinal habits; however, our case presented with non-specific symptoms such as acute abdominal pain and no vomiting or intestinal obstruction. The predominant extrapulmonary IMT regions involve include the mesentery and omentum.<sup>3</sup> However, the gastroesophageal junction, colon, rectum, appendix,<sup>15</sup> small bowel, gastric wall<sup>16</sup> and rarely, other regions of the gastrointestinal tract may be implicated. Our case presented with an ileojejunum mass of mostly mesenteric or subserosal adipose tissue growth. In general, masses appear on gross examination of a resection specimen as nodular and lobular, myxoid background sometimes with features of necrosis and hemorrhage.<sup>12</sup> These lesions measure from 2 to 20 cm in largest dimension<sup>2</sup> and the mean tumor size reported in the literature is 8 cm.<sup>8</sup> A recent study of IMT described three major histological characteristics. The first mainly involves inflammatory cells and has myxoid stroma. The second shows compact proliferation of spindle-shaped cells. The third contains abundant collagen in a plate-like pattern.<sup>17</sup> Yamamoto et al.<sup>18</sup> have reported lymphoplasmacytic infiltration containing germinal center in the lymphoid follicles in the latter feature. In our case, IMT displayed extensive lymphoid follicles, and microscopically, a mixture of inflammatory infiltrates composed largely of lymphocytes and plasma cells; few eosinophils are present. Atypical cells, mitosis, myxoid stroma, and necrosis were not present, but small clusters were present in neuronal hyperplasia in the fibrous stroma. The differential diagnosis of IMT includes reactive/reparative lesions and mesenchymal tumors of the gastrointestinal tract including granulation tissues and nodular fasciitis in reactive processes,<sup>4</sup> spindle cell sarcomas, spindle cell melanomas, and sarcomatoid carcinomas, dedifferentiated liposarcoma, gastrointestinal stromal tumors, Hodgkin's lymphoma, inflammatory fibroid polyp, and other fibro-inflammatory processes (or pseudoneoplasms) and malignant tumors.<sup>2,19</sup> Approximately 25% of patients with extrapulmonary IMT have recurrence, and distant metastasis (rate: <5%) has been reported. The principal therapy in patients with IMT is





**Fig. 2.** (A, B) Low power view demonstrating prominent storiform and fascicular pattern collagenized areas and chronic inflammatory cells (Hematoxylin and Eosin, 40 $\times$ ). (C) High-power magnification demonstrating the presence of tumor consist spindle cells shaped of myofibroblasts, mature plasma cells and lymphocytes (Hematoxylin and Eosin, 200 $\times$ ). (D) Immunohistochemically positive for smooth muscle actin (200 $\times$  objective). (E) Immunohistochemically positive for vimentin (40 $\times$  objective).

surgical resection, and in some situations, corticosteroids and non-steroidal anti-inflammatory drugs may be useful.<sup>4</sup> In our case, after approximately one month of follow-up, there was no evidence of symptoms or recurrent disease.

#### 4. Conclusion

Clinical behavior of IMT are similar to tumors of uncertain malignant potential. The tumors are generally biologically benign lesions that do not present a high risk of local recurrence and distant metastases. The preferential method of treatment is complete surgical excision of the lesion, and close clinicoradiological follow-up

with ultrasonography, chest roentgenography, and abdominal CT imaging is necessary. Previous studies report a considerably better prognosis in IMT patients with this method of treatment.

#### Conflict of interest

No financial competing interests.

#### Funding source

None.

## Ethical approval

Written informed consent was obtained from the patient for publication of this case report and its accompanying images. A copy of the written consent is available for review by the Editor-in-Chief of this journal upon request.

## Author contributions

Ali Koyuncuer: collected data, designed the research and wrote the paper.

## References

1. Palaskar S, Koshti S, Maralingannavar M, Bartake A. Inflammatory myofibroblastic tumor. *Contemp Clin Dent* 2011;**2**:274–7, <http://dx.doi.org/10.4103/0976-237X.91787>.
2. Goldblum JR, Folpe AL, Weiss SW. *Inflammatory myofibroblastic tumor. Enzinger and Weiss's soft tissue tumors*. 6th ed. Philadelphia, PA: Saunders; 2013. p. 304–10.
3. Difiore JW, Goldblum JR. Inflammatory myofibroblastic tumor of the small intestine. *J Am Coll Surg* 2002;**194**(April (4)):502–6.
4. Coffin CM, Watterson J, Priest JR, Dehner LP. Extrapulmonary inflammatory myofibroblastic tumor (inflammatory pseudotumor). A clinicopathologic and immunohistochemical study of 84 cases. *Am J Surg Pathol* 1995;**19**(August (8)):859–72.
5. Kushnir CL, Gerardi M, Banet N, Shih IEM, Diaz-Montes T. Extraterine inflammatory myofibroblastic tumor: a case report. *Gynecol Oncol Case Rep* 2013;**6**(July):39–41, <http://dx.doi.org/10.1016/j.gynor.2013.07.007>.
6. Choi AH, Bohn OL, Beddow TD, McHenry CR. Inflammatory myofibroblastic tumor of the small bowel mesentery: an unusual cause of abdominal pain and uveitis. *J Gastrointest Surg* 2011;**15**(April (4)):584–8, <http://dx.doi.org/10.1007/s11605-010-1408-3>.
7. Chen CK, Jan CI, Tsai JS, Huang HC, Chen PR, Lin YS, et al. Inflammatory myofibroblastic tumor of the lung—a case report. *J Cardiothorac Surg* 2010;**5**(July):55, <http://dx.doi.org/10.1186/1749-8090-5-55>.
8. Turner JR, Odze RD. Inflammatory myofibroblastic tumor. In: Odze RD, Goldblum JR, editors. *Surgical pathology of the GI tract, liver biliary tract, and pancreas*. 2nd ed. Philadelphia, PA: Saunders; 2009. p. 441.
9. Attili SV, Chandra CR, Hemant DK, Bapsy PP, RamaRao C, Anupama G. Retroperitoneal inflammatory myofibroblastic tumor. *World J Surg Oncol* 2005;**3**(October):66.
10. Ntloko S, Gounden A, Naidoo M, Madiba TE, Singh Y, Ramdial PK, et al. Intestinal inflammatory myofibroblastic tumour. *S Afr J Surg* 2011;**49**(November (4)):190–3.
11. Freeman A, Geddes N, Munson P, Joseph J, Ramani P, Sandison A, et al. Anaplastic lymphoma kinase (ALK 1) staining and molecular analysis in inflammatory myofibroblastic tumours of the bladder: a preliminary clinicopathological study of nine cases and review of the literature. *Mod Pathol* 2004;**17**(July (7)):765–71.
12. Fenoglio-Preiser CM, Noffsinger AE, Stemmermann GN, Lantz PE, Isaacson PG. *Inflammatory myofibroblastic tumors (inflammatory pseudotumors). Gastrointestinal pathology: an atlas and text*. 3rd ed. Philadelphia: Lippincott Williams & Wilkins; 2008. p. 1242–3.
13. Tao YL, Wang ZJ, Han JG, Wei P. Inflammatory myofibroblastic tumor successfully treated with chemotherapy and nonsteroidals: a case report. *World J Gastroenterol* 2012;**18**(December (47)):7100–3, <http://dx.doi.org/10.3748/wjg.v18.i47.7100>.
14. Hammas N, Chbani L, Rami M, Boubbou M, Benmiloud S, Bouabdellah Y, et al. A rare tumor of the lung: inflammatory myofibroblastic tumor. *Diagn Pathol* 2012;**7**(July):83, <http://dx.doi.org/10.1186/1746-1596-7-83>.
15. Sanders BM, West KW, Gingalewski C, Engum S, Davis M, Grosfeld JL. Inflammatory pseudotumor of the alimentary tract: clinical and surgical experience. *J Pediatr Surg* 2001;**36**(January (1)):169–73.
16. Kim EY, Lee IK, Lee YS, Yang N, Chung DJ, Yim KI, et al. Inflammatory myofibroblastic tumor in colon. *J Korean Surg Soc* 2012;**82**(January (1)):45–9, <http://dx.doi.org/10.4174/jkss.2012.82.1.45>.
17. De Petris G, Leung ST. Pseudoneoplasms of the gastrointestinal tract. *Arch Pathol Lab Med* 2010;**134**(March (3)):378–92, <http://dx.doi.org/10.1043/1543-2165-134.3.378>.
18. Yamamoto H, Yamaguchi H, Aishima S, Oda Y, Kohashi K, Oshiro Y, et al. Inflammatory myofibroblastic tumor versus IgG4-related sclerosing disease and inflammatory pseudotumor: a comparative clinicopathologic study. *Am J Surg Pathol* 2009;**33**(September (9)):1330–40.
19. Gleason BC, Hornick JL. Inflammatory myofibroblastic tumours: where are we now? *J Clin Pathol* 2008;**61**(April (4)):428–37.

## Open Access

This article is published Open Access at [sciendo.com](http://sciendo.com). It is distributed under the [IJSCR Supplemental terms and conditions](#), which permits unrestricted non commercial use, distribution, and reproduction in any medium, provided the original authors and source are credited.