


Contents lists available at ScienceDirect

Urology Case Reports

journal homepage: www.elsevier.com/locate/eucr

Pediatrics

Persistent Urinary Incontinence After Nephrectomy: A Case of Inverted-Y Ureteral Duplication with Ectopic Ureteral Insertion into the Vagina



Hiroshi Shimura, Takahiko Mitsui*, Tadashi Aoki, Manabu Kamiyama, Takashi Yamagishi, Masayuki Takeda

Department of Urology, University of Yamanashi Graduate School of Medical Science, Chuo, Yamanashi, Japan

ARTICLE INFO

Article history:

Received 7 August 2016

Received in revised form

30 August 2016

Accepted 7 September 2016

Keywords:

Inverted-Y duplication

Ectopic

Ureter

Incontinence

ABSTRACT

Inverted-Y ureteral duplication is one of the rarest anomalies of ureteral branching. We encountered a 20-year-old female patient with persistent incontinence even after nephrectomy for ectopic ureteral insertion into the vagina. She had inverted-Y ureteral duplication between the bladder and vagina, and urine was being transported from the bladder to the vagina. To the best of our knowledge, this is a rare case of inverted-Y ureteral duplication with ectopic ureteral insertion into the vagina as well as the ureter into the bladder, which became apparent due to persistent urinary incontinence even after nephrectomy. © 2016 The Authors. Published by Elsevier Inc. This is an open access article under the CC BY-NC-ND license (<http://creativecommons.org/licenses/by-nc-nd/4.0/>).

Introduction

Inverted-Y ureteral duplication is one of the rarest ureteral duplication anomalies. This anomaly forms two ureteral limbs distally, which fuse proximally and insert into the renal pelvis as a single ureter. One of the distal ureteral limbs inserts into the bladder, while the other limb ends in ectopia, ureterocele, atresia, or stasis with a calculus. In a few cases, one of the ureteral limbs has been reported to end in the vagina as an ectopic ureter.¹

Ureteral ectopia is a relatively common congenital anomaly of the urinary tract. When female pediatric patients develop continuous incontinence, the possibility of ureteral ectopia into the vagina needs to be considered. Hypoplastic kidney associated with the ectopic ureter may be treated by nephrectomy.

We encountered a case of inverted-Y ureteral duplication with two ureteral limbs of the ureter into the bladder and ectopic ureteral insertion into the vagina, which became apparent due to persistent urinary incontinence following nephrectomy. We herein report our rare case of inverted-Y ureteral duplication and discuss relevant literature.

Case report

A 20-year-old woman presented to our hospital with intermittent urinary incontinence. At 5 years old, she was diagnosed with right hypoplastic kidney and ectopic ureter inserting into the vagina at other hospital by CT, vaginography (Fig. 1A), and renography (Fig. 1B). Since she also had continuous urinary incontinence at that time, laparoscopic nephrectomy was performed on the right kidney. The resected right kidney was small and appeared to be hypoplastic (Fig. 1C).

Although urinary incontinence persisted in spite of surgery, its amount and frequency decreased with age. Voiding cystourethrography (VCUG), which was performed when she was 6 years old, showed low grade ureteral reflux in the right ureter in a retrospective review that was not recognized at that time (Fig. 2). This ureteral reflux indicated that there were two ureteral limbs; one inserted into the vagina and the other into the bladder.

At the age of 20, the patient was referred to our hospital with intermittent urinary incontinence. A small amount of urinary incontinence occurred after exercise without a desire to urinate. The patient also occasionally had urinary incontinence when sleeping. Laboratory test results were all within normal limits. The following examinations were performed under anesthesia to investigate the state of urinary incontinence.

* Corresponding author. 1110 Shimokato, Chuo, Yamanashi, 409-3898, Japan. Fax: +81 55 273 9659.

E-mail address: tmitsui@yamanashi.ac.jp (T. Mitsui).

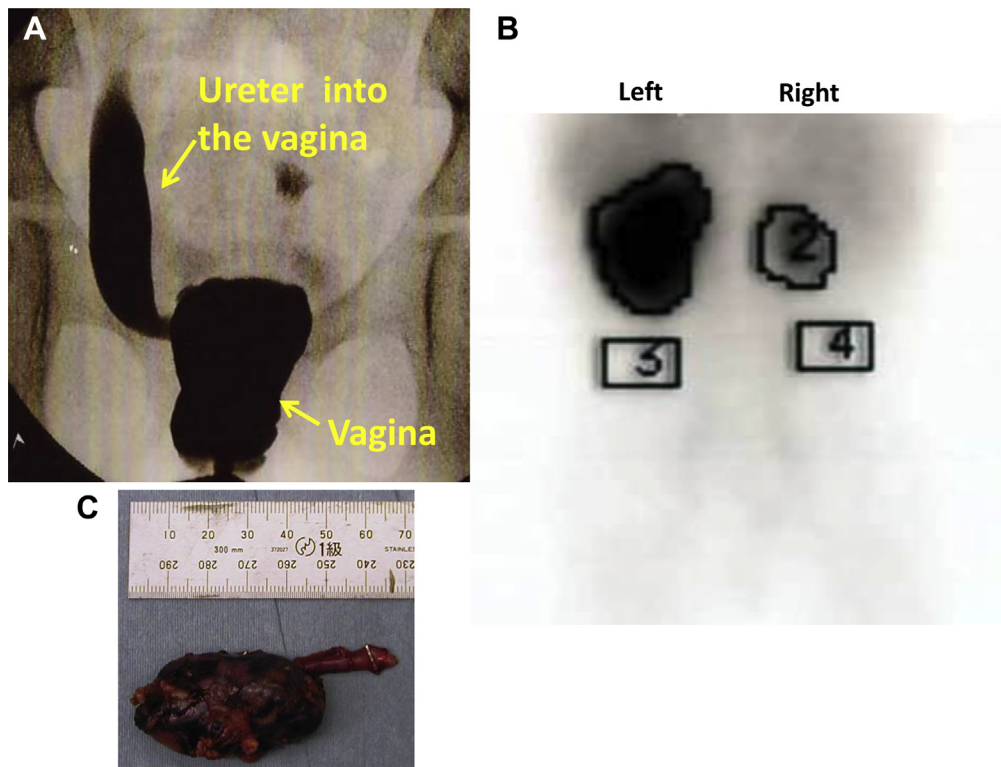


Figure 1. Preoperative vaginography, renography, and right kidney. A. Vaginography showed the insertion of the right ectopic ureter into the vagina. B. Preoperative renography showed almost no function in the right kidney. C. Resected right small kidney.

Cystourethroscopy showed the presence of the right ureteral orifice, and a fluoroscopic examination revealed that the right ureteral orifice was connected to the right ureter (Fig. 3A, 3B).

The shadow of the right ureter, which was revealed by the fluoroscopic examination, was enhanced in vaginography (Fig. 3C). These results indicated that the distal right ureter had split into two limbs, one of which entered the bladder and the other the vagina. Thus, urinary incontinence was considered to be caused by the transport of urine from the bladder to the vagina (Fig. 3D).

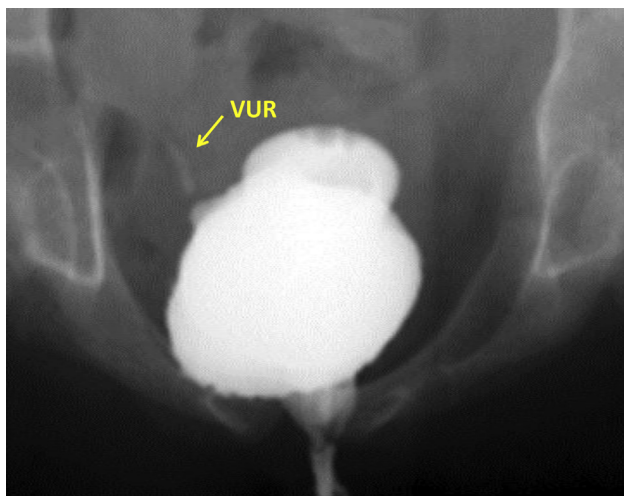


Figure 2. Voiding cystourethrography (VCUG). VCUG was performed after nephrectomy. The right ureter (arrow) was visualized. The contrasting density of the right ureter was too weak to be recognized at that time. VUR: vesicoureteral reflux.

We proposed surgery to excise the ureter entering the bladder; however, since the amount of urinary incontinence is small, she is currently being followed-up in the Outpatient Department without surgery.

Discussion

Inverted-Y ureteral duplication is one of the rarest anomalies of ureteral duplication, and its etiology has not yet been elucidated in detail. Only approximately 40 cases of this anomaly have been reported to date. In our case, urinary incontinence, which was caused by the ectopic ureter inserting into the vagina, was diagnosed at the age of 5. Since the possibility of inverted-Y ureteral duplication was not considered, laparoscopic nephrectomy of the hypoplastic kidney was performed. However, another limb branching from the right ureter to the bladder was subsequently detected, and the transport of urine resulted in a small amount of urinary incontinence. Thus, urinary incontinence may be the results of vesicoureteral reflux when intravesical pressure markedly increases.

The embryological origin of this anomaly remains unclear. Two ureteric buds may have fused into a single duct before entering the metanephric blastoma.^{2,3} While the proximal limb of the inverted-Y ureter is located in the trigon, the distal limb generally inserts into the ectopic area, such as the bladder neck, uterus, vagina, and seminal vesicles. In some cases, the distal limb had an ureterocele in the bladder neck.^{4,5} Thus, the distal limb of the inverted-Y ureter is similar to the simple ectopic ureter. Nephrectomy was performed for the simple ectopic ureter inserting into the vagina in our case.

Inverted-Y ureteral duplication is more common in females, and the insertion of the ectopic ureter into the reproductive tract has been reported in some cases.¹ In our case, inverted-Y ureteral

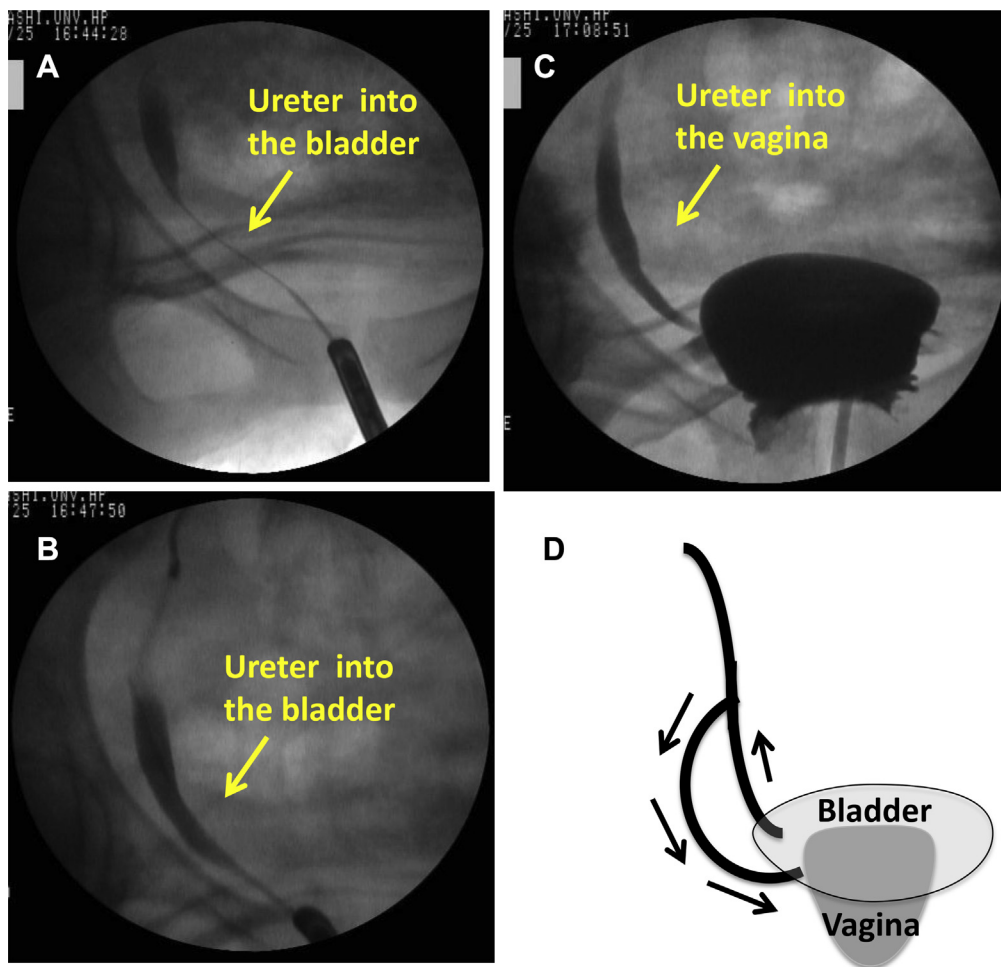


Figure 3. Retrograde ureterography and vaginography. A. The ureteral catheter was passed into the right ureter. B. After a radiopaque dye was injected into the right ureteral orifice, the right ureter was visualized. C. Vaginography showed an enhancement of the previous shadow of the right ureter. D. Schema of the right distal ureter. Urinary incontinence is caused by inverted-Y ureteral duplication with a vesicoureteral reflux and the ectopic ureter inserting into the vagina.

duplication was not considered preoperatively, because the hypoplastic and almost non-functioning kidney may have resulted in the misdiagnosis of inverted-Y duplication of the ureter in imaging studies. However, cystourethroscopy and retrograde pyeloureterography should be routinely performed before nephrectomy to reveal the duplicated system and possible bilateral ureteral ectopia in addition to rare case of inverted-Y ureteral duplication. Unfortunately, these examinations were not conducted in the previous hospital in our case.

In our case, the vesicoureteral reflux may induce urinary incontinence as part of the yo-yo phenomenon previously reported.⁵ In patients with persistent urinary incontinence even after nephrectomy, we need to consider inverted-Y duplication of the ureter even though it is rare.

As limitations of our case, first the communication between the vagina and the bladder was not unfortunately visualized clearly even in retrograde ureterography with catheter. This is due to that the branch might be occluded with catheter or overlapping with the each route from the bladder and vagina to the branch might be overlapped in two-dimensional examination. Second, urodynamics to exclude stress or urge urinary incontinence were not performed. Based on clinical signs such as intermittent urinary incontinence without an increase in abdominal pressure and the absence of urgency, we considered

urinary incontinence to occur with the vesicoureteral reflux via inverted-Y duplication of the ureter. Further studies including videourodynamics are needed in order to reveal the etiology of urinary incontinence in our case.

Conclusion

We encountered a case of inverted-Y ureteral duplication with the ureter into the bladder and ectopic ureteral insertion into the vagina. To the best of our knowledge, this is the first case report of persistent urinary incontinence after nephrectomy. It is important to consider the possibility of inverted-Y ureteral duplication in patients with urinary incontinence even after nephrectomy of a hypoplastic kidney with ectopic ureteral insertion into the vagina.

Conflict of interest

All authors declare that there are no competing financial interests in relation to this work.

Acknowledgments

No funding sources.

References

1. Upadhyay J, Zuckerman JM, Shekarriz B. Minimally invasive surgical approach to excision of symptomatic ectopic inverted-Y ureteral duplications. *J Pediatr Urol.* 2013;9(2):e114–e116.
2. Roy Choudhury S, Chadha R, Bagga D, et al. Spectrum of ectopic ureters in children. *Pediatr Surg Int.* 2008;24(7):819–823.
3. Schenkman NS, Fernandez EB, Wind G, Irby P. Inverted Y duplication of the ureter associated with a distal limb ectopic to the seminal vesicle. *J Urol.* 1994;152(3):946–947.
4. Regan TC, Dejter Jr SW. Inverted Y duplication of the ureter with associated ureterocele and bladder outlet obstruction. *J Urol.* 1996;155(2):642.
5. Tuney D, Akpınar IN, Biren T, et al. Inverted Y ureter anomaly and associated distal yo-yo phenomenon. *Australas Radiol.* 1998;42(2):154–156.