

CASE REPORT

Enzyme Replacement Therapy with Imiglucerase in a Taiwanese Child with Type 1 Gaucher Disease

Hsiang-Yu Lin¹, Shuan-Pei Lin^{1,2,3,4*}, Chih-Kuang Chuang^{2,5}, James Edmond Wraith⁶

Departments of ¹Pediatrics and ²Medical Research, Mackay Memorial Hospital, ³Mackay Medicine, Nursing and Management College, ⁴Department of Clinical Pathology, Taipei Institute of Pathology, ⁵Medical College, Fu-Jen Catholic University, Taipei, Taiwan, R.O.C., and ⁶Willink Biochemical Genetics Unit, Royal Manchester Children's Hospital, Hospital Road, Manchester, United Kingdom.

The treatment of type 1 Gaucher disease has dramatically improved with the development of enzyme replacement therapy (ERT). To date, however, imiglucerase treatment of this disease in Taiwanese pediatric patients has not been reported. A Taiwanese child with type 1 Gaucher disease was regularly treated with imiglucerase beginning October 1998. This 12-year 10-month-old boy had undergone splenectomy when he was 4 years old. He received intravenous imiglucerase 60 U/kg every 2 weeks for 78 months. No signs of pubertal development were documented at the commencement of ERT. There were no serious adverse effects. The patient had significant improvement in skeletal deformity, a dramatic decrease in liver size, markedly increased linear growth, alleviation of bone pain and bone crises, correction of anemia, and improved bone mineral density. ERT with imiglucerase improved the quality of life in this child with type 1 Gaucher disease. [*J Chin Med Assoc* 2006;69(5):228–232]

Key Words: enzyme replacement therapy, imiglucerase, pediatric type 1 Gaucher disease

Introduction

Gaucher disease is one of the most common hereditary autosomal recessive sphingolipidoses. Caused by a defect in lysosomal glucocerebrosidase,¹ it is a multisystem storage disorder manifested by anemia, thrombocytopenia, hepatosplenomegaly, and bone dysplasia. Primary involvement of the central nervous system occurs in a minority of patients.²

Gaucher disease is divided into 3 subtypes, based on the presence and progression of neurologic involvement. Type 1 (non-neuronopathic) is the most common subtype; it occurs at any age and has a heterogeneous clinical presentation. Type 2 (acute neuronopathic) is the most severe subtype and presents in the first month of life. It has a rapidly progressive clinical course, with

neurologic signs, including strabismus, trismus, and spasticity. Type 3 (subacute neuronopathic) usually occurs in childhood with a heterogeneous presentation; neurologic signs develop by adolescence, often beginning with a supranuclear gaze palsy.³

Type 1 Gaucher disease responds well to enzyme replacement therapy (ERT) with recombinant human macrophage-targeted recombinant human glucocerebrosidase (imiglucerase, Cerezyme[®]; Genzyme Corporation, Cambridge, MA, USA).^{4–7} This treatment was first introduced to Taiwan in October 1998, but the results of therapy in Taiwanese pediatric patients have not yet been reported. We have evaluated the outcome of 6 years of treatment with imiglucerase in a Taiwanese child with type I Gaucher disease.

*Correspondence to: Dr. Shuan-Pei Lin, Department of Pediatrics, Mackay Memorial Hospital, 92, Section 2, Chung-Shan North Road, Taipei 104, Taiwan, R.O.C.
E-mail: zsplin@ms2.mmh.org.tw • Received: July 26, 2005 • Accepted: December 20, 2005

Case Report

A boy born in December 1985 was first referred to our outpatient department in August 1998 for treatment of Gaucher disease. His parents were nonconsanguineous and healthy. An elder brother and elder sister had both died because of complications of the disease. The child had undergone splenectomy for severe splenomegaly at age 4 years. He fractured his left knee at age 10 and his left hip at age 12. He also had many episodes of bone crisis with severe bone pain. He walked only with great difficulty and was usually bedridden or wheelchair-bound. On physical examination, his height was 128.5 cm (< 3rd percentile) and weight was 25 kg (< 3rd percentile). He appeared to have poor linear growth, and there were severe bone deformities, multiple pathologic fractures, a barrel chest, multiple joint contractures, and a valgus deformity of the left knee joint. His extremities were very thin and weak. There was arm- and leg-length discrepancy (the right extremities being longer). He had hepatomegaly, with a palpable liver edge 14 cm below the subxiphoid process and 12 cm below the right costal margin. The patient's mental abilities were normal, and he did not show any signs of puberty.

On admission, a lumbosacral spine radiograph showed compression fractures of L1, L4, and L5. Magnetic resonance imaging (MRI) of the pelvis and lower extremities showed old infarcts in the lower lumbar spine, the pelvic bones bilaterally, and the right proximal and distal femur; avascular necrosis in both femoral heads; and new infarcts in the right trochanter and distal femur. Molecular analysis showed a homozygous L444P mutation, based on polymerase chain reaction (PCR)-restriction enzyme digestion method.⁸ Laboratory investigations revealed the following: leukocyte β -glucosidase, 0.39 $\mu\text{mol/g}$ protein/hour (control, 2.7 $\mu\text{mol/g}$ protein/hour; reference range, 1.0–5.0 $\mu\text{mol/g}$ protein/hour); plasma chitotriosidase, 29,200 $\mu\text{mol/hour}$ (control, 47 $\mu\text{mol/hour}$; reference range, 4–80 $\mu\text{mol/hour}$); hemoglobin, 11.2 g/dL; platelet count, $257 \times 10^9/\text{L}$; aspartate aminotransferase [AST], 72 U/L (normal range, 5–45 U/L); alanine aminotransferase [ALT], 31 U/L (normal range, 5–45 U/L); acid phosphatase, 47.5 U/L (normal range, 0.11–0.60 U/L); and alkaline phosphatase, 262 U/L (normal range, 200–495 U/L).

The patient was given imiglucerase at a dose of 60 U/kg every other week beginning October 1998. Imiglucerase came as a lyophilized powder and was stored at 4°C until use, then diluted in 0.9% NaCl just before infusion. It was infused intravenously through

a peripheral vein over 1–2 hours at a rate not exceeding 0.5–1 U/kg/min. The patient was weighed before each infusion to adjust the dose. The annual cost of this medication, approximately US\$ 400,000 for a 40-kg patient, was covered by Taiwan's National Health Insurance. Assessment of response included serial physical examination and laboratory tests, including complete blood counts, liver function tests (serum AST, ALT, and alkaline phosphatase), renal function tests (blood urea nitrogen [BUN] and creatinine), acid phosphatase, leukocyte β -glucosidase, and plasma chitotriosidase. Skeletal assessment included plain radiographs of the femur, spine, and pelvis.

The patient responded well to ERT given over 78 months, at the end of which time he was 19 years, 4 months old. There were no serious adverse effects. Puberty, beginning with pubic hair development, was documented in March 2000, after ERT had been implemented for 17 months. The patient had significant improvement of his skeletal deformities, a tremendously noticeable decrease in liver size, marked linear growth, and markedly decreased bone pain and bone crises. Figures 1A and B show the patient before and after ERT. After treatment, he could lift his arms above his shoulders without flexion. There was only a mild residual chest cage deformity and mild kyphoscoliosis and no palpable hepatosplenomegaly. After treatment, the lumbar and sacral spine radiographs showed an increased cortical thickness and no new compression fractures.

On physical examination after 78 months of treatment, the patient's height was 156 cm and weight was 41 kg. Figures 2A and B show the changes in height and weight over the 6-year treatment course. Table 1 shows serial hemoglobin concentrations, platelet counts, liver and renal function tests, and acid and alkaline phosphatase levels. The patient attained a normal hemoglobin level 12 months after beginning therapy. His platelet count was already within the normal range before starting treatment because of the splenectomy at age 4. However, the platelet count did increase, particularly early in the course of therapy. Because the patient received ERT before puberty, his alkaline phosphatase was high during the first year but then decreased gradually as he grew. The acid phosphatase gradually decreased over the treatment course.

We were only able to measure lumbar bone mineral density (BMD) by dual-energy radiograph absorptiometry after February 2001. The BMD of L2 to L4 was 0.645 g/cm² at that time. However, BMD gradually increased over the last 3 years of therapy, with the latest data of 0.941 g/cm² in July 2005.

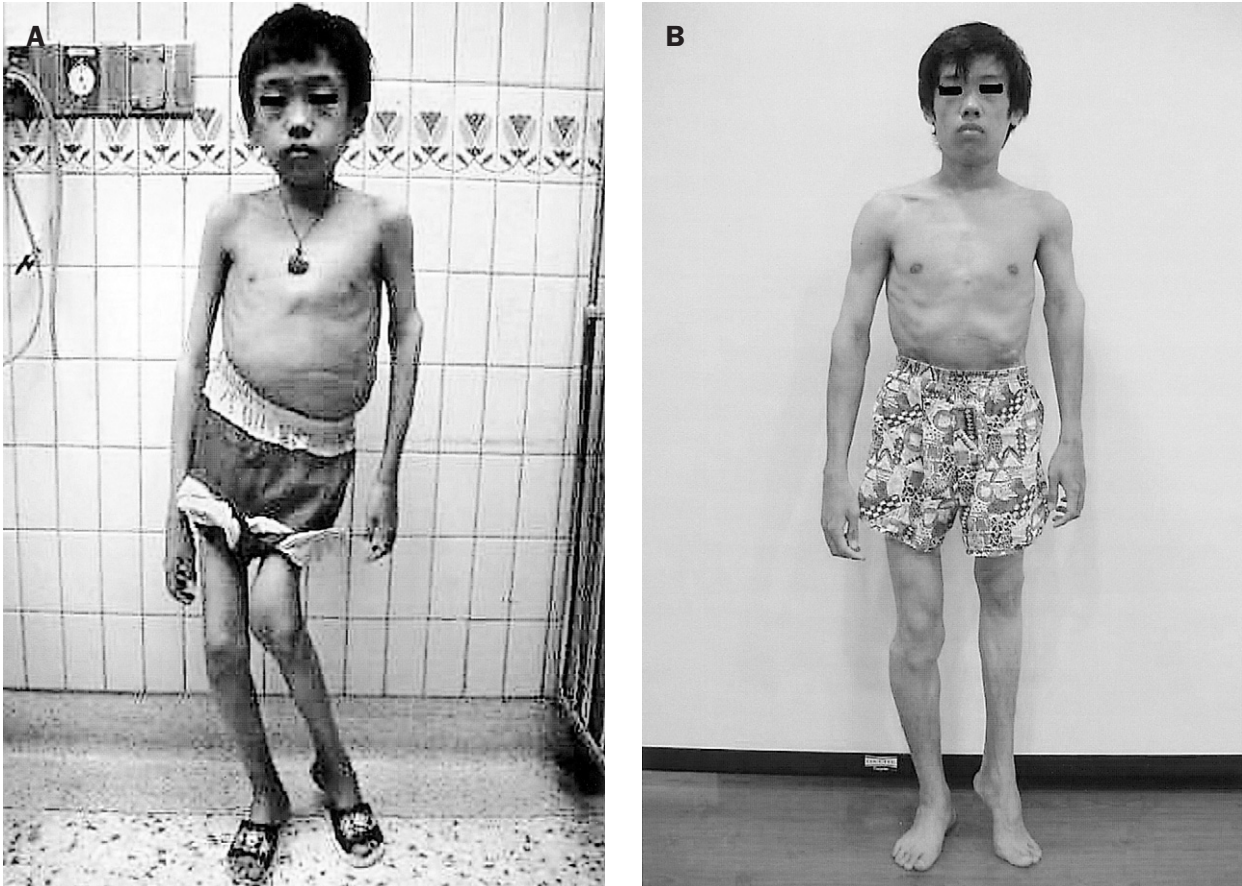

Figure 1. The patient before and after enzyme replacement therapy (ERT). (A) Pre-ERT (12 years and 10 months old); (B) Post-ERT (19 years and 4 months old).

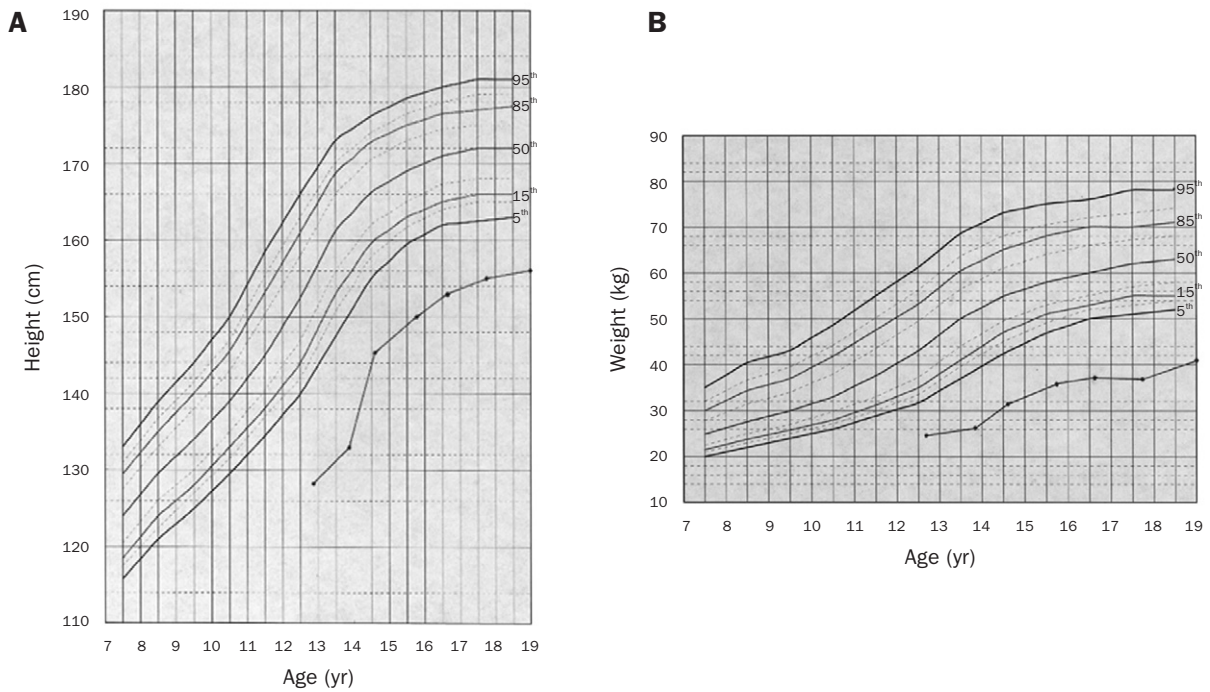


Figure 2. Change of the patient's height (A) and weight (B) during 6 years of enzyme replacement therapy compared to normal height and weight curves of Chinese children. Each closed circle represents one measurement of his height or weight.

Table 1. Serial hemoglobin concentrations, platelet counts, liver and renal function tests, and acid and alkaline phosphatase levels

	Initial	12 mo	24 mo	36 mo	48 mo	60 mo	72 mo
Hemoglobin (g/dL)	11.2	13.4	13.5	13.2	13.1	13.4	13.6
Platelet count (x 10 ³ /μL)	257	697	505	519	515	417	324
AST (U/L)	72	33	27	25	26	25	41
ALT (U/L)	31	20	17	17	20	16	34
BUN (mg/dL)	13	6	8	7	10	12	9
Creatinine (mg/dL)	0.3	0.3	0.4	0.4	0.5	0.6	0.6
Alkaline phosphatase (U/L)	262	169	157	218	–	126	94
Acid phosphatase (U/L)	47.5	19.6	18	16.7	19.2	–	8

AST = serum aspartate aminotransferase; ALT = serum alanine aminotransferase; BUN = blood urea nitrogen.

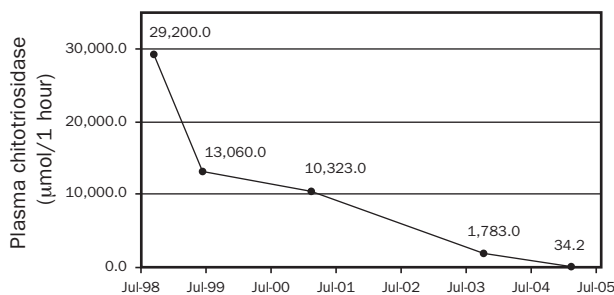


Figure 3. The effects of enzyme replacement therapy on the change of plasma chitotriosidase.

No new skeletal lesions occurred during treatment, and the patient did not complain again of bone pain after the first year of treatment. Because he had a 30–40° genu valgum on the left, he underwent corrective osteotomy of the left distal femur in April 2000. He was able to walk well without crutches after surgery.

Figure 3 shows the effects of ERT on the plasma chitotriosidase, a measurement thought to be an indicator of response to ERT.⁹ It gradually decreased over the course of treatment, and the comparison between data at the beginning and the end of the study shows a dramatic plummet. The liver was no longer palpable below the right costal and subxiphoid margins after ERT for 3 years.

Discussion

We have presented the first experience in Taiwan of treating pediatric type 1 Gaucher disease with imiglucerase. The only previous report of ERT for type 1 Gaucher disease in Taiwan involved 6 adults.¹⁰

In those cases, ERT effectively reduced organomegaly, corrected anemia and thrombocytopenia, improved liver function, and alleviated bone pain. In our patient, in addition to the above effects, imiglucerase also enhanced linear growth, alleviated skeletal deformity, and increased bone mineral density.

Gaucher disease severely impairs quality of life because of hematologic or skeletal complications, physical limitations, and psychosocial problems for both patients and their families.^{11,12} In previous studies, ERT has been shown to prevent progressive manifestations of Gaucher disease, as well as ameliorating specific features of the disease.^{4–6} Our experience is consistent with these studies.

Improved linear growth is both medically and socially important for children. In our patient, ERT resulted in a marked acceleration of growth, increased BMD, and alleviation of obvious skeletal deformities. Our findings are consistent with those of previous studies.^{13,14} Rosenthal et al⁷ concluded that ERT with imiglucerase over 3.5 years produced objective reversal of disease in both the axial and appendicular skeleton in patients with Gaucher disease. They documented marked improvement in marrow composition and bone mass in both children and adults.

Deegan and Cox reported that plasma chitotriosidase decreased gradually after ERT, and after 2 years of ERT, the chitotriosidase activity decreased to 30% of the baseline value.¹⁵ Our findings are similar to theirs. Moreover, our study showed plasma chitotriosidase changed to the normal value after ERT for 6 years.

The study by Weinreb et al found a 20–30% decrease in liver volume within 1–2 years after beginning ERT, with a reduction of 30–40% by 5 years.⁵ Our patient suffered from hepatomegaly, with the liver edge palpable 14 cm below the subxiphoid process and 12 cm below the right costal margin before ERT;

however, after ERT for 3 years, the liver was no longer palpable. Our experience is consistent with theirs.

In conclusion, our experience indicates that imiglucerase therapy beginning before puberty can significantly improve physical measures in type I Gaucher disease, with a marked enhancement in the quality of life.

Acknowledgments

This work was supported in part by a research grant MMH-E-93004 from Mackay Memorial Hospital, Taipei, Taiwan. The authors thank Professor Fuu-Jen Tsai for his help in molecular study on this patient.

References

1. Brady RO, Kanfer JN, Shapiro D. Metabolism of glucocerebrosides. II. Evidence of an enzymatic deficiency in Gaucher disease. *Biochem Biophys Res Commun* 1965;18:221–5.
2. Beutler E. Gaucher's disease. *N Engl J Med* 1991;325:1354–60.
3. Grabowski GA. Gaucher disease enzymology, genetics and treatment. In: Harris H, Hirschhorn K, eds. *Advances in Human Genetics*, vol. 21. New York: Plenum Press, 1993:377–441.
4. Zimran A, Elstein D, Levy-Lahad E, Zevin S, Hadas-Halpern I, Bar-Ziv Y, Foldes J. Replacement therapy with imiglucerase for type I Gaucher's disease. *Lancet* 1995;345:1479–80.
5. Weinreb NJ, Charrow J, Andersson HC, Kaplan P, Kolodny EH, Mistry P, Pastores G, et al. Effectiveness of enzyme replacement therapy in 1,028 patients with Type I Gaucher disease after 2–5 years of treatment: a report from the Gaucher registry. *Am J Med* 2002;113:112–9.
6. Barton NW, Brady RO, Dambrosia JM, Di Bisceglie AM, Doppelt SH, Hill SC, Mankin HJ, et al. Replacement therapy for inherited enzyme deficiency: macrophage-targeted glucocerebrosidase for Gaucher's disease. *N Engl J Med* 1991;324:1464–70.
7. Rosenthal DI, Doppelt SH, Mankin HJ, Dambrosia JM, Xavier RJ, McKusick KA, Rosen BR, et al. Enzyme replacement therapy for Gaucher disease: skeletal response to macrophage-targeted glucocerebrosidase. *Pediatrics* 1995;96:629–37.
8. Tsai FJ, Lee CC, Wu MC, Lin SP, Lin CY, Tsai CH, Kodama H, et al. Mutation analysis of type II Gaucher disease in five Taiwanese children: identification of two novel mutations. *Acta Paediatr Taiwan* 2001;42:231–5.
9. Czartoryska B, Tylki-Szymanska A, Gorska D. Serum chitotriosidase activity in Gaucher patients on enzyme replacement therapy (ERT). *Clin Biochem* 1998;31:417–20.
10. Hsu CC, Chien YH, Lai MY, Hwu WL. Enzyme replacement therapy with imiglucerase in Taiwanese patients with type I Gaucher disease. *J Formos Med Assoc* 2002;101:627–31.
11. Verderese CL, Graham OC, Holder-McShane CA, Harnett NE, Barton NW. Gaucher disease: a pilot study of the symptomatic responses to enzyme replacement therapy. *J Neurosci Nurs* 1993;25:296–301.
12. Charrow J, Andersson HC, Kaplan P, Kolodny EH, Mistry P, Pastores G, Rosenbloom BE, et al. The Gaucher registry: demographics and disease characteristics of 1698 patients with Gaucher disease. *Arch Intern Med* 2000;160:2835–43.
13. Kaplan P, Mazur A, Manor O, Charrow J, Esplin J, Gribble TJ, Wappner RS, et al. Acceleration of retarded growth in children with Gaucher disease after treatment with alglucerase. *J Pediatr* 1996;129:149–53.
14. Charrow J, Andersson HC, Kaplan P, Kolodny EH, Mistry P, Pastores G, Prakash-Cheng A, et al. Enzyme replacement therapy and monitoring for children with type I Gaucher disease: consensus recommendations. *J Pediatr* 2004;144:112–20.
15. Deegan PB, Cox TM. Clinical evaluation of biomarkers in Gaucher disease. *Acta Paediatr Suppl* 2005;94:47–50.