



African Journal of Urology

Official journal of the Pan African Urological Surgeon's Association
web page of the journal

www.ees.elsevier.com/afju
www.sciencedirect.com



Case report

Penile gangrene in a HIV patient

L.E. Mubenga^{a,*}, G. Maheshe^b, A. Murhula^c, D. Chimanuka^a

^a Department of Urology, Catholic University of Bukavu, Bukavu, Congo

^b Department of Radiology, Catholic University of Bukavu, Bukavu, Congo

^c Department of Internal Medicine, Catholic University of Bukavu, Bukavu, Congo

Received 29 May 2016; received in revised form 30 August 2016; accepted 21 September 2016

Available online xxx

KEYWORDS

Penile;
Necrosis;
HIV patient

Abstract

Introduction: The good vascularization of penis protects this organ from necrosis. Critical reduction of blood supply and aggressive infection of the genitalia are some of the rare conditions which can lead to penile necrosis. HIV infection can provide the two conditions and lead to a rapidly extensive penile gangrene.

Observation: A 47-year-old man developed a rapidly extensive penile necrosis despite local and systemic care. He was HIV positive and was not adherent with medical follow-up. Classical risk factors of blood vessels damages such are diabetes, hepatitis or cigarette smoking were absent. Total penectomy was performed. We describe the possibilities of HIV infection-induced penile gangrene.

Conclusion: HIV infection should be taken in account among causes of penile necrosis.

© 2016 Pan African Urological Surgeons Association. Production and hosting by Elsevier B.V. This is an open access article under the CC BY-NC-ND license (<http://creativecommons.org/licenses/by-nc-nd/4.0/>).

Introduction

The gangrene of the penis is a rare situation because of the good vascularization of this organ. Conditions leading to penile necrosis are a significant reduction of blood supply and/or tissue necrosis due to non-vascular causes. HIV infection can provide the two conditions and lead to a rapidly extensive penile gangrene.

Case presentation

A 47-year-old man was admitted to the emergencies service of the Provincial Referral General Hospital of Bukavu/Democratic Republic of Congo for a penile necrosis evolving for a week despite local and systemic care received in his district hospital. No genital trauma was reported.

He was known HIV positive for five years but was not adherent to anti-retroviral therapy (ART).

He was neither a cigarette smoker nor a diabetic.

* Corresponding author.

E-mail addresses: leonmubenga@yahoo.fr,
emmanuelmubengalm@gmail.com (L.E. Mubenga).

Peer review under responsibility of Pan African Urological Surgeons' Association.

<http://dx.doi.org/10.1016/j.afju.2016.09.005>

1110-5704/© 2016 Pan African Urological Surgeons Association. Production and hosting by Elsevier B.V. This is an open access article under the CC BY-NC-ND license (<http://creativecommons.org/licenses/by-nc-nd/4.0/>).

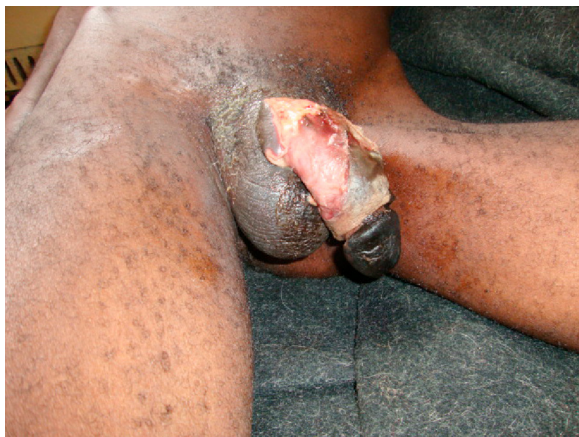

Figure 1 Penile gangrene.

His physical examination revealed a penile necrosis oozing a purulent fluid. There were no inguinal or femoral adenopathy. The prostate gland was normal on digital rectal examination.

The lower limbs presented feet hyperpigmentation, weak pedal pulses and hypoaesthesia (Fig. 1).

Nadir CD4 count was 118 cells/cm³; Hepatitis B and C were negative; glycaemia: 76 mg/dl and normal electrocardiogram.

Arteriogram showed a critical stenosis of external iliac arteries and calcifications in the popliteal arteries. Internal iliac and penile arteries were not visualized (Figs. 2 and 3).

A total penectomy was performed with placement of a urinary catheter. Postoperative care was assured by a multidisciplinary team. The patient received a broad spectrum antibiotics (Cefotaxime and Metronidazole) administered parenterally, supportive measures, and had daily antiseptic dressings. But his general condition worsened despite these treatments and he died in a multiple organ failure state one week after admission.

Histopathological analyses of the specimen revealed an extensive necrosis of both superficial and deeper tissues.

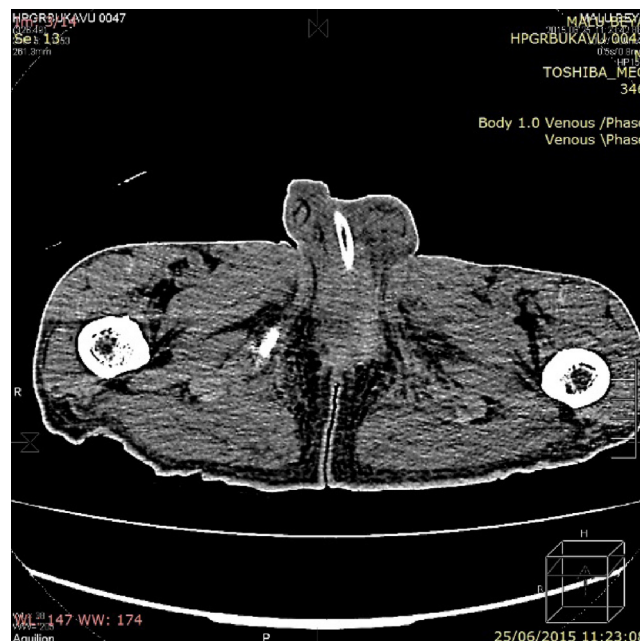

Figure 3 Internal iliac and penile arteries not visualized.

Discussion

There are various causes of penile gangrene; they are listed in Table 1 and can be grouped into vascular, non-vascular and mixed causes.

Some of them are obvious: vasculopathy induced by uncontrolled diabetes mellitus, trauma of the genitalia or priapism.

Iatrogenic causes constitute a large entity that should be avoid as much as possible. One experiences should serve others: penile compression due to tight stitches during circumcision and hypospadias repair, or by a flap during urethroplasty.

Concerning Al-Ghorab operation performed for the treatment of priapism, the main cause of penile gangrene is either priapism itself if the patient is received late or the surgical procedure; the limit of responsibilities between these two etiologies remains unclear.

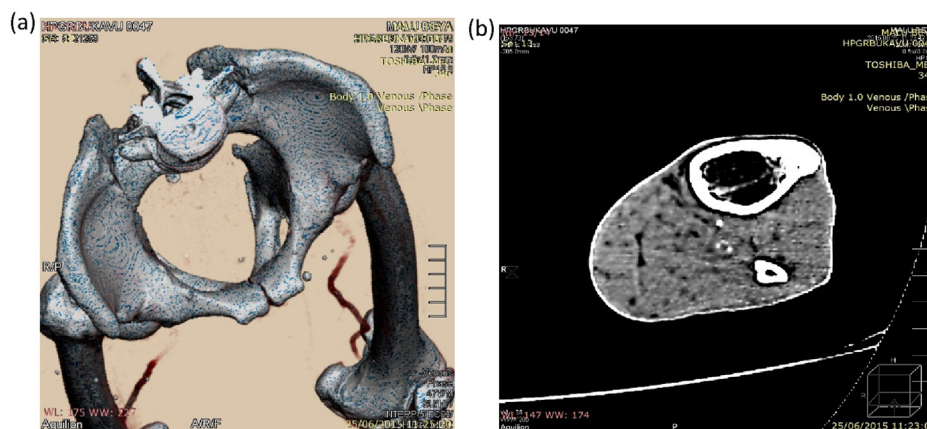


Figure 2 Arteriogram showing stenosis of external iliac arteries (a) and calcifications of popliteal arteries (b).

Table 1 Causes of penile gangrene.

Vascular	Non-vascular	Mixed
Strangulation [1]	Penile prosthesis [4]	Fournier [8]
Anticoagulants [2]	Urethral stones impaction [5]	Traumatism
Priapism [2]	Penile injections for girth augmentation (vaselinoma, paraffin) [6] Radiotherapy [7]	Postoperative: - Circumcision [9], - Hypospadias repair, - Al-ghorab [10], - TURP [11].
Condom catheter [3]		Diabetes mellitus [12]
Atherosclerosis		Pyoderma gangrenosum [13]

Penile necrosis due to penile prosthesis in case of erectile dysfunction is a rare but possible situation. The patient should be informed about the warning signs and the importance of a regular follow-up.

Pelvic radiotherapy and penile necrosis after a transurethral resection of the prostate due to an extensive traction during the procedure or the use of a defective resection loop have also been reported.

The condom catheter in paraplegic or bedridden patients should be adapted to the penile size, placed correctly and monitored. Compression by this instrument can achieve a tourniquet effect mostly in these patients with spinal cord injury and loss of sensation.

Other causes of penile necrosis are considered as curiosities described in the literature: self-injection of vaselinoma or paraffin in order to increase the penile size; stones urethral impaction leading to ischemia of the entire penis.

HIV infection increases the risk of atherosclerosis and vasculopathy; the more frequent damages concern the heart although several other organs are concerned [14–18].

The mechanisms are unclear; the hypotheses include dyslipidemias associated with HIV infection and antiretroviral therapy, immunodeficiency, and inflammation [14–18].

In our case the classical risk factors of atherosclerosis such as diabetes, hepatitis or cigarette smoking were absent [19–22].

Penile gangrene was a local manifestation of a systemic arterial vasculopathy induced by the HIV infection. The blood vessels damages were attributed to HIV infection itself and were predominant in external genitalia and lower limbs. In general the penis is protected from ischemia by its extensive collateral blood supply unlike the heart and the lower limbs [14–22].

In our patient the heart examination and the electrocardiogram were normal.

The dyslipidemias induced by antiretroviral therapy could not be considered because the patient was not adherent with the medical follow-up.

In addition opportunistic infections in HIV patients are aggressive and rapidly extensive mostly when the CD4 count is low.

In this patient atherosclerosis and smooth tissues infection were possible and could lead to penile gangrene.

Conclusion

Penile gangrene is a rare and frightening complication. To the best of our knowledge we believe that our case presents an exceptional condition of penile gangrene induced by HIV infection in absence of classical risk factors of atherosclerosis. This case is reported because of its rarity.

Conflict of interest

All authors declare that there is no conflict of interest.

Authors' Contributions

- Mubenga Mukengeshai Leon-Emmanuel. Email: leonmubenga@yahoo.fr and emmanuelmubengalm@gmail.com. Role: Urological assessment and surgical operation of the patient. Main author of the manuscript. Senior doctor of the patient.
- Maheshe Balemba Ghislain. Email: maheshghislain@gmail.com and balembapitchou@yahoo.fr. Role: Radiologist; he realized and interpreted scanner images. He actively participated in documentary research on the penile vascularization impairment among HIV infected patients.
- Murhula Aimé. Email: draime2006@gmail.com and draime2006@yahoo.fr. Role: Internist; He performed the medical assessment before operation and postoperative follow-up. He actively participated in documentary research on the link between HIV infection and blood vessels damages.
- Chimanuka Mirindi Dominique. Email: chimsdomis@gmail.com and chimsdomis@yahoo.fr. Role: He actively participated in documentary research on the causes of penile gangrene.

Source of funding

The authors did not obtain any external funding for the realization of this work. The Direction of the Provincial General Referral Hospital of Bukavu provided logistical facilities during the patient care and documentation; we mentioned this in the acknowledgements.

Patient consent

Obtained.

Acknowledgement

The authors thank the Direction of the Provincial General Referral Hospital of Bukavu for technical and logistical facilities during patient care and documentation of this case report.

References

- Nuhu A, Edino S, Agbese G, Kallamu R. Penile gangrene due to strangulation by a metallic nut: a case report and review of the literature. *Internet J Surg* 2008;21(2).

- [2] Nagathan DS, Pahwa HS, Kumar A, Goel A. Anticoagulant-induced priapism progressing to penile gangrene: a devastating complication. *BMJ Case Rep* 2012, <http://dx.doi.org/10.1136/bcr-2012-007073>.
- [3] Nazeer Kawoosa Nadeem UL. Isolated gangrene of the penis in a paraplegic patient secondary to a condom catheter. *Indian J Surg* 2011;73(August (4)):304–6.
- [4] Gómez BG, Otero JR, Sicilia LD, Alcaide EJ, García-Cruz E, Antolín AR. Ischemic gangrene of the glans following penile prosthesis implantation. *Case Rep Urol* 2013;2013. Article ID 323574, 4 pages.
- [5] Ramdass MJ, Naraynsingh V. Multiple urethral stones causing penile gangrene. *Case Rep Urol* 2014;2014. Article ID 182094, 3 pages.
- [6] De Siati M, Selvaggio O, Di Fino G, Liuzzi G, Massenio P, Sanguedolce F, et al. An unusual delayed complication of paraffin self-injection for penile girth augmentation. *BMC Urol* 2013;13:66.
- [7] Zyczkowski M, Bogacki R, Bryniarski P, Nowakowski K, Muskała B, Paradysz A. Gangrene of the penis, scrotum, and perineum, occurred after radiotherapy of rectal cancer. *Cent Eur J Urol* 2013;66:336–40.
- [8] Heiner JD, Eng KD, Bialowas TA, Devita D. Fournier's gangrene due to masturbation in an otherwise healthy male. *Case Rep Emerg Med* 2012;2012. Article ID 154025, 3 pages.
- [9] Uzun G, Ozdemir Y, Eroglu M, Mutluoglu M. Electrocautery-induced gangrene of the glans penis in a child following circumcision. *BMJ Case Rep* 2012, <http://dx.doi.org/10.1136/bcr-2012-007096>.
- [10] Ford-Glanton BS, Patel P, Siddiqui S. Penile gangrene with abscess formation after modified Al-Ghorab shunt for idiopathic ischemic priapism. *Case Rep Urol* 2014;2014. Article ID 705417, 3 pages.
- [11] Jariwala SK, Mammen KJ. Penile gangrene and urethrocutaneous fistula following transurethral resection of prostatic carcinoma. *Indian J Surg* 2011;73(November–December (6)):463–4.
- [12] Dogru T, Bulucu F, Sonmez A, Yilmaz MI, Demiriz M, Caglar K. Penile gangrene: a rare complication of diabetes mellitus. *Pract Diabetes Int* 2006;23(January/February (1)).
- [13] Kim Tae Heung, Oh Seung Young, Myung Soon Chul. Pyoderma gangrenosum of the penis. *J Korean Med Sci* 2009;24:1200–1202.
- [14] Eugenin EA, Morgello S, Klotman ME, Mosoian A, Lento PA, Berman JW, et al. Human immunodeficiency virus (HIV) infects human arterial smooth muscle cells in vivo and in vitro implications for the pathogenesis of HIV-mediated vascular disease. *Am J Pathol* 2008;172(April (4)).
- [15] Gibellini D, Alviano F, Miserocchi A, Tazzari PL, Ricci F, Clò A, et al. HIV-1 and recombinant gp120 affect the survival and differentiation of human vessel wall-derived mesenchymal stem cells. *Retrovirology* 2011;8(40).
- [16] Stein JH, Currier JS, Hsue PY. Arterial disease in patients with human immunodeficiency virus infection: what has imaging taught us? *JACC Cardiovasc Imaging* 2014;7(5):515–25.
- [17] Ssinabulya I, Kayima J, Longenecker C, Luwedde M, Semitala F, Kambugu A, et al. Subclinical atherosclerosis among HIV-infected adults attending HIV/AIDS care at two large ambulatory HIV clinics in Uganda. *PLoS One* 2014;9(2):e89537.
- [18] Wang D, Melancon JK, Verbesey J, Hu H, Liu Chenglong, Aslam S, et al. Microvascular endothelial dysfunction and enhanced thromboxane and endothelial contractility in patients with HIV. *J AIDS Clin Res* 2014;4(12):267.
- [19] Kiefer EM, Shi Q, Hoover DR, Kaplan R, Tracy R, Tien P, et al. Association of hepatitis C with markers of hemostasis in HIV infected and uninfected women in the women's interagency HIV study (WIHS). *J Acquir Immune Defic Syndr* 2013;62(3):301–10.
- [20] Hsue PY, Hunt PW, Schnell A, Kalapus SC, Hoh R, Granz P, et al. Role of viral replication, antiretroviral therapy, and immunodeficiency in HIV-associated atherosclerosis. *AIDS* 2009;23(9):1059–67.
- [21] Dressman J, Kincer J, Matveev SV, Guo Ling, Greenberg RN, Guerin T, et al. HIV protease inhibitors promote atherosclerotic lesion formation independent of dyslipidemia by increasing CD36-dependent cholesteryl ester accumulation in macrophages. *J Clin Invest* 2003;111:389–97.
- [22] Cysique LA, Moffat K, Moore DM, Lane TA, Davies NWS, Carr A, et al. HIV, vascular and aging injuries in the brain of clinically stable HIV-infected adults: a ¹H MRS study. *PLoS One* 2013;8(4):e61738, <http://dx.doi.org/10.1371/journal.pone.0061738>.