

Contents lists available at ScienceDirect

International Journal of Infectious Diseases

journal homepage: www.elsevier.com/locate/ijid

Case Report

Disseminated *Mycobacterium celatum* disease with prolonged pulmonary involvementCecilie Blenstrup Patsche^{a,b,*}, Erik Svensson^c, Christian Wejse^{a,b}^a GloHAU, Center for Global Health, Department of Public Health, Aarhus University, Aarhus, Denmark^b Department of Infectious Diseases, Aarhus University Hospital, Brendstrupgaardsvej 100, 8200 Aarhus N, Denmark^c Mycobacteriology Laboratory, Statens Serum Institut, Copenhagen, Denmark

ARTICLE INFO

Article history:

Received 3 October 2013

Received in revised form 18 February 2014

Accepted 21 February 2014

Corresponding Editor: Eskild Petersen, Aarhus, Denmark

Keywords:

Mycobacterium celatum

Non-tuberculous Mycobacterium

SUMMARY

Mycobacterium celatum is a rare cause of human infection, causing disseminated disease in immunosuppressed individuals. Infections localized to the lungs and the lymph nodes have also been reported in immunocompetent individuals. The existing literature on the subject is limited as are experiences with treatment regimens and durations. In the case presented herein, two different treatment regimens were applied to an immunocompromised HIV-negative patient with primary skin involvement and extensive pulmonary involvement due to suspected relapse on isoniazid, ethambutol, and clarithromycin treatment. The treatment regimen was changed to azithromycin, ciprofloxacin, and pyrazinamide and the treatment duration was prolonged to a total of 24 months, with good effect.

© 2014 The Authors. Published by Elsevier Ltd on behalf of International Society for Infectious Diseases. This is an open access article under the CC BY-NC-SA license (<http://creativecommons.org/licenses/by-nc-sa/3.0/>).

1. Introduction

Mycobacterium celatum is a slow-growing acid-fast bacillus that was first identified in 1993.¹ Its clinical presentation mimics that of *Mycobacterium tuberculosis* and the identification of *M. celatum* typically requires molecular testing. It is a rare cause of infection in humans that has been reported to cause localized infections in the lungs and the lymph nodes, as well as disseminated disease, the latter only seen in immunosuppressed individuals. The existing literature on the subject is limited and so are experiences with treatment regimens. In this case report, two different treatment regimens were used on a patient with primary skin involvement as well as extensive pulmonary involvement, and a long treatment was indicated.

2. Case report

A 70-year-old female presented with fatigue, dyspnea on exertion, a slightly productive cough, and an abscess on the right forearm with a fluctuating mass. Mycobacterial culture of the abscess showed *M. celatum*, identified by GenoType Mycobacterium AS (Hain Lifescience, Nehren, Germany). A computed

tomography (CT) scan revealed multiple enlarged lymph nodes in the axillae, periclavicular and mediastinal areas, along with splenomegaly and bullae in the lungs. A positron emission tomography (PET)-CT scan showed activity corresponding to the right lung parenchyma, upper and lower lobe, and both shoulders, including a previous fracture in the left shoulder (Figure 1). As part of the initial work-up, a bone marrow examination was done; this was normal. Histopathology was done on abscess material from the forearm and an enlarged axillary lymph node; only inflammation was found in the abscess material and no granuloma or malignancy was found in the lymph node. Acid-fast bacteria were found on microscopy of the abscess fluid, but all later specimens examined were negative.

After a review of the limited literature on *M. celatum* and in accordance with American Thoracic Society (ATS) guidelines,² it was decided to commence the following treatment regimen: clarithromycin 500 mg twice daily, isoniazid 300 mg once daily, and ethambutol 1200 mg once daily for 18 months. The patient suffered from chronic anemia and had been treated for epilepsy with lamotrigine and depression with mirtazapine; both conditions were stable. There was no known exposure to mycobacteria, no previous history of tuberculosis, and the patient was HIV-negative.

Drug susceptibility testing (DST) of the *M. celatum* isolate was initially done on Bactec 460 (BD, Franklin Lakes, NJ, USA) and this was later re-evaluated using Bactec MGIT (BD) and microdilution minimum inhibitory concentration (MIC) (TREK Diagnostic Systems,

* Corresponding author. Tel.: +245 54 54 615.

E-mail address: ceciliepatsche@live.dk (C.B. Patsche).

East Grinstead, UK). The DST results are given in Table 1; our *M. celatum* strain tested resistant to rifampin and rifabutin in both DSTs, was susceptible to isoniazid in the first DST, but was resistant in the second DST. All DSTs were performed in accordance with the manufacturers' instructions. There was no method for testing pyrazinamide susceptibility in non-tuberculous mycobacteria available in the laboratory.

During treatment, the fatigue and pain resolved and the abscess on the right forearm, which had continued to secrete for the first 2 months, healed completely within 6 months of treatment.

The patient showed signs of both humoral and cellular immunodeficiency with a severely decreased IgG2 level of 0.27 g/l and CD4 count

of 250 cells/mm³, with a decreased CD4/CD8 ratio and pathological B-cell phenotype. Yet there was normal total IgG, IgM, and IgA, thus the patient did not fulfill the criteria for a diagnosis of common variable immunodeficiency and was not offered immunoglobulin substitution treatment. During treatment for *M. celatum*, the CD4 count increased to 570 cells/mm³ but IgG2 was low and unchanged and the patient was diagnosed with idiopathic CD4 lymphopenia and an IgG2 subclass deficiency for which no treatment was indicated.

After 15 months of treatment, PET-CT revealed new round infiltrates on both lungs; the sizes of the multiple enlarged lymph nodes were unchanged and new enlarged lymph nodes had appeared alongside the iliac vessels (Figure 1). Relapse was

Table 1

Bactec 460 and Bactec MGIT (BD) and microdilution MIC of drugs to isolated *Mycobacterium celatum*

Drug	Bactec 460	Test result	Bactec MGIT and microdilution MIC: tested concentration mg/l	MIC, mg/l	Test result
Ethambutol	2.5 mg/l	S	5	4	S
Rifampin	2 mg/l	R	1	>8	R
Isoniazid	1.0 mg/l	S	0.1 and 0.4	2	R
Rifabutin	1.0 mg/l	R	0.5	2	R
Clofazimine	1 mg/l	S			
Ofloxacin	2.0 mg/l	S	2	–	S
Amikacin	4 mg/l	S	1	≤1	S
Clarithromycin	4 mg/l	S	1, 4, 16, and 64	≤0.06	S
Moxifloxacin			0.25	≤0.12	S

S, susceptible; R, resistant; MIC, minimum inhibitory concentration.

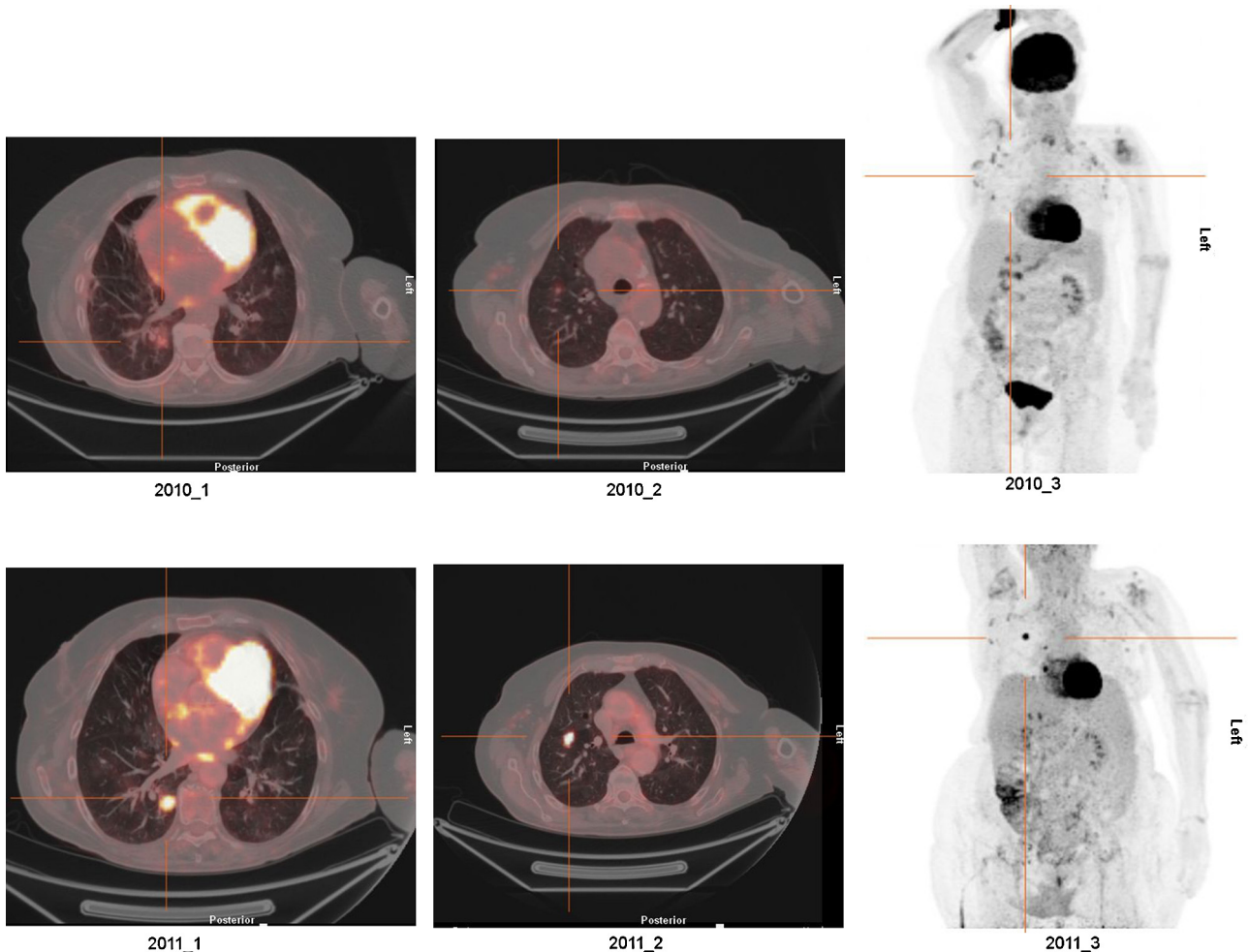


Figure 1. (A) Images taken in 2010. The CT scans show enlarged lymph nodes in the axillae, periclavicular and mediastinal areas, and splenomegaly and bullae in the lungs. The PET-CT shows activity in the right lung parenchyma, upper and lower lobe, and both shoulders. (B) Images taken in 2011. The PET-CT shows new round infiltrates in both lungs; the sizes of the multiple enlarged lymph nodes are unchanged and new enlarged lymph nodes have appeared alongside the iliac vessels.

suspected, although mycobacterial culture from bronchoalveolar lavage was negative. Histopathology of bronchoalveolar lavage fluid was normal, showing slight inflammation, and no malignancy was found. The treatment regimen was changed to azithromycin 500 mg twice daily, ciprofloxacin 500 mg twice daily, and pyrazinamide 2000 mg once daily for an additional 10 months and hence treatment was prolonged to a total of 24 months. There was a rapid improvement on this treatment; the cough, fever, and malaise disappeared, and there was normalization of C-reactive protein, however the erythrocyte sedimentation rate remained elevated. This was interpreted as a treatment effect, and after 24 months of treatment the patient felt well and treatment was therefore discontinued.

At a clinical control 6 months after the discontinuation of treatment, there were no signs of recurrence of the Mycobacterium and the patient felt well without any complaints.

3. Discussion

A patient with disseminated *M. celatum* disease and a primary immune deficiency was treated successfully with a combination of azithromycin, ciprofloxacin, and pyrazinamide. Previous treatment with clarithromycin, isoniazid, and ethambutol in accordance with the ATS guidelines² was unsuccessful. This case report adds to the sparse clinical data on the treatment of a rare mycobacterial infection, for which we know little about the clinical relevance of resistance testing. The clinical course indicates that the results of susceptibility testing were in agreement with the final treatment outcome and this case adds to the body of evidence on the treatment of *M. celatum*. No certain treatment failure was documented on the first treatment regimen, which has been found to be effective by others and for which there was in vitro susceptibility. Yet we chose a change of regimen due to the clinical deterioration and noted improvement following this change. The modified treatment regimen was chosen from the effective salvage regimen used by Piersimoni et al. in a reported immunocompromised case,³ which involved pyrazinamide. We chose this regimen in order to be able to keep the patient on an oral therapy and to change all used drugs. We had no knowledge of pyrazinamide resistance in this particular case, and although generally not on the list of recommended drugs in the ATS guidelines, we chose to use it based on the successful experience in the Italian case³ and from the general experience and World Health Organization (WHO) recommendations⁴ that pyrazinamide is useful in multidrug-resistant tuberculosis (MDR-TB) despite possible in vitro resistance.

In a 2004 review by Christiansen et al.,⁵ 19 previous cases of *M. celatum* were identified, of which 15 had occurred in immunosuppressed patients. A comparison of treatment regimens revealed that the *M. celatum* organism was generally susceptible to azithromycin, clarithromycin, and ciprofloxacin, although some isolates were reported to be resistant to ciprofloxacin. All isolates were reported to be resistant to rifampin and most to isoniazid. Although not thoroughly tested, it seemed that most isolates were susceptible to newer quinolones. Tan et al.⁶ reached the same conclusion based on a review of eight previous HIV-negative cases and also concluded that ethambutol is effective in the treatment

regimen. All but one of the cases in the review improved or were cured after such treatment. The ATS guidelines² suggest that *M. celatum* is susceptible to isoniazid and rifabutin, which, based on previous case reports, may not after all be the case.

In the latest reported case of *M. celatum*, a 25-year old patient's congenital cystic adenomatoid malformation in adulthood was complicated with an *M. celatum* infection.⁷ The infection was treated with ethambutol, rifampin, and clarithromycin, which was later supplemented with levofloxacin due to low susceptibility to rifampin. The treatment duration was 16 months, with the patient having a right lung lobectomy 4 months into treatment.

In another case of *M. celatum* pulmonary disease in an immunocompetent 33-year old patient,⁸ the treatment regimen was composed of clarithromycin, ethambutol, and ciprofloxacin for 1 year. The patient then had a pulmonary resection and the duration of treatment was prolonged to 2 years. This particular strain was found to be resistant to isoniazid and rifampin. Both cases had long treatment durations, and in the present case, the treatment duration was also prolonged to 24 months due to suspected relapse.

This case adds to the clinical experience that there is often a discrepancy between the resistance testing results in non-tuberculous mycobacterial isolates and the clinical response in the patient, as has been reviewed by Petrini.⁹ This is important to be aware of, and therefore it is important that clinical experiences with these patients are published.

In conclusion, *M. celatum* is an unusual cause of mycobacterial disease and there is little clinical knowledge about treatment options. This case report presents a case of disseminated infection in an immunocompromised patient with possible relapse on isoniazid, ethambutol, and clarithromycin treatment, but with a good response to a treatment regimen consisting of azithromycin, ciprofloxacin, and pyrazinamide.

Conflict of interest: No conflict of interest or funding sources to declare.

References

- Butler WR, O'Connor SP, Yakrus MA, Smithwick RW, Plikaytis BB, Moss CW, et al. *Mycobacterium celatum* sp. nov. *Int J Syst Bacteriol* 1993;**43**:539–48.
- An official ATS/IDSA statement. Diagnosis, treatment and prevention of non-tuberculous mycobacterial diseases. American Thoracic Society; 2007 [accessed on 16.07.14].
- Piersimoni C, Tortoli E, De Lalla F, Nista D, Donato D, Bornigia S, et al. Isolation of *Mycobacterium celatum* from patients infected with human immunodeficiency virus. *Clin Infect Dis* 1997;**24**:144–7.
- Falzon D, Jaramillo E, Schünemann HJ, Arentz M, Bauer M, Bayona J, et al. WHO guidelines for the programmatic management of drug-resistant tuberculosis: 2011 update. *Eur Respir J* 2011;**38**:516–28.
- Christiansen DC, Roberts GD, Patel R. *Mycobacterium celatum*, an emerging pathogen and cause of false positive amplified *Mycobacterium tuberculosis* direct test. *Diagn Microbiol Infect Dis* 2004;**49**:19–24.
- Tan C, Lai C, Chou C, Hsueh P. *Mycobacterium celatum* pulmonary infection mimicking pulmonary tuberculosis in a patient with ankylosing spondylitis. *Int J Infect Dis* 2009;**13**:e459–62.
- Ikegame S, Nagamatsu Y, Nagata N, Kazumi Y, Mitarai S, Iwasaki Y, et al. Congenital cystic adenomatoid malformation in adulthood complicated by *Mycobacterium celatum* infection. *Intern Med* 2012;**51**:2203–7.
- Jun H, Lee NY, Kim J, Koh W. Successful treatment of *Mycobacterium celatum* pulmonary disease in an immunocompetent patient using antimycobacterial chemotherapy and combined pulmonary resection. *Yonsei Med J* 2010;**51**:980–3.
- Petrini B. Non-tuberculous mycobacterial infections. *Scand J Infect Dis* 2006;**38**:246–55.