



## Original Article

Using amniotic membrane for anal sphincter repair  
in animal model

Ahmad Izadpanah<sup>a,b</sup>, Mohammad Rezazadehkermani<sup>b</sup>, Mohammadali Ghaderi<sup>c</sup>,  
Salar Rahimikazerooni<sup>a</sup>, Alireza Safarpour<sup>a</sup>, Kaynoosh Homayouni<sup>d</sup>, Maral Mokhtari<sup>e</sup>,  
Alimohammad Banzadeh<sup>a,b,\*</sup>

<sup>a</sup> Colorectal Research Center, Shiraz University of Medical Sciences, Shiraz, Iran

<sup>b</sup> Department of General Surgery, School of Medicine, Shiraz University of Medical Sciences, Shiraz, Iran

<sup>c</sup> Emergency Management Center, Shiraz University of Medical Sciences, Shiraz, Iran

<sup>d</sup> Department of Physical Medicine and Rehabilitation, School of Medicine, Shiraz University of Medical Sciences, Shiraz, Iran

<sup>e</sup> Department of Pathology, School of Medicine, Shiraz University of Medical Sciences, Shiraz, Iran

## ARTICLE INFO

## Article history:

Received 9 November 2015

Accepted 10 December 2015

Available online 1 February 2016

## Keywords:

Anal sphincter

Sphincteroplasty

Amniotic membrane

Electromyography

Fecal incontinence

## ABSTRACT

**Purpose:** Sphincter repair is the primary management for fecal incontinence especially in traumatic causes. Regardless of progression in the method and material of sphincter repair, the results are still disappointing. This study evaluates the efficacy of using amniotic membrane during sphincteroplasty regarding its effects in healing of various tissues.

**Methods:** Rabbits undergone sphincterotomy and after three weeks end to end sphincteroplasty was done. Animals divided to three groups: classic sphincteroplasty, sphincteroplasty with fresh amniotic membrane and sphincteroplasty with decellularized amniotic membrane. Three weeks after sphincteroplasty animals were sacrificed and sphincter complex was sent for histopathologic evaluation. Sphincter muscle diameter and composition of sphincter was evaluated. Before sphincterotomy, before and after sphincteroplasty electromyography of sphincter at the site of repair were recorded.

**Results:** No statistical significant difference was seen between groups even in histopathology or electromyography.

**Conclusion:** Although amniotic showed promising effects in the healing of different tissue in animal and human studies it was not effective in healing of injured sphincter.

© 2016 Sociedade Brasileira de Coloproctologia. Published by Elsevier Editora Ltda. All rights reserved.

\* Corresponding author.

E-mail: [bananzadeh@gmail.com](mailto:bananzadeh@gmail.com) (A. Banzadeh).

<http://dx.doi.org/10.1016/j.jcol.2015.12.004>

2237-9363/© 2016 Sociedade Brasileira de Coloproctologia. Published by Elsevier Editora Ltda. All rights reserved.

## Uso de membrana amniótica para reparo de esfíncter anal em modelo animal

### R E S U M O

#### Palavras-chave:

Esfíncter anal  
Esfíncteroplastia  
Membrana amniótica  
Eletromiografia  
Incontinência fecal

**Objetivo:** Reparo do esfíncter é o tratamento primário para casos de incontinência fecal, especialmente em causas traumáticas. Independentemente da progressão no método e do material de reparo do esfíncter, os resultados são ainda desapontadores. Esse estudo avalia a eficácia do uso da membrana amniótica durante a esfíncteroplastia, com relação aos seus efeitos na cura de diversos tecidos.

**Métodos:** Coelho foram submetidos a um procedimento de esfíncterotomia e, depois de transcorridas três semanas, foi realizada uma esfíncteroplastia término-terminal. Os animais foram divididos em três grupos: esfíncteroplastia clássica, esfíncteroplastia com membrana amniótica fresca, e esfíncteroplastia com membrana amniótica descelularizada. Três semanas após a realização da esfíncteroplastia, os animais foram sacrificados e o complexo esfínctérico foi encaminhado para avaliação histopatológica. O diâmetro do músculo esfínctérico e a composição do esfíncter foram avaliados. Antes da esfíncterotomia, e antes e depois da esfíncteroplastia, foi registrada a eletromiografia do esfíncter no local do reparo.

**Resultados:** Não foi observada diferença estatisticamente significativa entre os grupos, mesmo na histopatologia, ou na eletromiografia.

**Conclusão:** Embora a membrana amniótica tenha demonstrado efeitos promissores em termos da cicatrização dos diferentes tecidos em estudos com animais e em humanos, não foi observada eficácia na cura do esfíncter lesionado.

© 2016 Sociedade Brasileira de Coloproctologia. Publicado por Elsevier Editora Ltda.

Todos os direitos reservados.

## Introduction

Overall prevalence of fecal incontinence in the general population is 2% and surgical repair is the mainstay of treatment especially in the traumatic causes of sphincter defect. Although the techniques of sphincter repair was evolved during last decades but the result is still disappointing.<sup>1</sup> With the emerging of anal ultrasound evaluation of sphincter structure and detecting the sphincter defect became possible. The sphincter defect could be detected in most of the cases after the repair and the score of continence would decline with time. It is still unknown that this defect is due to the technique of repair or infection or natural process of healing.<sup>2</sup>

Comparing overlapping or end to end repair of sphincter defect did not make significant difference in the result of sphincter repair.<sup>3</sup> A Cochrane has shown no improvement in the outcome of simple sphincter repair or adding diverting ostoma to the repair procedure.<sup>4</sup> Studies also showed the efficacy of sphincter repair with Prolene or PDS sutures is higher than traditional repair with chromic or Vicryl suture.<sup>5</sup>

Amniotic membrane had shown promising results in healing pathways including: (1) proliferation, migration and chemotaxis of different cell types, (2) production and remodeling of extracellular matrix, (3) release of cytokines and growth factors. It has been used in many regenerative processes since 1910 when first used in skin graft.<sup>6</sup> Amniotic membrane is widely used in ophthalmology for cornea, conjunctiva, or orbit pathologies.<sup>7</sup> There are multiple molecular basis for explaining the possible mechanism of amniotic membrane healing pathways. Amniotic membrane contain high amount of IL-8

which is a strong stimulator for angiogenesis. It also contain platelet derived growth factor and basic fibroblast growth factor in relatively high concentration.<sup>8</sup>

Regarding mentioned evidences using amniotic membrane in sphincter repair, seemed to be reasonable to improve outcome. In this study we investigate the efficacy of amniotic membrane application during sphincter repair in animal model of sphincter damage.

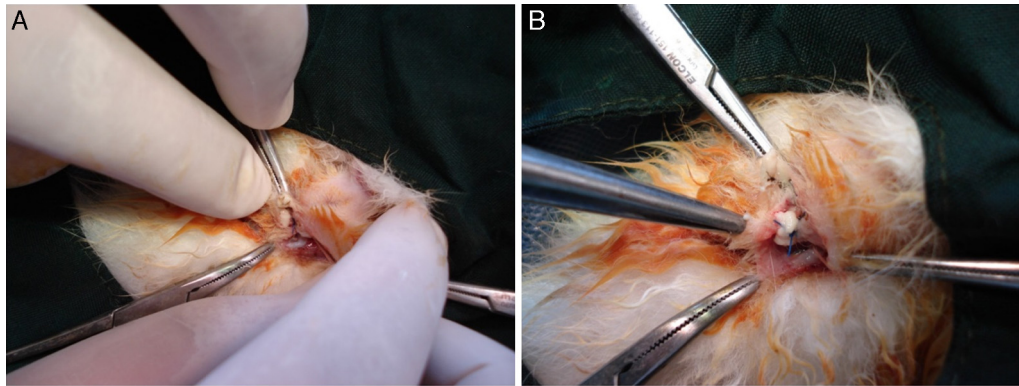
## Methods and materials

### Amniotic membrane preparation

In this study we used two forms of fresh and decellularized amniotic membrane. Fresh amnion was gathered from elective term cesarean sections in order to use normal amniotic membrane with least risk of infection. This amnion was kept in 4°C and used at least 8 hours after harvesting. Decellularized amniotic membrane was provided by Ghotbodini Burn hospital with the standard procedure.

### Animals

After approving of project by Shiraz university of Medical Sciences Ethics committee project was started. New Zealand Rabbits were provided by Shiraz University of Medical Science Animal Lab. Rabbits with weight range of 2.5–3 kg and age of six months were applied. They were kept in standard 12 hours day/night cycle with free access to water and standard rodent food. In this study we used 15 rabbits divided to three groups.



**Fig. 1 – Site of sphincteroplasty. (A) Simple sphincteroplasty group; (B) amniotic membrane is wrapped around the site of sphincteroplasty and fixed with sphincteroplasty suture.**

For control group simple end to end sphincter repair was done and in other two groups repair with fresh or decellularized amniotic membrane was done.

#### Electromyographic studies

Before any surgical intervention an EMG trace was taken at the posterior midline of sphincter as base line. Three weeks after sphincterotomy and three weeks after sphincteroplasty also an EMG trace was taken from each animal. The EMG was taken with concentric 26 gauge needles in lithotomy position after attachment of ground connection to the rabbit back. Frequency interval was recorded and the least frequency interval was associated with more competent sphincter muscle.

#### Surgical procedure

Animals were anesthetized with 80 mg/kg Ketamine and 12 mg/kg Xylazine before any intervention then they were fixed in lithotomy position and standard hair clipping, prep and drape were done. Then sphincterotomy was done in posterior midline using No. 11 blade. All fibers of external and internal sphincter were cut and separated. Three weeks after the sphincterotomy sphincter repair was done and animals categorized based on the way of sphincter repair as follow. After induction of anesthesia the rabbit was fixed in lithotomy position and a transverse incision was given posterior to the anus. Then free ends of sphincter muscle were found. In the control group simple end to end sphincter repair was done with 4-0 Prolene suture (Fig. 1A) and the skin over the site of repair closed with chromic 4-0. For amniotic membrane groups a 4 × 2 cm shit of amnion was prepared and repair was done over the shit and at the end of repair site of repair was wrapped with the shit and fixed to the repair site with sphincteroplasty suture ties (Fig. 1B) and skin closed with chromic suture.

Three weeks after sphincteroplasty, after recording the final EMG trace and induction of anesthesia anus and sphincter complex *en bloc* resected and site of repair marked with a 5-0 nylon suture then sent for pathologic examination in formalin solution. After that animals were sacrificed with intracardiac injection of KCl solution.

#### Histopathology evaluation

After fixing the samples in the formalin, 5 μm thick sections of the sample was taken and slides were reviewed by a blinded pathologist. At first site of sphincter repair evaluated and site of repair reported as muscle dominant, fibrosis dominant or mixed regarding previous literature.<sup>9</sup> Then the diameter of sphincter was measured at the site of repair in posterior quadrant. The diameter was also measured in anterior and lateral quadrants.

#### Statistical analysis

ANOVA was used to compare sphincter muscle diameter between groups and multivariate analysis was used to evaluate the EMG results between and within the different groups. All analyses were done by SPSS software.

#### Results

All of the animals tolerate the course of study well and no mortality was observed during the study period.

Table 1 briefly demonstrates the result of electromyography study of sphincter reported as frequency interval in different stages of the study. A one-way repeated measures ANOVA was conducted to compare the results of EMG of sphincter muscles at time 1 (prior to the intervention), time 2 (following the intervention) and time 3 (three-month follow-up). There was a significant effect for time, Wilks' Lambda = 0.316,  $F = 11.90$ ,  $p = 0.002$ . Mauchly's test of sphericity was not violated ( $p = 0.427$ ).

Table 2 demonstrates the mean muscle diameter in different groups. A Kruskal-Wallis Test revealed a statistically significant difference in lateral muscle diameter in three groups ( $p = 0.01$ ). Mann-Whitney tests revealed that the significance difference was between the lateral muscle diameter and two other anterior and posterior muscles diameters.

There was also no significant difference in sphincter structure at the site of sphincter repair. The distribution of fibrosis or muscle dominance between groups were similar as tested by Kruskal-Wallis test ( $p$  value = 0.75).

**Table 1 – Summary of electromyography results.<sup>a</sup>**

Group	Pre-sphincterotomy (time 1)	Pre-sphincteroplasty (time 2)	Post-sphincteroplasty (time 3)
Decellularized amniotic membrane	21 ± 5.48	35 ± 6.12	29 ± 5.48
Fresh amniotic membrane	12 ± 4.47	23 ± 4.47	16 ± 5.47
Control	28 ± 4.47	24 ± 5.48	22 ± 4.47

<sup>a</sup> Mean ± standard deviation of frequency interval recorded at the site of sphincteroplasty.

**Table 2 – Muscle diameters in sphincter quadrants.<sup>a</sup>**

	Anterior muscle diameter	Lateral muscle diameter <sup>b</sup>	Posterior muscle diameter
Decellularized amniotic membrane	2.3 ± 0.57	1.35 ± 0.28	2.2 ± 0.27
Fresh amniotic membrane	2.0 ± 0.0	2.4 ± 0.65	2.5 ± 0.5
Control	2.16 ± 0.45	2.4 ± 0.67	3.0 ± 0.79

<sup>a</sup> Mean ± standard deviation of muscle diameter.  
<sup>b</sup> The difference between Groups was statistically significant ( $p$  value = 0.01).

## Discussion

This study evaluates the efficacy of using amniotic membrane in sphincteroplasty of rabbit's injured anal sphincter. Although the result of electromyography showed improvement in the sphincter muscle function; especially in the fresh amniotic membrane group, but this difference was not statistically significant. Histopathology evaluation of sphincter muscle did not show a significant difference between groups. However it seems that high level of frequency interval variation caused this non-significant statistically difference.

Amniotic membrane was previously used for repair of various tissue defects such as cornea, skin and duodenum.<sup>10</sup> Some studies also showed sever fibrosis at the site of repair in human subjects<sup>11</sup> and this may leads to improve the outcome of rectovaginal fistula repair with using it as a prosthesis during the repair.<sup>12</sup> Enhance fibrosis also might be associated with better sphincter out come as it cause the free ends of sphincter attached stronger but this was not proven by our study as the composition of sphincter was not different between groups.

Amniotic membrane contains various levels of different cytokine and also stem cells; that may have potential role in the healing of injured sphincter. Since cells and sensitive structures might be damage with time we used fresh amniotic membrane and compare the results with processed amniotic membrane which also did not revealed a significant difference.

In this study we used histopathology evaluation as a marker of anatomic repair and electromyography as a marker of physiologic repair to evaluate the outcome of sphincteroplasty but the gold standard of evaluation of sphincter function is manometry. Application of manometry in small animals is not easily possible due to small size of anus and also lack of voluntary contraction and this is one of the week point of the study.

Although application of amniotic membrane in repair of different tissue defect especially in the field of coloproctology but application of amniotic membrane in rabbit sphincteroplasty was not associated with promising result. For further studies it is suggested to apply larger animal model and different way of evaluating sphincter function.

## Conflicts of interest

The authors declare no conflicts of interest.

## Acknowledgments

The study was funded by Vice Chancellor for research and technology Shiraz University of Medical Sciences (Grant No. 92-01-01-6232).

## REFERENCES

- Gutierrez B, Madoff R, Lowry A, Parker S, Buie W, Baxter N. Long-term results of anterior sphincteroplasty. *Dis Colon Rectum*. 2004;47(5):727–31.
- Corman ML, Bergamaschi RCM, Nicholls RJ, Fazio VW. *Corman's colon and rectal surgery*. 6th ed. Lippincott Williams & Wilkins; 2013.
- Pescatori LC, Pescatori M. Sphincteroplasty for anal incontinence. *Gastroenterol Rep*. 2014;2:92–7.
- Brown SR, Wadhawan H, Nelson RL. Surgery for faecal incontinence in adults. *Cochrane Database Syst Rev*. 2010;CD001757.
- Altomare DF, De Fazio M, Giuliani RT, Catalano G, Cuccia F. Sphincteroplasty for fecal incontinence in the era of sacral nerve modulation. *World J Gastroenterol*. 2010;16(42):5267–71.
- Silini A, Parolini O, Huppertz B, Lang I. Soluble factors of amnion-derived cells in treatment of inflammatory and fibrotic pathologies. *Curr Stem Cell Res Ther*. 2013;8:6–14.
- Rahman I, Said D, Maharajan V, Dua H. Amniotic membrane in ophthalmology: indications and limitations. *Eye*. 2009;23:1954–61.
- Koob TJ, Rennert R, Zabek N, Masee M, Lim JJ, Temenoff JS, et al. Biological properties of dehydrated human amnion/chorion composite graft: implications for chronic wound healing. *Int Wound J*. 2013;10:493–500.
- Aghaee-afshar M, Rezazadehkermani M, Asadi A, Malekpour-afshar R, Shahesmaeili A, Nematollahi-mahani S. Potential of human umbilical cord matrix and rabbit bone marrow-derived mesenchymal stem cells in repair of surgically incised rabbit external anal sphincter. *Dis Colon Rectum*. 2009;52:1753–61.
- Ghahramani L, Jahromi AB, Dehghani MR, Ashraf MJ, Rahimikazerouni S, Rezaianzadeh A, et al. Evaluation of repair

- in duodenal perforation with human amniotic membrane: an animal model (dog). *Adv Biomed Res.* 2014;3:113.
11. Kassem RR. Severe fibrosis of extraocular muscles after the use of lyophilized amniotic membrane in strabismus surgery. *J AAPOS.* 2011:410-1.
  12. Roshanravan R, Ghahramani L, Hosseinzadeh M, Mohammadipour M, Moslemi S, Rezaianzadeh A, et al. A new method to repair recto-vaginal fistula: use of human amniotic membrane in an animal model. *Adv Biomed Res.* 2014;3:114.