JACC: CARDIOVASCULAR IMAGING
VOL. 8, NO. 6, 2015
ISSN 1936-878X/$36.00
http://dx.doi.org/10.1016/j.jcmg.2014.06.025
© 2015 BY THE AMERICAN COLLEGE OF CARDIOLOGY FOUNDATION
PUBLISHED BY ELSEVIER INC.

iPIX

IMAGING VIGNETTE

Early Bioprosthetic Valve Failure

A Pictorial Review of Rare Causes

Paul C. Cremer, MD,* L. Leonardo Rodriguez, MD,* Brian P. Griffin, MD,* Carmela Tan, MD,† Rene Rodriguez, MD,† Douglas R. Johnston, MD,‡ Gosta B. Pettersson, MD,‡ Venu Menon, MD*

IN OLDER ADULTS, BIOPROSTHETIC VALVES RARELY FAIL WITHIN 5 YEARS OF THE INDEX SURGERY. Such failures pose a challenge to patients, clinicians, and surgeons. Although clinicians are generally aware of valve dysfunction related to overt endocarditis, patient-prosthesis mismatch, and technical error, less-recognized causes of early bioprosthetic valve failure include valve thrombosis (**Figures 1 and 2**, Online Videos 1 and 2), excessive pannus formation (**Figures 3 and 4**, Online Videos 3, 4, 5, and 6), and accelerated structural valve deterioration (**Figures 5 and 6**, Online Videos 7, 8, 9, and 10). Given their rarity, these failure mechanisms have

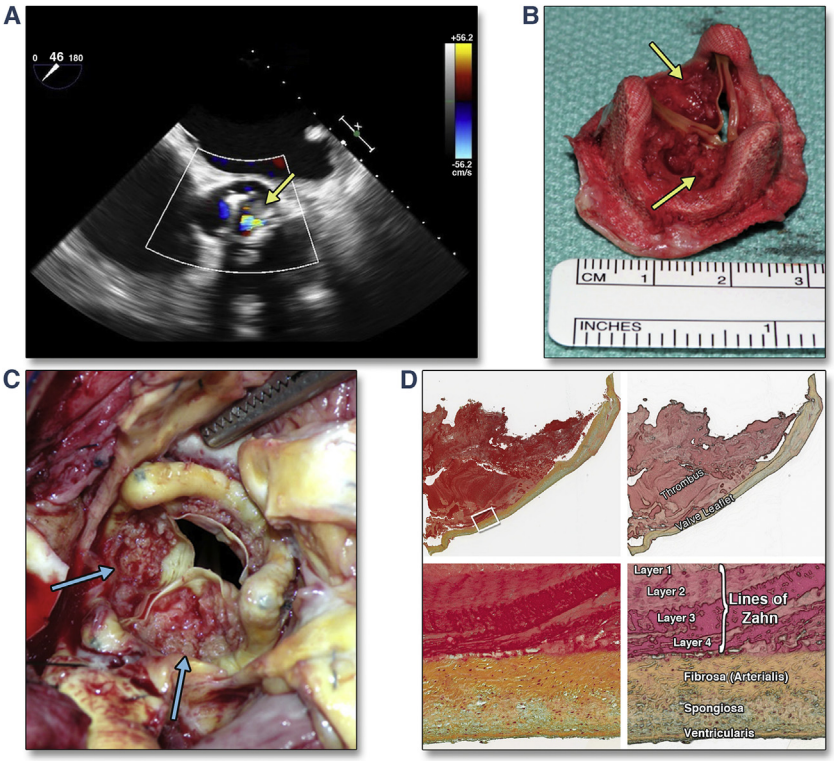

FIGURE 1 Thrombi on the Nonflow Surface of a Bioprosthesis Leading to Stenosis

One year after aortic valve replacement with a 25-mm Medtronic Mosaic valve (Medtronic, Minneapolis, Minnesota), severe aortic stenosis recurred in a 78-year-old patient **(A and B)** (Online Video 1). Thrombi suspected on transesophageal echocardiography are confirmed on the nonflow surface of the valve **(yellow arrows)**. A 67-year-old man presented similarly with recurrent severe aortic stenosis 1 year after aortic valve replacement with a 25-mm Biocor bioprosthesis (St. Jude Medical, St. Paul, Minnesota) **(C and D)**. Thrombi are seen on the nonflow surface of the valve **(C, blue arrows)**, and Movat stain reveals thrombus in **red** and leaflet in **yellow-green (D)**. Lines of Zahn represent layering of thrombus over time that stiffens the leaflet and renders it immobile. Even though results of blood cultures had been negative, culture of the valve grew *Propionibacterium acnes*, emphasizing the importance of a comprehensive assessment for infection because thrombus and infective endocarditis may both be present.

From the *Department of Cardiovascular Medicine, Heart and Vascular Institute, Cleveland Clinic, Cleveland, Ohio; †Department of Anatomic Pathology, Heart and Vascular Institute, Cleveland Clinic, Cleveland, Ohio; and the ‡Department of Thoracic and Cardiovascular Surgery, Heart and Vascular Institute, Cleveland Clinic, Cleveland, Ohio. The authors have reported that they have no relationships relevant to the contents of this paper to disclose.

Manuscript received May 23, 2014; revised manuscript received June 16, 2014, accepted June 19, 2014.

JACC: CARDIOVASCULAR IMAGING, VOL. 8, NO. 6, 2015
JUNE 2015:737–40

FIGURE 2 A Large Thrombus Causing Bioprosthetic Valve Stenosis

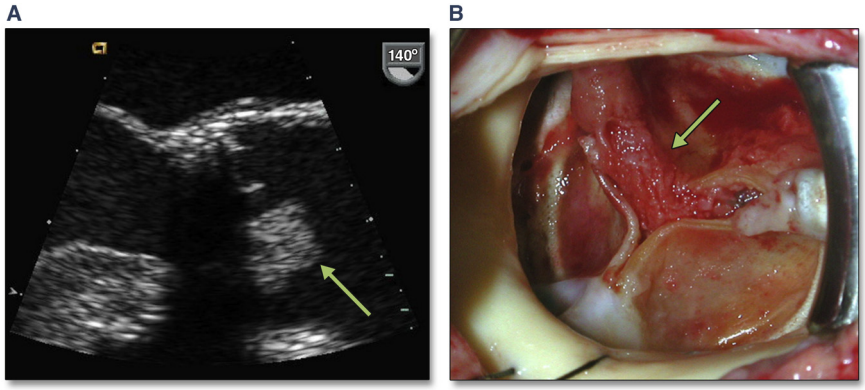

Three years after receiving a 21-mm Carpentier-Edwards valve (Edwards Lifesciences, Irvine, California), a 51-year-old woman returned with severe aortic stenosis and a large thrombus **(green arrows, A and B)** (Online Video 2). The microbiologic assessment was unremarkable, and she received a 24-mm homograft. With aortic valve thrombosis, the threshold for root replacement may be lower because aortic homografts may have decreased thrombogenicity.

FIGURE 3 Thrombus and Subvalvular Pannus Resulting in Bioprosthetic Valve Stenosis

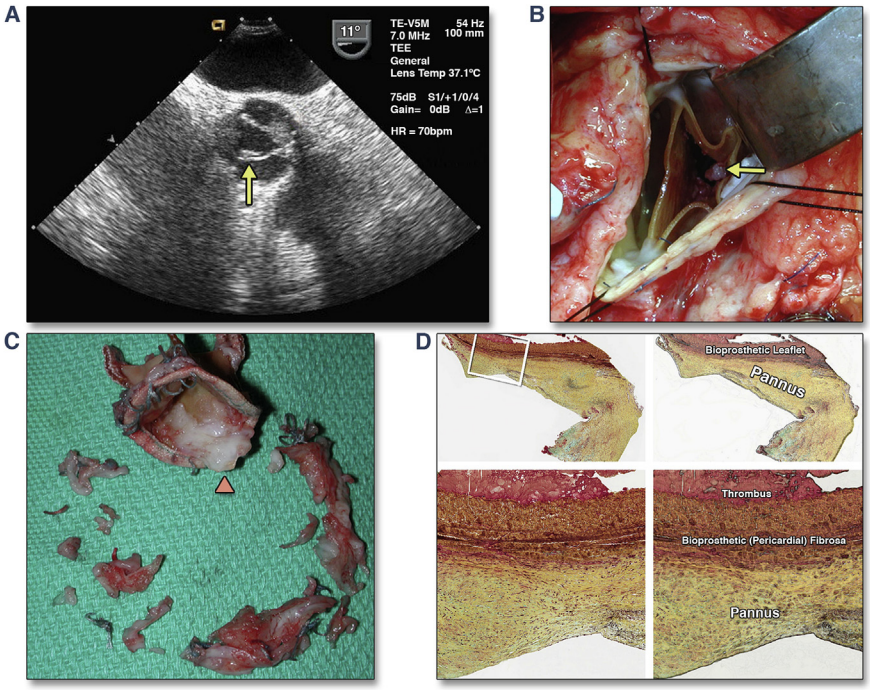

One year after aortic valve replacement with a 21-mm, 3-F stentless valve (Medtronic), a 58-year-old woman returned with severe aortic stenosis. A focal thrombus **(yellow arrow, A and B)** (Online Video 3) was observed, as well as extensive subvalvular pannus **(pink arrowhead, C)**. Movat stain of the valve **(D)** revealed the fibrosa layer of the bovine pericardium as **dark yellow-orange**, rich in fibrous tissue. Small thrombi may serve as a nidus for exuberant pannus formation. Both the thrombus and subvalvular pannus contribute to immobilization of the leaflet and valvular stenosis.

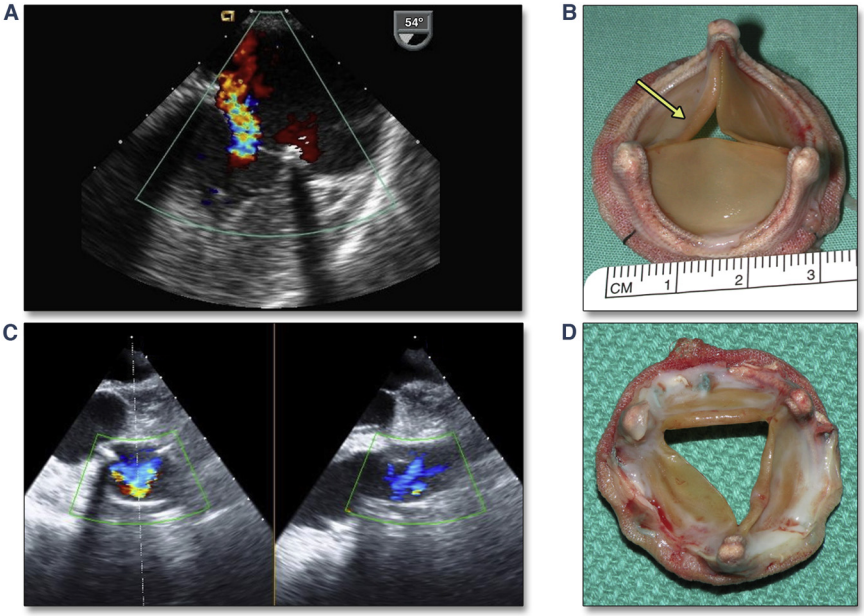

FIGURE 4 Pannus Restricting Leaflets to Cause Bioprosthetic Regurgitation

One year after mitral valve replacement with a 29-mm Carpentier-Edwards bioprosthesis (Edwards Lifesciences), a 70-year-old woman developed severe mitral regurgitation with a restricted leaflet **(A and B)** (Online Videos 4 and 5). Focal pannus formation led to restriction and infolding of the leaflet **(yellow arrow, B)**. A 46-year-old woman with repaired tetralogy of Fallot presented 2 years after receiving a 27-mm Carpentier-Edwards bioprosthesis for severe pulmonic regurgitation **(C and D)** (Online Video 6). Her dyspnea had returned, and she had recurrent severe pulmonic regurgitation. The bioprosthesis demonstrated extensive pannus formation restricting all leaflets.

not been well characterized, and echocardiographic features that may aid in diagnosis are sparse. In this pictorial essay, we highlight these lesser-known causes of early bioprosthetic valve failure. By recognizing simple echocardiographic findings within a clinical context, the correct diagnosis for these infrequent presentations can be ascertained (**Figure 7**).

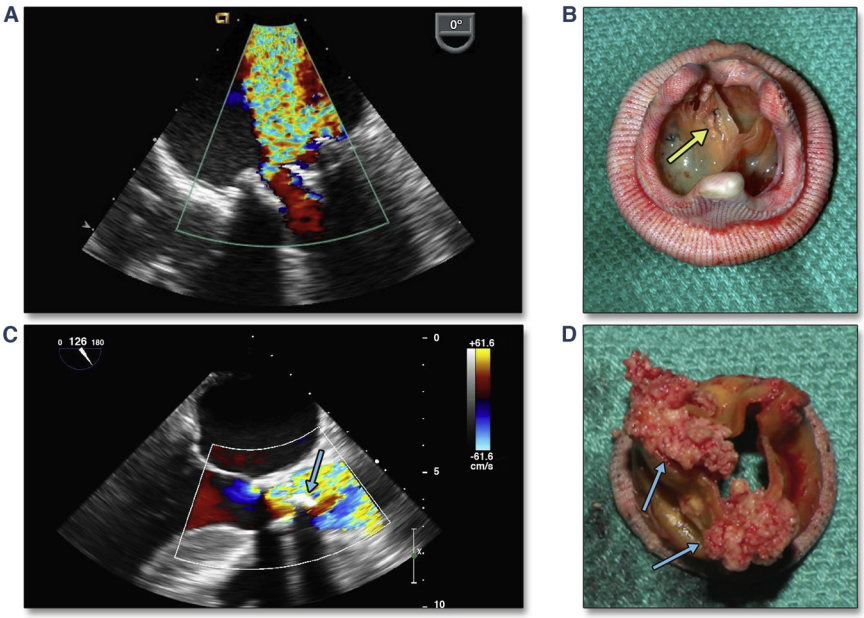

FIGURE 5 Calcification Causing a Leaflet Tear and Severe Bioprosthetic Regurgitation and Extrinsic Calcification Causing Bioprosthetic Stenosis

A 62-year-old woman presented with decompensated heart failure and severe mitral regurgitation 3 years after mitral valve replacement with a 27-mm Medtronic Mosaic porcine valve **(A and B)** (Online Video 7). At repeat surgery, the valve was calcified with a tear in 1 leaflet **(yellow arrow, B)**. A 70-year-old woman presented in decompensated heart failure 3 years after aortic valve replacement with a 19-mm Mitroflow (Sorin Group, Milan, Italy). An echocardiogram showed severe aortic stenosis and moderate aortic regurgitation. Surgery confirmed abnormalities on echocardiogram as extensive calcification **(C and D, blue arrows)** (Online Video 8). She subsequently received a 23-mm Trifecta bioprosthesis (St. Jude Medical). Concomitant patient-prosthesis mismatch may have contributed to the accelerated calcification.

JACC: CARDIOVASCULAR IMAGING, VOL. 8, NO. 6, 2015
JUNE 2015:737–40

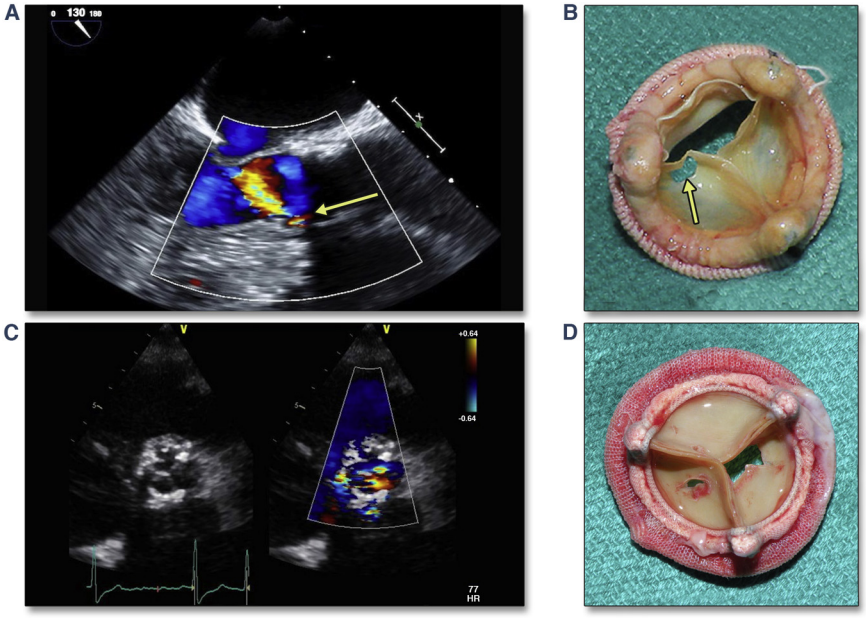

FIGURE 6 Primary Perforation and Endocarditis Leading to Bioprosthetic Regurgitation

One year after receiving a 25-mm Biocor bioprosthesis, a 73-year-old woman returned with dyspnea on exertion and significant aortic regurgitation despite a post-operative echocardiogram with no valvular dysfunction. A follow-up echocardiogram demonstrated valvular aortic regurgitation, and the valve had a round perforation in 1 leaflet **(A and B, yellow arrow)** (Online Video 9). There was no evidence of infection or calcification. In contrast, a 76-year-old man returned with heart failure and severe aortic regurgitation 1 year after aortic valve replacement with a 21-mm Carpentier-Edwards bioprosthesis. Upon re-operation, a large tear was seen in 1 leaflet, and a perforation was present in another **(C and D)** (Online Video 10). Bacterial polymerase chain reaction assay of the explanted valve was positive for *Tropheryma whipplei*. This finding again underscores the importance of an exhaustive search for endocarditis lest an infected valve is mistakenly labeled as failure due to a primary tear.

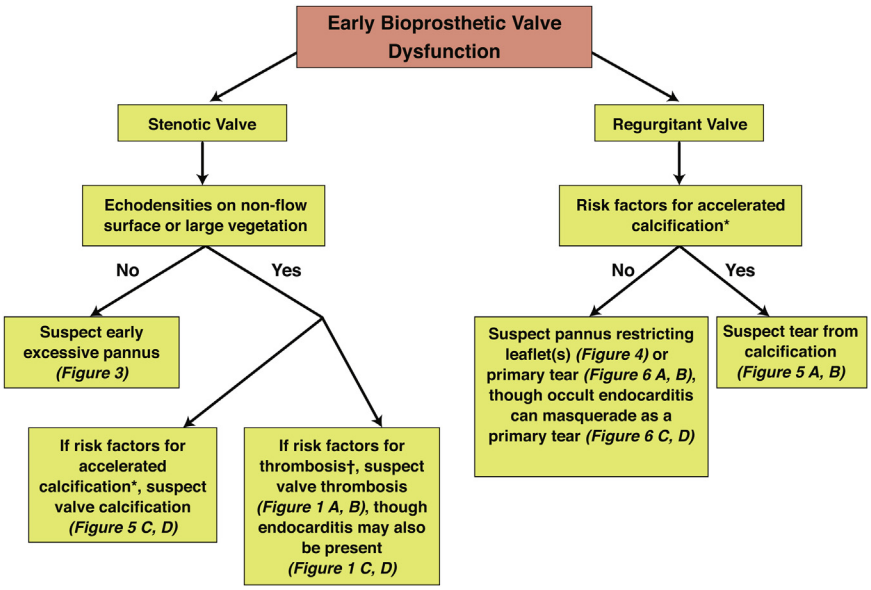

FIGURE 7 Simplified Approach to Rare Causes of Early Bioprosthetic Valve Failure

*Risk factors include younger age, enhanced immune response, hyperparathyroidism, diabetes mellitus, and mitral (as opposed to aortic) position. †Risk factors include a history of thromboembolic events, a sewing ring that is not yet fully endothelialized, and a lack of anticoagulation.

REPRINT REQUESTS AND CORRESPONDENCE: Dr. Venu Menon, Department of Cardiovascular Medicine, Cleveland Clinic, 9500 Euclid Avenue, Cleveland, Ohio 44195. E-mail: menonv@ccf.org.

KEY WORDS bioprosthetic valve, calcification, pannus, primary leaflet tear, structural valve deterioration, thrombus

APPENDIX For supplemental videos and their legends, please see the online version of this article.