



King Saud University

Saudi Journal of Biological Sciences

www.ksu.edu.sa
www.sciencedirect.com



الجمعية السعودية لعلمون الحياة
SAUDI BIOLOGICAL SOCIETY

ORIGINAL ARTICLE

Sex determination using discriminant function analysis in Indigenous (Kurubas) children and adolescents of Coorg, Karnataka, India: A lateral cephalometric study



Darshan Devang Divakar^{a,*}, Jacob John^b, Abdulaziz Abdullah Al Kheraif^a, Seema Mavinapalla^c, Ravikumar Ramakrishnaiah^a, Sajith Vellappally^a, Mohamed Ibrahim Hashem^a, M.H.N. Dalati^d, B.H. Durgesh^a, Rima A. Safadi^{e,f}, Sukumaran Anil^g

^a Dental Biomaterials Research Chair, Dental Health Department, College of Applied Medical Sciences, King Saud University, Riyadh 11433, Saudi Arabia

^b Department of Orthodontics, K.V.G Dental College, and Hospital Sullia, Karnataka, India

^c Department of Oral Medicine and Radiology, KVG Dental College and Hospital, Sullia, Karnataka, India

^d Consultant Orthodontist and Restorative Dentist, Springs Dental Care, New Road Side, Horsforth, Leeds, LS18 4QD, UK

^e College of Dentistry, King Saud Bin Abdul Aziz University for Health Sciences, Riyadh 11426, Saudi Arabia

^f Faculty of Dentistry, Jordan University of Science and Technology, PO Box 3030, Irbid 22110, Jordan

^g College of Dentistry, Jazan University, PO Box 114, Jazan 45142, Saudi Arabia

Received 14 March 2016; revised 21 April 2016; accepted 8 May 2016

Available online 14 May 2016

KEYWORDS

Discriminant function analysis;
Forensic investigation;
Indigenous;
Lateral cephalograms;
Sex determination

Abstract *Aim:* To test the validity of sex discrimination using lateral cephalometric radiograph and discriminant function analysis in Indigenous (Kuruba) children and adolescents of Coorg, Karnataka, India. *Methods and materials:* Six hundred and sixteen lateral cephalograms of 380 male and 236 females of age ranging from 6.5 to 18 years of Indigenous population of Coorg, Karnataka, India called Kurubas having a normal occlusion were included in the study. Lateral cephalograms were obtained in a standard position with teeth in centric occlusion and lips relaxed. Each radiograph was traced and cephalometric landmarks were measured using digital calliper. Calculations of 24 cephalometric measurements were performed. *Results:* Males exhibited significantly greater mean angular and linear cephalometric measurements as compared to females ($p < 0.05$) (Table 5).

* Corresponding author at: Oral Medicine and Radiology, Dental Biomaterials Research Chair, Dental Health Department, College of Applied Medical Sciences, King Saud University, Riyadh 11433, Saudi Arabia. Tel.: +966 538038291.

E-mail address: darshandevang@gmail.com (D. Devang Divakar).

Peer review under responsibility of King Saud University.



Production and hosting by Elsevier

<http://dx.doi.org/10.1016/j.sjbs.2016.05.008>

1319-562X © 2016 The Authors. Production and hosting by Elsevier B.V. on behalf of King Saud University.

This is an open access article under the CC BY-NC-ND license (<http://creativecommons.org/licenses/by-nc-nd/4.0/>).

Also, significant differences ($p < 0.05$) were observed in all the variables according to age (Table 6). Out of 24 variables, only ULTc predicts the gender. The reliability of the derived discriminant function was assessed among study subjects; 100% of males and females were recognized correctly. *Conclusion:* The final outcome of this study validates the existence of sexual dimorphism in the skeleton as early as 6.5 years of age. There is a need for further research to determine other landmarks that can help in sex determination and norms for Indigenous (Kuruba) population and also other Indigenous population of Coorg, Karnataka, India.

© 2016 The Authors. Production and hosting by Elsevier B.V. on behalf of King Saud University. This is an open access article under the CC BY-NC-ND license (<http://creativecommons.org/licenses/by-nc-nd/4.0/>).

1. Introduction

In forensic and physical anthropological discipline, skeletal elements play an important role in sex determination. Although pelvis is commonly used for sex determination, skull serves as second best option. However, morphological characteristics and morphometry methods have been used with certainty; cephalometric radiographs are an asset of being more explicit when correlated to morphologic methods.

Humans have come a long way from primitive to modern life. The enthusiasm to achieve new heights has brought an ambience of scientific advancement and technology. On the other hand, the zeal to invent new ideas also coerced to a rolling swell in crime rate, terrorism, disasters and other atrocious conditions (Chandra Shekar and Reddy, 2009). In all such incidents, establishing an identity of an individual is an essential aspect in any investigating procedure. Ascertainment of sex from skeletal carcasses is one of the most critical aspects of osteological analysis which is crucial to medicolegal investigations (Mahesh Kumar et al., 2013; Patil and Mody, 2005) and physical anthropological research. It also plays an imperative role in establishing the biological profile of deceased, while facial reconstruction is unfeasible if sex is not correctly identified (Mathur et al., 2014). The precise and conscientious estimation of biological sex, age and ancestry is a necessity for the recognition of anonymous human remains in forensic investigations (Kranioti et al., 2014). Consequently, segregating, annotating and appraising the manifestations of sex form an indispensable part of all skeletal examination (Mathur et al., 2014).

Varieties of techniques are used in the establishment of sex by utilizing various guidelines. While dealing with skeletal remains, age, sex and racial affinity are the major fundamental determinations that must be sought. Although, the pelvis is thought to be the most definitive sex indicator, the skull also offers numerous excellent sex indicators which can be effectively preserved (Mahesh Kumar et al., 2013). Skull is possessed of hard structures, due to which it is the foremost maintained part of a skeleton. Therefore, in many situations it is the only accessible component for forensic investigations (Patil and Mody, 2005).

Despite the morphometric and anthropometric methods used in determining the identity of sex from an excarnated skull, radiographs offer an accurate, simpler, perfect and emulative method of sex determination by linear and angular measurements (Naikmasur et al., 2010). Many researchers have asserted that the estimation of sex by skull radiographs is a consistent technique which bestows exactness up to 80–100%. This precision can be further amplified by lateral and

postero-anterior cephalometric radiographs as they reveal supplementary features and additional points for analogizing (Naikmasur et al., 2010). Lateral cephalogram is exemplary for the analysis of skull as it provides information of a variety of anatomical points in a single radiograph and also it supplies details of architectural and morphological architectures and intra-cranial niceties for evaluation (Patil and Mody, 2005).

Analysis of the human skull by means of discriminant function has turned out to be an imperative method in legal medicine and forensic anthropology. The assessment of morphological character makes it feasible to use them as metrical variables for consequent discriminant function analysis (Franceschini et al., 2007). The main goal of this study was, therefore, to test the legitimacy of sex determination using lateral cephalometric radiography with discriminant function analysis on the Indigenous (Kuruba) population of Coorg, Karnataka, India.

Indigenous groups such as Eravas, Kurubas, Poleyas, and Kudiyas were the original inhabitants of Kodagu in the Western Ghats in India. They reside in the forests of Coorg and depend on it for their livelihood. We had included one such group i.e. Kurubas in our study for better understanding of them.

2. Materials and methods

This study is based on the metric data collected from lateral cephalometric radiographs to identify sexually dimorphic dissimilarities in craniofacial growth. Subjects with skeletal malocclusion, history of craniofacial trauma, developmental disorders of jaws, orthodontic or surgical orthognathic treatment were not included in this study. With teeth in centric occlusion and lips relaxed, lateral cephalograms were acquired in a standard position. Only acceptable quality radiographs were included for the study. The sample included 380 males and 236 females divided into age groups with increments of

Table 1 Distribution of study subjects according to age and gender.

Age (Years)	Male n (%)	Female n (%)	Total n (%)
≤8.5	35 (68.6)	16 (31.4)	51 (8.3)
8.6–10.5	75 (58.6)	53 (41.4)	128 (20.8)
10.6–12.5	117 (55.5)	94 (44.5)	211 (34.3)
12.6–14.5	81 (61.4)	51 (38.6)	132 (21.4)
≥14.6	72 (76.6)	22 (23.4)	94 (15.3)
Total	380 (61.7)	236 (38.3)	616 (100)

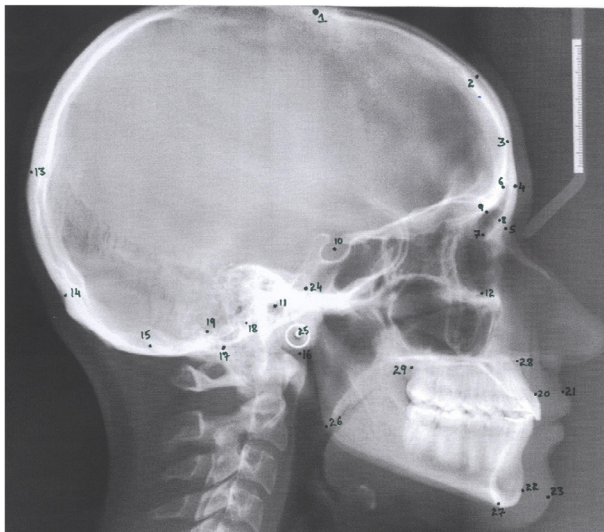


Figure 1 Cephalometric landmarks plotted on radiograph.

2.5 years as shown in [Table 1](#). An informed consent was taken to obtain their lateral cephalograms in the study. The magnification of measurements from each cephalogram used in the study was 10%, as manual tracing of films provides a physical representation of the data, tracing of 616 lateral cephalometric radiographs were done using a 0.05 mm mechanical pencil.

With the help of optimally working viewer, predetermined landmarks were identified and plotted on cephalograms. Using sella to nasion line and porion to orbitale line (Frankfort Horizontal) planes were established. The planes and landmarks are illustrated in ([Fig. 1](#)), [Tables 2 and 3](#). Computation of 24 cephalometric measurements was carried out.

The linear and angular variable measurements as shown in [Table 2](#), were systematized and moved to the MS-Office 2010, Excel data sheet, according to age and gender with males being represented by number 1 and females by number 2. (1 = males, 2 = Females).

2.1. Statistical analysis

Collected data were subsequently subjected to statistical analysis using the Statistical Package for the Social Sciences (SPSS) version 20.0. All the variables were subjected to descriptive statistics to obtain means, standard deviations and Student's *t* test for each of the measurements. Analysis of variance (ANOVA) was also done for each age group (Group a: 6.4–8.5; Group b: 8.6–10.5; Group c: 10.6–12.5; Group d: 12.6–14.5; Group e: 14.6–17.9) to check the discrepancies in variables across the age groups.

Fischer's linear discriminant function analysis was used for the complete sample and each individual group, to differentiate and exhibit which variables acknowledge for the best categorization between the groups. Significance was set at

Table 2 Cephalometric Variables.

Variable	Description
<i>Angular (°)</i>	
GM–SN	Glabella-metopion to sella-nasion (SN)
GM–FH	Glabella-metopion to porion-orbitale (Frankfort horizontal plane, FH)
GM–BaN	Glabella-metopion to basion-nasion (BaN)
G–Sg–M	Glabella-supraglabellare to supraglabellare-metopion
IOP–SN	Inion-opisthocranion to sella-nasion
IOP–FH	Inion-opisthocranion to porion-orbitale
IOP–BaN	Inion-opisthocranion to basion-nasion
O–I–Op	Opisthion-inion to inion-opisthocranion
<i>Linear (mm)</i>	
Sg–GM	Supraglabellare to glabella-metopion
G–SgN	Glabella to supraglabellare-nasion
FSHt	V1–V2 (frontal sinus height, vertical parameters of the frontal sinus cavity)
FSWd	H1–H2 (frontal sinus width on inner bregma to nasion line)
I–OpO	Inion to opisthocranion-opisthion
Ma–SN	Mastoidale to sella-nasion
Ma–FH	Mastoidale to porion-orbitale
MaHt	Mastoidale to B1–B2 (mastoid height from cranial base)
MaWd	B1–B2 (mastoid width at the level of cranial base)
<i>Proportional (%)</i>	
GPI glabella projection index = distance between glabella and the supraglabellare to nasion X100/distance between supraglabellare and nasion	
<i>Additional Cephalometric Variables:</i>	
(1) UL thickness distance between UL to UIF	
(2) Pfh distance from ramus height in mm from Articulare(Ar) tangent to ascending ramus to Mandibular plane (Gonion (Go) to Menton (Me))	
(3) LAFH: distance between Anterior Nasal Spine (ANS) to Menton (Me) line	
(4) ULTe ratio of total chin thickness to upper lip thickness	
(5) AfhPfh palatal plane(ANS-PNS) to Menton (Me) in relation to Pfh	

Table 3 Cephalometric landmarks.

1. Bregma (B)	16. Basion (Ba)
2. Metopion (M)	17. Mastoidale (Ma)
3. Supraglabellare (Sg)	18. B1
4. Glabella (G)	19. B2
5. Nasion (N)	20. Upper incisor facial (UIF)
6. V1	21. Upper lip (UL)
7. V2	22. Pogonion (Pog)
8. H1	23. Pogonion Soft Tissue (PogSt)
9. H2	24. Condylion (Co)
10. Sella (S)	25. Articulare(Ar)
11. Orbitale (Or)	26. Gonion (Go)
12. Porion (Po)	27. Menton (Me)
13. Opisthocranium (Op)	28. Anterior Nasal Spine (ANS)
14. Inion (I)	29. Posterior Nasal Spine (PNS)
15. Opisthion (O)	

$p < 0.05$. The discriminant function was derived for variables and a discriminant score was later determined for individuals.

3. Results

Among all study subjects ($n = 616$), majority (61.7%) were males followed by females (38.3%) and belonged to 10.6–12.5 years (34.3%) followed by 12.6–14.5 years (21.4%) age group. There were only 8.3% subjects below 8.5 years of age [Table 4](#).

Males exhibited significantly greater mean angular and linear cephalometric measurements as compared to females ($p < 0.05$) [Table 5](#). Also, significant differences ($p < 0.05$) were observed in all the variables according to age [Table 6](#).

The 24 cephalometric variables were subjected to discriminant function analysis to test their efficacy in differentiating the two sexes. Out of 24 variables, only ULTc predicts the gender. A discriminant function equation was derived using the coefficient of cephalometric variables ([Table 6](#)). According to functions at group centroids 0–2.917 were predicted as males and 0 to –4.801 were predicted as females [Table 7](#).

The reliability of the derived discriminant function was assessed among study subjects; 100% of males and females were recognized correctly [Table 8](#).

4. Discussion

Sex determination based on skeletal components serves a vital role to set up the biological profile of human remains in forensic and legal medicine ([Devang Divakar et al., 2015](#)). In cases where skull is only accessible for the forensic analysis which is required for medicolegal cases, it is very crucial to determine the gender and stature in order to establish the identity of the deceased person ([Mathur et al., 2014](#)). When a part of the bone of mutilated body is found it poses a challenge in identification. Availability of easy, cost-effective, rapid and precise procedures can significantly diminish the time taken in recognition of individuals, thus declining the legalities related with the same ([Binnal and Yashoda Devi, 2012](#)).

Radiographs are imperative tools which are handled in forensic anthropological examination particularly when skeletal remnants for investigation are not properly documented ([İşcan, 2005](#)). Factors such as genetic makeup and environmental conditions, socioeconomic status, food style and physical activities are subsidies to inter-population disparity. Evaluating skulls for dimorphism consistently includes visual methods which are absolutely instinctive, thereby causing high

Table 4 Comparison of mean angular and linear measurements of cephalometric variables among males and females.

Variables	Units	Male (Mean ± SD)	Female (Mean ± SD)	p -value
GM–SN	degree	96.5 ± 4.2	92.7 ± 6.7	0.001*
GM–FH	degree	104.6 ± 4.07	102.2 ± 3.57	0.001*
GM–BaN	degree	77.8 ± 3.5	75.8 ± 3.5	0.001*
G–Sg–M	degree	163.6 ± 3.1	161.1 ± 2.5	0.001*
IOP–SN	degree	96.7 ± 5.3	94.7 ± 4.8	0.001*
IOP–FH	degree	106.3 ± 2.7	102.6 ± 2.8	0.001*
IOP–BaN	degree	79.7 ± 2.6	75.2 ± 2.5	0.001*
O–I–Op	degree	132.3 ± 1.9	127.6 ± 5.3	0.001*
Sg–GM	mm	3.1 ± 1.2	2.7 ± 0.7	0.001*
G–SgN	mm	2.2 ± 0.5	1.9 ± 0.4	0.001*
FSht	mm	21.5 ± 3.2	19.2 ± 2.3	0.001*
FSWd	mm	7.1 ± 1.1	6.3 ± 0.6	0.001*
I–OpO	mm	17.9 ± 0.7	16.7 ± 0.8	0.001*
Ma–SN	mm	31.6 ± 1.8	29.7 ± 1.3	0.001*
Ma–FH	mm	20.4 ± 1.3	19.6 ± 1.2	0.001*
MaHt	mm	5.5 ± 0.6	5.2 ± 0.5	0.001*
MaWd	mm	15.3 ± 0.9	14.3 ± 0.8	0.001*
UL	mm	12.1 ± 0.8	11.5 ± 0.8	0.001*
Tc	mm	10.9 ± 0.7	10.4 ± 0.7	0.001*
Pfh	mm	46.1 ± 3.4	44.1 ± 2.3	0.001*
LAFH	mm	59.1 ± 2.7	57.1 ± 2.3	0.001*
GPI	%	7.6 ± 1.5	6.1 ± 0.6	0.001*
ULTc	%	120.7 ± 2.5	103.5 ± 3.6	0.001*
AfhPfh	mm	127.9 ± 2.8	125.4 ± 3.1	0.001*

Test applied: t -test, *indicates statistical significance at $p < 0.05$.

Table 5 Comparison of mean angular and linear measurements of cephalometric variables according to age group.

Variables	Units	Age group (years) (Mean ± SD)					p-value
		≤8.5	8.6–10.5	10.6–12.5	12.6–14.5	≥14.6	
GM–SN	degree	93.4 ± 4.2	86.9 ± 6.7	96.6 ± 1.9	97.7 ± 2.4	99.9 ± 1.9	0.001*
GM–FH	degree	101.6 ± 3.3	97.8 ± 3.5	105 ± 2.3	106 ± 1.4	106.4 ± 1.6	0.001*
GM–BaN	degree	74.5 ± 2.9	71.6 ± 2.2	78.4 ± 1.8	78.6 ± 2.2	80.1 ± 1.6	0.001*
G–Sg–M	degree	157.1 ± 3.6	161.9 ± 2.5	162 ± 1.9	164.4 ± 1.5	165.3 ± 2.6	0.001*
IOP–SN	degree	97.5 ± 5.7	87.5 ± 4.2	97.5 ± 2.2	98 ± 0.9	99.4 ± 2.7	0.001*
IOP–FH	degree	107.7 ± 2.9	102.2 ± 6	104 ± 1.8	106.3 ± 0.7	106.6 ± 2.2	0.001*
IOP–BaN	degree	80.3 ± 3.1	77.2 ± 5.2	76.8 ± 1.8	77.7 ± 2.2	80.8 ± 2.1	0.001*
O–I–Op	degree	132.1 ± 3.9	127.9 ± 7.4	131.1 ± 2.7	131.6 ± 2.5	130.7 ± 0.7	0.001*
Sg–GM	mm	4.2 ± 0.9	3.2 ± 0.6	2.9 ± 0.6	2.6 ± 1.7	2.8 ± 0.4	0.001*
G–SgN	mm	1.7 ± 0.3	1.7 ± 0.3	2.1 ± 0.3	2.2 ± 0.3	2.7 ± 0.6	0.001*
FSHt	mm	16.8 ± 1.4	16.9 ± 1.2	20.4 ± 1.4	23.1 ± 1.3	24.4 ± 1.9	0.001*
FSWd	mm	5.1 ± 0.5	6.1 ± 0.5	6.7 ± 0.6	7.2 ± 0.5	7.7 ± 1.1	0.001*
I–OpO	mm	17.3 ± 0.9	17.1 ± 1.2	17.5 ± 1	17.7 ± 0.5	17.4 ± 0.7	0.001*
Ma–SN	mm	29.9 ± 1.3	30.1 ± 1.2	30.9 ± 1.8	30.1 ± 1.4	33.2 ± 1.7	0.001*
Ma–FH	mm	19.8 ± 0.7	20.1 ± 1.1	19.1 ± 1	20.9 ± 0.8	21.4 ± 1.1	0.001*
MaHt	mm	4.5 ± 0.8	5.4 ± 0.4	5.7 ± 0.6	5.3 ± 0.4	5.4 ± 0.4	0.001*
MaWd	mm	14.5 ± 0.8	15.5 ± 0.5	14.7 ± 0.8	14.6 ± 0.7	15.1 ± 1.7	0.001*
UL	mm	11 ± 0.9	11.8 ± 0.8	12.1 ± 0.6	12.4 ± 0.9	11.7 ± 0.7	0.001*
Tc	mm	9.7 ± 0.8	10.5 ± 0.6	10.9 ± 0.5	11.1 ± 0.6	10.5 ± 0.7	0.001*
Pfh	mm	42.5 ± 1.4	43.1 ± 1.3	44.1 ± 1.8	46.4 ± 1.4	50.9 ± 1.9	0.001*
LAFH	mm	54.7 ± 2.4	56.1 ± 2	58.3 ± 1.4	58.9 ± 1.8	62.2 ± 1	0.001*
GPI	%	5.5 ± 1.1	6.4 ± 0.2	6.5 ± 0.3	7.4 ± 1.3	9.1 ± 1.8	0.001*
ULTc	%	117.4 ± 10.7	115.3 ± 8.9	113.6 ± 7.2	112.5 ± 7.9	114.5 ± 11.3	0.006*
AfhPfh	mm	126.9 ± 2.8	128.3 ± 2.9	128.3 ± 2.8	125 ± 2.7	125.1 ± 2.3	0.001*

Test applied: one way ANOVA, *indicates statistical significance at $p < 0.05$.

Table 6 Standardized canonical discriminant function coefficients.

Cephalometric variables	Function 1
GM–FH	.190
IOP–SN	–.297
O–I–Op	.152
FSHt	.546
FSWd	.145
I–OpO	.266
Ma–SN	.253
Ma–FH	.281
Tc	–.208
LAFH	.184
GPI	–.421
ULTc	1.130
AfhPfh	.216

$$D = -75.84 + 0.49 (GMFH) - 0.058 (IOPSN) + 0.042 (OIOp) + 0.185 (FSHt) + 0.156 (FSWd) + 0.344 (IOPo) + 0.148 (MaSN) + 0.216 (MaFH) - 0.29 (Tc) + 0.071 (LAFH) - 0.327 (GPI) + 0.376 (ULTc) + 0.073 (AfhPfh).$$

inter-observer discrepancy. Radiographs in this regard afford a more accurate, simple and explicit technique for sex determination by linear and angular measurements and also aid in reducing the inter-observer bias as documented by Hsiao et al. (2010) and (Devang Divakar et al., 2015). Radiographic methods like cephalometry, which is based on measurements and morphometry are more precise and can be used conse-

Table 7 Functions at group centroids.

Sex	Function 1
Male	2.917
Female	– 4.801

Unstandardized canonical discriminant functions evaluated at group means.

Table 8 Accuracy of discriminant function in sex determination.

	Sex	Predicted Group Membership n (%)		Total
		Male	Female	
Original n (%)	Male	380 (100)	0	380 (100)
	Female	0	236 (100)	236 (100)

100% of original grouped cases correctly classified.

quently in the assessment of sex using skulls (Naikmasur et al., 2010).

In 1931, Broadbent and Hofrath introduced radiographic cephalometry to aid in the diagnosis of skeletal and dental patterns in Orthodontics. This innovative practice had played very important aspect in appreciating pathology and anatomy of the skeleton as they can afford architectural and morphological minutiae thus illuminating supplementary traits and

various points for correlation (Devang Divakar et al., 2015). It also has the benefit of being measurable by the productive method of discriminant analysis. An imperative requirement of precise identification of sex in a skeleton is, knowledge about their racial origin so that the highest signifying cephalometric variables can be measured (Hsiao et al., 2010). Cephalometric radiographs are not only used by orthodontists but has been captured the attention of anthropologists for sex determination of adult and adolescent population (Sprowl, 2013).

Based on the morphological or anthropometric analysis, accuracy of determining the sex of the skull ranges from 77 to 92%. The precision of determination rely upon the features that are present on the skull and their condition (Devang Divakar et al., 2015; Badam et al., 2011; Kamath et al., 2015; Wankhede et al., 2015). The veracity of determination of gender by means of pelvic bone alone, stated to be 90–100% accurate, which in turn made it as the most chosen bone for gender identification (Badam et al., 2011). Next to pelvis other skeletal elements which show near accurate results are the skull, thorax, vertebrae, femur and scapula (Devang Divakar et al., 2015). In Juveniles, the craniofacial bones attain maturity early in life and thus serve as the most excellent source for gender identification. Various authors namely Hsiao et al., Patil and Mody and Veyre-Goulet et al., in their research have confided upon cephalograms to establish discriminant functions for craniofacial sex determination (Gonzalez, 2012). Discriminant analysis is utilized to categorize individuals into two or more different groups with reference to sets or measurements. This method can also be used to recognize the variables responsible for making the categorization (Badam et al., 2011). This technique overcomes several problems ingrained in instinctive procedures of sexing skulls, implementing a reasonably clear, objective method of sexing material with a computable accuracy (Mathur et al., 2014) and helps as an objective statistical procedure for determination of sex (Badam et al., 2011).

According to some authors, craniofacial growth feature between the two sexes is basically similar, but sexual dimorphism detected is the consequence of initial accomplishment of skeletal maturity in females than males (Binnal and Yashoda Devi, 2012). Hsiao et al., put a new method for sex determination using lateral cephalometric radiographs and discriminant function analysis from the skull. Sex was determined with 100% precision attained in an arbitrary sample of hundred Taiwanese adults deriving eighteen cephalometric variables by means of discriminant function (Mathur et al., 2014) showing correlation and similar results with our study. A study conducted by Patil and Mody by means of discriminant function yielded 99% accuracy with 10 cephalometric measurements. In another study by Veyre-Goulet et al. in 2008 inferred 95.6% certainty in 114 samples with discriminant function obtained from 18 cephalometric variables. By these studies, we can definitely conclude that the technique used for sexing the skull by means of lateral cephalograms with discriminant function analysis appears appropriate forever, although the main analytic variables fluctuate concerning the relative ethnicity (Mathur et al., 2014).

Evaluation of skeletal landmarks through metric analysis had also been conducted, in which mastoid process of one hundred and thirty-five adult skulls with the age ranging from 25 to 65 were calculated from the upper zygomatic arch to the mastoid tip with the help of sliding calliper. Direct and step-

wise discriminant function analyses were utilized to examine the calculated measurements and their study showed that sex could be determined with 87% accuracy. Investigators also noticed that asterion to mastoidale being the most productive measurement exhibited 75.4% accuracy (Sprowl, 2013).

Several studies were conducted to differentiate sex using adult skeletal components, but only a few studies have been tried to compare the cephalometric values among children and adolescents. Earlier researchers assumed that sexual dimorphism does not subsist until puberty. Using size and shape of the mandible, pogonion, glabella, and supraorbital region sex determination were much easier. But within a few years researchers discovered that in the preadolescent group existence of sexual dimorphism is seen in the silhouette of the craniofacial complex (Sprowl, 2013; Kamath et al., 2015; Wankhede et al., 2015). The outcome of our study supports the former hypothesis of sexual dimorphism in preadolescence, even though sexually dimorphic features are not as obvious until puberty. Our study displays that determination of sexual dimorphism can be done using statistical significance in the preadolescent 'ages ranging from 6.5 to 18 years.

Gonzalez in 2010 performed a lateral cephalometric study of Europeans aged 5–16 to evaluate sexual dimorphism. Totally 83 lateral cephalograms out of which 47 male and 36 female cephalograms were hand traced and later transformed into a cross-sectional sample of 598 subjects by adding twenty-five male and twenty-five female cephalograms in every age group. Using backward stepwise and canonical discriminant function analysis of twenty variables gave 87.3% accuracy in identification of sex. This research implied that sexual dimorphism already existed at the same time when craniofacial growth was achieved as early as around the age of six years, which was also noted in our study. Further progress of these features is due to the craniofacial characteristics that are particular to each sex (Sprowl, 2013).

The inferred discriminant functional equation in the current study was 100% precise in discriminating male and female groups. In 2005, Franklin et al., used 8 cephalometric variables and claimed an accuracy of 77 to 80% in sex determination. Another study conducted by Naikmasur et al., in 2010 used 11 variables and gave a result of 81.5% and 88.2% accuracy correspondingly by correlating the dependability of cranio-mandibular parameters in South Indian and Indian immigrants of Tibetan populations. The discrepancy in the results of various studies may be elucidated due to the differing number of parameters in sex determination (Binnal and Yashoda Devi, 2012). Study conducted by Sumati et al., using 4 variables of mastoid process showed 76.6% accuracy with stepwise discriminant function analysis, in which length of the mastoid was found to be highly significant which alone gave an accuracy of 66.7% (Ali and Al-Nakib, 2013). Due to the anatomical position and the compact nature of the mastoid process it is highly resistant to damage and is considered to be a favorable landmark for sex determination (Binnal and Yashoda Devi, 2012).

In this present study, 24 cephalometric measurements were used in discriminant function analysis and they yielded excellent sex discrimination in the subjects of known sex. All variables listed in Table 2 were examined and a stepwise discriminant function was conducted to decide the most significant variables contributing to gender determination. In this study, men showed significantly larger measurements for all

linear skeletal parameters and angular parameters at $p < 0.05$. Out of 24 variables, only ULTc predicts the gender.

The consequence of this study corroborates previous theories of sexual dimorphism of the human craniofacial skeleton in preadolescence. The study concluded showing that the skull of human displays anatomic variation between males and females. The discriminant function analysis resulted in 100% discrimination of gender with 100% females and 100% males correctly identified. Even though, sexually dimorphic traits are not as evident in the skeleton until after the onset of puberty, this study shows that sexual dimorphism can be determined with statistical significance in the preadolescent, this may be due to the different genetic and environmental makeup of this Indigenous groups. The final outcome of this study validates the existence of sexual dimorphism in the skeleton as early as 6.5 years of age. There is a need for further research to determine other landmarks that can help in sex determination and norms for Indigenous (Kuruba) population and also other Indigenous groups of Coorg, Karnataka, India.

5. Conclusion

In conclusion, the results obtained from this study shows that sexual dimorphism can be determined in pre and post-adolescents by means of discriminant function analysis. The need for quick and precise forensic methods in the investigation of semi-decomposed and fragmented human remains is increasing which necessitates developing an accurate method for identification of sex. As the skeletal complex of the human is affected by a number of environmental factors, specific standards of assessment must be drawn and applied to a particular population under consideration. The findings of the present study confirm the role of lateral cephalograms and the 24 cephalometric parameters in the identification of sex. Further studies should be conducted to evaluate discriminant method on different populations with a diverse age group to confirm its reliability. The derived discriminant function equation can be useful in the identification of the sex of human remains pertaining to Indigenous (Kuruba) population of Coorg, Karnataka, India. Our results will, therefore, be useful among both genders in forensic dentistry for identification purposes.

The authors would like to express their appreciation to the Pacific Academy of Higher Education & Research University, Post Graduate Studies and Udaipur, India.

Acknowledgement

The project was financially supported by King Saud University, Vice Deanship of Research Chairs Kingdom of Saudi Arabia, Riyadh.

References

- Ali, Aysar Razzaq, Al-Nakib, L.H., 2013. The value of lateral cephalometric image in sex identification. *J. Baghdad Coll. Dent.* 25 (2), 54–58.
- Badam, Raj Kumar, Manjunath, M., Rani, M.S., 2011. Determination of sex by discriminant function analysis of lateral radiographic cephalometry. *J. Indian Acad. Oral Med. Radiol.* 23 (3), 179–183.
- Binnal, Almas, Yashoda Devi, B., 2012. Identification of sex using lateral cephalogram: role of cephalofacial parameters. *J. Indian Acad. Oral Med. Radiol.* 24 (4), 280–283.
- Chandra Shekar, B.R., Reddy, C.V., 2009. Role of dentist in person identification. *Indian J. Dent. Res.* 20 (3), 356–360. <http://dx.doi.org/10.4103/0970-9290.57377>.
- Devang Divakar, Darshan, John, J., Al Kheraif, A.A., Ramakrishnaiah, Ravi Kumar, Mavinapalla, Seema, Alshahrani, Obaid Abdullah, 2015. Cranio-mandibular parameters of lateral cephalometric radiograph to determine sex in forensic investigations: an electronic search study. In: *Anthropologist* 21 (1,2), 98–104.
- Francesquini, Junior L., Francesquini, M.A., De La Cruz, B.M., Pereira, S.D., Ambrosano, G.M., Barbosa, C.M., Daruge, E., 2007. Identification of sex using cranial base measurements. *J. Forensic Odontostomatol.* 25 (1), 7–11.
- Gonzalez, R.A., 2012. Determination of sex from juvenile crania by means of discriminant function analysis. *J. Forensic Sci.* 57 (1), 24–34. <http://dx.doi.org/10.1111/j.1556-4029.2011.01920.x>.
- Hsiao, Tin-Hsin, Tsai, S.-M., Chou, Szu-Ting, Pan, Jing-Yun, Tseng, Yu-Chuan, Chang, Hong-Po, Chen, Hong-Sen, 2010. Sex determination using discriminant function analysis in children and adolescents: a lateral cephalometric study. *Int. J. Legal Med.* 124, 155–160.
- İşcan, M.Y., 2005. Forensic anthropology of sex and body size. *Forensic Sci. Int.* 147 (2), 107–112. <http://dx.doi.org/10.1016/j.forsciint.2004.09.069>.
- Kamath, Venkatesh Gokuldas, Radhakrishna Shetty, M.A., Avadhani, Ramakrishna, 2015. Binary logistic regression analysis of foramen magnum dimensions for sex determination. *Anat. Res. Int.*, 9.
- Kranioti, Elena.F., Garcia-Donas, J.G., Langstaff, H., 2014. Sex estimation of the Greek mandible with the aid of discriminant function analysis and posterior probabilities. *Rom. J. Legal Med.* 22, 101–104.
- Mahesh Kumar, Lone, M.M., Patnaik, V., 2013. Determination of sex by discriminant function analysis: a cephalometric study. *Int. J. Pure Appl. Biosci.* 1 (4), 18–21.
- Mathur, Ruchi U., Mahajan, A.M., Dandekar, Rishikesh C., Patil, Rahul B., 2014. Determination of sex using discriminant function analysis in young adults of Nashik: a lateral cephalometric study. *J. Adv. Med. Dent. Sci.* 2 (1), 21–25.
- Naikmasur, V.G., Shrivastava, R., Mutalik, S., 2010. Determination of sex in South Indians and immigrant Tibetans from cephalometric analysis and discriminant functions. In: *Forensic Sci. Int.* 197 (1–3). <http://dx.doi.org/10.1016/j.forsciint.2009.12.052>, 122 e121–126.
- Patil, K.R., Mody, R.N., 2005. Determination of sex by discriminant function analysis and stature by regression analysis: a lateral cephalometric study. *Forensic Sci. Int.* 147 (2–3), 175–180. <http://dx.doi.org/10.1016/j.forsciint.2004.09.071>.
- Sprowl, A.E., 2013. Sex Determination Using Discriminant Function Analysis in Hispanic Children and Adolescents: A Lateral Cephalometric Study (Master of Science). University of Nevada, Las Vegas.
- Wankhede, K.P., Bardale, R.V., Chaudhari, G.R., Kamdi, N.Y., 2015. Determination of sex by discriminant function analysis of mandibles from a Central Indian population. *J. Forensic Dent. Sci.* 7 (1), 37–43. <http://dx.doi.org/10.4103/0975-1475.150304>.