

Oncology

Bladder Contracture – A Rare and Serious Side Effect of Intravesical Bacillus Calmette-Guérin Therapy

Cindy Garcia^{*,1}, Hamesh Jina, Philip Bergersen, Venu Chalasani

Department of Urology, Hornsby Hospital, Palmerston Rd, Hornsby, NSW 2077, Australia

ARTICLE INFO

Article history:

Received 30 September 2015

Accepted 7 October 2015

Keywords:

Bladder cancer

Side effect

BCG

Contracture

ABSTRACT

Instillation of intravesical bacillus Calmette-Guérin (BCG) is an effective treatment for non-muscle invasive bladder cancer (NMIBC). The high incidence of side effects may limit its tolerability in patients. Local side effects including cystitis and hematuria are common but generally self-limiting. Bladder contractures are a rare but serious consequence of BCG treatment. In this case, an 82 year-old male developed BCG reactivation and subsequent bladder contractures following transurethral resection of the prostate (TURP) three years post-BCG. To our knowledge, this is the first reported case of BCG reactivation post-TURP leading to the rare but serious effect of bladder contractures.

© 2016 The Authors. Published by Elsevier Inc. This is an open access article under the CC BY-NC-ND license (<http://creativecommons.org/licenses/by-nc-nd/4.0/>).

Introduction

Bladder cancer is a common malignancy and is confined to the mucosa or submucosa in 75% of cases.¹ It is treated with a combination of transurethral resection (TUR) and adjuvant intravesical chemotherapy or BCG immunotherapy. Intravesical BCG is an effective treatment for NMIBC compared to TUR and intravesical chemotherapy, or TUR alone, and has been shown to prevent cancer recurrence, and may even delay tumor progression.¹ BCG therapy is associated with a high incidence of side effects that commonly occur during induction or the first 6 months of maintenance treatment.² Serious adverse effects occur in the minority of patients with the incidence of bladder contractures being less than 1%.³

Case presentation

In October 2007, an 82 year-old male presented for investigation of painless macroscopic hematuria on a background of BPH and emphysema. Initial investigations included urine cytology, urine culture, TRUS and CT of the abdomen and pelvis. Laboratory investigations were unremarkable, while imaging results demonstrated an enlarged prostate measuring 130 cc. Diagnostic cystoscopy conducted in the same month demonstrated a lesion on

the right bladder wall that was resected. Histology showed a high-grade papillary bladder cancer. His repeat cystoscopy 6 weeks later was clear.

On surveillance cystoscopy 6 months later, an area of erythema suggestive of carcinoma-in-situ (CIS) near the right ureteric orifice was noted and resected; this was confirmed on histology. Given his tumor profile, the patient was commenced on a 6-weeks course of induction BCG therapy in March 2008. The patient completed six rounds of induction intravesical BCG therapy that was well tolerated. No maintenance therapy was given.

The patient underwent TURP in July 2008, following an episode of urinary retention in conjunction with a history of obstructive voiding symptoms. At the time of the TURP, the bladder looked macroscopically normal with a good capacity and no sign of contractions. The histology of the prostate specimen showed nodular hyperplasia of the prostate in addition to granulomatous inflammation indicative of the BCG effect. Serial surveillance cystoscopies and urine cytology were clear.

By late 2010, almost 3 years following BCG therapy, the patient began experiencing issues with nocturnal frequency and incontinence. Urine cultures taken were positive for mycobacteria. A repeat cystoscopy showed marked inflammatory changes within the bladder, with associated thickened bladder mucosa; biopsies taken at the time confirmed BCG cystitis. The patient was commenced on a course of oral Rifampicin, Isoniazid and Pyridoxine in standard doses for a total of 9 months for reactivation of BCG.

Ongoing daytime frequency and urge incontinence prompted repeat urine cultures that grew *Klebsiella oxytoca* and was

* Corresponding author. Tel.: +61 02 9926 7111.

E-mail address: cindyjc.garcia@gmail.com (C. Garcia).

¹ Present address: Royal North Shore Hospital, Reserve Rd, St Leonards, NSW 2065, Australia.

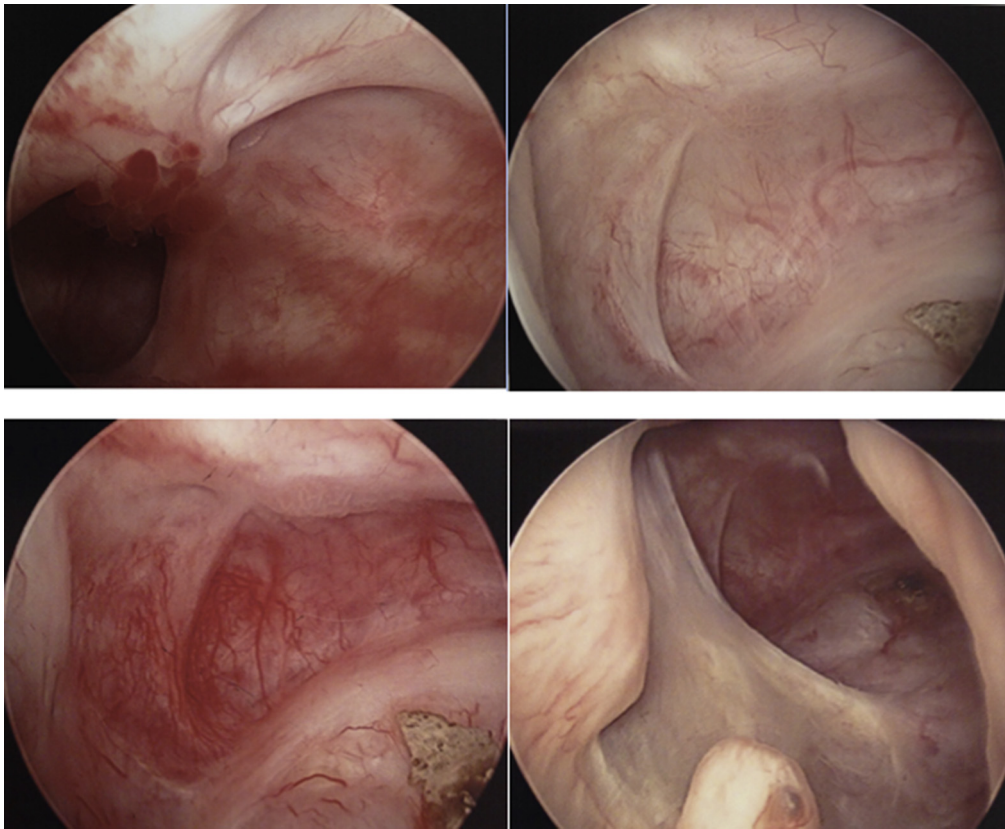


Figure 1. Follow-up cystoscopy in 2012 in which there was no bladder cancer recurrence, but evidence of bladder wall irregularity and inflammation. The bladder demonstrated evidence of fibrosis and poor contractility.

appropriately treated based on sensitivities. In spite of appropriate antibiotic treatment, the patient's symptoms persisted. Further investigation with a CT abdomen and pelvis in September 2011 demonstrated marked mural thickening of the bladder with bilateral hydro-ureter and hydronephrosis. Check cystoscopy in the same month showed significant improvement in the inflammation, however, some areas of bullous edema persisted. Biopsies taken at the time revealed congestion and inflammatory cell infiltrate, but no evidence of malignancy. Additionally, repeat urine cultures were negative for *Mycobacterium bovis* BCG but did show a small number

of atypical cells that were considered to be reactive in nature. The patient was advised to undertake bladder training, wear a urodome and was commenced on solifenacin succinate.

Repeat urine cultures following the completion of tuberculosis treatment were all negative for *M. bovis*, suggesting successful treatment of his BCG reactivation. However, his symptoms of frequency and urge incontinence persisted despite medication and behavioral therapy. Subsequent surveillance cystoscopy showed no cancer recurrence, but did demonstrate bladder irregularity with multiple septae, diverticuli and evidence of contractures.

Over the next 2 years continued surveillance did not identify a recurrence of bladder cancer, though the bladder remained fibrotic and poorly contractile. The patient was not a candidate for surgery due to his anesthetic risk, thus his ongoing incontinence was managed with incontinence pads and urodomes indefinitely (Figs. 1 and 2).

Discussion

The most common side effects of intravesical BCG treatment are local and transient. As demonstrated in the EORTC Genito-Urinary Cancers Group Randomized Phase 3 Study, local side effects occur in 62.8% of patients with the most common being chemical cystitis (35.0%), frequency (23.6%), bacterial cystitis (23.3%), and macroscopic hematuria (22.6%).⁴ Systemic side effects reported included malaise (15.5%) and fever (8.1%). Though side effects are a common occurrence, a reduction in dose or the duration of maintenance therapy does not significantly decrease the incidence of side effects.⁴

Granulomatous prostatitis is another common effect of BCG treatment, caused by mycobacterium contaminated urine. Most

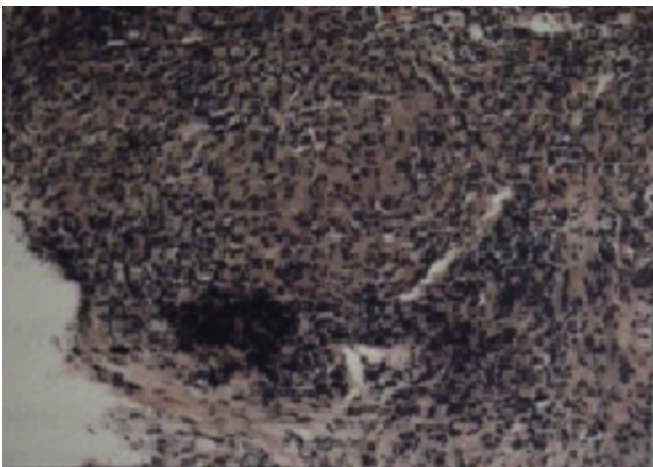


Figure 2. Bladder biopsy demonstrating inflamed stromal tissue with dense chronic and granulomatous inflammatory infiltrate.

patients will be asymptomatic with 5% requiring treatment with Isoniazid, Rifampicin and fluoroquinolones.² While transient local side effects may be managed symptomatically, more serious adverse effects such as bladder contractures can result in permanent incontinence, as in this case. BCG-associated bladder contractures are rare and tend to be associated with maintenance therapy and multiple TURBTs.² Published cases of bladder contractures post-BCG treatment evidence that this side effect tends to occur early in the induction phase of treatment.⁵

In our case, the reactivation of BCG with resultant granulomatous prostatitis and bladder contracture occurred 3 years post-induction BCG; the patient had not received maintenance BCG. Further, treatment was initiated at least 2 weeks post-resection in order to minimize the risk of mycobacterium absorption, in accordance with the International Bladder Cancer Group's recommendations.² This case highlights the need for increased vigilance regarding rare BCG-related adverse effects beyond the induction period, and in the absence of risk factors.

The incidence of adverse effects may be prevented through correct catheterization technique, deferral of treatment following traumatic catheterization or UTI, use of Ofloxacin, and dose reduction in patients with demonstrated intolerance. Prompt recognition of serious adverse effects requires early consultation with an infectious disease specialist, and appropriate antibiotic treatment. In this case, the consequences of the BCG reactivation led to a fibrotic, poorly compliant bladder with persistent frequency and permanent incontinence. Surgical treatment options were limited in this patient were due to his anesthetic risk.

This case demonstrates the need for increased awareness of BCG reactivation in patients undergoing TURP post-BCG. Furthermore, vigilant monitoring of potential adverse effects is required beyond the induction phase of treatment, as is demonstrated in this case of delayed BCG reactivation. The consequences of BCG reactivation are

particularly dire in patients for whom surgical treatment options are limited.

Conclusion

Delayed reactivation of BCG following TURP is not a well-described phenomenon. The bladder contractures that may result, however, can have devastating consequences for the patient. Though the true risk of such events is difficult to predict, the possibility of their occurrence and the consequences should be considered and discussed with patients.

Consent

Consent for the construction and publication of this case reports was obtained from the patient prior to submission.

Conflict of interest statement

The authors of this case have no conflicts of interest to declare.

References

1. Babjuk M, Burger M, Zigeuner R, et al. EAU guidelines on non-muscle-invasive urothelial carcinoma of the bladder: update 2013. *Eur Urol.* 2013;64(4):639–653.
2. Witjes JA, Palou J, Soloway M, et al. Clinical practice recommendations for the prevention and management of intravesical therapy-associated adverse events. *Eur Urol Suppl.* 2008;7(10):667–674.
3. Koya MP, Simon MA, Soloway MS. Complications of intravesical therapy for urothelial cancer of the bladder. *J Urol.* 2006;175(6):2004–2010.
4. Brausi M, Oddens J, Sylvester R, et al. Side effects of Bacillus Calmette-Guérin (BCG) in the treatment of intermediate-and high-risk Ta, T1 papillary carcinoma of the bladder: results of the EORTC genito-urinary cancers group randomised phase 3 study comparing one-third dose with full dose and 1 year with 3 years of maintenance BCG. *Eur Urol.* 2014;65(1):69–76.
5. Nieder AM, Sved PD, Stein JP, et al. Cystoprostatectomy and orthotopic ileal neobladder reconstruction for management of bacille Calmette Guérin-induced bladder contractures. *Urology.* 2005;65(5):909–912.