



Technical note

A novel minimally invasive technique for removal of a bent femoral intramedullary nail

Apipop Kritsaneephaiboon*, Boonsin Tangtrakulwanich, Korakot Maliwankul

Department of Orthopaedic Surgery and Physical Medicine, Faculty of Medicine, Prince of Songkla University, Songkhla 90110, Thailand

1. Introduction

Intramedullary (IM) nailing is considered as the gold standard and preferred method for fixation of femoral shaft fractures because of the high rate of fracture union and low incidence of complications.^{21,22} The rate of removal of IM nails is low,⁹ and it can be a challenging procedure, especially when the nail is bent or broken.^{1,7,17–19} Furthermore, it is more complicated to remove a bent nail than a broken one because it is difficult to pass a bent nail through the IM canal.^{10,17}

Several case reports have been published regarding different techniques for the removal of a bent femoral IM nail.^{2–6,8,10–20} Most of these techniques require fracture exposure and a special cutting instrument for bone dissection or nail resection. Therefore, the potential complications from these procedures such as soft tissue damage, thermal necrosis or metal debris may affect fracture healing.

Herein, we present a novel, minimally invasive technique to remove a bent femoral nail without opening the fracture, bone resection or nail cutting in one patient.

2. Case presentation

One month following an antegrade femoral IM nailing for a Gustilo type I open fracture of the midshaft of the right femur, a 19-year-old man slipped during a rainstorm and consequently had severe pain and deformity of his right thigh where the nail had been inserted (Fig. 1). There were no other associated injuries such as an open wound or neurovascular injury.

A plain radiograph of his right thigh revealed anterolateral bending of the nail, and that the femoral shaft fracture was not completely united with some callus formation (Fig. 2A and B).

Nail removal and further internal fixation of the right femoral shaft fracture were indicated. The procedure was considered as urgent, and an operation was scheduled on the day of his arrival.

3. Surgical technique

Under general anaesthesia, the patient was placed in the supine position on a radiolucent operative table. Initially, closed manipulation of the bent IM nail and femoral deformity using the three-point manoeuvre as described by Patterson and Ramser¹⁶ was attempted, but failed. Then the patient's position was changed to the left lateral decubitus orientation on the fracture table, as in a routine procedure of femoral IM nailing.

First, two separate 2.5 cm skin incisions were made at the lateral aspects of the proximal and distal thigh (Fig. 3). Exposure of the lateral cortex of the proximal and distal femur was achieved by a transvastus lateralis approach.

A submuscular extraperiosteal tunnel was then created by passing a tunnelling instrument through the proximal to the distal

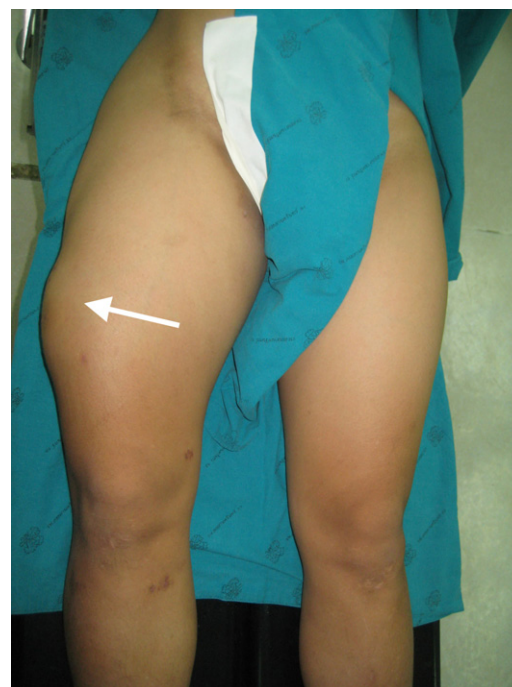


Fig. 1. The patient had marked swelling and deformity at his right thigh (arrow).

* Corresponding author. Tel.: +66 74 451601; fax: +66 74 429898.
E-mail address: kapipope@yahoo.com (A. Kritsaneephaiboon).

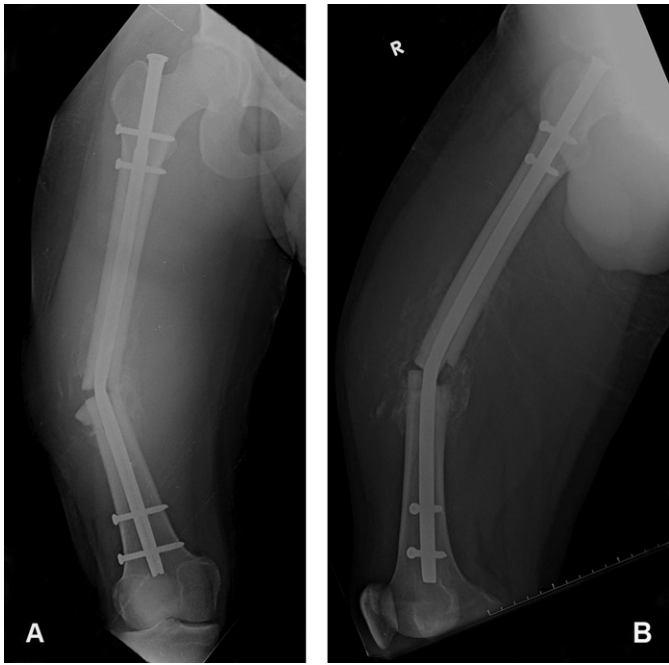


Fig. 2. Radiographs showing the bent IM nail with 30° varus angulation in an AP view (A) and 30° anterior angulation in a lateral view (B).

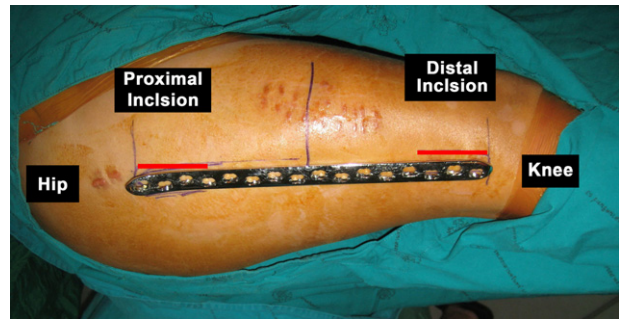


Fig. 3. The proximal and distal skin incisions (red lines).

incision. After preparation of the submuscular tunnel, a 16-hole reused broad locking plate (5.0 mm; Synthes GmbH, Oberdorf, Switzerland), which had been precontoured to fit the lateral aspect of the femur (plastic bone; Fig. 4A–C), was inserted from the

proximal to the distal incision following the track previously made by the tunnelling instrument (Fig. 5).

After the proper position of the plate was achieved by using an image intensifier, two locking screws were inserted to fix the plate with the proximal femur (Fig. 6A and B).

The next step was applying a collinear reduction clamp (Synthes GmbH, Oberdorf, Switzerland) at the distal incision to bring the distal femur into the contact with the distal part of plate (Fig. 7A and B). By tightening this reduction clamp, force was applied over the convexity of the bone and bent nail through the plate, and gradually increased until the deformity at femoral shaft was corrected and the bent nail was straightened, carefully managed under fluoroscopic control (Fig. 8A and B). Then distal plate fixation was performed by insertion of one locking screw distal to the tip of the nail, after which the collinear reduction clamp was removed. There was no additional fracture exposure, bone resection or nail destruction.

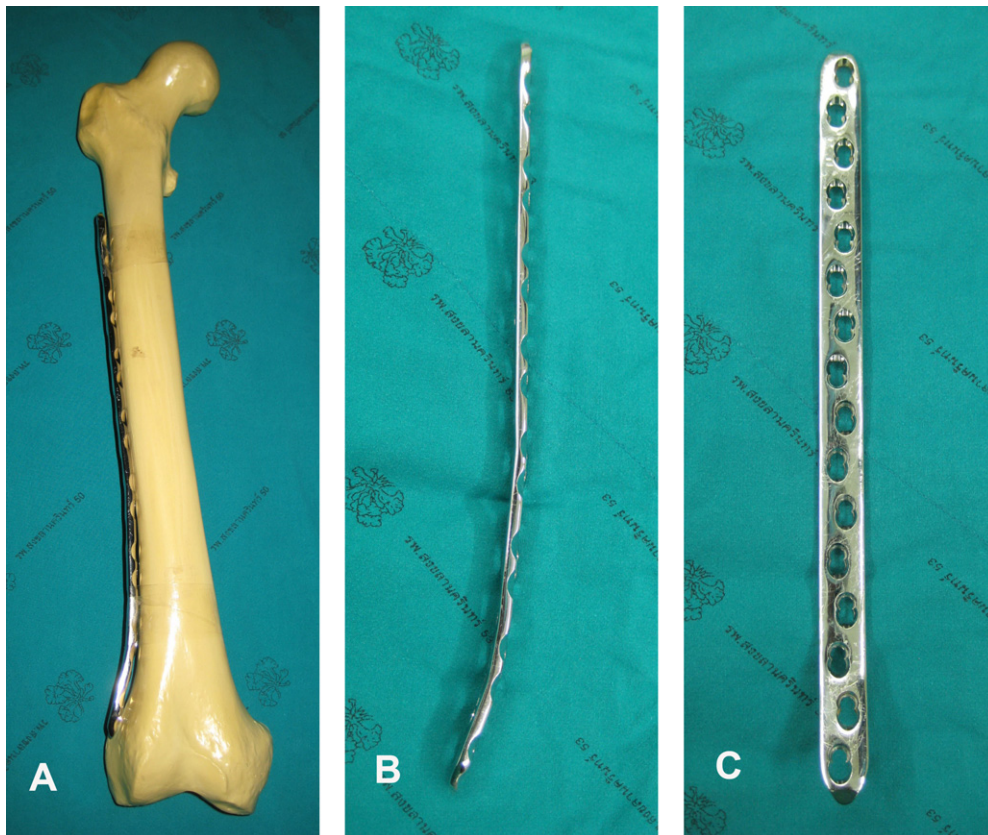


Fig. 4. The reused broad locking plate was contoured to the shape of the lateral aspect of the femur (plastic bone), (A). The precontoured locking plate in lateral and AP views (B and C).

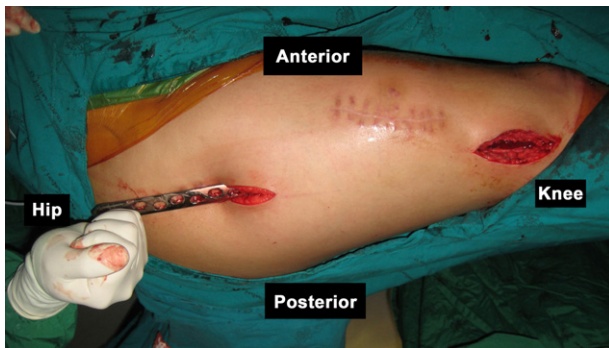

Fig. 5. The locking plate was inserted from the proximal to the distal incision.

The interlocking screws were removed and the bent nail was extracted smoothly through the original incision at the hip (Fig. 9). The femoral canal was then reamed to a circumference 2 mm greater than the diameter of the original nail, and a new nail, 1 mm larger in circumference than the original nail was inserted. After that the temporary locking plate and screws were removed.

Finally, four interlocking screws were inserted through the new nail as a static mode without bone grafting (Fig. 10A and B).

There were no complications post-operatively. Four months after the second surgery, fracture union was complete (Fig. 11A and B), and the patient had regained full range of motion of the hip and knee with normal gait (Fig. 11C and D).

4. Discussion

Bent nails commonly result following a secondary trauma, while the major causes of broken nails are nonunion, unstable or comminuted fractures and pathological fractures.⁵ Because a bent nail usually blocks the IM canal, extraction of a bent nail is more serious and difficult than the extraction of a broken nail.^{10,17}

Variable techniques have been proposed for the removal of a bent femoral IM nail.^{2–6,8,10–20} However, there is still no universally accepted method. Patterson and Ramser¹⁶ described in situ straightening of a bent nail through the application of external force on the femur, but this technique does not work in high-strength nails.² Opening the fracture site, complete cutting the nail and removing each piece separately has been also reported.^{11–13,18} Another approach has been to partially cut a nail

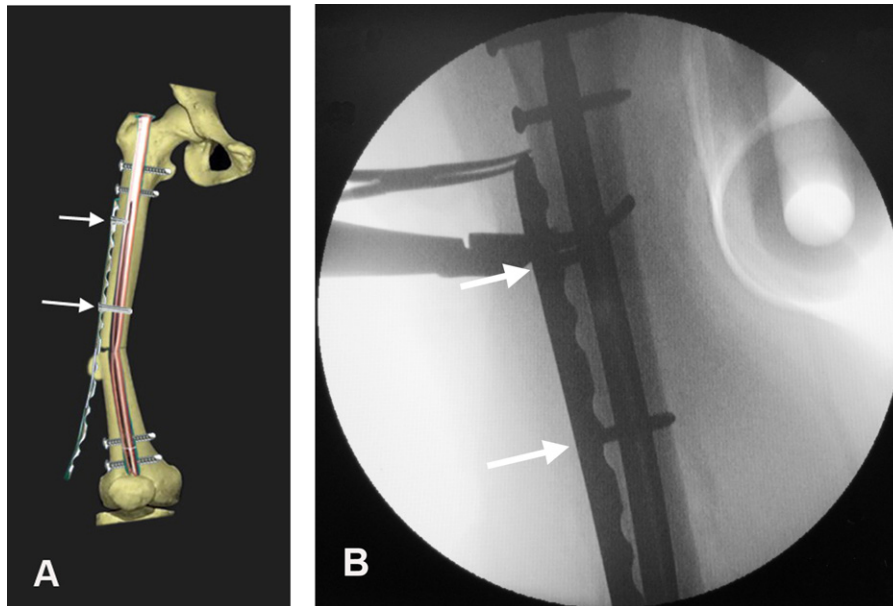


Fig. 6. The plate was fixed to the proximal femur with two locking screws (white arrows; A and B).

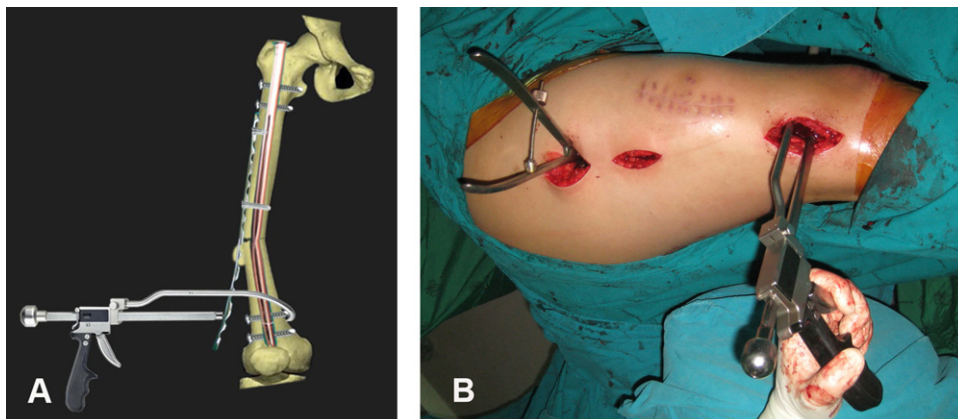


Fig. 7. A collinear reduction clamp was applied to hold the plate with the distal femur at the distal incision (A and B).

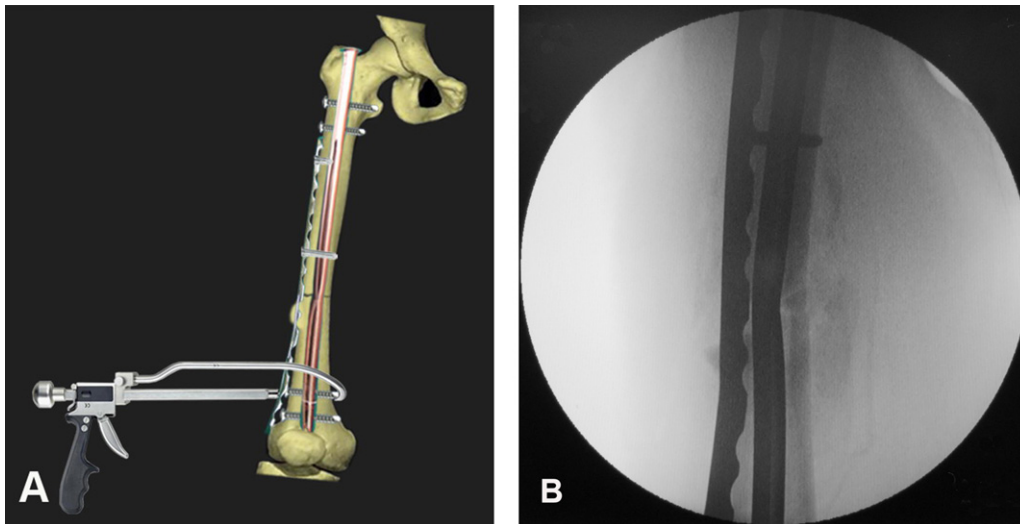


Fig. 8. The collinear reduction clamp was tightened to gradually reduce the femoral deformity and straighten the bent nail (A). There was 5° varus angulation after straightening the nail (B).

at the apex of the deformity after exposure of the fracture^{2,4–6,8,14,15,19} or using a percutaneous technique,³ straightening the nail through closed manipulation and then removing the nail as a single unit from the previous nail insertion incision. Most of these methods require opening the fracture and bone sectioning, which damage the surrounding soft tissue and may interfere with fracture healing.^{6,14,17,19} Soft tissue contamination from metal debris and thermal necrosis from nail resection by using the special cutting equipment are the major concern of these techniques.

In this study, we demonstrate a novel technique for removal of a bent femoral IM nail using the combination of a locking plate and a collinear reduction clamp. The advantage of this technique is that it is a minimally invasive procedure with no fracture exposure, no need for bone resection, no metal debris and no thermal necrosis from nail cutting. Furthermore, the collinear reduction clamp has a hook which is designed to pass around the bone with minimal disturbance to the soft tissue.

There was a low risk of iatrogenic fracture during the bent nail extraction from this technique because the plate and reduction clamp temporarily reduced the fracture. Furthermore,

the locking plate is an angular stable implant which allows the use of multiple unicortical locking screws at the proximal femur with the IM nail inside. Therefore, the nail exchange was an easy procedure because there was the temporary fixation of the locking plate without the obstruction from the unicortical locking screws.

Although the nail was straightened almost to the original shape in our case, the remaining deformity of the nail may still interfere




Fig. 9. The extracted nail still had a varus deformity.

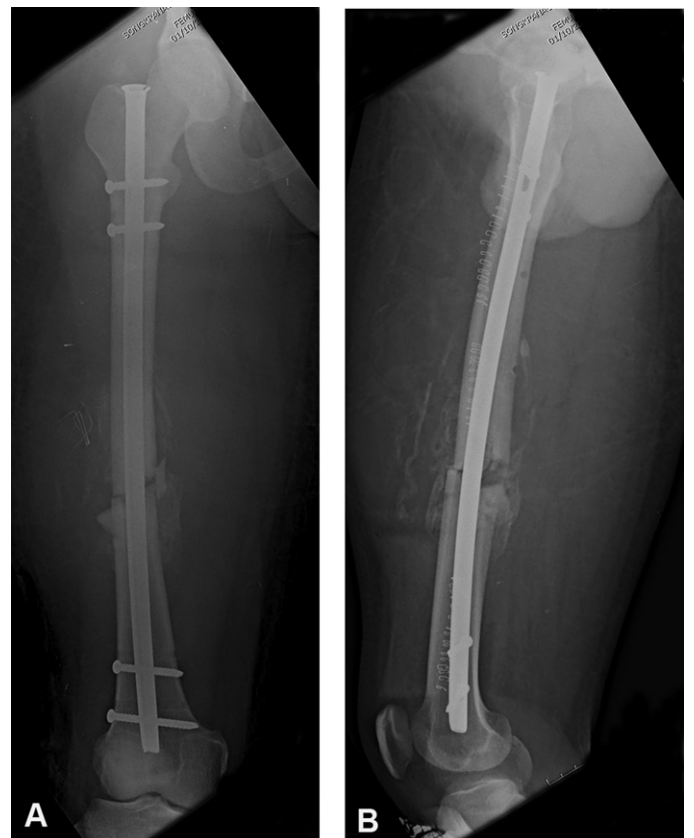

Fig. 10. Radiographs showing the exchanged nail without bone grafting (A and B).

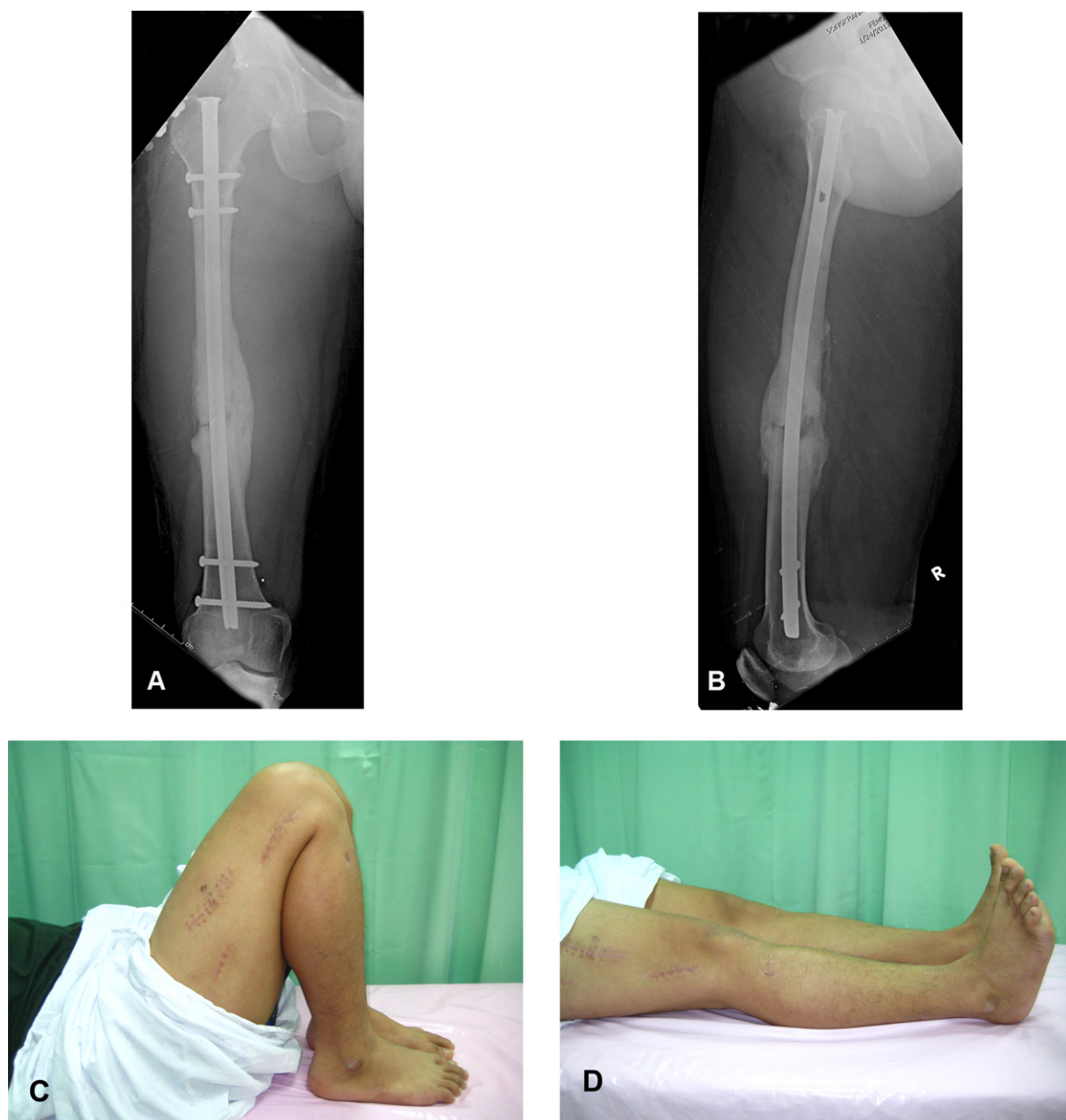

Fig. 11. Radiographs showing the complete healing of the femoral shaft fracture (A and B). The patient had a full range of motion of right hip, knee and ankle (C and D).

with the IM canal during nail extraction. Therefore, it is necessary to use an image-intensifier to check the position of the nail to avoid further iatrogenic fractures. Furthermore, the collinear reduction clamp we used is an expensive device which is not available in every hospital. However, another reduction clamp such as a bone-holding forceps¹⁷ or a Lane bone holding clamp which has enough power to straighten the bent nail may be used as an alternative instrument.

5. Conclusion

We propose a novel minimally invasive technique for removal of a bent femoral IM nail by using a locking plate and a collinear reduction clamp. This technique is a simple and effective method for straightening and then removing a bent nail without disruption of the fracture healing and minimal damage of the soft tissue.

Acknowledgments

The authors thank Suthorn Bavornratanavech, MD, of Bangkok Hospital, Bangkok, and Kanyika Chamniprasas, MD, of the Department of Orthopaedic Surgery and Physical Medicine, Faculty of Medicine, Prince of Songkla University, for their support.

References

1. Aggerwal S, Soni A, Saini UC, Gahlot N. Removal of a bent tibial intramedullary nail: a rare case report and review of the literature. *Chinese Journal of Traumatology* 2011;14:107–10.
2. Al Maleh AA, Nielsen KS. How to remove a bent intramedullary nail. A technical note. *Acta Orthopaedica Scandinavica* 1998;69:638–9.
3. Apivatthakakul T, Chiewchantanakit S. Percutaneous removal of a bent intramedullary nail. *Injury* 2001;32:725–6.
4. Banerjee R, Posner M. Removal of a bent intramedullary nail with a posttraumatic sagittal plane deformity. *Journal of Trauma* 2009;66:1500–3.

5. Bek D, Demiralp B, Tunay S, Sehirlioglu A, Atesalp AS. Removal of a bent inflatable femoral nail: a case report. *Acta Orthopaedica et Traumatologica Turcica* 2008;42:211–3.
6. Burzynski N, Scheid DK. A modified technique for removing a bent intramedullary nail minimizing bone and soft tissue dissection. *Journal of Orthopaedic Trauma* 1994;8:181–2.
7. Hak DJ, McElvany M. Removal of broken hardware. *Journal of the American Academy of Orthopaedic Surgeons* 2008;16:113–20.
8. Heffernan MJ, Leclair W, Li X. Use of the f-tool for the removal of a bent intramedullary femoral nail with a sagittal plane deformity. *Orthopedics* 2012;35:e438–41.
9. Hui C, Jorgensen I, Buckley R, Fick G. Incidence of intramedullary nail removal after femoral shaft fracture healing. *Canadian Journal of Surgery* 2007;50:13–8.
10. Kockesen TC, Tezer M, Tekkesin M, Kuzgun U. Traumatic femoral diaphyseal fracture and a bent intramedullary nail in a case with a completely healed femoral diaphyseal fracture. *Acta Orthopaedica et Traumatologica Turcica* 2002;36:177–80.
11. LaSalle WB, Horwitz T. A method to cut and remove in situ bent intramedullary nail. *Clinical Orthopaedics and Related Research* 1974;103:30–1.
12. Nicholson P, Rice J, Curtin J. Management of a refracture of the femoral shaft with a bent intramedullary nail in situ. *Injury* 1998;29:393–4.
13. Nicolaidis V, Polyzois V, Tzoutzopoulos A, Stavlas P, Grivas TB, Korres D. Bent femoral intramedullary nails: a report of two cases with need for urgent removal. *European Journal of Orthopaedic Surgery and Traumatology* 2004;14:188–91.
14. Ohtsuka H, Yokoyama K, Tonegawa M, Higashi K, Itoman M. Technique for removing a bent intramedullary femoral nail: a case report. *Journal of Orthopaedic Trauma* 2001;15:299–301.
15. Park J, Yang KH. Removal of a bent nail after refracture of the femoral shaft. *Injury* 2012;43:1209–11.
16. Patterson RH, Ramser Jr JR. Technique for treatment of a bent Russell–Taylor femoral nail. *Journal of Orthopaedic Trauma* 1991;5:506–8.
17. Shen PC, Chen JC, Huang PJ, Lu CC, Tien YC, Cheng YM. A novel technique to remove bent intramedullary nail. *Journal of Trauma* 2011;70:755–8.
18. Singh R, Sharma AK, Kiranpreet. An innovative technique to cut and extract loose bent Kuntscher nail. *Indian Journal of Medical Sciences* 2004;58:439–41.
19. Sonanis SV, Lampard AL, Kamat N, Shaikh MR, Beard DJ. A simple technique to remove a bent femoral intramedullary nail and broken interlocking screw. *Journal of Trauma* 2007;63:435–8.
20. Stahel PF, Flierl MA, Morgan SJ, Smith WR. Management of a trochanteric fracture complicated by a bent solid intramedullary femoral nail in situ: description of technique. *Journal of Orthopaedic Trauma* 2010;24:e25–30.
21. Winquist RA, Hansen ST, Clawson DK. Closed intramedullary nailing of femoral fractures: a report of five hundred and twenty cases. *Journal of Bone and Joint Surgery* 1984;66:529–39.
22. Wolinsky PR, McCarty E, Shyr Y, Johnson K. Reamed intramedullary nailing of the femur: 551 cases. *Journal of Trauma* 1999;46:392–9.