

Available online at www.sciencedirect.com

SciVerse ScienceDirect

Journal of the Chinese Medical Association 76 (2013) 31–36

www.jcma-online.com

Original Article

Transarterial detachable coil embolization of direct carotid-cavernous fistula: Immediate and long-term outcomes

Chao-Bao Luo^{a,b,c,*}, Michael Mu-Huo Teng^{a,b}, Feng-Chi Chang^{a,b}, Chung-Jung Lin^{a,b},
Wan-Yuo Guo^{a,b}, Cheng-Yen Chang^{a,b}

^a Department of Radiology, Taipei Veterans General Hospital, Taipei, Taiwan, ROC

^b Department of Radiology, National Yang-Ming University School of Medicine, Taipei, Taiwan, ROC

^c Department of Radiology, National Defense Medical Center, Taipei, Taiwan, ROC

Received February 15, 2012; accepted June 5, 2012

Abstract

Background: Transarterial embolization is a standard method for management of direct carotid-cavernous fistula (DCCF). The purpose of this study was to report our experiences, and immediate and long-term outcomes of endovascular embolization of DCCFs by using detachable coils (DCs).

Methods: Over 8 years, 24 patients with 25 DCCFs underwent endovascular DC embolization. There were 15 men and nine women; age ranged from 8 to 82 years (mean, 39 years). Immediate and long-term angiographic as well as clinical outcomes after endovascular DC embolization were retrospectively analyzed. The number and the length of DCs used to occlude the fistula were also evaluated.

Results: Eighteen DCCFs were successfully occluded by single-session endovascular embolization with preservation of the parent artery. Retreatments by transvenous ($n = 5$) and/ or transorbital routes ($n = 3$) had to be performed in seven patients because of residual fistula ($n = 4$) or recurrent fistula ($n = 4$) occurring within 3 weeks after embolization. The average numbers and length of coils to occlude the fistulas were 14 (range, 2–31) and 189 cm (range, 16–756 cm), respectively. Four patients had small residual fistulas with spontaneous thrombosis on follow-up angiography. Three patients had transient cranial nerve impairment of the third ($n = 1$) or sixth ($n = 2$) nerve. There was no significant procedure-related neurological complication. The follow-up period was 3–48 months (mean, 19 months).

Conclusion: Endovascular DC embolization of DCCFs was proved both efficacious and safe in managing high-flow fistulas with sustained angiographic and clinical effects, particularly in those DCCFs with small fistula track and/or cavernous sinus. However, retreatment via various routes may be necessary in some patients because of residual or recurrent fistulas.

Copyright © 2012 Elsevier Taiwan LLC and the Chinese Medical Association. All rights reserved.

Keywords: detachable coil; direct carotid-cavernous fistula; embolization; outcome

1. Introduction

Direct carotid-cavernous fistula (DCCF) is a high-flow arteriovenous fistula between the cavernous sinus (CS) and internal carotid artery (ICA). It commonly results from a traumatic tear or aneurysm rupture in the CS portion of the ICA. DCCFs usually present with ocular-orbital venous

congestion and cephalic bruit. The goal of treatment is to occlude the fistula with preservation of the ICA flow. In the past, transarterial balloon embolization of DCCFs was the standard method and had promising results.^{1–3} Due to lack of availability of detachable balloons, endovascular embolization using DC has become the mainstay for management of DCCFs. However, the immediate and long-term effect of DC for DCCFs has not been thoroughly evaluated.^{4–7}

The purpose of this study was to report our experience of endovascular DC embolization in 24 patients with 25 DCCFs and to evaluate the immediate and long-term effects of DC in managing DCCFs.

* Corresponding author. Dr. Chao-Bao Luo, Department of Radiology, Taipei Veterans General Hospital, 201, Section 2, Shih-Pai Road, Taipei 112, Taiwan, ROC.

E-mail address: cbluo@vghtpe.gov.tw (C.-B. Luo).

2. Methods

From October 2002 to September 2010, there were 24 patients with 25 DCCFs who were treated by endovascular DC embolization. This study was approved by Institutional Review board of Taipei Veterans General Hospital (IRB 201001003IA). The clinical data of the 24 patients are summarized in Table 1. These patients included 15 men and nine women, and their ages ranged from 8 to 82 years (mean 39 years). All patients had ocular–orbital venous congestive manifestations such as chemosis, bruit, and proptosis; three presented with headache, one experienced neurologic deficit because of intracerebral hemorrhage. Endovascular procedures of DCCFs were performed under general anesthesia using a femoral approach. Activated clotting time was maintained at a value of twice the baseline value by intravenous administration of heparin. A 6F or 7F guiding catheter was positioned in the cervical ICA, followed by navigation of microcatheter(s) to the CS. Occlusion of the DCCFs was initiated by selection of the proper DC; DCs were packed into the CS as densely as possible. The endpoint of the procedures was complete occlusion of the fistula flow ($n = 17$) or slow fistula flow with further coil embolization being impossible because of recoil of microcatheter into the parent artery ($n = 8$).

A postembolization angiogram was done immediately after the completion of the procedure to check for occlusion of the

fistula. Of these 25 DCCFs, 18 had follow-up with conventional and/or magnetic resonance angiography to evaluate the occluded fistula. All patients were followed-up clinically for an average of 19 months (range, 3–48 months).

3. Results

Results and follow-up findings are listed in Table 1. The average number and length of coils used were 14 (2–31) and 189 cm (16–756 cm), respectively, and largely depended on the size of the fistula tract and CS. Complete fistula closures were documented on immediate postembolization angiograms in 17 DCCFs (Fig. 1), whereas small residual flow remained in the other eight and spontaneous thrombosis was confirmed in four DCCFs by follow-up angiograms within 7 days. Retreatment was necessary in four persistent residual (Fig. 2) and four recurrent DCCFs (Figs. 2 and 3) occurring on Days 1, 2, 11 and 17, respectively, after embolization. All these eight recurrent and/or residual fistulas were found in 16 larger CSs that needed longer coils (>100 cm) to pack the CS and fistula. Conversely, nine small fistulas with small CSs embolized by less coil length (<100 cm) all were treated in a single session with fistula total occlusion demonstrated by postembolization or follow-up angiograms (Table 1). Transarterial balloon-assisted *n*-butyl-2-cyanoacrylate (NBCA; Nycomed, Ingenor, Paris, France) embolization was performed in two; transvenous DC

Table 1
Demography and outcomes of endovascular detachable coil embolization in 24 patients with 25 direct carotid-cavernous fistulas.

Patient/sex/ age (y)	DC number/ length	Adjuvant embolic agent	Adjuvant access route(s)	Causes of adjuvant embolic agent and/or access route	Outcome	Follow-up (mo)
1/M/35	2/16 cm	Nil	Nil		Cure	20
2/F/24	13/234 cm	Nil	Nil		Cure	18
3/M/21	7/92 cm	Nil	Nil		Residual fistula with spontaneous cure	36
4/F/56	6/78 cm	Nil	Nil		Cure	23
5/F/39	9/88 cm 6/30 cm	Nil	Nil		Cure/residual fistula then spontaneous cure	18
6/F/82	3/48 cm	Nil	Nil		Cure	25
7/M/23	7/88 cm	Nil	Nil		Cure	36
8/M/35	16/283 cm	Nil	Nil		Residual fistula with spontaneous cure	28
9/M/67	8/96 cm	Nil	Nil		Cure	32
10/M/46	4/68 cm	Nil	Nil		Cure	19
11/F/24	11/134 cm	Nil	Nil		Cure	14
12/F/48	12/152 cm	NBCA	Nil	Residual fistula	Transient CN6 palsy	26
13/F/26	21/283 cm	NBCA	Transorbital	Recurrent fistula	Cure	25
14/M/8	19/225 cm	NBCA	Transorbital	Residual fistula	Transient CN6 palsy	16
15/M/51	9/128 cm	Nil	Nil		Cure	9
16/F/62	15/238 cm	Nil	Nil		Cure	19
17/M/27	25/250 cm	Nil	Nil		Cure	5
18/M/59	24/299 cm	Nil	Nil		Cure	18
19/F/46	28/345 cm	NBCA	Trans-FV, transorbital	Residual and recurrent fistulas	Transient CN3 palsy	17
20/M/24	31/756 cm	Nil	Trans-FV		Cure	7
21/M/31	21/205 cm	Nil	Trans-FV, trans-IPS	Recurrent fistula	Cure	16
22/M/34	15/189 cm	Nil	Trans-FV	Recurrent fistula	Cure	6
23/M/18	16/175 cm	NBCA	Nil	Residual fistula	Cure	4
24/M/57	14/235 cm	Nil	Nil		Residual fistula then spontaneous cure	3

CN = cranial nerve; FV = facial vein; IPS = inferior petrous sinus.

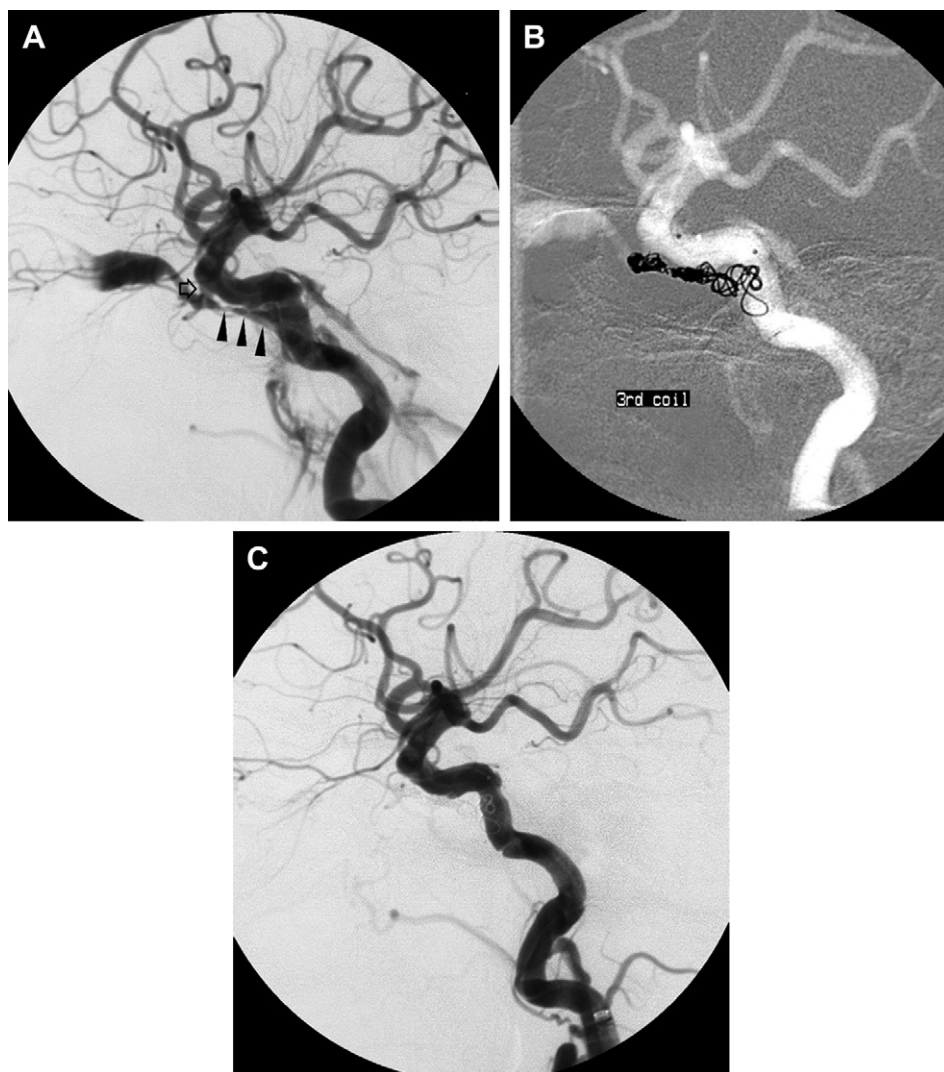


Fig. 1. A 82-year-old woman had right DCCF with small fistula and cavernous sinus. (A) Right lateral carotid angiogram revealed a DCCF with small fistula track (arrow) and small cavernous sinus (arrowheads). (B,C) Transarterial detachable coil (DC) embolization with total occlusion of the fistulae was achieved by the placement of three DCs with total length of 48 cm of coils into the cavernous sinus (CS).

embolization via facial vein ($n = 4$, Figs. 2B and 3E) and/or inferior petrous sinus ($n = 1$) was initiated in five, while three underwent a transorbital approach (Fig. 2E) by using NBCA and DC embolization. After the last session of procedures, three patients had temporary functional impairment of the sixth ($n = 2$) or third ($n = 1$) cranial nerve, which may be related to initial dense coil packing; this resolved completely within 6 months. No significant procedure-related neurological complication or recurrent fistula was observed in any of the 24 patients. All the ocular-orbital symptoms and signs related to fistula such as bruit, chemosis, proptosis, or headache gradually resolved after the final endovascular treatment.

4. Discussion

DCCFs were usually treated with detachable balloon in the past. By the high-flow fistula flow, the balloon could be guided into the fistula and CS. Before detachment, the balloon could be inflated by contrast media to a volume larger than the

orifice of the fistula to block the fistula flow and to prevent its retrograde herniation into the ICA. This method is relatively simple and inexpensive in some cases. However, in those patients with complex vascular and/or fistula anatomy such as a tortuous, stenotic ICA, intimal flap, small fistula tract, or a small CS, the balloon cannot be directed into an ideal position such that the fistula is occluded with ICA preservation. Furthermore, the potential risks of detachable balloon in these patients are premature balloon detachment with inadvertent occlusion of carotid artery or intracranial branches leading to thromboembolic events.³

Placement of a cover stent is another treatment option. It may immediately obliterate DCCFs by placing an impermeable barrier across the site of fistula communication. The major advantage of the cover stent itself is the capability to preserve the flow of the ICA by successful navigation and deployment of the stent into the cavernous ICA to occlude the tear.⁸ The disadvantages of this stent are its stiffness and larger caliber, making it difficult to navigate into the distal ICA,

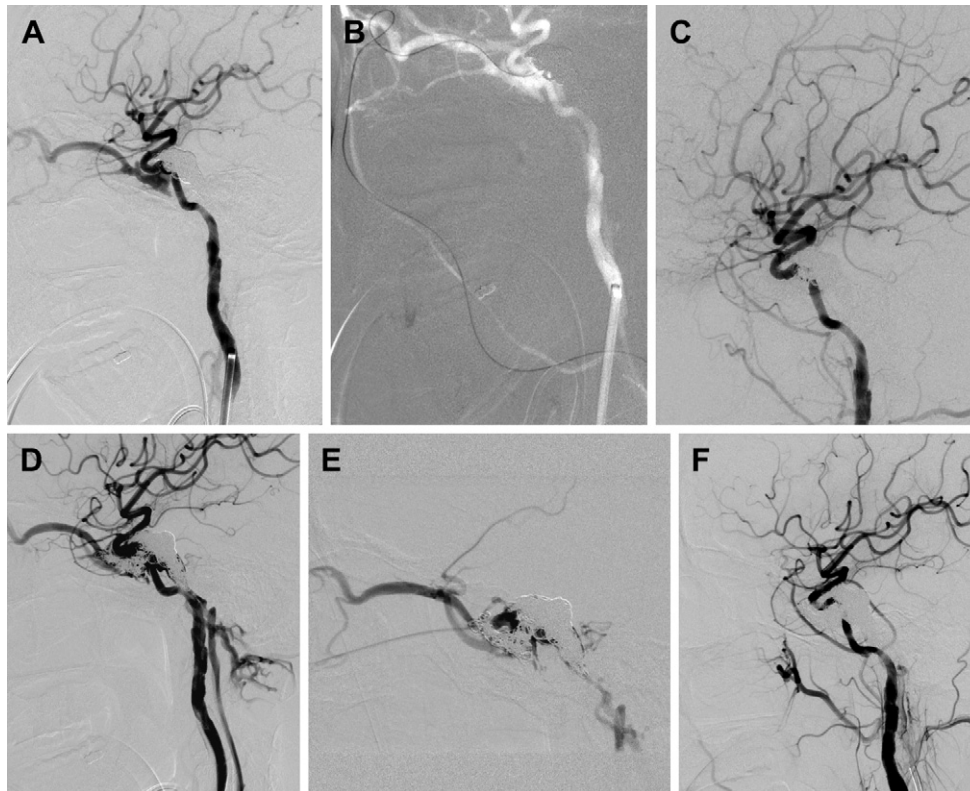


Fig. 2. A 46-year-old woman presented with right DCCFs. (A) Postembolization lateral carotid angiography demonstrated residual fistula with exclusive draining to ophthalmic vein. (B–D) She underwent transfacial vein DC embolization with total occlusion of the fistula; unfortunately, she had recurrent fistula with anterior and posterior drains. (E,F). Transorbital DC and NBCA embolization were performed with total occlusion of the fistula.

particular in those patients with tortuous ICA.⁹ Furthermore, residual or recurrent fistula may occur because of leaking of fistula flow between the stent and the arterial wall. In addition, dual anti-platelet regime to maintain the patency of the ICA is necessary. So far, long-term safety data are lacking in use of covered stents to treat the DCCFs.

The use of standard platinum coils alone has been reported in the treatment of intracranial high-flow AVFs.¹⁰ By navigating a microcatheter into the CS through the fistula tract, microcoils can be placed into the CS, leading to fistula occlusion. Technical pitfalls associated with embolization done with these coils include the impossibility of easy retrieval, the relative stiffness of the coils, the risk of perforation, and the difficulty of packing them tightly resulting in residual fistula. DC, however, is retrievable and allows precise coil placement; furthermore, DC has longer coils available than conventional platinum coils. However, the disadvantages of DC are that it is very expensive and not thrombogenic, and a residual fistula may occur because of insufficient packing of the fistula and CS. Furthermore, in DCCFs with larger CS, many coils are needed and coil mass may superimpose with the nearby parent artery, leading to difficulty in evaluating the patency of the parent artery. To prevent coil herniation into the parent artery, stent-assisted coil embolization had been reported, this technique is particularly useful when the tear in the ICA is large.¹¹ DC was thought to be a far more suitable embolic material for those DCCFs with small fistula tracts and

small CS.^{4,5} Another major concern is the recurrent or residual fistula, which may be reduced by the advent of the hydrogel coil (Hydrocoil; MicroVention, Inc, Aliso Viejo, CA, USA). By the expansion of the hydrogel attached to the coil, there is higher packing density than conventional DC, and with lower coil number and length requirements.¹²

In our series, DC was selected as a first line of embolic material to occlude DCCFs. To achieve mechanical blockage the shunting flow with angiographic cure of the DCCF, the CS should be as densely packed as possible. However, recoil of microcatheter from the CS into the ICA is not uncommon during advancement of the coils into the CS because there is less space in the CS in the late stage of embolization. In this circumstance, recatheterization of the microcatheter into the fistula/CS is difficult because of blockage by previously detached coils. Another drawback of DC embolization is recurrent fistula, which is particularly common in fistulas with larger tears associated with a larger CS, because there is less coil packing density compared with those of small fistula and small CS. To treat these residual or recurrent fistulas, a transvenous route by direct occlusion of the venous drains is an alternative. Transinferior petrous sinus and/or transfacial vein can be selected, depending on whether the fistula drainage is posterior or anterior, such as seen in Cases 19, 20, 22, and 23. Another access route is via transorbit, by direct puncture of superior ophthalmic vein or CS. A transorbital approach to treat difficult fistula anatomy has been reported.^{13–15} In these

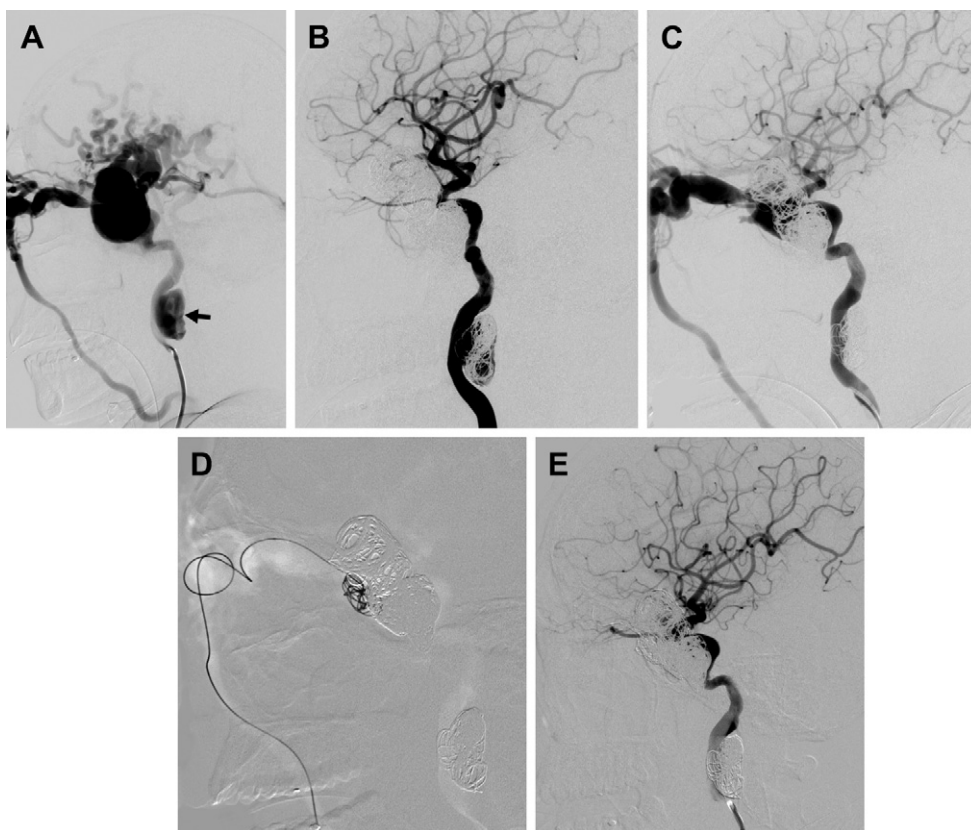


Fig. 3. A 24-year-old man presented with left DCCF with complete steal phenomenon. (A) Left frontal carotid angiogram shows a DCCF with large CS and with complete steal of carotid blood flow; he also had a traumatic aneurysm in the cervical internal carotid artery (arrow). (B) A total of 29 DCs with total length of 756 cm were employed to occlude fistula, and CS resulted in total occlusion of the fistula with preservation of the ICA. (C) The patient had recurrent fistulas, which was subsequently confirmed by carotid angiogram with drainage exclusively to the superior ophthalmic vein. (D,E) He underwent transfacial vein DC embolization leading to total occlusion of the fistula.

series, we had treatment residual or recurrent fistula by direct puncture of the CS in three patients. The potential risks of this method are injury of the optic nerve and eyeball, intraorbital hematoma formation, and difficulty to achieve hemostasis at the end of procedure. Because it is more invasive and risky, it should be performed by an experienced operator who is familiar with the technique. Furthermore, this method is reserved for those fistulas in which there has been failure to achieve morphologic cure with preservation of ICA flow by other routes. In our series, we selected NBCA as an adjuvant embolic agent to treat recurrent ($n = 2$) or residual ($n = 3$) fistulas. Under a protective balloon in the ICA, about 1–2 ml 50% NBCA/lipiodol mixture was slowly infused into the CS. The advantages of NBCA are its low cost and quick formation of thrombus with occlusion of the fistula.¹⁶ However, it should be used with caution and performed by experienced operators because it is a liquid and it is difficult to control its flow during infusion. Inadvertent leakage into the ICA results in catastrophic complications.

In our series, two to 31 coils (mean, 14) with an average length of 189 cm were used to achieve angiographic cure. The number and length of coils largely depended on the size of the CS. In our series, subtotal or partial obliteration of the fistulae with residual fistula was observed in eight DCCFs at the end

of the procedure; of these, four showed spontaneous closure of the residual fistula on follow-up angiogram 3–4 days after embolization. Therefore, subtotal occlusion with small and/or slow residual shunting flow may not indicate failure and does not appear to be a definite indication for retreatment. However, a follow-up angiogram is mandatory to check for the occurrence of spontaneous thrombosis or larger residual fistula.

In conclusion, transarterial DC embolization of DCCFs was proved in both efficacy and safety for managing high-flow AVFs with sustained effect, particularly in DCCFs with a small fistula track and/or CS. However, retreatment via various routes and/or embolic materials maybe necessary in some DCCFs with larger fistula associated with larger CS because of residual or recurrent fistulas. Meticulous evaluation and understanding of the angioarchitecture of the fistula is important to avoid cranial nerve palsies or incomplete occlusion of the fistulas.

Acknowledgments

This work was supported in part by a grant from the Taipei Veterans General Hospital (V98C1-153, V99C1-012) and NSC (97-2314-B-075-062-my2, 99-2314-B-075-045-my2).

References

1. Lewis AI, Tomsick TA, Tew JM. Management of 100 consecutive direct carotid-cavernous fistulae: result of treatment with detachable balloons. *Neurosurgery* 1995;**36**:239–45.
2. Luo CB, Teng MMH, Yen DH, Chang FC, Lirng JF, Chang CY. Endovascular embolization of recurrent traumatic carotid-cavernous fistula managed previously with detachable balloons. *J Trauma* 2004;**56**:1214–24.
3. Luo CB, Teng MMH, Chang FC, Lirng JF, Chang CY. Endovascular management of the traumatic cerebral aneurysms associated with traumatic carotid cavernous fistulae. *Am J Neuroradiol* 2004;**25**:501–5.
4. Guglielmi G, Viñuela F, Duckwiler G, Dion J, Stocker A. High-flow, small-hole arteriovenous fistula: treatment with electrodetachable coils. *Am J Neuroradiol* 1995;**16**:325–8.
5. Siniluoto T, Seppänen S, Kuurne T, Wikholm G, Leinonen S, Svendsen P. Transarterial embolization of a direct carotid cavernous fistula with Guglielmi detachable coils. *Am J Neuroradiol* 1997;**18**:519–23.
6. Luo CB, Teng MM, Chang FC, Chang CY. Endovascular treatment of intracranial high-flow arteriovenous fistulas by Guglielmi detachable coils. *J Chin Med Assoc* 2006;**69**:80–5.
7. Seruga T. Endovascular treatment of a direct post-traumatic carotid-cavernous fistula with electrolytically detachable coils. *Wien Klin Wochenschr* 2006;**118**(Suppl 2):80–4.
8. Li J, Lan ZG, Xie XD, You C, He M. Traumatic carotid-cavernous fistulas treated with covered stents: experience of 12 cases. *World Neurosurg* 2010;**73**:514–9.
9. La Tessa G, Pasqualetto L, Catalano G, Marino M, Gargano C, Cirillo L, et al. Traumatic carotid cavernous fistula: failure of endovascular treatment with two stent-grafts. *Interv Neuroradiol* 2005;**11**:369–75.
10. Halbach VV, Higashida RT, Barnwell SL, Dowd CF, Hieshima GB. Transarterial platinum coil embolization of carotid-cavernous fistulae. *Am J Neuroradiol* 1991;**12**:429–33.
11. Morón FE, Klucznik RP, Mawad ME, Strother CM. Endovascular treatment of high-flow carotid cavernous fistulas by stent-assisted coil placement. *Am J Neuroradiol* 2005;**26**:1399–404.
12. Wang ZG, Ding X, Zhang JQ, Qu CC, Wang CW, Huang DZ, et al. HydroCoil occlusion for treatment of traumatic carotid-cavernous fistula: preliminary experience. *Eur J Radiol* 2009;**71**:456–60.
13. Lin CJ, Luo CB, Chang FC, Teng MM, Wang KL, Chu SH. Combined transarterial, transvenous, and direct puncture of the cavernous sinus to cure a traumatic carotid cavernous fistula. *J Clin Neurosci* 2009;**16**:1663–5.
14. Teng MMH, Lirng JF, Chang T, Chen SS, Guo WY, Cheng CC, et al. Embolization of carotid-cavernous fistulae by means of direct puncture of superior orbital fissure. *Radiology* 1995;**194**:705–11.
15. White JB, Layton KF, Evans AJ, Tong FC, Jensen ME, Kallmes DF, et al. Transorbital puncture for the treatment of cavernous sinus dural arteriovenous fistulas. *Am J Neuroradiol* 2007;**28**:1415–7.
16. Luo CB, Teng MM, Chang FC, Chang CY. Transarterial balloon-assisted n-butyl-2-cyanoacrylate embolization of direct carotid cavernous fistulas. *Am J Neuroradiol* 2006;**27**:1535–40.