




Available online at
 ScienceDirect
www.sciencedirect.com

Elsevier Masson France
 EM|consulte
www.em-consulte.com

**Orthopaedics
& Traumatology**
 Surgery & Research

REVIEW ARTICLE

Pelvic reorientation osteotomies and acetabuloplasties in children. Surgical technique[☆]

J. Sales de Gauzy*

Pediatric Orthopaedic Department, Children Hospital, 330, avenue de Grande-Bretagne, 31026 Toulouse cedex 03, France

Accepted: 14 June 2010

KEYWORDS

Pelvic osteotomy;
 Acetabuloplasty;
 Peri-acetabular
 osteotomy;
 Salter;
 Dega;
 Pemberton

Summary The objectives of pelvic osteotomies are to improve femoral head coverage and coxofemoral joint stability. The most currently used osteotomies can be divided into reorientation osteotomies (Salter and Pol le Cœur triple osteotomy) and acetabuloplasties (Pemberton and Dega). All these osteotomies share an identical installation on the table and bikini-type incision. The Salter osteotomy uses a single osteotomy line located at the inferior gluteal line. The Pol Le Cœur triple pelvic osteotomy combines innominate osteotomies of the iliopubic and ischiopubic rami via a genitofemoral approach (inguinal). In these two reorientation osteotomies, the acetabulum tilts in retroversion, improving the anterior and lateral coverage but reducing the posterior coverage. In the Pemberton acetabuloplasty, the osteotomy line is incomplete. It begins anteriorly between the iliac spines and ends posteriorly immediately above the triradiate cartilage. The posterior part of the ilium remains intact. The Pemberton acetabuloplasty causes retroversion and plicature of the acetabulum responsible for reducing its diameter. Anterior and lateral coverage of the femoral head is improved and posterior coverage remains unchanged. In the Dega acetabuloplasty, the osteotomy line is incomplete. It begins laterally above the acetabulum and terminates just above the triradiate cartilage. The medial part of the ilium remains intact. The Dega acetabuloplasty reduces the diameter of the acetabulum and improves overall femoral head coverage (anterior, lateral, and posterior).

© 2010 Elsevier Masson SAS. All rights reserved.

Introduction

In children, the purpose of pelvic osteotomies is to improve femoral head coverage and coxofemoral joint stability.

There are three types of osteotomy.

- Reorientation osteotomies. These are complete osteotomies that redirect the entire acetabulum. Several types have been described depending on the location and

[☆] Based on the presentation by J. Sales de Gauzy at the 84th SOFCOT annual convention.

* Tel.: +33 5 34 55 85 26; fax: +33 5 34 55 85 32.

E-mail address: salesdegauzy.j@chu-toulouse.fr.

number of lines: Salter innominate osteotomy, double osteotomy, triple osteotomy.

- Acetabuloplasties: Dega acetabuloplasty and Pemberton acetabuloplasty. These are incomplete osteotomies redirected by a hinge located at the triradiate cartilage.
- Chiari osteotomy. This is an osteotomy of the ilium that enlarges the acetabulum by medializing the coxofemoral joint.

This paper describes the technique of the main osteotomies used in children, with variations proposed based on these basic techniques. We will not describe the Chiari osteotomy, which is a salvage procedure whose indications have become rare in the pediatric population.

Reorientation osteotomies

Effect of reorientation osteotomies

These osteotomies modify the orientation of the acetabulum without changing the volume. The acetabulum is redirected forward, downward, and outward. The amount of redirection depends on the osteotomy site; the closer the osteotomy is to the acetabulum, the more displacement is possible. A sector of coverage is always improved at the expense of the opposite sector: anterior and lateral femoral head coverage is improved, but posterior coverage is reduced.

Prerequisites

Performing a reorientation osteotomy imperatively requires the possibility of obtaining complete reduction of the femoral head in the depth of the acetabulum, good preoperative joint range of movement with normal or subnormal amplitudes, and good congruency of the joint surfaces.

Preoperative arthrography can be useful to simulate the effects of the reorientation osteotomy and verify the joint congruency.

Description

Salter innominate osteotomy [1,2]

There is a single osteotomy line located at the inferior gluteal line. The acetabulum is tipped using the flexibility of the pubic symphysis (Fig. 1).

Installation. The surgery is performed under general anesthesia on a standard surgical table. The child is installed in the three-quarter supine position, and the position is maintained by a sheet rolled against the child's back. The entire buttock area must be left free to facilitate the surgical approach and the hip mobilization maneuvers. The entire lower limb is prepared and dressed with a sterile stocking (Fig. 2).

Tenotomy of the adductors. This procedure is optional and is particularly useful in cases of surgical reduction of hip dislocation associated with the osteotomy (Salter procedure). Tenotomy can be performed percutaneously. The coxofemoral joint is placed in flexion and abduction. Through a punctiform incision in the genitofemoral fold, the

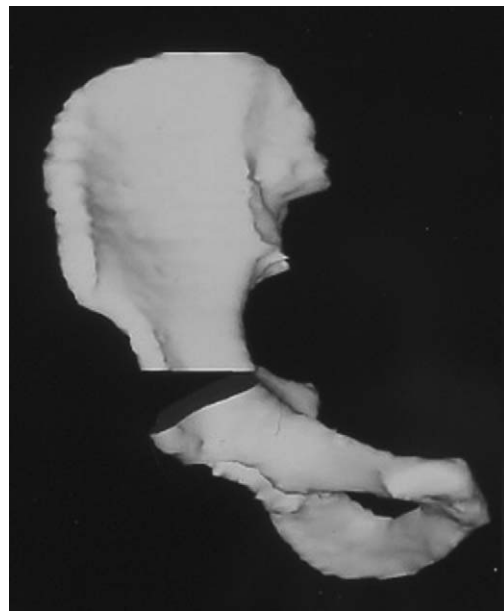


Figure 1 Salter innominate osteotomy.
J. Sales de Gauzy, Conférence d'enseignement 2009, éd. Elsevier-Masson SAS.

cord of the adductor longus is divided step-by-step using a tenotome.

Approach. The incision is a bikini-type incision located 1.5 cm below the iliac crest. It extends from the middle part of the iliac crest to the middle of the groin fold.

The intermuscular space between the sartorius and tensor fasciae latae is approached next. In this space, the descending branch of the lateral cutaneous nerve of the thigh is identified and protected. The tensor fasciae latae and sartorius muscles are separated from bottom to top up to the anterosuperior iliac spine, bringing us to the anterior perichondrium of the ilium, between the superior and inferior iliac spines. The perichondrium is incised using a scalpel.

Incision of the iliac crest. The oblique muscles of the abdomen cover the iliac crest. They are detached under the iliac crest and then lifted from bottom to top, revealing the cartilaginous iliac crest, which is straightforwardly incised to the bone, using the scalpel. The incision extends from the anterior edge of the anterosuperior iliac spine to the middle third of the iliac crest. It should be linear, taking care to separate the crest into medial and lateral parts of identical thickness.

Exposure of the ilium. Using a raspatory, the medial and lateral sides of the crest cartilage are detached from the bony iliac crest and left in continuation with the periosteum. The iliac fossa (the medial iliac fossa) and the gluteal surface can be isolated very easily under the periosteum. On the lateral side, the dissection extends to the supra-acetabular groove, from the reflected tendon of the rectus femoris and the greater ischiatic incisura (greater sciatic notch). On the medial side, dissection extends to the greater ischiatic incisura. During the medial dissection, coagulation of one or two feeding arteries is achieved by diathermy if the arteries are visible or by placing bone wax in the feeding artery holes if these arteries have been torn out (Fig. 3).

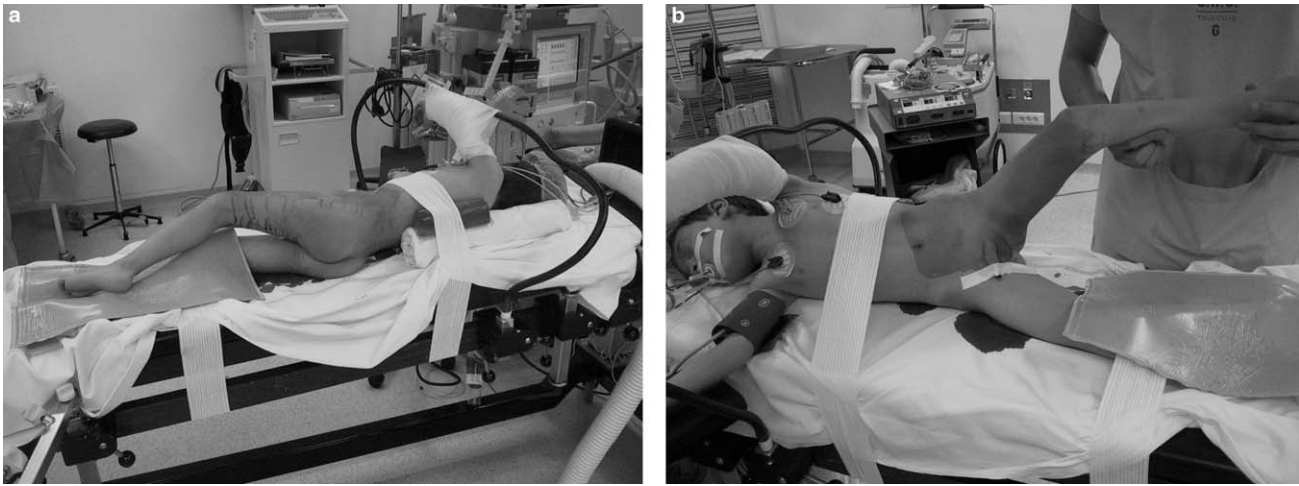


Figure 2 Installation in the three-quarter supine position. The buttock remains free.
J. Sales de Gauzy, Conférence d'enseignement 2009, éd. Elsevier-Masson SAS.

Tenotomy of the psoas-iliac muscle. This facilitates mobilization of the acetabular unit. It is done extraperiosteally. The psoas-iliac muscle is located in contact with the medial periosteum, facing the iliopubic eminence. It is prudent to identify the femoral nerve located within the iliac muscle. The approach to the muscle fibers is easy. They are pulled back using a retractor, then, flexing the hip at least 70°, the tendon of the psoas muscle is revealed, which can be divided at the tendon–muscle fiber junction.

Positioning the Gigli saw. The Gigli saw should be positioned at the greater ischiatic incisura. It is located level with the anterosuperior iliac spine. At this level, the periosteum is detached both medially and laterally with a curved raspatory. A raspatory with blunt edges (a Chiari-type raspa-

tory) can be useful to enlarge the passage. Two Langenbeck retractors then move the muscles from the iliac fossa (internal iliac fossa) and from the gluteal surface (external iliac fossa). Then a dissector is put in place so that the Gigli saw can be passed through. The trajectory should be made from inward to outward so that the sciatic nerve is not damaged. The saw should be new and waxed. To facilitate saw passage, we recommend first passing a wire to which the saw is then attached (Fig. 4).

Osteotomy. Two blunt retractors are positioned to protect the crest cartilage and the skin from the saw. The osteotomy line is perpendicular to the wing of the ilium. It starts at the greater ischiatic incisura and ends just above the anteroin-

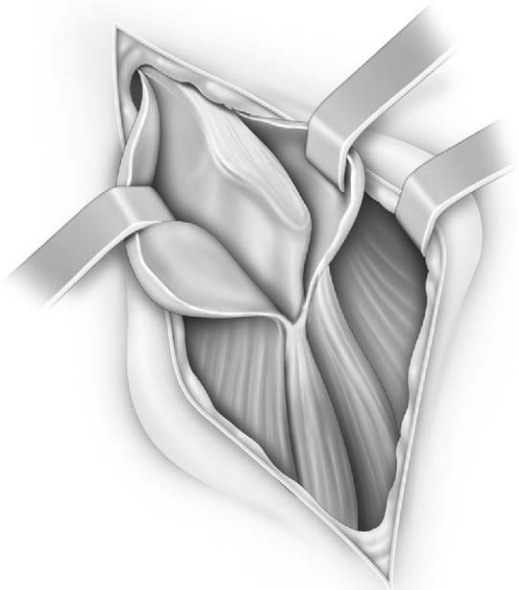


Figure 3 Subperiosteal exposure of the iliac fossa (medial iliac fossa) and gluteal surface (external iliac fossa).
J. Sales de Gauzy, Conférence d'enseignement 2009, éd. Elsevier-Masson SAS.

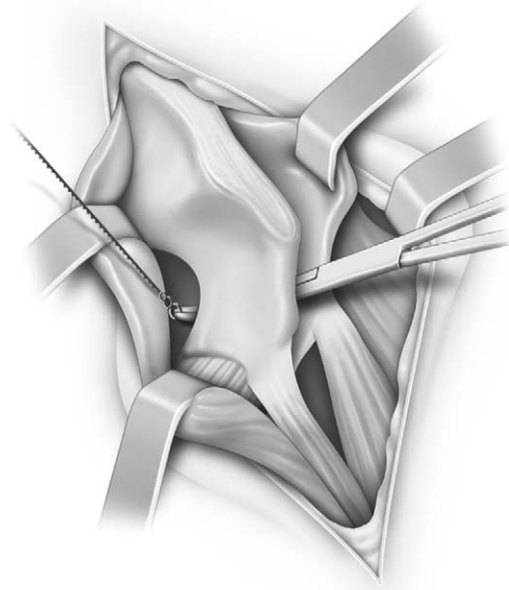


Figure 4 Passage of the Gigli saw at the greater ischiatic incisura (greater sciatic notch).
J. Sales de Gauzy, Conférence d'enseignement 2009, éd. Elsevier-Masson SAS.

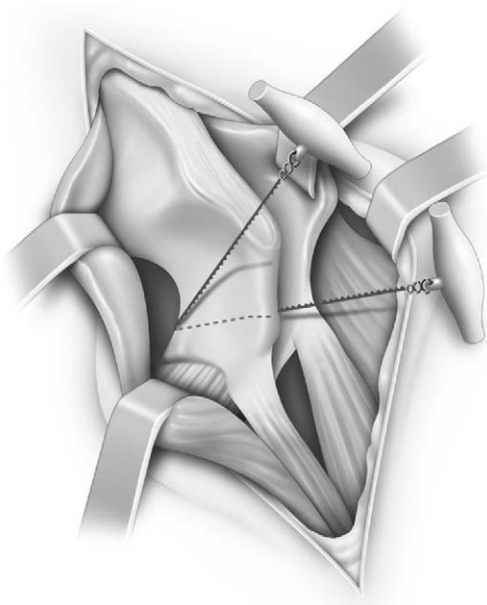


Figure 5 Innominate osteotomy (at the inferior gluteal line).
J. Sales de Gauzy, Conférence d'enseignement 2009, éd.
Elsevier-Masson SAS.

ferior iliac spine. The saw action should be regular, wide, rapid, and smooth (Fig. 5).

Harvesting the graft. A bicortical graft is harvested using Liston forceps on the anterior and superior part of the wing of the ilium. It should be triangular to perfectly match the anterior opening. The base corresponds to the anterior ilium edge.

Mobilization of the acetabular block. Two sharp bone holders are placed on both sides of the innominate osteotomy line. The forceps should be positioned as far back as possible, perfectly symmetrical. The upper fragment is maintained immobile, whereas the lower fragment is mobilized downward, outward, and forward. Displacement should be assisted with the Salter maneuver, consisting of placing the heel on the knee of the contralateral limb. It is very important to check that at the greater ischiatic incisura the cortices have remained in contact and that there is no posterior displacement of the distal fragment (Fig. 6).

Placing the graft and fixation. The graft is placed at the anterior opening and then fixed using two K-wires (diameter 15–18 depending on the child's age). Smooth wires, easier to use than threaded wires, can be employed though threaded wires prevent migration. The wires are put in place with a driver beginning with the wing of the ilium in the graft harvest zone. One is directed toward the posterior column, the other forward. Ideally, both wires go through the graft. They should be driven 1–2 cm into the distal pelvic unit. The hip must then be mobilized so as to ensure that the wires are not intra-articular.

Closure. The crest cartilage is carefully closed using cross-stitches. We advise removing an additional triangle from the iliac wing to facilitate the closure of the crest cartilage. The wires are then bent and cut so as to be flush with the iliac crest. This will facilitate later removal. Then the oblique muscles are reinserted. Subcuticular skin closure is generally done using resorbable suture.

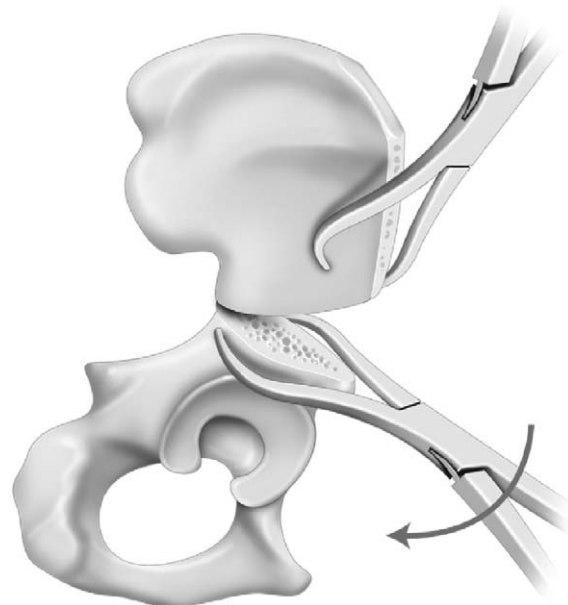


Figure 6 Mobilization of the acetabular unit. Tipping forward and outward.
J. Sales de Gauzy, Conférence d'enseignement 2009, éd.
Elsevier-Masson SAS.

Radiological follow-up. The child is placed supine and an AP X-ray is taken. It should show ovalization of the obturator foramen (obturator hole), showing the quality of the pelvic tip and the femoral head–acetabulum ratio, with normalization of the external coverage angle and the acetabular index as well as reduction of femoral head lateralization. One criterion for a good osteotomy is the existence of a posterior hinge between the two iliac fragments with no diastasis or backward displacement of the distal fragment.

Postoperative immobilization. A plaster or fiberglass hip spica cast is made, with the hip positioned in slight abduction and neutral rotation. In certain cases, the opposite limb is included to obtain better stability.

Postoperative follow-up. After 45 days, the cast and wires are removed and clinical and radiological evaluation are performed. Weightbearing is generally authorized 2 weeks after cast removal.

Pol Le Cœur triple pelvic osteotomy [1,3]

In addition to the innominate osteotomy, this procedure includes an osteotomy of the ischiopubic and iliopubic rami mid-distance between the acetabulum and the pubis. The intervention begins with iliopubic and ischiopubic osteotomies. The innominate osteotomy follows, which is identical to the Salter osteotomy described above (Fig. 7).

Installation. Installation is identical to the Salter osteotomy.

Osteotomy of the iliopubic and ischiopubic rami. The coxofemoral joint is placed in flexion-abduction and external rotation (Fig. 8). The incision is vertical in the genitofemoral fold. The adductor muscles are isolated and detached using the diathermy from the angular surface of the pubis to the medial edge of the obturator foramen. The obturator nerve along the adductor brevis muscle should be preserved. It is

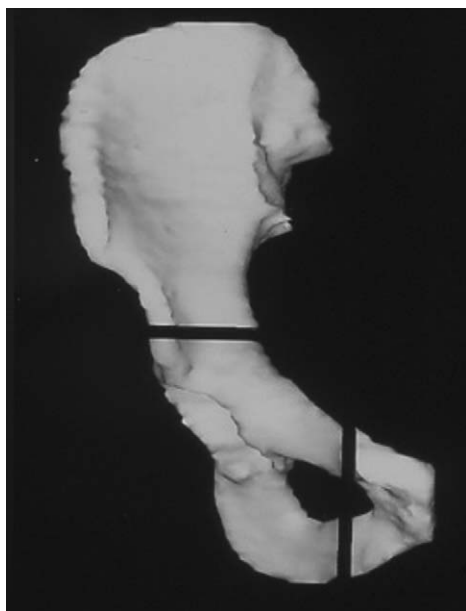

Figure 7 Pol le Cœur triple osteotomy.
J. Sales de Gauzy, Conférence d'enseignement 2009, éd.
Elsevier-Masson SAS.

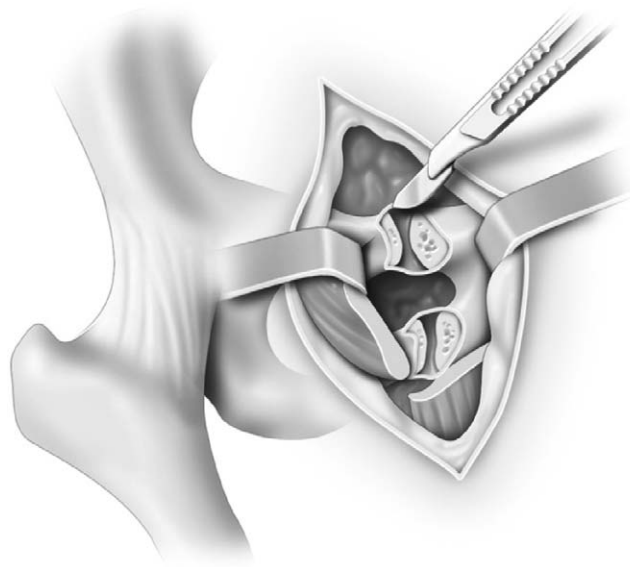


Figure 8 Pol le Cœur triple osteotomy. Osteotomy of the
iliopectoral and ischiopectoral rami.
J. Sales de Gauzy, Conférence d'enseignement 2009, éd.
Elsevier-Masson SAS.

not necessary to divide the adductor brevis muscle.

The ischiopectoral ramus is dissected intraperiosteally to prevent lesion to the cavernous body. The iliopectoral ramus can be approached extraperiosteally. Two Langenbeck retractors are placed, protecting the soft tissues during the osteotomy. The osteotomies are carried out near the pubis with an osteotome. Excision of a few millimeters of bone using a bone rongeur is recommended to obtain better mobilization of the acetabulum. After the osteotomy, deep bleeding may occur, which is normally easily stopped by pressure with a hemostatic compress. The wound is closed

immediately in two layers (subcutaneous and cutaneous) with a suction drain installed. The adductor muscles are left in place or can be sutured to prevent formation of an unsightly hollow.

Innominate osteotomy. The innominate osteotomy is identical to the technique described in the Salter osteotomy.

End of the operation, postoperative care, and follow-up. After the three osteotomies, the continuation of the intervention (tipping, graft placement, fixation) as well as the postoperative treatments are identical to those described for the Salter innominate osteotomies. An X-ray is taken at the end of the procedure.

Acetabuloplasties

Acetabuloplasties are incomplete osteotomies at the superior and inferior pubic rami. In the Dega acetabuloplasty, the line is curvilinear and located above the acetabulum. Only the lateral cortex is resected. The osteotomy line ends above the triradiate cartilage. In the Pemberton acetabuloplasty, the line is curvilinear, begins between the anterosuperior iliac spine, and ends at the posterior branch of the triradiate cartilage.

Effects of Dega and Pemberton acetabuloplasties

Tipping is obtained thanks to a hinge at the horizontal branch of the triradiate cartilage. The shape of the acetabulum is modified because of the plicature of the acetabular roof, the radius of the acetabular curvature is reduced, which increases its depth and thus increases its volume.

However, although osteotomies increase acetabulum volume, they reduce its diameter. Thus, they can only be effective if its radius of curvature remains greater than the radius of the femoral head.

The Pemberton osteotomy especially improves the anterior and lateral coverage of the femoral head; it also results in a retroversion effect of the acetabulum. The posterior coverage remains unchanged, except if the graft is placed very far back.

The Dega osteotomy improves the overall coverage, anterior, lateral, as well as posterior.

Prerequisite

Dega and Pemberton osteotomies require that the femoral head can be completely relocated, the joint surfaces be adequately congruent, the joint have good mobility, and the triradiate cartilage be open.

Pemberton acetabuloplasty [4,5]

Installation

Installation is identical to the Salter osteotomy. Before preparing and draping, one must check that the image intensifier can be properly positioned (Fig. 9).

Approach

The approach is identical to the Salter osteotomy. The iliac fossa (internal iliac fossa) and the gluteal surface (external iliac fossa) are exposed.

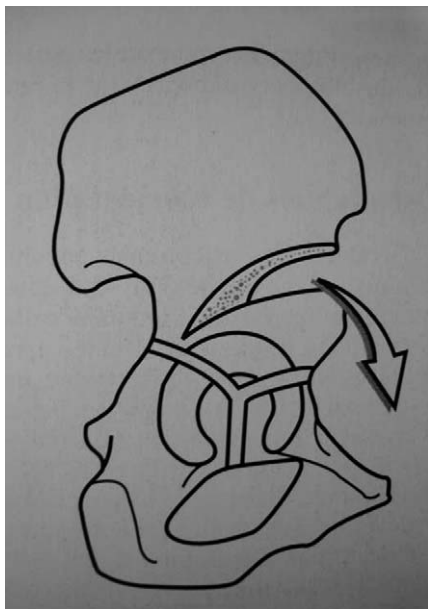


Figure 9 Pemberton acetabuloplasty.
J. Sales de Gauzy, Conférence d'enseignement 2009, éd.
Elsevier-Masson SAS.

Osteotomy

Two Langenbeck retractors are placed in the greater ischiatic incisura.

The osteotomy begins between the anteroposterior and anteroinferior iliac spines. It is curvilinear, going backward and downward toward the posterior branch of the triradiate cartilage. It ends just above the triradiate cartilage, a few millimeters before the greater ischiatic incisura. The osteotomy is performed in several steps: the medial and lateral cortices are resected separately, then the cancellous zone is resected using a curved osteotome. If lateral tipping is to be increased, the resection of the medial cortex must be more distal than the lateral cortical section. In this way, during the opening of the osteotomy, straightening the cutting plane tips the acetabulum outward.

Mobilization of the acetabulum

The acetabulum roof is tipped either using an osteotome as a lever or a Meary distractor at the anterior part of the osteotomy.

Graft placement

The opening is maintained by a bicortical graft harvested from the anterior and superior part of the iliac wing (Fig. 10). The graft is positioned at the anterior part of the osteotomy, which provides anterior and lateral lowering. If improved posterior coverage is sought, the graft must be positioned farther toward the back.

Fixation

Two wires are used for fixation.

Closure and postoperative immobilization

The wound is closed as in the Salter osteotomy. A hip spica cast is placed for 6 weeks.

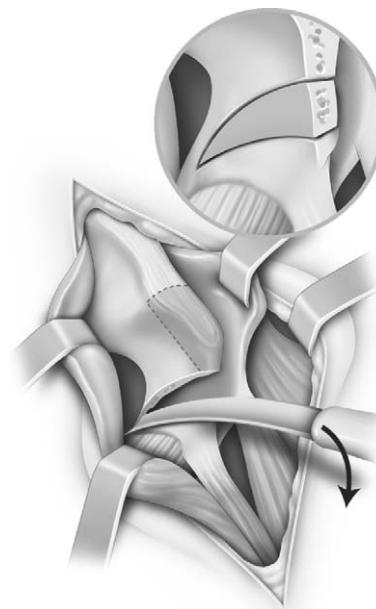


Figure 10 Pemberton acetabuloplasty. Mobilization of the acetabulum and graft placement.
J. Sales de Gauzy, Conférence d'enseignement 2009, éd.
Elsevier-Masson SAS.

Dega acetabuloplasty [4,6]

Installation

Installation is identical to the Salter osteotomy. Since it is performed with scopic guidance, one must check that the image intensifier can be properly positioned (Fig. 11).

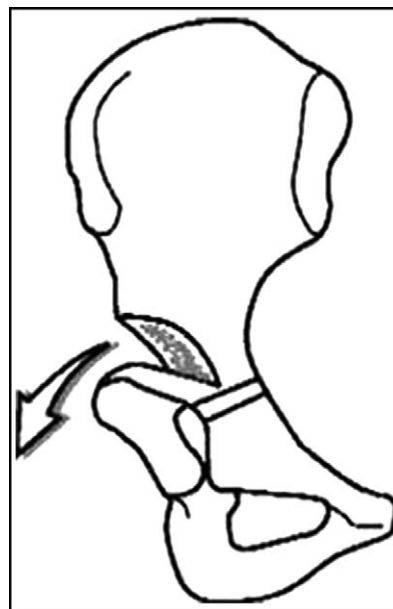


Figure 11 Dega acetabuloplasty.
J. Sales de Gauzy, Conférence d'enseignement 2009, éd.
Elsevier-Masson SAS.



Figure 12 Dega acetabuloplasty. Osteotomy line under scopic guidance.

J. Sales de Gauzy, Conférence d'enseignement 2009, éd. Elsevier-Masson SAS.

Approach

The incision is a bikini-type incision, identical to the Salter osteotomy procedure. The intermuscular space between tensor fasciae latae and sartorius is developed.

Only the gluteal surface (lateral iliac fossa) is exposed. Exposure extends forward to the anterior edge of the ilium to the greater ischiatic incisura at the back. A Hohmann retractor is put in place.

Osteotomy

The osteotomy is performed under fluoroscopy. The osteotomy line is located 15 mm above the acetabular rim, following the contour of the acetabulum. It extends from the anteroinferior iliac spine to the greater ischiatic incisura (greater sciatic notch). The procedure begins at the two extremities (anterosuperior iliac spine and greater ischiatic incisura) with bicortical resection for a few millimeters using Kerrison forceps. Then the osteotomy is carried out using a curved osteotome. It passes toward the triradiate cartilage and stops just above it. The medial cortex is not resected (Fig. 12).

Mobilization of the acetabulum

The acetabulum is lowered using a lever maneuver with two osteotomes, then two Meary distractors.

Graft placement

Tipping is maintained by several tricortical grafts harvested from the iliac crest. Depending on the position of the grafts,

anterior, lateral, or posterior coverage can be privileged. Generally, good stability is obtained and no fixation is necessary.

Closure

The wound is closed using the same procedure as for reorientation osteotomies. An AP X-ray is taken.

Postoperative treatment

A hip spica cast is put in place after the surgery for 6 weeks.

Conclusion

The four osteotomies described in this article are basic interventions in pediatric orthopaedics. Their indications are different depending on the type of pathology to be treated [7,8], with, however, certain cases for which any of the four techniques can be discussed depending on the operator's experience and preference.

Conflict of interest statement

No conflicts of interest.

References

- [1] Sales de Gauzy J, Cahuzac JP. Ostéotomies pelviennes de réorientation. In: Orthopédie Pédiatrique. Membre inférieur et bassin. Paris: Masson; 2005. p. 10–8.
- [2] Salter RB. Innominate osteotomy in the treatment of congenital dislocation and subluxation of the hip. *J Bone Joint Surg (Br)* 1961;43:518–39.
- [3] Le Cœur P. Correction des défauts d'orientation de l'articulation coxofémorale par ostéotomie de l'isthme iliaque. *Rev Chir Orthop* 1965;51:211–2.
- [4] Carlioz H, Madi F. Ostéotomie de Dega et ostéotomie de Pemberton. In: Orthopédie Pédiatrique. Membre inférieur et bassin. Paris: Masson; 2005. p. 10–8.
- [5] Pemberton PA. Pericapsular osteotomy of the ilium for treatment of congenital subluxation and dislocation of the hip. *J Bone Joint Surg (Am)* 1965;47:65–86.
- [6] Dega W. Osteotomia Trans-iliakalna w leczeniu wrodzonej dysplazji biodra. *Chir Narz Ruchu Ortop Pol* 1974;39:601–13.
- [7] Padovani JP. Techniques et indications des ostéotomies pelviennes chez l'enfant. In: Conférences d'enseignement 1977 (cahiers d'enseignement de la SOFCOT, n° 7, p. 29–50). Paris: Expansion scientifique française; 1977.
- [8] Sales de Gauzy J. Indications des ostéotomies pelviennes chez l'enfant. Conférences d'enseignement 1997 (cahiers d'enseignement de la SOFCOT, n° 62, p. 71–90). Paris: Expansion scientifique française; 1997.