

Tachycardia-Mediated Cardiomyopathy Secondary to Focal Atrial Tachycardia

Long-Term Outcome After Catheter Ablation

Caroline Medi, BMED,*† Jonathan M. Kalman, MBBS, PhD,* Haris Haqqani, MBBS,*
Jitendra K. Vohra, MD,* Joseph B. Morton, MBBS, PhD,* Paul B. Sparks, MBBS, PhD,*
Peter M. Kistler, MBBS, PhD*‡

Melbourne, Australia

- Objectives** This study aimed to characterize the incidence, clinical and electrophysiologic features, and long-term outcomes of patients with tachycardia-mediated cardiomyopathy (TCM) secondary to focal atrial tachycardia (AT).
- Background** TCM is known to complicate atrial tachyarrhythmias. Little is known of the patient and tachycardia characteristics associated with the development of left ventricular (LV) dysfunction and the long-term outcomes after cure of tachycardia.
- Methods** A total of 345 patients with focal AT underwent radiofrequency ablation between January 1997 and July 2008. A retrospective analysis was performed to identify patients with LV dysfunction, defined as an ejection fraction <50% on echocardiography. Patients with pre-existing structural heart disease (n = 14) were excluded. Patients with TCM (n = 30) and without TCM (n = 301) were compared. Recovery of LV function was also assessed.
- Results** The incidence of TCM was 10%. Incessant or very frequent paroxysmal tachycardia was strongly associated with TCM, compared to patients without TCM (100% vs. 20%, p < 0.001). Patients in the TCM group were younger (mean age 39 ± 22 years vs. 51 ± 17 years, p = 0.0006) and more frequently male (60% vs. 38%, p < 0.001). Patients with TCM had a longer mean tachycardia cycle length (502 ± 131 ms vs. 402 ± 105 ms, p < 0.0001) and slower ventricular rate (117 ± 21 beats/min vs. 141 ± 33 beats/min, p = 0.0007) during tachycardia compared with patients who did not have TCM. Appendage sites are associated with a high incidence of incessant tachycardia (84%) and LV dysfunction (42%). After successful ablation, LV function was restored in 97% of patients at a mean of 3 months.
- Conclusions** Cardiomyopathy occurs in 10% of patients with focal AT. A slower incessant tachycardia is more frequently complicated by cardiomyopathy. Long-term restoration of LV function can be achieved after successful catheter ablation of the tachycardia focus. (J Am Coll Cardiol 2009;53:1791-7) © 2009 by the American College of Cardiology Foundation

Tachycardia-mediated cardiomyopathy (TCM) is an important reversible cause of left ventricular (LV) dysfunction that may complicate both supraventricular and ventricular arrhythmias (1,2). Catheter ablation is highly effective in providing long-term success for the majority of patients with supraventricular arrhythmias (3,4). The mechanistic insights into the pathophysiology of TCM are based on animal models in which rapid right atrial and ventricular

pace has been used to induce heart failure. Prior animal studies have demonstrated a relationship between an increasing tachycardia rate and duration and increased severity of LV dysfunction (5). Although TCM is known to occur secondary to incessant supraventricular arrhythmias, there is a paucity of data describing the characteristics of focal atrial tachycardia that lead to TCM.

The aim of the present study was to determine the incidence of TCM among patients presenting with focal atrial tachycardia (AT), the electrophysiologic characteristics of focal AT associated with the development of reversible LV dysfunction, and the long-term clinical outcome after successful catheter ablation.

Methods

Study population. The study population consisted of a consecutive series of 345 patients undergoing radiofrequency ablation (RFA) for focal AT between January 1997

From the *Department of Cardiology, Royal Melbourne Hospital, and the Department of Medicine, University of Melbourne, Melbourne, Australia; †Department of Cardiology, The Alfred Hospital, Melbourne, Australia; and the ‡Baker Heart Research Institute, Melbourne, Australia. Dr. Medi has received a scholarship from the Cardiac Society of Australia and New Zealand, a medical post-graduate scholarship from the National Heart Foundation, and a Cardiovascular Lipid Research Grant (Pfizer Australia). Dr. Haqqani has received a Medical Postgraduate Research Scholarship from the National Health and Medical Research Council. Dr. Kistler has received research support from the Cardiac Society of Australasia.

Manuscript received September 15, 2008; revised manuscript received January 26, 2009, accepted February 13, 2009.

**Abbreviations
and Acronyms**

- AT** = atrial tachycardia
- AV** = atrioventricular
- EP** = electrophysiology
- LV** = left ventricular
- LVEF** = left ventricular ejection fraction
- RFA** = radiofrequency ablation
- TCL** = tachycardia cycle length
- TCM** = tachycardia-mediated cardiomyopathy

and July 2008. All patients had clinically documented paroxysmal or incessant AT. Comparison of P-wave morphology with the sinus rhythm P-wave was made to identify ectopic AT. The lower atrial rate was 100 beats/min with a change or distinct difference in the P-wave morphology to the typical sinus P-wave important in the diagnosis of focal AT. Tachycardia was defined by the presence of ≥ 10 consecutive tachycardia beats on 12-lead electrocardiogram or Holter monitor. Incessant tachycardia was defined as continuous tachycardia or continuous paroxysms of tachycardia separated by ≤ 2 sinus beats (6). Patients had failed therapy with a mean of 1.5 ± 1.2 antiarrhythmic drugs before the procedure. Patients routinely undergo echocardiography before electrophysiology (EP) study and RFA. Left ventricular dysfunction was defined as a left ventricular ejection fraction (LVEF) of $< 50\%$. Patients were considered to have pre-existing LV dysfunction when cardiomyopathy occurred in the context of known significant coronary artery disease, valvular heart disease, congenital heart disease, or inherited cardiomyopathy; cardiomyopathy had been documented before the onset of tachycardia; or the echocardiographic abnormalities were segmental or of a pattern attributable to another cause. These patients ($n = 14$) were excluded from the analysis. Comparisons were made between patients with TCM ($n = 30$) and without TCM ($n = 301$).

Of the patients with TCM, 27 of 30 (90%) were in tachycardia at the time of baseline (pre-ablation) echocardiogram, and 3 of 30 (10%) were in sinus rhythm. At the time of echocardiography, the mean heart rate in the incessant population was 114 ± 16 beats/min versus 69 ± 9 beats/min in the sinus rhythm population ($p < 0.0001$).

EP study. All patients underwent EP study in the fasting state with minimal use of sedation, and after the provision of informed written consent. All antiarrhythmic drugs were discontinued a minimum of 5 half-lives before the procedure.

CATHETER POSITIONING. Catheter positioning and the approach used in our laboratory for ablation of focal AT have been previously described in detail (7). In brief, catheters were positioned in the following manner: 1) coronary sinus catheter (10-pole) positioned with the proximal bipole at the ostium of the coronary sinus; 2) crista terminalis catheter (20-pole) positioned along the crista terminalis; 3) His bundle electrogram catheter; and 4) mapping and ablation catheter. When necessary, the 3-dimensional electroanatomic mapping system was used.

MAPPING AND DEFINITION OF FOCAL AT. Diagnosis of focal AT was made using standard electrophysiologic criteria (7). Anatomic localization of the atrial focus was performed during tachycardia or atrial ectopy by analysis of the following: 1) surface electrogram P-wave morphology (8); 2) right atrial endocardial activation sequence during tachycardia (9,10); 3) conventional point by point mapping; and 4) when necessary, the 3-dimensional electroanatomic mapping system. Definitions of anatomic locations of tachycardia origin within the atria have been previously described (6,9-11). In the right atrium, these foci tend to occur along the crista terminalis (12), tricuspid annulus (13), ostium of the coronary sinus, and the perinodal region. In the left atrium, foci occur predominantly at the pulmonary vein ostia and less commonly at the mitral annulus, left atrial appendage, and left-sided septum.

Tachycardia cycle length was assessed by calculating the mean cycle length of 10 consecutive tachycardia beats from intracardiac electrograms recorded at the time of EP/RFA, and is a measure of the atrial rate in tachycardia. The tachycardia cycle length (TCL) is expressed in milliseconds. Ventricular rate was assessed by calculating the mean heart rate of 10 consecutive QRS complexes in tachycardia recorded during EP/RFA. Ventricular rate is expressed as beats/min. Patients with incessant tachycardia had a tachycardia pattern described in the preceding text. One patient had incessant atrial ectopy with persistent atrial bigeminy or trigeminy and was included in this group.

RFA. RFA was performed with continuous temperature feedback control of power output to achieve a target temperature of 50° to 60°C for a maximum power of 40 to 50 W. The power was reduced to 30 W for tachycardia sites at the pulmonary vein ostia and within the atrial appendages. Irrigated ablation was used where adequate power could not be achieved. Acute procedural success was defined by the absence of tachycardia or ectopy 30 min after ablation despite infusion of isoproterenol ($\leq 6 \mu\text{g}/\text{min}$) and burst atrial pacing.

Follow-up. Patients were followed up by the treating electrophysiologist and by telephone interview. Any patient with symptoms suggestive of recurrent tachycardia was reviewed by the treating electrophysiologist, and attempts were made to document the rhythm. The patients with impaired LV function underwent repeat echocardiography after successful ablation.

Statistical analysis. All continuous variables are expressed as mean \pm SD. Comparisons between groups were performed with an unpaired Student *t* test or Mann-Whitney *U* test. Categorical variables, expressed as numbers and percentages, were compared with a chi-square test. A value of $p < 0.05$ was considered statistically significant.

Results

Patient characteristics. The study population included 345 patients (40% male; mean age 50 ± 18 years, range 9 to

Table 1 Clinical and Tachycardia Characteristics in Patients With Tachycardia-Mediated Cardiomyopathy

Anatomic Site	Age (yrs)	Male	Symptom Duration (yrs)	TCL	Ventricular Rate	Pre-Ablation LVEF
PV (n = 8)	36 ± 24	63 (5)	7 ± 8	407 ± 121	125 ± 14	34 ± 11
AA (n = 8)	24 ± 7	88 (7)	3 ± 5	616 ± 137	103 ± 19	34 ± 10
Perinodal (n = 2)	61 ± 28	100 (2)	0.8 ± 0.4	502 ± 45	123 ± 11	38 ± 11
CS (n = 1)	67 ± 0	100 (1)	5 ± 0	N/A*	89†	36
CT (n = 3)	41 ± 4	0 (0)	5 ± 5	413 ± 54	145 ± 23	40 ± 9
TA (n = 3)	44 ± 22	33 (1)	10 ± 13	406 ± 115	151 ± 49	45 ± 0
Multifocal (n = 5)	49 ± 28	40 (2)	7 ± 9	522 ± 32	116 ± 6	34 ± 13

Values are mean ± SD or % (n). *Premature atrial complex 37% total beats. †Mean rate Holter monitor.
 AA = atrial appendage; CS = coronary sinus; CT = crista terminalis; LVEF = left ventricular ejection fraction; N/A = not applicable; PV = pulmonary vein; TA = tricuspid annulus; TCL = tachycardia cycle length.

85 years). Left ventricular dysfunction was present in 44 patients. Fourteen of 44 patients had prior structural heart disease secondary to ischemic (n = 10), congenital (n = 2), dilated cardiomyopathy (n = 1), and valvular heart disease (n = 1). These patients were excluded owing to alternate potential mechanisms of impaired LV function. Therefore, 30 of 331 (10%) patients demonstrated cardiomyopathy secondary to focal AT. Of the patients considered to have TCM, the mean LVEF was 35 ± 11%. Echocardiographic assessment of LV function was undertaken during tachycardia in 27 of 30 patients. Of the 30 patients with TCM, 12 underwent echocardiography within 48 h after the ablation procedure. Eleven of 12 patients were in tachycardia during the pre-ablation echocardiogram, and all post-ablation echocardiograms were performed in sinus rhythm. The mean heart rate during the pre-ablation echocardiogram for these 12 patients was 110 ± 19 beats/min. There was no significant difference between LVEF pre-ablation versus the immediate post-ablation echocardiogram (LVEF 36 ± 10% vs. 39 ± 10%, p = 0.5). The clinical characteristics of the patient population with TCM are presented in Table 1.

Tachycardia characteristics. Comparisons between patients with and without TCM are presented in Table 2. The TCM group was younger (mean age of 39 ± 22 years, range 9 to 81 years, vs. 51 ± 17 years, range 15 to 85 years; p = 0.0006) and was significantly more likely to be male (60% vs. 38%, p < 0.001) (Table 2). There was no significant difference in symptom duration or use of antiarrhythmic drugs between the 2 groups.

Table 2 Clinical Characteristics of Patients With and Without TCM

	TCM (n = 30)	No TCM (n = 301)	p Value
Age, yrs	39 ± 22	51 ± 17	0.0006
Male	60	38	<0.001
Incessant/very frequent paroxysmal	100	20	<0.001
Antiarrhythmic drugs	1.4 ± 1.3	1.5 ± 1.1	0.7
Symptom duration, yrs	6 ± 7	6 ± 8	0.9
TCL, ms	502 ± 131	402 ± 105	<0.0001
HR, beats/min	117 ± 21	141 ± 33	0.0007
Pre-ablation LVEF, %	35 ± 11	59 ± 1	<0.0001

Values are % or mean ± SD.
 HR = heart rate; TCM = tachycardia-mediated cardiomyopathy; other abbreviations as in Table 1.

There were significant differences in the TCL of the ectopic AT, and also of the ventricular rate during tachycardia, between patients with and without TCM. Patients with TCM had a longer mean atrial TCL and slower ventricular rate during tachycardia than did patients without TCM (TCL 502 ± 131 ms vs. 402 ± 105 ms, p < 0.0001; and ventricular rate 117 ± 21 beats/min vs. 141 ± 33 beats/min, p = 0.0007) (Table 2).

Incessant or frequent paroxysmal tachycardia was significantly associated with TCM compared with patients who had normal LV function (100% vs. 20%, p < 0.001). Incessant tachycardia was present in 27 of 30 patients with TCM: very frequent paroxysmal tachycardia separated by short episodes (>2 beats) of sinus rhythm was present in 2 patients, and 1 patient had LV dysfunction (EF 36%) after a 5-year history of incessant atrial ectopy with normal ventricular function. This unusual presentation followed persistent atrial bigeminy/trigeminy on electrocardiography and Holter monitoring, although sustained tachycardia was not present. After the development of cardiomyopathy, catheter ablation was performed at the ostium of the coronary sinus. After successful ablation of the ectopic foci, there was complete recovery of LV function in this patient with frequent isolated ectopy.

Sixteen of the 30 foci that resulted in TCM originated from either the atrial appendages (n = 8) or the pulmonary veins (n = 8). This reflected the frequent occurrence of incessant tachycardias from these anatomic sites.

Incessant AT. Overall, incessant AT occurred in 82 of 331 (25%) patients (Table 3). The TCM occurred in 30 of 82 (37%) patients with incessant tachycardia. A comparison of the characteristics of patients with incessant AT who had TCM with those of patients who also had incessant AT but did not have TCM showed the following: 1) incessant AT patients with TCM were similar in age (mean age 39 ± 22 years) and sex (60% male) to incessant AT patients without TCM (mean age 45 ± 18 years, p = 0.2; 54% male, p = 0.8); 2) symptom duration was not significantly different between incessant AT patients with TCM (6 ± 7 years) and without TCM (4 ± 6 years, p = 0.5); and 3) in incessant AT patients with TCM, the TCL was longer (502 ± 131 ms) and ventricular response rate was slower (mean heart rate 117 ± 21 beats/min) than in patients who did not have

Table 3 Anatomic Sites of Origin of Focal Atrial Tachycardia for Entire Study Population

	PV (n = 44)	MA (n = 13)	AA (n = 19)	Perinodal (n = 40)	CS (n = 27)	CT (n = 85)	TA (n = 53)	Multi (n = 28)
Male	50 (22)	8 (1)	79 (15)	45 (18)	59 (16)	18 (15)	47 (25)	36 (10)
Age, yrs	38 ± 16	53 ± 16	33 ± 18	50 ± 14	40 ± 22	56 ± 13	48 ± 20	57 ± 14
Incessant	59 (26)	0 (0)	84 (16)	20 (8)	11 (3)	6 (5)	32 (17)	25 (7)
Tachycardia-mediated cardiomyopathy	18 (8)	0 (0)	42 (8)	5 (2)	4 (1)	4 (3)	6 (3)	18 (5)

Values are % (n) or mean ± SD.

MA = mitral annulus; other abbreviations as in Table 1.

TCM (TCL 446 ± 106 ms, p = 0.05; and heart rate 132 ± 33 beats/min, p = 0.05).

The incidence of incessant AT and incidence of TCM as per anatomic site of origin is presented in Table 3. Common anatomic sites of incessant tachycardia were the atrial appendages (n = 16 of 19; 84%) and pulmonary vein ostia (n = 26 of 44; 59%) (Fig. 1). These sites also had a high incidence of associated TCM (Table 3). Cardiomyopathy developed in 8 of 19 (42%) patients with tachycardia originating from the right or left atrial appendages, and in 8 of 44 (18%) patients with a pulmonary vein origin, significantly higher than from other anatomic locations (14 of 238; 6%; p = 0.008).

RFA. Catheter ablation was attempted in 303 of 345 patients. Ablation was not attempted in the remaining 42 owing to insufficient activity (n = 22), close proximity to the

atrioventricular (AV) node (n = 12), and multiple changing morphologies (n = 8). Acute success in patients for whom RF was pursued was achieved in 272 of 303 (90%) patients. In patients with TCM, success without use of medication was achieved in 26 of 30 (87%) patients at mean follow-up of 23 ± 21 months. Of the other 4 patients, 2 with right atrial appendage tachycardia had recurrence of post-ablation tachycardia and are now successfully controlled with drugs with normalization of LV function; 1 patient had incessant multifocal tachycardia unable to be mapped and eliminated with RFA, and this patient has been only partially controlled with medication; and 1 83-year-old patient had subsequent pacemaker implantation and AV node ablation.

Recovery of LV function. Left ventricular function returned to normal in 29 of 30 (97%) patients at 2.8 ± 2 months after successful ablation (Fig. 2). One now 20-year-

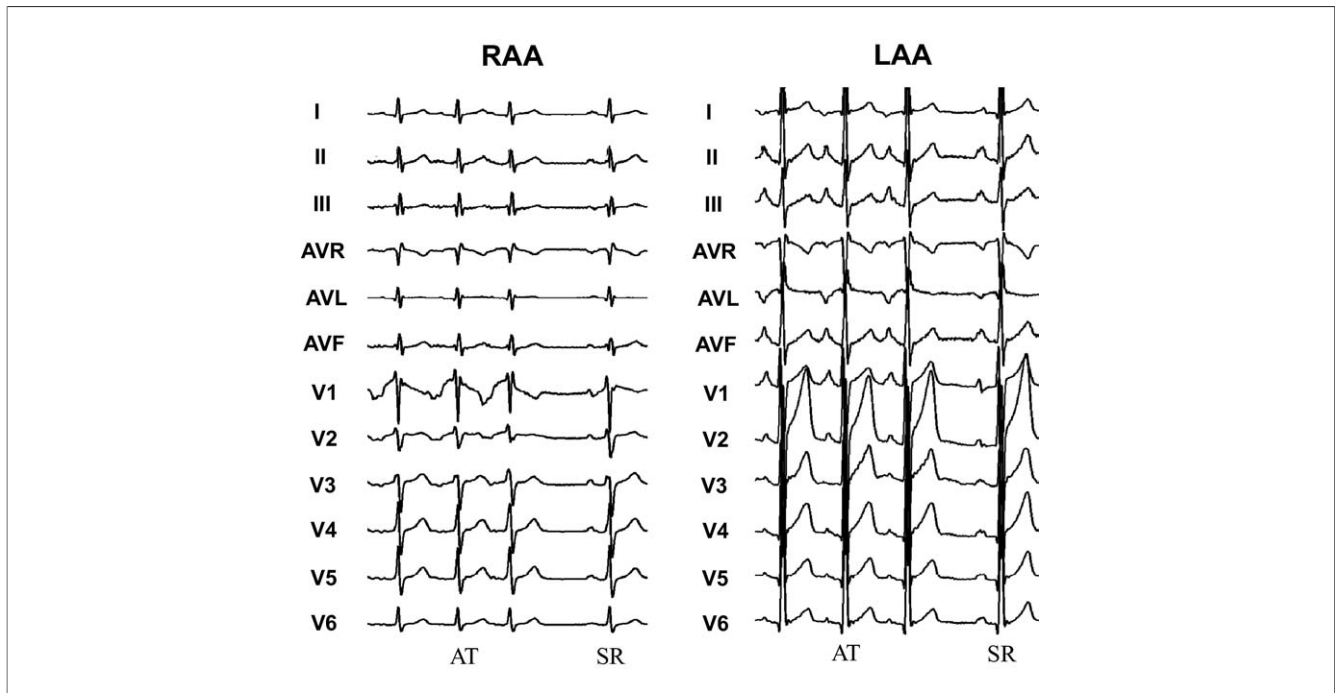


Figure 1 Tachycardia P Waves With Sinus Rhythm in 2 Patients With Incessant AT

(Left) This patient was a 53-year-old man who presented with a 6-month history of palpitations. Left ventricular ejection fraction was normal. In atrial tachycardia (AT), the P-wave is broad, inverted, and notched in leads V₁ and V₂ and positive in leads II, III, and avF. Electrophysiology study revealed an origin at the base of the right atrial appendage (RAA), and radiofrequency ablation was successful in terminating the tachycardia. (Right) This patient was a 32-year-old asymptomatic woman in incessant tachycardia. The P-wave in tachycardia is bifid positive in the inferior leads, broad and positive in leads V₁ through V₆, and negative in lead I. Tachycardia was successfully ablated at the origin of the left atrial appendage (LAA). SR = sinus rhythm.

old male who presented with incessant tachycardia soon after birth has persistent LV dysfunction. Previous attempts at RFA were unsuccessful owing to multiple changing foci of tachycardia. Partial control of tachycardia with medical therapy has led to an improvement in LV function, from severe (LVEF 22%) to mildly impaired (LVEF 40% to 59%). There have been no instances of syncope or sudden cardiac death in the TCM group at a mean follow-up of 20 ± 28 months.

Discussion

This study provides a detailed description of cardiomyopathy secondary to focal atrial tachycardia in a large patient cohort with long-term follow-up. The important findings were as follows: 1) 30 of 82 (37%) patients with incessant tachycardia presented with a TCM (30 of 331 patients, representing 10% of the atrial tachycardia cohort); 2) anatomic sites with a predilection for incessant tachycardia (the atrial appendages and pulmonary veins) were most frequently complicated by LV dysfunction; and 3) successful catheter ablation was achieved in 26 of 30 patients. Successful control with drugs was achieved in 3 of the 4 remaining patients; an 83-year-old patient with an incessant parahisian tachycardia proceeded to pacemaker implantation and AV node ablation. Therefore, complete recovery of LV function was obtained in 29 of 30 (97%) patients. There were no late adverse events in long-term follow-up.

Animal studies of TCM. In tachypacing-induced animal models of heart failure, an increasing rate, longer duration, and type of tachycardia are primarily responsible for the development of myopathic change (14). Constant or incessant rapid pacing at a pre-defined fixed rate is generally used for the induction of the cardiomyopathic state. In contrast, tachyarrhythmias in humans, even when incessant, demonstrate significant variability related to diurnal variation and

autonomic tone. This is an important consideration when bridging the gap from “bench to bedside” in interpreting the findings from animal models (2). Notwithstanding these limitations, important insights into the pathophysiology of TCM have been determined.

Human studies of TCM. Tachycardia has been well described as an important cause of reversible LV dysfunction (15–17). The incidence of TCM is poorly defined and likely underestimated. In patients with unexplained cardiomyopathy, approximately 50% (18,19) have been classified as idiopathic. Kasper et al. (18) reported that, of 673 consecutive patients with presumed dilated cardiomyopathy, 1 case was attributed to tachycardia (18). That is likely to be an underestimate, particularly among patients with atrial fibrillation and dilated cardiomyopathy in whom uncontrolled tachycardia may cause or exacerbate heart failure (20). In addition, children with permanent junctional reciprocating tachycardia appear vulnerable to the development of LV dysfunction, with 24 of 85 (28%) children affected in 1 series (21). TCM has also rarely been reported to complicate other frequent paroxysmal or persistent supraventricular tachycardias, including AV nodal re-entry tachycardia and AV re-entrant tachycardias (1,16,22). The diagnosis of AT may be challenging, particularly at ventricular rates of 110 beats/min as presented in the current study. Differentiating sinus tachycardia from AT may be difficult, with tachycardia considered an “appropriate” compensatory response to LV dysfunction. In the majority of instances, an analysis of P-wave morphology will readily rule out a sinus mechanism. However, foci arising from the crista terminalis or from right-sided pulmonary veins may have a P-wave morphology indistinguishable from a sinus P-wave and lead to an incorrect diagnosis of compensatory sinus tachycardia (8).

In the present study, cardiomyopathy developed in one-third of patients with incessant AT. When compared with all patients with AT who did not have a cardiomyopathy, patients with TCM demonstrated a longer atrial TCL and ventricular response. Patients with rapid paroxysmal AT may be more likely to be symptomatic with palpitations and more aware of tachycardia episodes. More rapid tachycardia is likely to be appropriately diagnosed and not mistaken for sinus tachycardia. Patients with rapid AT may, therefore, be recognized earlier and given more rapid treatment, leaving less time for TCM to develop. By contrast, patients with slower incessant tachycardia may not present early with palpitations, but rather, later with symptoms of cardiac failure.

When a comparison was made between patients with incessant tachycardia in whom cardiomyopathy did or did not develop, similar differences in cycle length and ventricular response were observed. Symptom duration (although notoriously difficult to assess), age at presentation, and sex were not significantly different. Alternate factors beyond tachycardia rate (and possibly duration) are likely important in the predisposition to LV dysfunction.

In the present study, foci arising from the atrial appendages and pulmonary veins were frequently incessant; how-

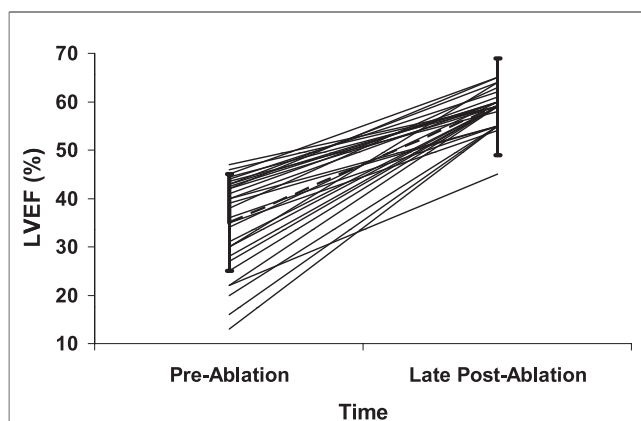


Figure 2 LVEF Before and After Ablation in Patients With TCM

A total of 27 of 30 patients with tachycardia-mediated cardiomyopathy (TCM) were in tachycardia during the initial echocardiographic assessment of left ventricular function. Pre-ablation left ventricular ejection fraction (LVEF) was $35 \pm 11\%$, improving to $59 \pm 3\%$ at 2.8 ± 2 months post-ablation.

ever, there was no significant difference in the likelihood of TCM developing according to site of origin if tachycardia was incessant. This observation suggests that the predilection for TCM to develop relates to the incessant nature of the focus rather than to the anatomical site of origin. Genetic factors influencing predisposition for TCM to develop may play an important role. Angiotensin-converting enzyme gene polymorphisms have been associated with TCM (23). A genotype containing a deletion allele is associated with elevated angiotensin-converting enzyme and angiotensin II concentrations (24). Deshmukh et al. (23) described an increase in the deletion/deletion genotype in incessant tachycardia patients with cardiomyopathy compared with normal LV function. This overexpression of the renin-angiotensin system may account for an individual predisposition to develop cardiomyopathy in the context of incessant tachycardia in some patients.

A high burden of ventricular ectopic activity has been shown to result in LV dysfunction (25). In the present study, 1 patient had impaired ventricular function in response to frequent or "incessant" atrial ectopy. This is a highly unusual and rare case of frequent atrial ectopics resulting in cardiomyopathy, and this patient does not reflect the clinical outcomes of patients who have a high burden of atrial or ventricular ectopy seen on Holter monitoring.

Clinical implications. In our study population, incessant tachycardia occurred in approximately 25% of patients with focal AT, and TCM developed in approximately one-third of these patients. These tachycardia foci predominantly originated from the atrial appendages and from the pulmonary vein ostia. Successful RFA of atrial tachycardia foci was possible for the vast majority of these patients and resulted in complete reversibility of tachycardia-induced LV dysfunction. At a mean follow-up of almost 2 years, there were no late sudden deaths among this population.

Recovery of LV function after control of persistent tachycardia has been demonstrated for a range of different tachycardia mechanisms (15-17,26). However, recent data have suggested that there may be persistence of structural abnormalities even with return to normal ventricular function. Nerheim et al. (27) reported the long-term outcomes of 24 patients with complete recovery from TCM after control of differing cardiac arrhythmias. Five patients who had recurrence of atrial fibrillation had a very rapid recurrence of heart failure, suggesting that some structural LV abnormalities may have persisted. Three other patients, all of whom had recurrence of atrial fibrillation (1 had undergone AV node ablation), died suddenly months to several years later despite apparent preservation of LV function, again raising the possibility of persistent LV structural abnormalities (27). We cannot rule out the presence of persistent occult LV abnormalities in our population. However, our data suggest that, for patients undergoing curative ablation of focal AT, late arrhythmia recurrence is rare and the long-term prognosis is excellent.

Study limitations. The calculation of LV systolic function in the presence of a shortened diastolic filling time may result in an underestimate of LVEF. In this clinical study, we were unable to control for the effects of differences in heart rhythm in the assessment of LV function at baseline and after successful catheter ablation. In 27 of 30 (90%) patients, the echocardiography determination of baseline LV function was performed during tachycardia. We have included the findings from 12 patients in incessant AT who underwent an early repeat echocardiogram within 48 h after the restoration of sinus rhythm by catheter ablation. There was no significant difference between pre-ablation LVEF ($36 \pm 10\%$) and immediate post-ablation LVEF ($39 \pm 10\%$; $p = 0.5$).

Conclusions

TCM occurred in 10% of patients with focal AT. Incessant tachycardia is necessary for the development of TCM, and was seen in approximately one-third of the total population of patients with focal AT. Incessant tachycardias characteristically originated from the atrial appendages and pulmonary veins and had a significantly longer cycle length than did paroxysmal tachycardias, which did not result in cardiomyopathy. Long-term restoration of LV function can be achieved with successful control or elimination of tachycardia in the majority of patients.

Reprint requests and correspondence: Dr. Peter M. Kistler, Department of Cardiology, The Alfred Hospital, Melbourne 3004, Australia. E-mail: peter.kistler@bakeridi.edu.au.

REFERENCES

1. Packer DL, Bardy GH, Worley SJ, et al. Tachycardia-induced cardiomyopathy: a reversible form of left ventricular dysfunction. *Am J Cardiol* 1986;57:563-70.
2. Fenelon G, Wijns W, Andries E, Brugada P. Tachycardiomyopathy: mechanisms and clinical implications. *Pacing Clin Electrophysiol* 1996;19:95-106.
3. Chen SA, Chiang CE, Yang CJ, et al. Sustained atrial tachycardia in adult patients. Electrophysiologic characteristics, pharmacologic response, possible mechanisms and effect of radiofrequency ablation. *Circulation* 1994;90:1262-78.
4. Higa S, Tai CT, Lin YJ, et al. Focal atrial tachycardia: new insight from noncontact mapping and catheter ablation. *Circulation* 2004;109:84-91.
5. Armstrong PW, Stopps TP, Ford SE, De Bold AJ. Rapid ventricular pacing in the dog: pathophysiologic studies of heart failure. *Circulation* 1986;74:1075-84.
6. Saoudi N, Cosio F, Waldo A, et al. Classification of atrial flutter and regular atrial tachycardia according to electrophysiologic mechanism and anatomic basis: a statement from a joint expert group from the Working Group of Arrhythmias of the European Society of Cardiology and the North American Society of Pacing and Electrophysiology. *J Cardiovasc Electrophysiol* 2001;12:852-66.
7. Kistler PM, Sanders P, Fynn SP, et al. Electrophysiological and electrocardiographic characteristics of focal atrial tachycardia originating from the pulmonary veins acute and long-term outcomes of radiofrequency ablation. *Circulation* 2003;108:1968-75.
8. Kistler PM, Roberts-Thomson KC, Haqqani HM, et al. P-wave morphology in focal atrial tachycardia: development of an algorithm to predict the anatomic site of origin. *J Am Coll Cardiol* 2006;48:1010-7.

9. Kalman JM, Olgin JE, Karch MR, Hamdan M, Lee RJ, Lesh MD. "Cristal tachycardias": origin of right atrial tachycardias from the crista terminalis identified by intracardiac echocardiography. *J Am Coll Cardiol* 1998;31:451-9.
10. Morton JB, Sanders P, Das A, Vohra JK, Sparks PB, Kalman JM. Focal atrial tachycardia arising from the tricuspid annulus: electrophysiologic and electrocardiographic characteristics. *J Cardiovasc Electrophysiol* 2001;12:653-9.
11. Kistler PM, Sanders P, Hussin A, et al. Focal atrial tachycardia arising from the mitral annulus: electrophysiologic and electrophysiologic characterization. *J Am Coll Cardiol* 2003;41:2212-9.
12. Fynn SP, Morton JB, Deen VR, et al. Conduction characteristics at the crista terminalis during onset of pulmonary vein atrial fibrillation. *J Cardiovasc Electrophysiol* 2004;15:855-61.
13. Morton JB, Sanders P, Das A, Vohra JK, Sparks PB, Kalman JM. Focal atrial tachycardia arising from the tricuspid annulus: electrophysiologic and electrocardiographic characteristics. *J Cardiovasc Electrophysiol* 2001;12:653-9.
14. Zupan I, Rakovec P, Budihna N, Breclj A, Kozelj M. Tachycardia induced cardiomyopathy in dogs; relation between chronic supraventricular and chronic ventricular tachycardia. *Int J Cardiol* 1996;56:75-81.
15. Yarlagadda RK, Iwai S, Stein K, et al. Reversal of cardiomyopathy in patients with repetitive monomorphic ventricular ectopy originating from the right ventricular outflow tract. *Circulation* 2005;112:1092-7.
16. Cruz FE, Cheriex EC, Smeets JL, et al. Reversibility of tachycardia-induced cardiomyopathy after cure of incessant supraventricular tachycardia. *J Am Coll Cardiol* 1990;16:739-44.
17. Noe P, Van Driel V, Wittkamp F, Sreeram N. Rapid recovery of cardiac function after catheter ablation of persistent junctional reciprocating tachycardia in children. *Pacing Clin Electrophysiol* 2002;25:191-4.
18. Kasper EK, Agema WR, Hutchins GM, Deckers JW, Hare JM, Baughman KL. The causes of dilated cardiomyopathy: a clinicopathologic review of 673 consecutive patients. *J Am Coll Cardiol* 1994;23:586-90.
19. Felker GM, Thompson RE, Hare JM, et al. Underlying causes and long-term survival in patients with initially unexplained cardiomyopathy. *N Engl J Med* 2000;342:1077-84.
20. Prystowsky EN. Assessment of rhythm and rate control in patients with atrial fibrillation. *J Cardiovasc Electrophysiol* 2006;17 Suppl:7-10.
21. Vaksman G, D'Hoinne C, Lucet V, et al. Permanent junctional reciprocating tachycardia in children: a multicentre study on clinical profile and outcome. *Heart* 2006;92:101-4.
22. Furushima H, Chinushi M, Sugiura H, et al. Radiofrequency catheter ablation for incessant atrioventricular nodal reentrant tachycardia normalized H-V block associated with tachycardia-induced cardiomyopathy. *J Electrocardiol* 2004;37:315-9.
23. Deshmukh PM, Pramod M, Krishnamani R, Romanyshyn M, Johnson AK, Noti JD. Association of angiotensin-converting enzyme gene polymorphism with tachycardia cardiomyopathy. *Int J Mol Med* 2004;13:455-8.
24. Nakai K, Itoh C, Miura Y. Deletion polymorphism of the angiotensin-I converting enzyme gene is associated with serum ACE concentration and increased risk for CAD in the elderly. *Circulation* 1994;90:2199-202.
25. Rhee KH, Jung JY, Rhee KS, et al. Tachycardiomyopathy induced by ventricular premature complexes: complete recovery after radiofrequency catheter ablation. *Korean J Intern Med* 2006;21:213-7.
26. Heinz G, Siostrzonek P, Kreiner G, Gossinger H. Improvement in left ventricular systolic function after successful radiofrequency His bundle ablation for drug refractory, chronic atrial fibrillation and recurrent atrial flutter. *Am J Cardiol* 1992;69:489-92.
27. Nerheim P, Birger-Botkin S, Piracha L, Olshansky B. Heart failure and sudden death in patients with tachycardia-induced cardiomyopathy and recurrent tachycardia. *Circulation* 2004;110:247-52.

Key Words: atrial tachycardia ■ cardiomyopathy ■ tachycardia-mediated cardiomyopathy.