



## American Brachytherapy Society—Groupe Européen de Curiethérapie—European Society of Therapeutic Radiation Oncology (ABS-GEC-ESTRO) consensus statement for penile brachytherapy

Juanita M. Crook<sup>1,\*</sup>, Christine Haie-Meder<sup>2</sup>, D. Jeffrey Demanes<sup>3</sup>, Jean-Jacques Mazeron<sup>4</sup>, Alvaro A. Martinez<sup>5</sup>, Mark J. Rivard<sup>6</sup>

<sup>1</sup>Department of Radiation Oncology, British Columbia Cancer Agency, Center for the Southern Interior, Kelowna, BC, Canada

<sup>2</sup>Department of Radiation Oncology, Institut Gustave-Roussy, Villejuif, France

<sup>3</sup>Department of Radiation Oncology, UCLA Medical Center, Los Angeles, CA

<sup>4</sup>Department of Radiation Oncology, Hôpital Pitié-Salpêtrière, Paris, France

<sup>5</sup>Michigan Healthcare Professionals, 21st Century Oncology, Farmington Hills, MI

<sup>6</sup>Department of Radiation Oncology, Tufts University School of Medicine, Boston, MA

### ABSTRACT

**PURPOSE:** To develop a consensus statement between the American Brachytherapy Society (ABS) and Groupe Européen de Curiethérapie/European Society for Therapeutic Radiation and Oncology (GEC-ESTRO) for the use of brachytherapy in the primary management of carcinoma of the penis.

**METHODS AND MATERIALS:** The American Brachytherapy Society and Groupe Européen de Curiethérapie/European Society for Therapeutic Radiation and Oncology convened a group of expert practitioners and physicists to develop a statement for the use of <sup>192</sup>Ir in low-dose-rate (LDR), pulse-dose-rate, and high-dose-rate (HDR) brachytherapy for penile cancer.

**RESULTS:** Decades of brachytherapy experience with LDR <sup>192</sup>Ir wire and pulse-dose-rate <sup>192</sup>Ir sources for this rare malignancy indicate a penile preservation rate of 70% at 10 years postimplant. Chief morbidities remain stenosis of the urethral meatus and soft tissue ulceration at the primary site. Nonhealing ulceration can be successfully managed with various measures including hyperbaric oxygen treatment. HDR brachytherapy implant procedures are technically similar to LDR. The optimal HDR dose and fractionation schemes are being developed.

**CONCLUSIONS:** The good tumor control rates, acceptable morbidity, and functional organ preservation warrant recommendation of brachytherapy as the initial treatment for invasive T1, T2, and selected T3 penile cancers. © 2013 American Brachytherapy Society. Published by Elsevier Inc. All rights reserved.

### Keywords:

Penile carcinoma; Interstitial brachytherapy; Low-dose-rate brachytherapy; Pulse-dose-rate brachytherapy; High-dose-rate brachytherapy

### Introduction

The Board of the American Brachytherapy Society (ABS) invited a leading author in the field (JMC) to draft a statement for penile brachytherapy with international participation. CH-M was invited to coauthor the statement.

Received 6 July 2012; received in revised form 30 November 2012; accepted 10 January 2013.

\* Corresponding author. Department of Radiation Oncology, British Columbia Cancer Agency Cancer, Center for the Southern Interior, 399 Royal Avenue, Kelowna, BC V1Y 5L3, Canada. Tel.: +1-250-712-3979; fax: +1-250-712-3911.

E-mail address: [jcrook@bccancer.bc.ca](mailto:jcrook@bccancer.bc.ca) (J.M. Crook).

Subsequently, review and input were sought from those practitioners personally known to have experience in the field (AAM, DJD, and JJM). The final draft was approved by the ABS Board of Directors and by the Groupe Européen de Curiethérapie and the European Society of Therapeutic Radiation and Oncology Council. Literature review revealed an absence of randomized studies. One multicenter retrospective review from Rozan *et al.* (1) in France and a handful of reported series from single institutions provide Level 3 evidence. Nonetheless we believe this consensus statement will provide valuable guidance.

Squamous cell carcinoma of the penis is a relatively rare malignancy in the developed world, with an incidence of

approximately 1 per 100,000 men (2), although much higher in some third world countries being more than 4 per 100,000 in Paraguay (3), and cited as up to 1% by age of 75 years in some parts of Uganda (4). It is highly curable in its early stages. Surgical amputation (penectomy) is often the first or only treatment method considered, but traditional amputative surgery is associated with a high level of psychosexual morbidity (5–7). Surgery, however, is not the only potentially curative treatment. Organ-sparing definitive radiation therapy, with or without local resection, can provide both cure and a high rate of penile preservation. Many urologists may only see one or two cases in a lifetime of practice, so awareness of this therapeutic alternative may be limited. Because penile-sparing approaches are being used more frequently in centers with experience, referral to such centers is recommended. This review is designed to inform radiation oncologists, urologists, and other physicians about the role of radiation therapy in the treatment of carcinoma of the penis.

### Patient evaluation

Carcinoma of the penis is most frequently located on the glans and prepuce (8). It occurs much more frequently in uncircumcised men, although human papillomavirus-associated cases have been reported in men circumcised as neonates (9). The first step in evaluation is to obtain a tissue biopsy, preferably deep enough to show the extent of invasion (10). Next, one must ensure full visibility of the lesion, which is often hidden under a phimotic foreskin (11). This step consists of either circumcision or a dorsal slit incision to expose the lesion, prevent soft tissue strangulation and tissue necrosis, and to promote hygiene. When possible, along with circumcision, local tumor excision can be performed to remove gross tumor and necrotic debris. These excisions must be done in a manner that preserves the cosmetic and functional integrity of the penis. Wound healing is usually adequate to allow brachytherapy to proceed within 10–14 days.

A complete history and physical examination to assess comorbidities and a workup to rule out metastatic disease are needed. Particular attention should be given to the

relationship of the lesion to the urethra and the clinical status of the inguinal lymph nodes, which are the primary lymphatic drainage of the penis. Brachytherapy requires anesthesia and usually involves 5–6 days of hospitalization. The patient's general health, including cardiorespiratory status, the presence of diabetes as a risk for delayed healing, and the relative risk for thromboembolic disease should all be assessed before the procedure. Imaging should include a chest X-ray and CT scan of the abdomen and pelvis to evaluate the regional lymph nodes and rule out distant metastasis. A CT scan is especially helpful for men with higher body mass index where groin palpation is less reliable in detecting adenopathy. All cases with moderately or poorly differentiated disease, or clinical stage T2 or higher should have CT or positron emission tomography–CT staging. Clinical evaluation of the primary tumor may underestimate the depth of invasion, especially if biopsies are relatively superficial. Therefore, imaging of the penis with either ultrasound or MRI with prostaglandin-induced erection can be helpful in determining the extent of the primary tumor and its relationship to the urethra. This information can assist in brachytherapy catheter placement (12, 13).

### Patient selection

The disease staging system in Table 1 is the TNM Seventh edition (2010) from the American Joint Committee on Cancer Cancer Staging Manual (14). Stage Tis, Ta, or T1a can be dealt with effectively using superficially ablative, penile-sparing modalities such as CO<sub>2</sub>–neodymium–yttrium–aluminum–garnet (YAG) laser (15, 16). Such early superficial lesions are usually not managed with brachytherapy except in the case of recurrent or persistent disease. Tumors that are of clinical stage T1b or T2 and less than 4 cm in maximum diameter are most suitable for primary brachytherapy. Lesions confined to the glans are ideal but those with minor extension across the coronal sulcus are also suitable provided the extension can be covered with no more than one additional plane of needles. If larger lesions are treated, especially those extending into the corpora cavernosa, it must be understood by the patient and referring physicians that there is higher risk of local

Table 1  
TNM primary tumor and clinical nodal staging

Tx: primary tumor cannot be assessed	Nx: nodes cannot be assessed
T0: no evidence of primary tumor	N0: no palpable nodes or visible enlargement from imaging
Tis: carcinoma <i>in situ</i>	N1: palpable mobile unilateral inguinal node
Ta: noninvasive verrucous carcinoma	N2: palpable mobile multiple or bilateral inguinal nodes
T1a: subepithelial connective tissue invasion, but no lymph vascular invasion and not poorly differentiated	N3: palpable fixed inguinal nodal mass or pelvic lymphadenopathy, unilateral or bilateral
T1b: subepithelial connective tissue invasion with lymphovascular invasion and/or poorly differentiated	
T2: corpus spongiosum or cavernosum invasion	
T3: urethral invasion	
T4: invades other adjacent structures	

Based on the American Joint Committee on cancer of penile carcinoma (2010).

failure and complications (17). Lesions otherwise suited to brachytherapy for management of the primary tumor may present with early adenopathy or require sentinel lymph node evaluation or inguinal node dissection. A combined approach of brachytherapy for the primary and surgical evaluation of lymph nodes can be considered.

T3 tumors with extension into the penile urethra are generally not optimal candidates for brachytherapy, although those cases where urethroscopy reveals submucosal deformity without mucosal disruption may still be treated with success, although there is however an increased risk of meatal stenosis that should be explained and understood by the patient. If a locally advanced primary tumor presents with concomitant adenopathy, brachytherapy is unlikely to play a role in management and combinations of external beam radiotherapy (EBRT) with chemotherapy ± surgery should be considered (18).

Tumor grade is not an exclusion factor for brachytherapy (19). In the 74 cases treated by Crook *et al.* (19) between 1989 and 2007, half had well-differentiated and the other half had moderately or poorly differentiated cancer. Moderately and poorly differentiated tumors responded as well as those that were well differentiated. Local recurrences occurred in six well-differentiated and two moderate-to-poorly differentiated cases.

**Technical aspects**

Penile brachytherapy is not a treatment modality that needs to be available in every radiotherapy department. A high volume and varied brachytherapy practice that undertakes interstitial brachytherapy for other tumor sites may wish to provide this treatment as the basic principles are not dissimilar to those for other interstitial implants. As this is an uncommon tumor, three to six

cases per year are sufficient to justify a program. Collaboration with a penile carcinoma center of excellence is recommended.

Penile brachytherapy can be performed under general anesthesia or penile block with systemic sedation. Antibiotic prophylaxis is optional. Low-dose-rate (LDR) brachytherapy consists of either manually afterloaded <sup>192</sup>Ir or pulse-dose-rate (PDR) brachytherapy. The latter uses automated afterloading with a high-intensity <sup>192</sup>Ir source to deliver hourly pulses. The two are similar in implant principles and total dose. These implants should be clinically designed according to the anatomic extent of tumor. Knowledge of the Paris system of dosimetry (20) as shown in Fig. 1 is a helpful guide for placement of sources so that the prescription isodoses will encompass the visible and palpable tumor with an appropriate margin. Because the depth of invasion is often underappreciated, margins should be generous and of 10 mm or greater in all directions around the gross tumor volume to delineate the clinical target volume.

The implant may be performed with a template or, if properly stabilized, with other multicatheter interstitial methods. The first step is insertion of a Foley catheter to assist in urethral localization. Although the urethra can be bracketed quite closely by the implant needles, it is essential to avoid transfixing it. The afterloading devices (carrier needles or catheters) are inserted in parallel planes with equal spacing to create a uniform volume implant orthogonally to the longitudinal direction of the penis. Single-plane implants are discouraged because the isodose at a depth will be scalloped and may result in underdose to a part of the tumor. Generally, two to three planes of needles or catheters are sufficient (21). For the template technique, individual needles (19.5 gauge for LDR and 17.5 gauge for PDR) are held in a parallel array using predrilled Lucite or plexiglass templates. When using brachytherapy

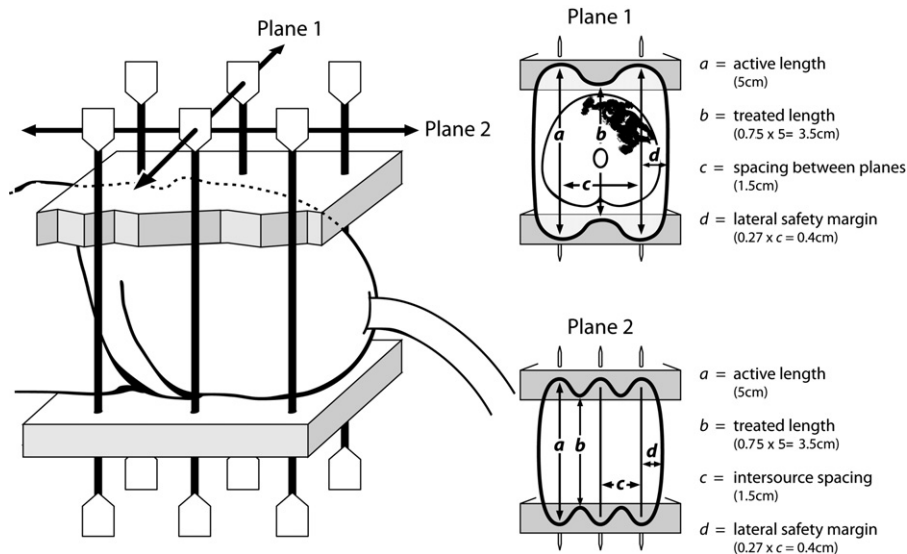


Fig. 1. Schematic of a two-plane, six-needle implant showing the prescription isodose coverage according to the Paris system rules.

catheters, the applicators are stabilizing devices such as Jackson–Pratt drains or fixing buttons. Appropriate spacing is chosen to cover the lesion, avoid the urethra, and provide an adequate margin. For LDR or PDR implants, spacing of 12–18 mm is acceptable, but 14–16 mm is preferred. Spacing should be equivalent between adjacent needles and planes of needles. It should be noted that the closer the spacing, the less the lateral margin of high dose coverage lateral to the needles. Exterior planes of needles or “plesiocurietherapy” (i.e., placed in space outside the penis) can be used to ensure adequate coverage of the surface and allow the most superficial of the “in-tissue” planes to be deep enough to avoid scarring or necrosis from sources being too close to the skin. Tissue-equivalent bolus is placed between the exterior plane and the tissue surface to provide adequate radiation scatter (Fig. 2).

The high-dose-rate (HDR) implant procedure is technically similar to the LDR brachytherapy, but it is not essential for the catheters to exactly follow a particular spacing system because source loading and dwell time adjustments (dosimetry optimization) can be used to modulate the intensity of the radiation within the treatment volume within a certain range. Closer spacing is preferable for the HDR technique, generally 10–12 mm between needles or catheters because it improves the control and uniformity of the dosimetry. For instance, to minimize central dose to the urethra, periurethral needles can be more widely separated. A template that accommodates this flexibility is shown in Fig. 3. Holes are drilled on 3-mm centers (the closest possible to still have the enough template material between the holes for strength) allowing the needles to be spaced 9 or 12 mm apart as required. The bridge keeps the two templates parallel at all times. The parallel planes of needles can be either staggered or superimposed. Similar catheter spacing considerations can be applied to other stabilization techniques.

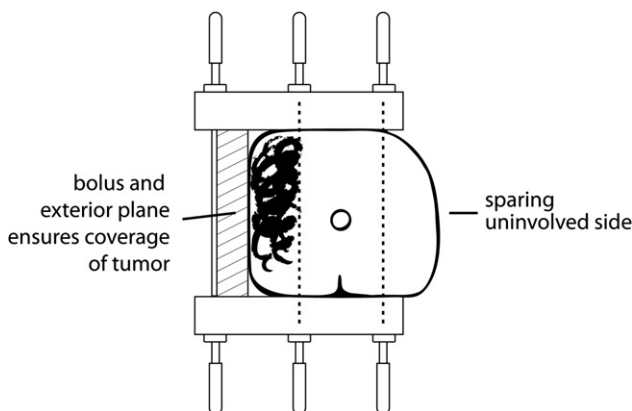


Fig. 2. A unilateral tumor allows some sparing of uninvolved glans. An exterior plane of needles with bolus filling the gap to the penile surface allows dose coverage at the surface without having to position needles in tissue within 3 mm of the skin that can result in scarring and ulceration.

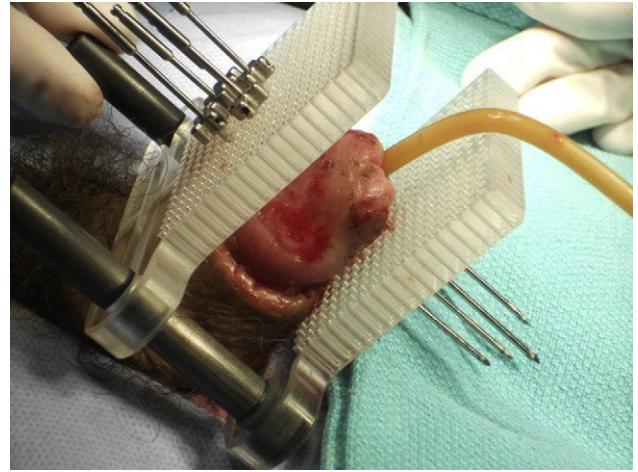


Fig. 3. High-dose-rate template with holes drilled on 3-mm centers to allow flexibility of spacing.

### Dosimetry

#### Dose prescription

*Low-dose-rate/pulse-dose-rate brachytherapy.* The rules of the Paris system are well described and are well suited to the template technique of penile brachytherapy (22). The placement of the sources is clinically based, and the completed implant is stable, which allows imaging for dose calculation to be omitted. Such an approach assumes that a standard implant distribution has been achieved, and is maintained, and that standard dose calculations are performed. Precise measurements, accurate to within 1 mm, must be taken of the spacing between the templates and of the active source lengths. The source placement for each needle is known and confirmed by measurement of the protrusion length of the needles on either side of the templates. Dose calculations are then done for this stable cubic array. In a nontemplate LDR or PDR technique, images are essential for dosimetry. With PDR treatment planning, some optimization can be introduced to minimize the dips of the isodoses between the needle planes in a template-guided technique (Fig. 4), or to compensate for unequal spacing in a nontemplate technique. According to the Paris system, prescription for LDR and PDR is to 85% of the dose rate minima between the planes. The LDR prescribed dose is generally 60 Gy at 0.5–0.6 Gy/h with the treatment completed in about 5 days. For PDR treatments, pulses equivalent to the hourly dose rate of an LDR implant are delivered every hour (23–25).

Where remote afterloading is not available, manual afterloading may be used with  $^{192}\text{Ir}$  radioactive sources in the form of thin wires or plastic ribbons with seeds. Sources are cut to the required length in the radioisotope room with strict radiation protection including use of extremity and whole body dosimeters, tweezers, and forceps for handling of sources, and protective body shields. After each source



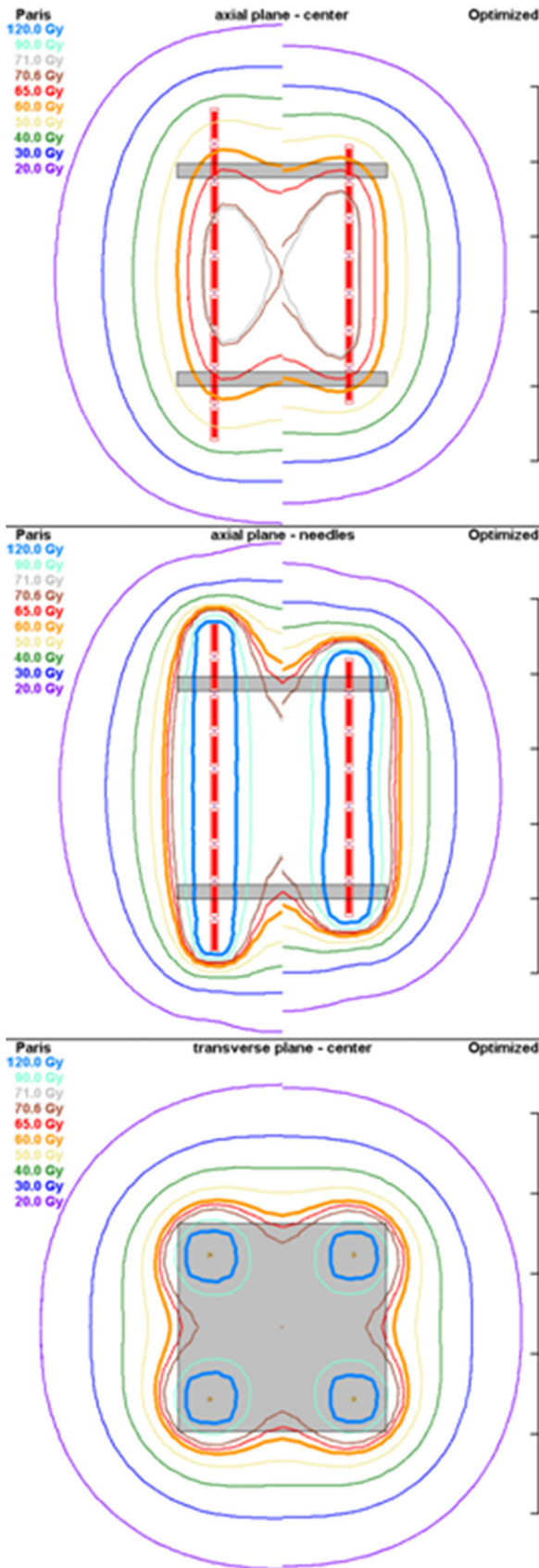


Fig. 4. Small glans can be covered with four needles without exceeding 18 mm spacing. Pulse-dose rate (PDR) allows some dose optimization that decreases the amount of dose reduction between the implant planes. At left

has been cut and put in a portable shielded container to be transported to the patient, the work area should be surveyed and the source inventory logbook updated. Sources may be loaded manually into the needles after the patient has been transferred to the shielded room on the ward or in the operating room. For a full discussion of source handling and precautions, see Ref. (21).

**High-dose-rate brachytherapy.** The literature on HDR <sup>192</sup>Ir brachytherapy for penile cancer is sparse. One published experience involved mainly single-plane implants and used twice daily fractions of 3.0 Gy to deliver 54 Gy over 9 consecutive days (26). Turning to unpublished experience from experts in the field (AAM and DJD), we concluded that fractionation of 3.2 Gy twice daily for a total of 38.4 Gy in 6 days for volume implants is well tolerated. The interval between fractions should be at least 6 h. Penile necrosis has been seen after doses of 42–45 Gy in 6 days (3.5–3.75 Gy × 12), but these doses may be tolerable if attention is paid to dose homogeneity and the V<sub>125</sub> (percentage of the planning target volume receiving 125% of the prescribed dose) is kept lower than 40% and the V<sub>150</sub> kept lower than 20%. To decrease the incidence of urethral strictures, the urethra V<sub>115</sub> should be 10% or less and the V<sub>90</sub> less than 95% of the volume. Dose constraints to the skin to minimize confluent areas greater than 125% of the prescription will reduce the risk of necrosis. CT-based planning is mandatory for HDR <sup>192</sup>Ir penile brachytherapy, with three-dimensional delineation of the gross tumor volume, clinical target volume, skin, and urethra (Fig. 5). For treatment planning purposes, the patient is scanned in the supine or lateral decubitus position. CT slice thickness less than 2 mm and in-plane resolution lower than 0.5 mm are recommended to provide high-resolution anatomic information and accurate needle localization. If there is concern for penile edema or needle positioning, repeat CT imaging may be performed during the course to validate the geometry.

**Postimplant management**

For LDR, PDR, or HDR, the patient remains in the hospital for the duration of the implant. Bed rest is recommended, but the implant is stable enough and often well enough tolerated that the patient may ambulate for personal necessities. The Jackson–Pratt drain or tube-and-button system allow more mobility. In general, these implants are well tolerated. Analgesia requirements may include narcotic and/or non-narcotic medications. Antibiotics are not routinely prescribed. The Foley catheter remains *in situ* for the duration of the implant. Careful hygiene of

in each dose diagram is a low-dose-rate distribution resultant from the Paris system of treatment planning using uniform source strength per unit length. At right is the dose distribution from an optimized treatment plan (PDR/high-dose rate) as used with modern computerized planning.

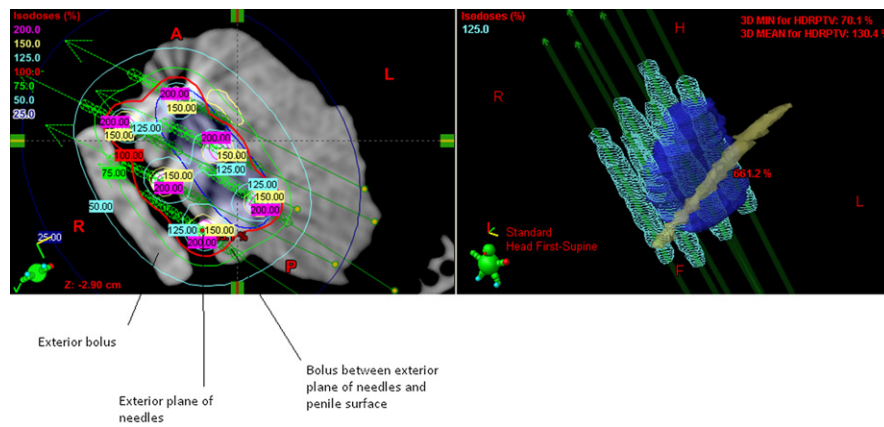


Fig. 5. High-dose-rate dosimetry for a six-needle implant with exterior plane and bolus. A second layer of bolus is placed lateral to (outside) the exterior plane (the exterior plane is sandwiched between two layers of bolus).

the implant device and urinary catheter is indicated. If the patient is disinclined to ambulate, then antiembolic stockings and low-dose heparin (5000 U every 12 h) or low-molecular-weight heparin are recommended as prophylaxis. The discontinuous pulses of PDR and HDR implants facilitate nursing care and minimize exposure to the personnel.

The implant can be removed either at the bedside with sufficient analgesia or in the operating room with sedation. Bleeding is usually minimal and can be controlled with the application of light pressure. The patient can be discharged the same day with home care instructions for hygiene, which include daily soaks of the distal penis in lukewarm water with the addition of baking soda or salt in a receptacle such as a coffee mug. Moist desquamation throughout the treated area is expected (Fig. 6) and usually starts within 10–15 days. A loose tubular non-stick dressing will prevent the healing skin from adhering to underclothes. The site should not be tightly bandaged with an occlusive dressing as this maneuver promotes infection and delays healing. Multiagent antibiotic cream or ointment

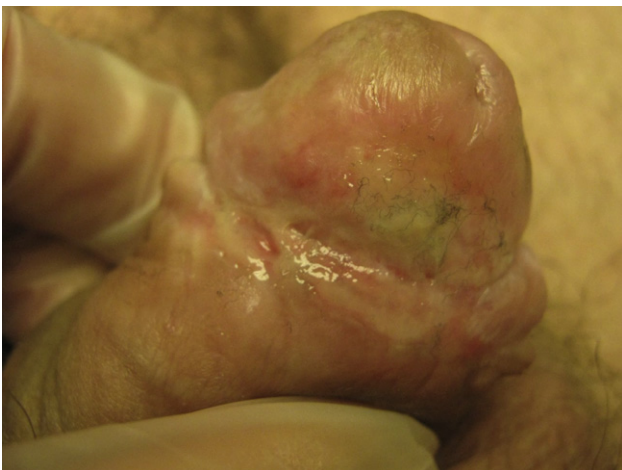

Fig. 6. Moist desquamation at 1 mo after high-dose-rate brachytherapy.

can be applied for the first 2–4 weeks, and some authors recommend that vitamin E ointment be applied later on as re-epithelialization progresses. Complete healing usually occurs within 2 months but in some cases may take 3–4 months or longer, especially in patients with diabetes or vascular disease. Smoking is discouraged as it is believed to delay wound healing. Intercourse can be resumed when the patient is comfortable, although the healing epithelium is fragile, and extra water-based lubrication is recommended.

## Clinical results

Table 2 shows a summary of the results in the literature for LDR/PDR brachytherapy. Two of the more noteworthy studies with large numbers of patients and mature followup from single centers are those from de Crevoisier *et al.* (27) and Crook *et al.* (19). In the report by Crook *et al.* (19), actuarial local control and penile preservation at 5 years were 87% and 88%, and at 10 years were 72% and 67%, respectively. de Crevoisier *et al.* (27) reported penile preservation of 72% at 10 years. Because local failures can occur even beyond 5 years, prolonged followup is mandatory. Of eight local failures, five occurred in the first 2 years and the remaining three at 4.5, 7, and 8 years (19). With continued surveillance, late local failures were successfully managed surgically such that the 10-year cause-specific survival was 84–90%. Grade is a strong predictor of disease-free survival ( $p = 0.005$ ). In the series of 67 patients of Crook *et al.* (19), 4% of well-differentiated tumors recurred regionally or distantly as compared with a 31% regional/distant recurrence rate for moderately or poorly differentiated tumors (19).

A common approach to nodal management is to perform clinical evaluation of the lymph nodes by palpation and CT staging. In cases that were clinically and radiographically node negative (N0), observation of the lymph nodes may be selected; however, the presence of subclinical

Table 2  
Clinical results of penile brachytherapy taken from the literature

References	Number of patients	Dose (Gy)	Mean followup in mo (range)	% 5-Y local control (y)	% 5-Y + cancer-specific survival (y) <sup>a</sup>	Complications	% Penile preservation (y)
Chaudhary <i>et al.</i> (32)	23	50	21 (4–117)	70 (8)		0% Necrosis and 9% stenosis	70 (8)
de Crevoisier <i>et al.</i> (27)	144	65	68 (6–348)	80 (10)	92 (10)	26% Necrosis and 29% stenosis	72 (10)
Crook <i>et al.</i> (19)	67	60	48 (6–194)	87 (5) 72 (10)	83.6 (10)	12% Necrosis and 9% stenosis	88 (5) 67 (10)
Delannes <i>et al.</i> (33)	51	50–65	65 (12–144)	86 crude	85	23% Necrosis and 45% stenosis	75
Kiltie <i>et al.</i> (34)	31	63.5	61.5	81	85.4	8% Necrosis and 44% stenosis	75
Mazeron <i>et al.</i> (17)	50	60–70	36–96+	78 crude		6% Necrosis and 19% stenosis	74
Rozan <i>et al.</i> (1)	184	63	139	86	88	21% Necrosis and 45% stenosis	78
Soria <i>et al.</i> (35)	102	61–70	111	77	72	Not stated	72 (6)

<sup>a</sup> Corrected for intercurrent deaths.

microscopic disease will go undetected in these cases, resulting in subsequent regional failure. Furthermore, delayed management of clinically suspicious lymph nodes after a 6-week course of antibiotics is also no longer advised. Rather, ultrasound-guided fine-needle aspiration for cytology can be used to investigate borderline or suspicious lymph nodes (28). Crook *et al.* (19) recommend surgical staging using either sentinel lymph node dissection, if the expertise is available, or modified inguinal lymphadenectomy (13, 29, 30) for all moderately or poorly differentiated cancers and for those well-differentiated tumors that are greater than 4 cm or at clinical stage T2 or higher. Dynamic sentinel lymph node dissection using patent blue dye and gamma emission reduces the false-negative rate to less than 5% in experienced centers. Suitable primary brachytherapy can be combined with surgical management of the lymph nodes in a multidisciplinary approach. Postoperative EBRT to the groins and pelvis can be offered to those patients with multiple involved nodes or the presence of extracapsular disease.

The most common late sequelae of penile brachytherapy are soft tissue ulceration and urethral meatal stenosis. Cosmesis is usually very good with minor areas of hypo- or hyperpigmentation or telangiectasia (Fig. 7). Fibrosis is limited to the area of the implant, and erectile function is usually maintained because the corpora and shaft have not been irradiated.

Nonhealing soft tissue ulceration beyond 3 months is reported in 6–26% of cases, and is dependent on dose, technique, and tumor stage and volume. For LDR or PDR brachytherapy, higher rates are associated with a higher prescribed dose of 65 Gy (27), whereas ulceration rates with 60 Gy are in the order of 12% (19). The risk is higher with tumors greater than 4 cm in diameter and with a larger number of needles. De Crevoisier *et al.* (27) have shown that two factors predictive of complications were dose rate higher than 0.6 Gy/h and treatment volume greater than 22 cm<sup>3</sup>. When using PDR, the dose rate can be adapted by increasing the pulse frequency and decreasing the pulse dose to keep the hourly dose rate at 0.6 Gy/h or lower.

Hyperbaric oxygen therapy can bring about speedy resolution of ulceration when more conservative measures fail,

although a prolonged series of “dives” over 6–8 weeks is required (31).

Meatal stenosis is reported in 9–45% (1), but is related to proximity of distal sources to the meatus. Crook *et al.* (19) reported a rate of 9%, but routinely supplied patients with a commercially available meatal dilator to be used as required to deal with any impairment of urinary stream. This may be beneficial in preventing problematic scarring of the meatus.

## Conclusions

Brachytherapy provides excellent local control of T1–T2 penile squamous cell carcinoma (and selected T3 lesions), ideally smaller than 4 cm with no or minimal extension onto the penile shaft. Circumcision preceding brachytherapy is essential. Penile conservation rates of 87% and 70% at 5 and 10 years, respectively, can be achieved with brachytherapy. Lymph node observation is appropriate for small (T1) well-differentiated tumors.

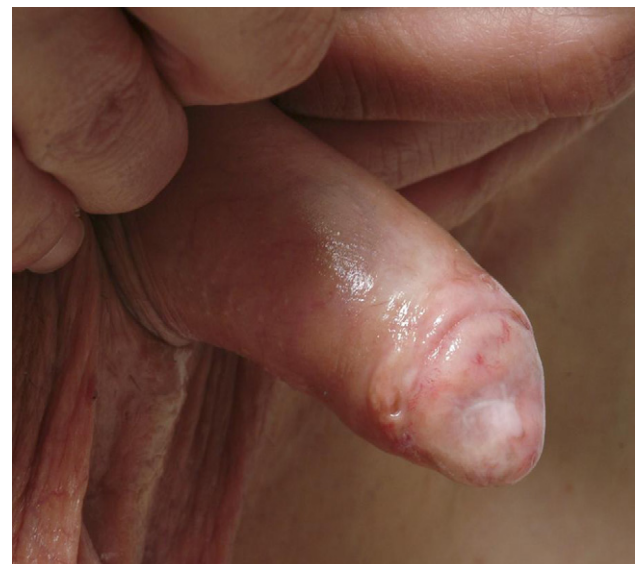

Fig. 7. Telangiectasia and area of hypopigmentation 6 years after pulse-dose-rate brachytherapy.



Radiographic assessment and directed biopsies are warranted in moderate or poorly differentiated or larger tumors. Although surgical management of positive or suspicious lymph nodes is preferred, EBRT is an option if the patient is not a surgical candidate. Because local recurrence can happen even after 5 years, extended followup is mandatory because both local and regional failures can be salvaged surgically. Meatal stenosis and soft tissue ulceration are the most common significant late effects, but can be effectively managed conservatively while retaining penis conservation. LDR and PDR <sup>192</sup>Ir brachytherapy fractionation is well established with mature data in the literature. HDR <sup>192</sup>Ir brachytherapy for penile cancer is under development.

## References

- [1] Rozan R, Albuissou E, Giraud B, et al. Interstitial brachytherapy for penile carcinoma: A multicentric survey (259 patients). *Radiother Oncol* 1995;36:83–93.
- [2] Jemal A, Siegel R, Ward E, et al. Cancer statistics, 2007. *CA Cancer J Clin* 2007;57:43–66.
- [3] Bleeker MC, Heideman DA, Snijders PJ, et al. Penile cancer: Epidemiology, pathogenesis and prevention. *World J Urol* 2009;27:141–150. [10.1007/s00345-008-0302-z](https://doi.org/10.1007/s00345-008-0302-z).
- [4] Dillner J, von Krogh G, Horenblas S, et al. Etiology of squamous cell carcinoma of the penis. *Scand J Urol Nephrol Suppl* 2000;205:189–193.
- [5] Opjordsmoen S, Fossa SD. Quality of life in patients treated for penile cancer. A follow-up study. *Br J Urol* 1994;74:652–657.
- [6] Opjordsmoen S, Waehre H, Aass N, et al. Sexuality in patients treated for penile cancer: Patients' experience and doctors' judgement. *Br J Urol* 1994;73:554–560.
- [7] Romero FR, Romero KR, Mattos MA, et al. Sexual function after partial penectomy for penile cancer. *Urology* 2005;66:1292–1295. [10.1016/j.urology.2005.06.081](https://doi.org/10.1016/j.urology.2005.06.081).
- [8] Wanick FB, Teichner TC, Silva R, et al. Squamous cell carcinoma of the penis: Clinicopathologic study of 34 cases. *An Bras Dermatol* 2011;86:1082–1091.
- [9] Saibishkumar EP, Crook J, Sweet J. Neonatal circumcision and invasive squamous cell carcinoma of the penis: A report of 3 cases and a review of the literature. *Can Urol Assoc J* 2008;2:39–42.
- [10] Velazquez EF, Barreto JE, Rodriguez I, et al. Limitations in the interpretation of biopsies in patients with penile squamous cell carcinoma. *Int J Surg Pathol* 2004;12:139–146.
- [11] Daling JR, Madeleine MM, Johnson LG, et al. Penile cancer: Importance of circumcision, human papillomavirus and smoking in situ and invasive disease. *Int J Cancer* 2005;116:606–616. [10.1002/ijc.21009](https://doi.org/10.1002/ijc.21009).
- [12] Lont AP, Besnard AP, Gallee MP, et al. A comparison of physical examination and imaging in determining the extent of primary penile carcinoma. *BJU Int* 2003;91:493–495.
- [13] Solsona E, Algaba F, Horenblas S, et al. EAU guidelines on penile cancer. *Eur Urol* 2004;46:1–8. [10.1016/j.eururo.2004.03.007](https://doi.org/10.1016/j.eururo.2004.03.007).
- [14] Sobin LHC. Penis (ICD-0 C60). In: *TNM classification of malignant tumours*. 6th ed. New York, NY: John Wiley and Sons, Inc.; 2002. p. 181–183.
- [15] Schlenker B, Gratzke C, Seitz M, et al. Fluorescence-guided laser therapy for penile carcinoma and precancerous lesions: Long-term follow-up. *Urol Oncol* 2011;29:788–793. [10.1016/j.urolonc.2009.10.001](https://doi.org/10.1016/j.urolonc.2009.10.001).
- [16] Meijer RP, Boon TA, van Venrooij GE, et al. Long-term follow-up after laser therapy for penile carcinoma. *Urology* 2007;69:759–762. [10.1016/j.urology.2007.01.023](https://doi.org/10.1016/j.urology.2007.01.023).
- [17] Mazon JJ, Langlois D, Lobo PA, et al. Interstitial radiation therapy for carcinoma of the penis using iridium 192 wires: The Henri Mondor experience (1970–1979). *Int J Radiat Oncol Biol Phys* 1984;10:1891–1895.
- [18] Pagliaro LC, Crook J. Multimodality therapy in penile cancer: When and which treatments? *World J Urol* 2009;27:221–225. [10.1007/s00345-008-0310-z](https://doi.org/10.1007/s00345-008-0310-z).
- [19] Crook J, Ma C, Grimard L. Radiation therapy in the management of the primary penile tumor: An update. *World J Urol* 2009;27:189.
- [20] Pierquin B, Chassagne D, Wilson F. *Modern brachytherapy*. New York, NY: Masoom Publishers; 1987.
- [21] Crook J, Jezioranski J, Cygler JE. Penile brachytherapy: Technical aspects and postimplant issues. *Brachytherapy* 2010;9:151–158. [10.1016/j.brachy.2009.05.005](https://doi.org/10.1016/j.brachy.2009.05.005).
- [22] Pierquin B, Dutreix A, Paine CH, et al. The Paris system in interstitial radiation therapy. *Acta Radiol Oncol Radiat Phys Biol* 1978;17:33–48.
- [23] Chen CZ, Huang Y, Hall EJ, et al. Pulsed brachytherapy as a substitute for continuous low dose rate: An in vitro study with human carcinoma cells. *Int J Radiat Oncol Biol Phys* 1997;37:137–143.
- [24] Armour EP, White JR, Armin A, et al. Pulsed low dose rate brachytherapy in a rat model: Dependence of late rectal injury on radiation pulse size. *Int J Radiat Oncol Biol Phys* 1997;38:825–834.
- [25] Fowler JF, Van Limbergen EF. Biological effect of pulsed dose rate brachytherapy with stepping sources if short half-times of repair are present in tissues. *Int J Radiat Oncol Biol Phys* 1997;37:877–883.
- [26] Petera J, Sirak I, Kasaova L, et al. High-dose rate brachytherapy in the treatment of penile carcinoma—first experience. *Brachytherapy* 2011;10:136–140. [10.1016/j.brachy.2010.05.007](https://doi.org/10.1016/j.brachy.2010.05.007).
- [27] de Crevoisier R, Slimane K, Sanfilippo N, et al. Long-term results of brachytherapy for carcinoma of the penis confined to the glans (N- or NX). *Int J Radiat Oncol Biol Phys* 2009;74:1150–1156. [10.1016/j.ijrobp.2008.09.054](https://doi.org/10.1016/j.ijrobp.2008.09.054).
- [28] Kochhar R, Taylor B, Sangar V. Imaging in primary penile cancer: Current status and future directions. *Eur Radiol* 2010;20:36–47. [10.1007/s00330-009-1521-4](https://doi.org/10.1007/s00330-009-1521-4).
- [29] Tanis PJ, Lont AP, Meinhardt W, et al. Dynamic sentinel node biopsy for penile cancer: Reliability of a staging technique. *J Urol* 2002;168:76–80.
- [30] Valdes Olmos RA, Tanis PJ, Hoefnagel CA, et al. Penile lymphoscintigraphy for sentinel node identification. *Eur J Nucl Med* 2001;28:581–585.
- [31] Gomez-Iturriaga A, Crook J, Evans W, et al. The efficacy of hyperbaric oxygen therapy in the treatment of medically refractory soft tissue necrosis after penile brachytherapy. *Brachytherapy* 2011;10:491–497. [10.1016/j.brachy.2011.01.009](https://doi.org/10.1016/j.brachy.2011.01.009).
- [32] Chaudhary AJ, Ghosh S, Bhalavat RL, et al. Interstitial brachytherapy in carcinoma of the penis. *Strahlenther Onkol* 1999;175:17–20.
- [33] Delannes M, Malavaud B, Douchez J, et al. Iridium-192 interstitial therapy for squamous cell carcinoma of the penis. *Int J Radiat Oncol Biol Phys* 1992;24:479–483.
- [34] Kiltie AE, Elwell C, Close HJ, et al. Iridium-192 implantation for node-negative carcinoma of the penis: The Cookridge Hospital experience. *Clin Oncol (R Coll Radiol)* 2000;12:25–31.
- [35] Soria JC, Fizazi K, Piron D, et al. Squamous cell carcinoma of the penis: Multivariate analysis of prognostic factors and natural history in monocentric study with a conservative policy. *Ann Oncol* 1997;8:1089–1098.