

## CASE REPORT

# Computed Tomography Findings of Gossypiboma

Tzu-Chieh Cheng<sup>1</sup>, Andy Shau-Bin Chou<sup>2</sup>, Chin-Ming Jeng<sup>1</sup>, Pau-Yuan Chang<sup>2\*</sup>, Chau-Chin Lee<sup>2</sup>

<sup>1</sup>Department of Radiology, Cathay General Hospital, and <sup>2</sup>Department of Radiology, Buddhist Tzu Chi General Hospital, Taipei, Taiwan, R.O.C.

Gossypiboma is composed of non-absorbable surgical material with a cotton matrix. Gossypiboma is usually under-reported and is a severe medicolegal issue. Thus, we describe the computed tomography (CT) findings of gossypiboma in our institution. From January 2003 to June 2006, gossypibomas diagnosed in our institution and their data regarding sex, age, previous operation, location, the interval between the operation and the diagnosis of gossypiboma, clinical presentation, indication of CT, CT findings and further management were collected. There were 6 cases of gossypiboma, 4 men and 2 women. Three of our cases had previous chest surgery and the other 3 cases had previous abdominal surgery. The locations of 3 (50%) cases were in the left anterior subphrenic space. The mean interval between original operation and diagnosis was  $24.6 \pm 33.4$  months (range, 17 days to 8 years). With regard to CT findings, 3 (50%) cases had an isodense mass and 3 (50%) had a typical mass containing curvilinear opaque structures. The mean size of the gossypibomas was  $62 \times 62 \times 67$  mm. Because gossypiboma is due solely to human factors and is a severe medicolegal issue, continuous education should be considered. [*J Chin Med Assoc* 2007;70(12):565–569]

**Key Words:** foreign bodies, spiral computed tomography, surgical sponge

## Introduction

Retained postoperative foreign bodies, of which sponges are the most common, is a rare condition and due solely to human factors.<sup>1,2</sup> Gossypiboma (also called textiloma or cottonoid) is a term used to describe a mass in the body that is composed of a cotton matrix surrounded by a foreign body reaction.<sup>3</sup> A foreign body left behind after an operation is a severe medicolegal issue and often under-reported.<sup>4,5</sup> Thus, we reviewed 6 cases of gossypiboma diagnosed based on previous operative history and high-density whirling structures on computed tomography (CT) scan in our institution.

## Case Reports

From January 2003 to June 2006, gossypibomas diagnosed based on previous operative history and CT in our institution were collected. Data on sex, age, previous operation, location, the interval between the operation and the diagnosis of gossypiboma, clinical presentation, indication of CT, CT findings and further management were collected.

A total of 6 cases of gossypiboma were included in our study. Table 1 summarizes the patients' characteristics. There were 4 (67%) men and 2 (33%) women, with a mean age of  $54.7 \pm 16.8$  years (range, 23–79 years). Two of our cases were incidental findings (33%). Three (50%) of our cases had chest procedures and 3 (50%) had abdominal procedures. Of the 6 cases, the locations of 3 (50%) gossypibomas were in the left anterior subphrenic space. The mean interval between the previous procedure and diagnosis with CT was  $24.6 \pm 33.4$  months (range, 17 days to 8 years). With regard to CT findings, 3 (50%) cases had isodense masses, 2 (33%) had low-density masses and 1 (17%) had a heterogeneous mass. Three (50%) cases had typical high-density whirling structure. The mean size of the gossypibomas was  $62 \times 62 \times 67$  mm (range,  $28 \times 35 \times 25$  mm to  $180 \times 187 \times 215$  mm).

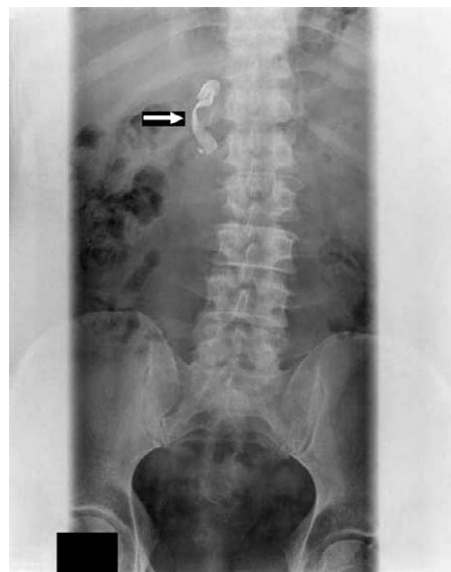### Case 1

A 51-year-old man had stage III renal cellular carcinoma. Two months after right radical nephrectomy via a transabdominal approach, he had left leg pain and flank pain. An abdominal plain film revealed a well-defined amorphous radio-opaque shadow over

\*Correspondence to: Dr Pau-Yuan Chang, Department of Radiology, Buddhist Tzu Chi General Hospital, 707, Section 3, Chung Yang Road, Hualien 970, Taiwan, R.O.C.  
E-mail: [tcuarnium@yahoo.com.tw](mailto:tcuarnium@yahoo.com.tw) • Received: April 3, 2007 • Accepted: October 23, 2007

**Table 1.** Summary of the 6 cases

No./Sex/Age (yr)	Operation site	Related symptoms	Interval	Size (mm)	Location	Mass density	Opaque pattern	Resection
1/M/51	Abdomen	No	67 d	28 × 35 × 25	Left anterior subphrenic space	Isodense	Radio-opaque structure	No
2/M/53	Chest	Yes	84 d	32 × 29 × 35	Left anterior subphrenic space	Isodense	Typical high-density whirling structure	Yes
3/M/61	Chest	Yes	17 d	30 × 30 × 30	Left anterior subphrenic space	Heterogeneous	Radio-opaque structure	Yes
4/M/61	Abdomen	Yes	8 yr	180 × 187 × 215	Lesser sac of abdomen	Low density	Typical high-density whirling structure	Yes
5/F/23	Chest	Yes	2 yr and 2 mo	40 × 28 × 30	Anterior segment of left upper lobe of lung	Isodense	Typical high-density whirling structure	Yes
6/F/79	Abdomen	No	1 yr and 8 mo	34 × 29 × 30	Gallbladder fossa	Low density	Radio-opaque structure	No

**Figure 1.** Case 1: plain X-ray of the abdomen. Note the well-defined radio-opaque marker of the retained swab (arrow).

the right upper abdomen (Figure 1). CT for radiotherapy programming revealed a 28 × 35 × 25 mm isodense mass with high-density structure in the left anterior subphrenic space. The diagnosis was based on previous surgical history and typical sponge-like material seen in radiology. The patient went on programmed radiotherapy and the mass was left untreated due to there being no related clinical symptoms of the incidental gossypiboma. No related event was noted at the patient's 1-year follow-up.

### Case 2

A 53-year-old man had symptomatic rheumatic heart disease. About 3 months after mitral valve replacement via a longitudinal median sternotomy approach, he had aggregated hoarseness and dizziness. Chest CT for sternal wound infection revealed a 32 × 29 × 35 mm isodense mass with typical high-density whirling structure in the left anterior subphrenic space (Figure 2). Debridement was performed and pathology confirmed the diagnosis of gossypiboma. No related clinical event was noted at the patient's 1-year follow-up.

### Case 3

A 61-year-old man had 3-vessel coronary artery disease. Seventeen days after coronary artery bypass surgery via a longitudinal median sternotomy approach, he had persistent high fever. Chest CT for sternal wound infection revealed a 30 × 30 × 30 mm heterogeneous mass with high-density structure in the left anterior subphrenic space. Debridement was performed and pathology confirmed the diagnosis of gossypiboma.

No related clinical event was noted at the patient's regular 6-month follow-up.

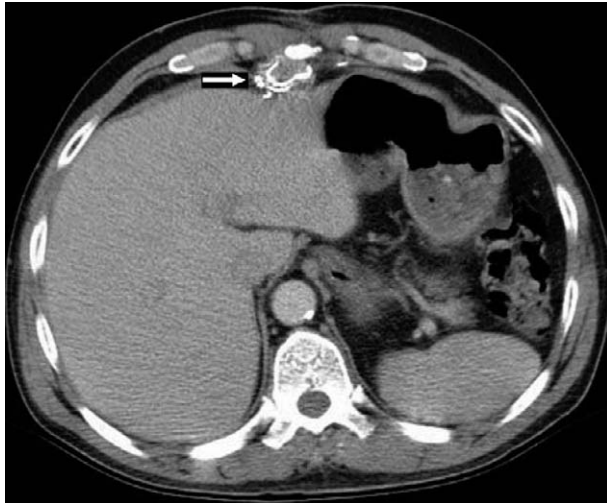#### Case 4

A 61-year-old man had gastric cancer. About 8 years after total gastrectomy via a transabdominal approach, he had intermittent right upper abdominal pain for 3 months. CT for abdominal evaluation showed a  $180 \times 187 \times 215$  mm low-density mass with peripheral rim and typical high-density whirling structure in the lesser sac of the abdomen. Similar CT findings of a smaller mass had been noted in another institution 2 years previously. The patient underwent resection for possible recurrence of gastric cancer, but pathology confirmed the diagnosis of gossypiboma. No

related clinical event was noted at his 3-month follow-up.

#### Case 5

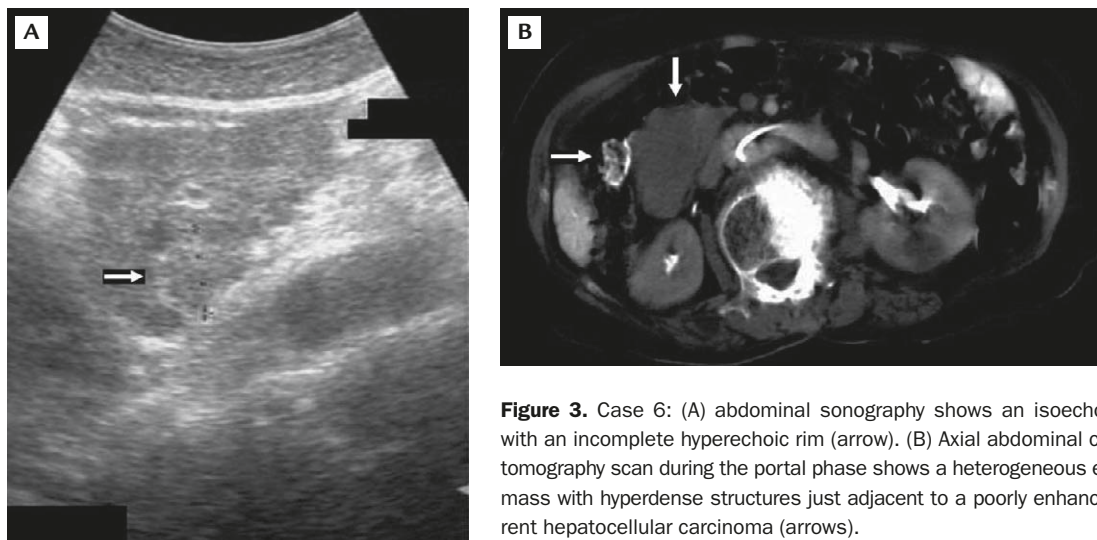
A 23-year-old woman had chest contusion complicated with hemothorax. About 2 years and 2 months after surgical chest drainage via a transthoracic approach, she had sore throat, cough and mild hemoptysis for several days. CT for persistent shadow over the left upper lung field on chest plain film revealed a  $40 \times 28 \times 30$  mm isodense mass with typical high-density whirling structure in the anterior segment of the left upper lobe of the lung. She was the only patient who had a correct sponge count among our cases. Resection was performed and pathology confirmed the gossypiboma at another institution. No related clinical event was noted at the patient's recent follow-up.



**Figure 2.** Case 2: axial abdominal computed tomography scan. Note the mass with typical high-density whirling structures (arrow) in the left anterior subphrenic space.

#### Case 6

A 79-year-old woman had hepatocellular carcinoma (HCC) status of post-lumpectomy at the left hepatic lobe via a transabdominal approach about 1 year and 8 months previously. Abdominal plain film revealed an irregular radio-opaque shadow over the right abdomen. Ultrasonographic findings of the lesion favored an isoechoic mass with incomplete hyperechoic peripheral wall (Figure 3). CT for clinical follow-up revealed recurrent left HCC and a  $34 \times 29 \times 30$  mm low-density mass with high-density structure in the gallbladder fossa. Well-defined wire-like structure in a recurrent HCC lesion before embolization is uncommon, and the following combined CT arterial portography showed a low possibility of metastasis (Figure 3). The patient underwent transarterial embolization for recurrent HCC and the gossypiboma was left untreated



**Figure 3.** Case 6: (A) abdominal sonography shows an isoechoic mass with an incomplete hyperechoic rim (arrow). (B) Axial abdominal computed tomography scan during the portal phase shows a heterogeneous enhanced mass with hyperdense structures just adjacent to a poorly enhanced recurrent hepatocellular carcinoma (arrows).

due to there being no related clinical symptoms. The diagnosis was based on typical sponge-like material observed in radiology. No related clinical event was noted at the patient's recent follow-up.

## Discussion

The term gossypiboma is derived from the Latin *gossypium*, meaning cotton, and the Kiswahili word *boma*, meaning place of concealment.<sup>6</sup> Gossypibomas are masses formed by retained surgical sponges and reactive tissue.<sup>7</sup> Gossypiboma is due solely to human factors. For example, some authors reported a 76% incidence of false count of surgical sponges during operation.<sup>4</sup> The reported incidence of gossypiboma varies between 1/1,000 and 1/10,000 procedures.<sup>2</sup>

The clinical presentation and the time interval between the original operation and the diagnosis of gossypiboma are variable and depend on the location and type of reaction evoked. About a third of gossypiboma patients remain asymptomatic, with the foreign body solely detected radiographically, because cotton sponges do not undergo any specific decomposition or biomedical reaction.<sup>4</sup>

Most commonly, aseptic fibrinous inflammatory reactions and adhesions encapsulate the gossypiboma in the omentum and nearby organs. Accordingly, the diagnosis is difficult because of the less severe symptoms and the delay in onset from previous surgery. Patients usually remain asymptomatic and the gossypibomas are detected incidentally.

On the other hand, cotton sponge may lead to exudative inflammatory reaction, with abscess or fistula formation. This usually presents much earlier than the fibrinous reaction sequel.<sup>2,7</sup> The resultant abscess and the pressure exerted by the foreign body may lead to an external opening, or this may force an opening into an adjacent adherent hollow organ. During this erosion process, which may take years, most patients are symptomatic and present with abdominal pain, nausea, vomiting, anemia, an abdominal mass, diarrhea, malnutrition, weight loss or intestinal obstruction. Alternatively, the gossypiboma may be spontaneously expelled per rectum without any serious problems after a variable period of 10 days to 15 years. The peristaltic activity of the intestine helps in propelling the foreign body.

Although surgical swabs were widely labeled with radio-opaque markers after the 1980s, which facilitates their detection, the diagnosis of gossypiboma is not easy.<sup>5,6</sup> The markers may be distorted by folding, twisting or disintegration over time. The diagnosis is difficult using only plain X-ray.<sup>1,2,4,8,9</sup> Moreover, even

in the presence of a radio-opaque marker, gossypiboma can be difficult to visualize and may be overlooked, or an erroneous diagnosis may be made.

Ultrasound, CT or magnetic resonance imaging (MRI) is usually a necessary procedure, especially in chronic cases, because the lesion may mimic a malignant mass.<sup>10-12</sup> They are valuable tools in facilitating the diagnosis in most cases. CT is a practical tool for detecting radio-opaque foreign bodies.<sup>1,2,4,8,9</sup> The typical spongiform pattern is the most characteristic CT sign of gossypiboma; another sign associated with the condition is an inhomogeneous, low-density mass with a thin high-density capsule that shows marked enhancement after administration of contrast material. The mass may contain wavy, striped, high-density areas that represent the sponge itself.<sup>1,3</sup>

All 6 cases were presented in combined conference or confirmed with the previous operator. Among our cases, 4 were symptomatic and the gossypibomas were removed surgically. The charts showed a false count of surgical sponges in 5 (83%) cases. Pathologic evidence was only available in 4 (67%) of our cases due to potential medicolegal complexity. Four of their plain X-ray films were available, and only 1 of these was valuable for diagnosis of gossypiboma. Sonography was only available in 1 case, with inconclusive findings. Otherwise, CT findings of all 6 cases were suggestive of a foreign body-related mass. Thus, CT is a practical tool for detecting possible gossypiboma in both symptomatic and asymptomatic cases.

When no radio-opaque marker is seen on plain X-ray or CT, ultrasonography may show a hyperechoic encapsulated mass, but the characteristic internal structure of the gauze granuloma is best visualized on MRI.<sup>2,7</sup> Theoretically, the magnetic resonance spectrum can distinguish inflammatory pseudotumors from neoplastic lesions.<sup>6,10</sup> Positron emission tomography reportedly shows gossypiboma as a lesion with unusual rim enhancement, which may also be potentially interesting in differential malignancy.<sup>13-15</sup>

We have described the clinical presentation and CT characteristics of 6 cases of gossypiboma in our institution. Gossypiboma is usually under-reported and is a severe medicolegal issue. Human errors cannot be abolished, but must be reduced to a minimum. In this regard, continuous medical education is the cornerstone.

## References

1. Kokubo T, Itai Y, Ohtomo K, Yoshikawa K, Iio M, Atomi Y. Retained surgical sponges: CT and US appearance. *Radiology* 1987;165:415-8.

2. Bani-Hani KE, Gharaibeh KA, Yaghan RJ. Retained surgical sponges (gossypiboma). *Asian J Surg* 2005;28:109–15.
3. Topal U, Gebitekin C, Tuncel E. Intrathoracic gossypiboma. *AJR Am J Roentgenol* 2001;177:1485–9.
4. Hu SC, Pang HL, Hsieh HF. Gossypiboma (retained surgical sponge): report of a case. *Gastroenterol J Taiwan* 2005;22:329–34.
5. Tzeng JE, Wei CK, Chang SM, Lin CW. Surgical gauze pseudo-tumor (gauzoma): a case report. *Tzu Chi Med J* 2006;18:49–51.
6. Rajput A, Loud PA, Gibbs JF, Kraybill WG. Diagnostic challenges in patients with tumors: case 1. gossypiboma (foreign body) manifesting 30 years after laparotomy. *J Clin Oncol* 2003;19:3700–5.
7. Cerwenka H, Bacher H, Kornprat P, Mischinger HJ. Gossypiboma of the liver: CT, MRI and intraoperative ultrasonography findings. *Dig Surg* 2005;22:311–2.
8. Huang WC, Jiang JK, Wang HS, Yang SH, Chen WS, Lin TC, Lin JK. Retained rectal foreign bodies. *J Chin Med Assoc* 2003;66:607–12.
9. Fong YC, Lin WC, Hsu HC. Intrapelvic migration of a Kirschner wire. *J Chin Med Assoc* 2005;68:96–8.
10. Karila-Cohen P, Kotobi H, Weber N, Merran S. Gossypiboma of the abdomen. *J Radiol* 2004;85:17–20. [In French]
11. Yen CH, Chen JD, Tui CM, Chou YH, Lee CH, Chang CY, Yu C. Internal hernia: computed tomography diagnosis and differentiation from adhesive small bowel obstruction. *J Chin Med Assoc* 2005;68:21–8.
12. Lan MY, Lien CF, Liao WH. Using high resolution computed tomography to evaluate middle ear cleft aeration of postoperative cholesteatoma ears. *J Chin Med Assoc* 2003;66:217–23.
13. Chen PL, Wang PY, Hsu HY. Reversible electroencephalographic and single photon emission computed tomography abnormalities in Hashimoto's encephalopathy. *J Chin Med Assoc* 2005;68:77–81.
14. Vento JA, Karak PK, Henken EM. Gossypiboma as an incidentaloma. *Clin Nucl Med* 2006;31:176–7.
15. Chung CT, Wang CF, Chou CS, Wang SJ, Kao CH, Lan HC. Single photon emission computed tomography (SPECT) for low back pain induced by extension with no root sign. *J Chin Med Assoc* 2004;67:349–54.