



Contents lists available at ScienceDirect

## International Journal of Surgery Case Reports

journal homepage: [www.casereports.com](http://www.casereports.com)

# Autologous segmental tibia bone transfer in the treatment of distal tibia Gustilo-Anderson type-III open fracture: A case report



Mehmet Demirel<sup>a,\*</sup>, Turgut Akgül<sup>a</sup>, Gökhan Polat<sup>a</sup>, Mehmet Fevzi Çakmak<sup>a</sup>, Fatih Dikici<sup>b</sup>

<sup>a</sup> Department of Orthopaedics and Traumatology, Istanbul University Faculty of Medicine, Istanbul, Turkey

<sup>b</sup> Department of Orthopaedics and Traumatology, Acibadem University Hospital, Istanbul, Turkey

## ARTICLE INFO

### Article history:

Received 13 June 2016

Received in revised form 28 July 2016

Accepted 28 July 2016

Available online 4 August 2016

### Keywords:

Open fractures

Autologous bone graft

Tibia

Kept in abdominal wall

Gustilo-Anderson type-III

Case report of autologous tibia

## ABSTRACT

**INTRODUCTION:** We present the results of a two-stage reconstruction performed with autologous segmental tibia bone transfer on a distal tibia Gustilo-Anderson type-IIIC open fracture in this paper. Our aim is to discuss the results of this surgery, potential failures and complications in our procedures, and ways to protect against osteolysis.

**PRESENTATION OF CASE:** A 20-year-old male who has undergone surgery in our clinic for a Gustilo-Anderson type-III open fracture of the left tibia using autologous tibia segmental bone transfer. The first operation consisted of removing the exposed bony fragment and placing it in the abdominal wall. Fifty days after the first operation, an intramedullary nailing operation was performed using the autologous bone fragment kept in the abdominal wall. Before the final procedure, we assessed the viability of the bone fragment using scintigraphy as well as the paprika sign was observed on the fragment during operation. Patient was seen in follow-up every three weeks to evaluate for successful osteosynthesis; however, osteolysis eventually established in the 7th month of follow-up.

**DISCUSSION:** Specific treatment modalities with each having different advantages and disadvantages are a matter of debate in tibia fractures with bone and soft tissue loss. To our knowledge, there are no such cases reported in the literature of autologous tibia bone transfer for osteosynthesis with the fractured bone segment temporarily being stored inside the abdominal wall for nutritional supplementation.

**CONCLUSION:** The osteosynthesis with autologous tibia bone transfer may be employed by saving the segment inside abdominal wall, if suitable conditions are provided.

© 2016 The Author(s). Published by Elsevier Ltd on behalf of IJS Publishing Group Ltd. This is an open access article under the CC BY-NC-ND license (<http://creativecommons.org/licenses/by-nc-nd/4.0/>).

## 1. Introduction

AO/OTA 42-C2 tibia complex segmental fractures generally occur with a high energy trauma. These injuries are typically accompanied by soft tissue injuries related to these fractures by virtue of the high energy trauma [1]. Some 63% of open fractures with accompanying soft tissue injury are seen in the diaphyseal part of the tibia. One- or two-stage treatment of osteosynthesis are performed in open fractures. Osteosynthesis can be primarily performed in extremity bones covered with qualified soft tissue such as the femur; however, several treatment methods may be required in tibia fractures due to the poor coating of soft tissue [2].

The traditional treatment in open fractures of the lower leg with bone and soft tissue loss is to utilize bone graft, after restoring an adequate soft tissue coverage. Nevertheless, psychological

problems related to prolonged treatment, recurrent surgeries, and complications such as deformity, non-union, delayed union, and discrepancy of lower limb may cause unsatisfactory results [3,4,6]. Therefore, bifocal compression-distraction osteogenesis with an external fixator may be a salvage procedure [5].

The purpose of this case report is to present the results of a two-stage reconstruction procedure of an open segmental tibia fracture with bone and soft tissue loss.

## 2. Case report

A 20-year-old male was referred to our hospital with a Gustilo-Anderson Type-IIIC open fracture on left lower leg after a motorcycle accident. He was conscious with stable vital signs and otherwise healthy with no systemic diseases or associated trauma. The patient had about 15 cm of soft tissue loss along posterior side of the left lower leg and 8 cm of an exposed tibia fragment upon presentation (Fig. 1) and radiographic examination (Fig. 2a, b). There were no neurovascular injuries with the exception of total disruption posterior tibial artery with no flow on CT angiography.

\* Corresponding author at: Istanbul University, Istanbul Faculty of Medicine, Department of Orthopaedics and Traumatology, Çapa Fatih Istanbul 34050, Turkey.  
E-mail address: [dr88.mehmet.demirel@gmail.com](mailto:dr88.mehmet.demirel@gmail.com) (M. Demirel).

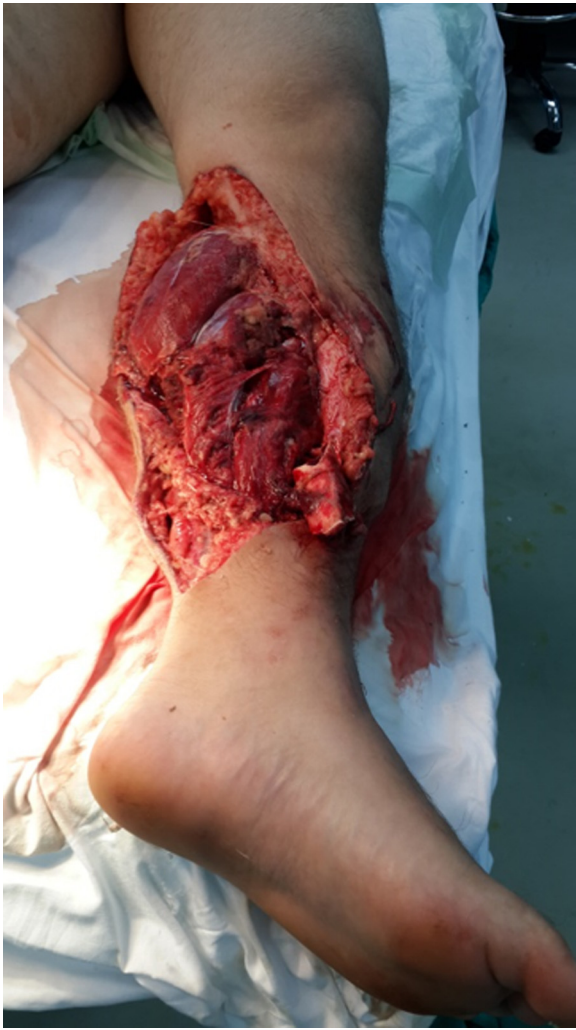

Fig. 1. Large soft tissue defect.

Cardiovascular consultation was obtained with no possibility of vascular reconstruction. The patient then was consulted with the plastic surgery; a surgical flap was considered unsuitable due to poor blood supply. In the light of the findings above, we decided to keep the exposed tibia fragment in the patients' own abdominal wall and planned a two-stage reconstruction, in order to reduce the risk of infection. An informed consent for this treatment plan was obtained from the patient. The patient was transferred to operation theater within 3 h of the accident.

Reconstruction with reverse saphenous vein graft was performed as soon as debridement and irrigation was enforced. After the loose fracture fragment in the tibia diaphysis was placed between layers of the peritoneum (Fig. 3a, b), stabilization of the fracture was obtained using an AO type external fixator. Two grams of bone cement were mixed with teicoplanin was placed in the defect area of the bone (Fig. 4a, b). The wound was debrided afterwards, and a bedside vacuum-assisted wound closure system was used to assist reconstruction of the soft tissue. Cefazoline  $4 \times 1$  gr/24 h, gentamicin 80 mg once daily, and metronidazole  $2 \times 500$  mg intravenous antibiotic treatment was given to the patient during the post-operative period.

C-reactive protein (CRP), sedimentation, and white blood cell (WBC) levels were 54 mg/dL, 137, 10 600/mm<sup>3</sup>, respectively, on the 20th day of the post-operative follow-up period. Acinetobacter and enterobacter were identified in the bacterial wound culture; therefore, intravenous ciprofloxacin antibiotic medication

was started as recommended by the Department of Infection Diseases. In addition, no abscess was seen in the patient's abdomen under the ultrasonography (USG). A split thickness skin graft was performed on the 30th post-operative day; with the development of a favorable granulation tissue over the wound site.

During his stay, patient became addicted to the opioid treatment and had mood impairment. Antidepressant and anxiolytic medications were ordered by the psychiatrist, and analgesic medication was rearranged.

Osteosynthesis treatment was planned as soon as CRP and sedimentation levels decreased to normal levels, and the split thickness skin graft was considered successful on 50th day of follow-up. Consequently, after the vitality of the bone fragment, which had been maintained between layers of the peritoneum, was checked using 3-phase bone scintigraphy, intramedullary osteosynthesis was performed with the tibia fragment (Fig. 5). The paprika sign was observed on the autologous segmental tibia during the operation (Fig. 6). Demineralized bone matrix (DBM) was applied to the area of fracture to increase union potential. We locked the intramedullary nail statically and did not apply fibula osteotomy. The patient was discharged on post-operative week 1 with cefprozolone  $2 \times 1$  g PO.

Secondary healing of the wound area was completely achieved in the postoperative 7th month. However, control plain radiographies displayed osteolysis in the autologous bone fragment, which was confirmed with a repeat 3-phase bone scintigraphy. Conversely, full union resulted in the area of the fibula fracture with synostosis in the proximal side of the fracture line (Fig. 7).

### 3. Discussion

Open fractures of the tibia almost always occur with high energy trauma; which tend to be Gustilo-Anderson Type-III open fractures, usually accompanied by large soft tissue damages, and neurovascular injuries, and increased risk of infection [13]. Specific treatment modalities remain a challenge in tibia fractures with bone and soft tissue loss. However, there are several possible treatment modalities such as distraction-compression histogenesis with an Ilizarov-type external fixator, osteosynthesis with plate and screw, intramedullary nailing, application of vascularized or non-vascularized contralateral fibula graft, allograft reconstruction, and tibia-fibula synostosis. All of these methods have disadvantages and advantages [14].

In this case we preferred to use an autologous segmental exposed tibia bone graft for osteosynthesis (Table 1).

Autologous bone grafts have osteoconductive, osteoinductive, and osteogenic features, and are the gold standard among the bone grafts. Allografts are developed in order to avoid donor site morbidity and extensive bone loss of autologous bone grafts [15]. An autologous segmental bone graft is kept in the anterior abdominal wall after decompressive craniectomy by neurosurgeons in posttraumatic brain injuries. Similarly, this method is also used for open fractures of the skull by plastic and reconstructive surgeons [16]. However, to our knowledge, no such use autologous segmental bone graft has been reported in orthopaedic surgery thus far. In theory, the human body provides a natural depot by passive diffusion in order to avoid devitalization of the autologous graft. Viability of grafts can be evaluated using computer tomography and radionuclide activity in the first postoperative year [16].

To our knowledge, our patient was the first in the orthopaedic surgery literature to have a fragment of tibia fracture stored between layers of the peritoneum, which was performed as opposed to conventional sources such as fibula and iliac crest. Despite the fact that the donor site was different, he was treated with conventional methods. The treatment failed with devel-

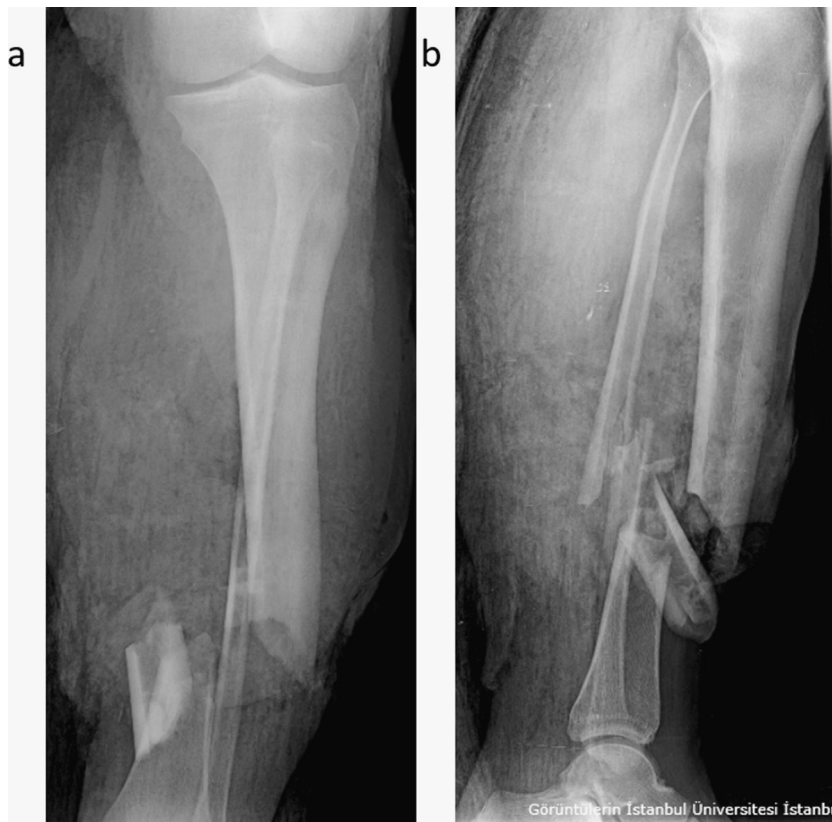

Fig. 2. a and b anteroposterior and lateral radiographies of the left crus display AO/OTA 42-C2 tibia complex segmental fracture.

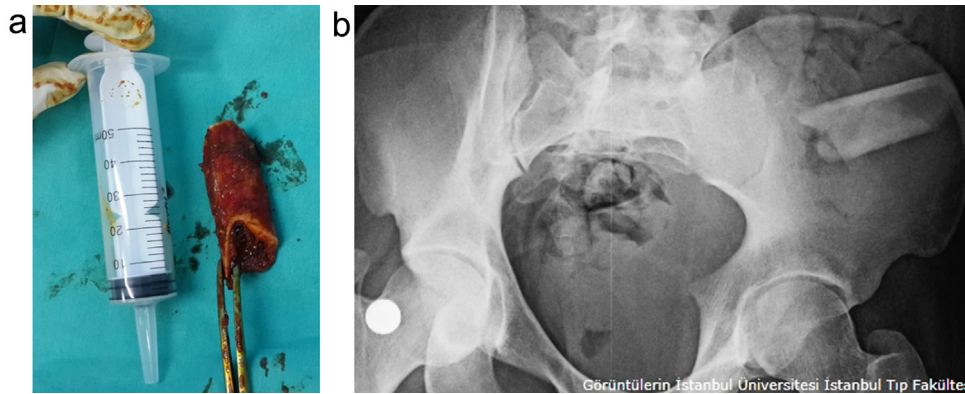


Fig. 3. a: The autologous tibia bone graft. b: The bone in the abdominal wall.

**Table 1**  
Timeline of the case report.

Within 3 h after the accident	Operation time	On the 20th postoperative day	On the 30th postoperative day	On the 50th postoperative day	In the postoperative 7th month
Had a motorcycle accident.	<i>Use of Autologous Segmental Tibia Bone Transfer</i>	Acinetobacter and enterobacter were identified.	A split thickness skin graft was performed.	The split thickness skin graft was considered successful.	Secondary healing of the wound area was completely achieved.
Gustilo-Anderson type-IIIC open crus fracture	Reconstruction with reverse saphenous vein graft	Ciprofloxacin antibiotic medication was started.		Vitality of the bone fragment was checked using scintigraphy.	Radiographies displayed osteolysis in the autologous bone fragment.
Injury of the arteria tibialis posterior	Use of AO type external fixator			Intramedullary osteosynthesis was performed with the tibia fragment.	Full union in the area of the fibula fracture and synostosis in the proximal side of the fracture line.
Took a two-stage treatment decision.					



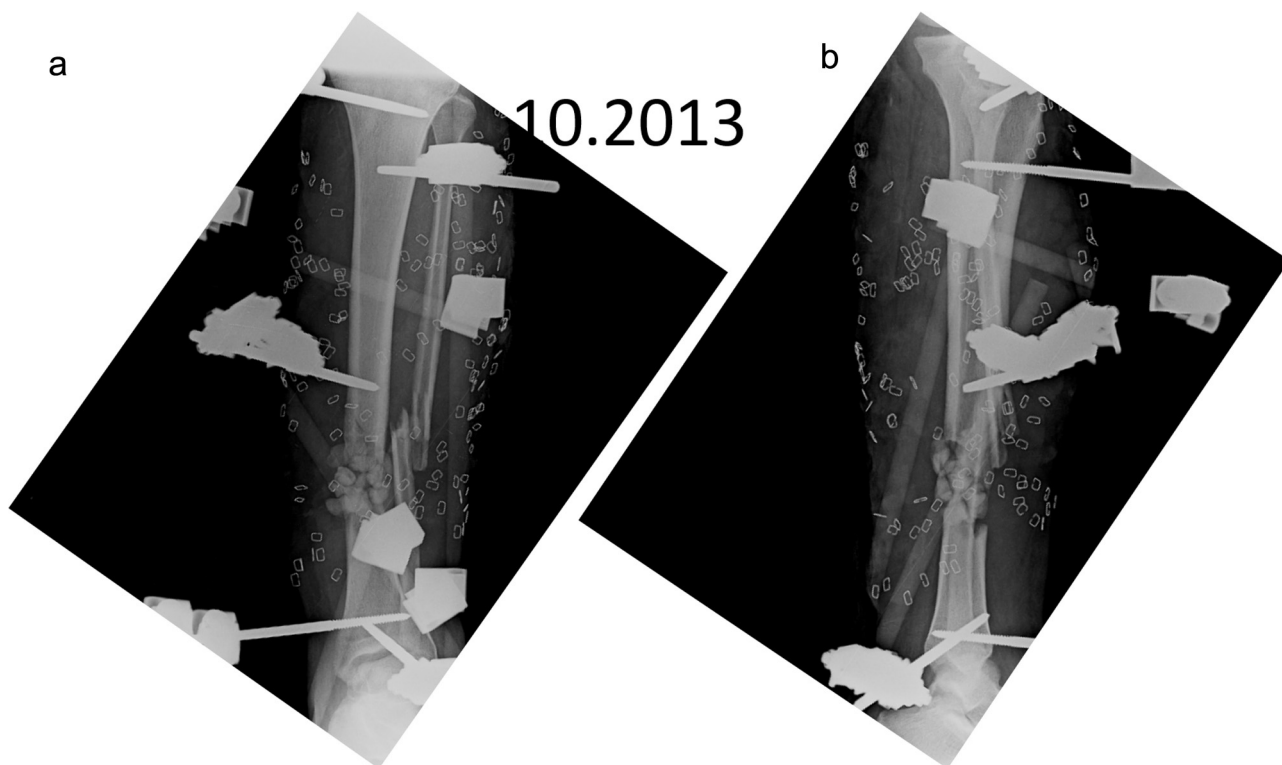


Fig. 4. a and b postoperative anteroposterior and lateral radiographies of the crus.

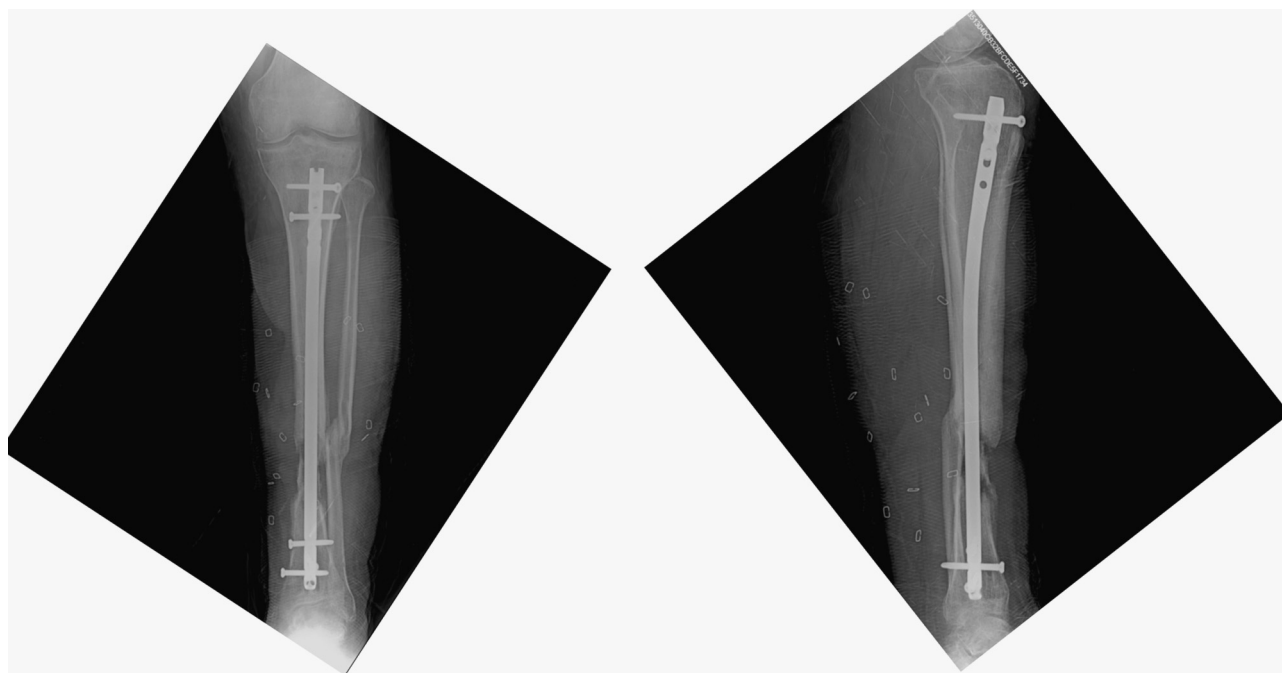


Fig. 5. Anteroposterior and lateral radiographies of the crus 1 day after the operation.

opment of osteolysis. We believe that the static locking of the intramedullary nail without performing a fibula osteotomy or pedicle flap at the first stage of treatment may have caused osteolysis of the bone graft. In the light of this result, we consider that distraction-compression osteogenesis should be the first and definitive treatment method in this type of case.

It was reported that bifocal compression-distraction osteogenesis has high rates of successful results in clinical and radiological evaluation in the literature. In addition, authors observed that acute shortening and progressive lengthening ensured a shorter treatment period and a lower complication rate than conventional methods [8–10]. Conversely, the disadvantage of this technique is frequently related to value of shortening length, and the safe limit

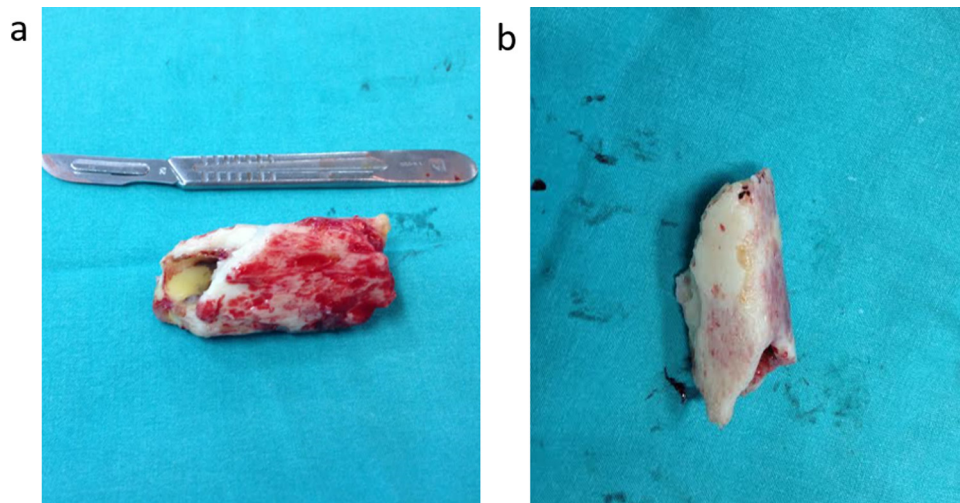


Fig. 6. a and b figures display the paprika sign.

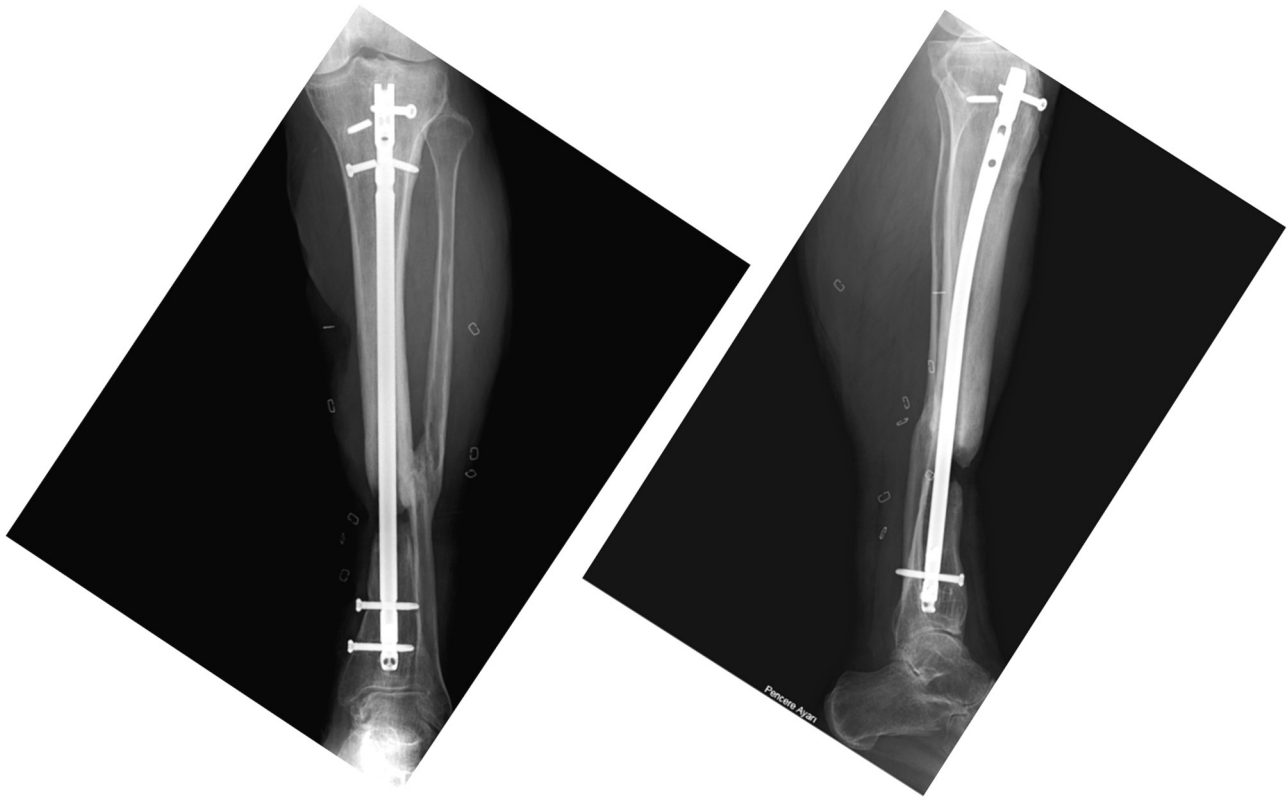


Fig. 7. Postoperative 7th month, osteolysis in the fracture area, full union in the area of the fibula fracture, and synostosis in the proximal side of the fracture line.

in the tibia for acute shortening is noticed as 3 cm or less in the literature [7,10]. However, Atbaşı et al. evaluated arterial configuration after acute tibia shortening using angiography, and showed that there was no change in arterial configuration up to 4 cm, minimal arterial bending after 4–6 cm shortening, and arterial tortuosity after 8 cm shortening [11]. We think that 5 cm shortening was adequate in our case because of the vascular injury. Anastomosis of arteria tibialis posterior would have been performed at the same time without requirement for a saphenous vein graft after 5 cm shortening.

Furthermore, we think that a 10-cm-sized skin and soft tissue defect can be repaired favourably with the acute shortening technique. It may not have been necessary to apply a flap or skin graft

[3]. On the other hand, an Ilizarov fixator system would have inhibited subsequent plastic surgery operations. Gopal et al. reported that external fixators created various difficulties in reconstructing open tibia fractures accompanied by heavy soft tissue damage; therefore, intramedullary nailing was the first-line treatment in their cases [12].

#### 4. Conclusion

Autologous bone graft is golden standard inside whole the bone grafts. We presented a result of two-stage reconstruction which used segmental autologous tibia graft. We believe that the static locking of the intramedullary nail without performing a fibula

osteotomy or pedicle flap at the first stage of treatment may have caused osteolysis of the segmental tibia autologous bone graft. As a result, osteosynthesis technique with an autologous segmental tibia graft can be performed successfully so long as suitable conditions are supplied. The bone fragment can be kept viable in the abdominal wall until the planned transfer.

#### Sources of funding

None.

#### Consent

Appropriate consent from the patient was obtained per institutional protocol and guidelines. A copy of the written consent is available for review by the Editor-in-Chief of this journal on request.

#### Ethical approval

Advocate Health Care Institutional Review Board does not require review for case reports.

#### Conflict of interest

The authors declare that they have no conflict of interest.

#### Author contribution

Mehmet Demirel, MD: drafting of the article, critical revision of the article for important intellectual clinical content; (2) Turgut Akgül, MD: equal contribution as lead author, drafting of the article, revision of the article for important intellectual clinical content; (3) Gökhan Polat, MD: revision of the clinical and intellectual content of the article; (4) Mehmet Ekin MD: revision of the clinical and intellectual content of the article; (5) Mehmet Fevzi Çakmak MD: revision of the clinical and intellectual content of the article; (6) Fatih Dikici MD: revision of the clinical and intellectual content of the article.

#### Guarantor

Fatih Dikici, MD.

#### Acknowledgement

The authors would like to acknowledge the University, the Faculty of Medicine, Department of Orthopedics and Traumatology.

#### References

- [1] Raymond R. White, George M. Babikian, Antonio Pace. AO Trauma 2. edition, 2012. pp. 834–852.
- [2] A. Agrawal, V.D. Chauhan, R.K. Maheshwari, A.K. Juyal, Primary nailing in the open fractures of the tibia-is it worth? *J. Clin. Diagn. Res.* 7 (6) (2013) 1125.
- [3] M.A. El-Rosasy, Acute shortening and re-lengthening in the management of bone and soft-tissue loss in complicated fractures of the tibia, *J. Bone Joint Surg. Brit. Vol.* 89 (1) (2007) 80–88.
- [4] J.L. Marsh, L. Prokuski, J.S. Biermann, Chronic infected tibial non-unions with bone loss: conventional techniques versus bone transport, *Clin. Orthop.* 301 (1994) 139–146.
- [5] A. Lerner, L. Fodor, M. Soudry, I.J. Peled, D. Herer, Y. Ullmann, Acute shortening: modular treatment modality for severe combined bone and soft tissue loss of the extremities, *J. Trauma Acute Care Surg.* 57 (3) (2004) 603–608.
- [6] J.T. Watson, M. Anders, B.R. Moed, Management strategies for bone loss in tibial shaft fractures, *Clin. Orthop.* 315 (1995) 138–152.
- [7] D. Paley, D.C. Maar, Ilizarov bone transport treatment for tibial defects, *J. Orthop. Trauma* 14 (2000) 76–85.
- [8] D.R. Marsh, S. Shah, J. Elliott, N. Kurdy, The Ilizarov method in nonunion, malunion and infection of fractures, *J. Bone Joint Surg. [Br.]* 79-B (1997) 273–279.
- [9] M. Saleh, A. Rees, Bifocal surgery for deformity and bone loss after lower-limb fractures: comparison of bone-transport and compression-distraction methods, *J. Bone Joint Surg. [Br.]* 77-B (1995) 429–434.
- [10] D. Paley, M.A. Catagni, F. Argnani, et al., Ilizarov treatment of tibial nonunions with bone loss, *Clin. Orthop.* 241 (1989) 146–165.
- [11] Z. Atbasi, B. Demiralp, E. Kilic, O. Kose, M. Kurklu, M. Basbozkurt, Angiographic evaluation of arterial configuration after acute tibial shortening, *Eur. J. Orthop. Sur. Traumatol.* 24 (8) (2014) 1587–1595.
- [12] S. Gopal, S. Majumder, A.G. Batchelor, et al., Fix and flap: the radical orthopaedic and plastic treatment of severe open fractures of the tibia, *J. Bone Joint Surg. [Br.]* 82-B (2000) 959–966.
- [13] W.C. Campbell, S.T. Canale, J.H. Beaty, *Campbell's Operative Orthopaedics*, Mosby/Elsevier, 2013.
- [14] A. Rahimnia, F. Fitoussi, G. Penneçot, K. Mazda, Treatment of segmental loss of the tibia by tibialisation of the fibula: a review of the literature, *Trauma Mon.* 16 (4) (2012) 154.
- [15] G.I. Drosos, P. Touzopoulos, A. Ververidis, K. Tilkeridis, K. Kazakos, Use of demineralized bone matrix in the extremities, *World J. Orthop.* 6 (2) (2015) 269.
- [16] K. Movassaghi, J. Ver Halen, P. Ganchi, S. Amin-Hanjani, J. Mesa, M.J. Yaremchuk, Cranioplasty with subcutaneously preserved autologous bone grafts, *Plast. Reconstr. Surg.* 117 (1) (2006) 202–206.

#### Open Access

This article is published Open Access at [sciedirect.com](http://sciedirect.com). It is distributed under the [IJSCR Supplemental terms and conditions](#), which permits unrestricted non commercial use, distribution, and reproduction in any medium, provided the original authors and source are credited.