

Available online at www.sciencedirect.com
 ScienceDirect

Journal of the Chinese Medical Association 74 (2011) 48–50

www.jcma-online.com

Case Report

Cytomegalovirus and herpes simplex virus as causes of bilateral anterior uveitis in an immunocompetent patient[☆]

Shih-Yi Yang^a, Mei-Ju Chen^{a,b,*}, Ko-Hua Chen^{a,b,c}, An-Fei Li^{a,b}, Ching-Kuang Chou^{a,b},
Shui-Mei Lee^{a,b}

^a Department of Ophthalmology, Taipei Veterans General Hospital, Taipei, Taiwan, ROC^b Department of Ophthalmology, National Yang-Ming University School of Medicine, Taipei, Taiwan, ROC^c Division of Medical Engineering, National Health Research Institutes, Taipei, Taiwan, ROC

Received 28 January 2010; accepted 14 June 2010

Abstract

We report a case with two distinct clinical manifestations of bilateral anterior uveitis caused by two different members of the herpes virus group. A 72-year-old immunocompetent man, who had a documented history of two episodes of Posner-Schlossman syndrome in the left eye, presented with multiple mutton-fat keratic precipitates and elevated intraocular pressure (IOP) in his right eye. Herpes simplex virus Type I DNA was detected by polymerase chain reaction in the aqueous humor of the right eye. One year later, the patient appeared with a few round and whitish keratic precipitates and elevated IOP in his left eye. Polymerase chain reaction analysis showed positive for cytomegalovirus in the aqueous humor of the left eye. During both episodes, the anterior uveitis subsided and IOP returned to normal after systemic and topical antiglaucomatous medication as well as topical steroid.

Copyright © 2011 Elsevier Taiwan LLC and the Chinese Medical Association. All rights reserved.

Keywords: Anterior uveitis; Cytomegalovirus; Herpes simplex virus

1. Introduction

Anterior uveitis accompanied by high intraocular pressure (IOP) is related to a variety of diseases, including herpes simplex virus (HSV) or varicella zoster virus (VZV)-associated anterior uveitis, Fuchs heterochromic iridocyclitis, and the Posner-Schlossman syndrome (PSS). Cytomegalovirus (CMV) infection is common in the general community but rarely causes ocular diseases in immunocompetent persons.¹ Recent literature indicates that CMV may cause chronic and/or recurrent anterior uveitis and corneal endotheliitis in otherwise healthy patients.^{2–7} Here, we report an immunocompetent patient with

recurrent CMV anterior uveitis in the left eye and HSV anterior uveitis in the right eye. The presence of viral DNA in the aqueous humor of both eyes was confirmed by polymerase chain reaction (PCR) during the active phase of uveitis.

2. Case report

An otherwise healthy 72-year-old man visited our ophthalmic clinic with complaint of pain in the right eye that had lasted for 1 week. He had a documented history of two episodes of iritis with elevated IOP (more than 50 mmHg) in the left eye a few years before. His visual acuity was 20 of 25 in the right eye and 20 of 30 in the left eye. IOPs were 19 mmHg in the right eye and 13 mmHg in the left eye. Slit lamp microscope examination showed 1+ cell and 2+ flares in the anterior chamber and multiple mutton-fat keratic precipitates (KPs) in the right eye (Fig. 1). There were mild cataractous changes in both eyes. Posterior segments were unremarkable in both eyes. A sample of

[☆] The authors declare no conflict of interest.

* Corresponding author. Dr. Mei-Ju Chen, Department of Ophthalmology, Taipei Veterans General Hospital 201, Section 2, Shih-Pai Road, Taipei 112, Taiwan, ROC.

E-mail address: mj_chen@vghtpe.gov.tw.




Fig. 1. The right eye under slit lamp microscope examination showed multiple mutton-fat keratic precipitates.

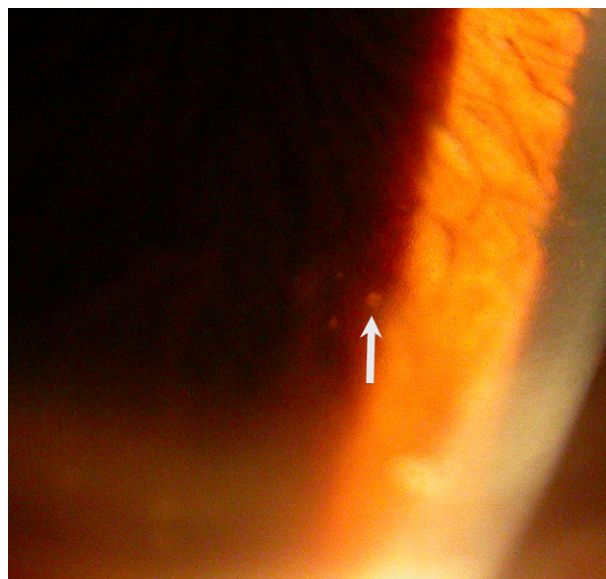


Fig. 2. The left eye under slit lamp microscope examination showed a few round and whitish keratic precipitates (arrow).

the aqueous humor was collected for PCR analysis. Under the diagnosis of PSS, the patient was treated with topical 1% prednisolone acetate every 2 hours daily. Four days later, the inflammation in the anterior chamber subsided, but IOP rose to 28 mmHg. Thus, 1% prednisolone acetate use was tapered to every 4 hours, and topical brimonidine was applied every 8 hours daily. After 1 week, IOP had decreased to 10 mmHg with residual minimal KPs. Serologic tests showed all negative titers for immunoglobulin M but positive titers for immunoglobulin G against HSV, VZV, and CMV. PCR analysis was positive for HSV Type I but negative for VZV and CMV. After 1 month, no inflammation was noted in the anterior chamber. IOP returned to the normal range without any medication.

Four months later, the patient visited our clinic again because of halo vision in the left eye for 2 days. His visual acuity was the same as compared with 1 year before. IOPs were 14 mmHg in the right eye and 27 mmHg in the left eye. Mild inflammation in the anterior chamber with a few round and whitish KPs was noted in the left eye (Fig. 2). Diffuse iris atrophy in the left eye was found as well. Gonioscopy revealed open angle without synechiae in both eyes. Diagnostic anterior chamber paracentesis was performed in the left eye. The aqueous humor was positive for CMV DNA but negative for HSV and VZV by PCR. The results of a complete blood cell count and humoral and cellular immunity tests were all within normal limits (CD4/CD8 cell: 44/24). The patient was treated with topical brimonidine every 8 hours daily, 0.02% fluorometholone four times daily, and oral acetazolamide (250 mg) three times daily. IOP returned to normal, and the anterior chamber reaction improved in 10 days. The patient remained asymptomatic with a normal IOP over the next 1 year.

3. Discussion

HSV anterior uveitis typically presents as a unilateral, chronic, and/or recurrent inflammation associated with

keratitis and endotheliitis. Stromal iris atrophy is characteristic of herpetic inflammation and may be patchy or sectoral.⁸ An increase in IOP is a frequent complication of herpetic uveitis and probably because of outflow obstruction caused by inflammatory debris and/or viral trabeculitis.⁸ Although most herpetic uveitis is secondary to corneal diseases, primary HSV iridocyclitis without concomitant keratitis has been reported in the literature and is considered to be a distinct entity among herpetic eye diseases.^{9,10} Our patient had suffered from anterior uveitis with an elevated IOP, diffuse mutton-fat KPs (Fig. 1), and anterior chamber reaction in the right eye. The clinical findings strongly suggested a herpetic infection, which was further confirmed by PCR analysis of the aqueous humor.

CMV anterior uveitis, uncommon in immunocompetent patients, has recently been recognized as a separate entity.^{4,5} It may present with IOP elevation; inflammation in anterior chamber; and variable degree of iris atrophy and KPs as a recurrent, acute, or chronic condition. According to previous reports, some cases may be diagnosed as PSS, herpetic anterior uveitis, or Fuchs heterochromic iridocyclitis initially.^{4,5} Our patient had experienced three episodes of anterior uveitis with a marked elevation of IOP in the left eye. A few round and whitish KPs (Fig. 2), mild inflammatory signs in the anterior chamber, and elevated IOP were observed during active uveitis, which was diagnosed as PSS initially as well. However, CMV was determined to be the offending pathogen after PCR analysis of the aqueous humor. PCR analysis has been used in diagnosis of HSV, VZV, and CMV infections in ocular tissues routinely for many years.¹¹ Because PCR is highly sensitive, to prevent a false-positive result, we always do DNA sequencing to confirm the result once the PCR data are positive.

CMV infection in anterior eye tissues is rare in immunocompetent hosts, but subclinical reactivation of latent CMV has been shown in elderly patients.^{12,13} Long-term CMV infection may be the result of an imbalance in cytokine

production and of reduced T-cell diversity.^{12,14} It is possible that such alterations in immune surveillance could put patients at greater risk of viral uveitis. We hypothesize that HSV anterior uveitis in the current case may have suffered from an immune dysregulation related to a chronic subclinical CMV infection, although the patient had a normal immune status on the basis of routine immunological examinations.

In conclusion, we have reported an elderly immunocompetent patient presented with bilateral anterior uveitis. Two distinct clinical manifestations were caused by two different members of the herpes virus group—HSV and CMV, which was further confirmed by PCR analysis of the aqueous humor sample.

References

1. Yoser SL, Forster DJ, Rao NA. Systemic viral infections and their retinal and choroidal manifestations. *Surv Ophthalmol* 1993;**37**:313–52.
2. Markomichelakis NN, Canakis C, Zafirakis P, Marakis T, Mallias I, Theodossiadis G. Cytomegalovirus as a cause of anterior uveitis with sectoral iris atrophy. *Ophthalmology* 2002;**109**:879–82.
3. Mietz H, Aisenbrey S, Ulrich Bartz-Schmidt K, Bamborschke S, Kriegelstein GK. Ganciclovir for the treatment of anterior uveitis. *Graefes Arch Clin Exp Ophthalmol* 2000;**238**:905–9.
4. De Schryver I, Rozenberg F, Cassoux N, Michelson S, Kestelyn P, Lehoang P, et al. Diagnosis and treatment of cytomegalovirus iridocyclitis without retinal necrosis. *Br J Ophthalmol* 2006;**90**:852–5.
5. Van Boxtel LA, van der Lelij A, van der Meer J, Los LI. Cytomegalovirus as a cause of anterior uveitis in immunocompetent patients. *Ophthalmology* 2007;**114**:1358–62.
6. Koizumi N, Suzuki T, Uno T, Chihara H, Shiraishi A, Hara Y, et al. Cytomegalovirus as an etiologic factor in corneal endotheliitis. *Ophthalmology* 2008;**115**:292–7.
7. Chee SP, Bacsal K, Jap A, Se-Thoe SY, Cheng CL, Tan BH. Corneal endotheliitis associated with evidence of cytomegalovirus infection. *Ophthalmology* 2007;**114**:798–803.
8. Daicker B. Cytomegalovirus panuveitis with infection of corneo-trabecular endothelium in AIDS. *Ophthalmologica* 1988;**197**:169–75.
9. Chang M, van der Horst CM, Olney MS, Peiffer RL. Clinicopathologic correlation of ocular and neurologic findings in AIDS: case report. *Ann Ophthalmol* 1986;**18**:105–6. 110–1.
10. van der Lelij A, Ooijman FM, Kijlstra A, Rothova A. Anterior uveitis with sectoral iris atrophy in the absence of keratitis: a distinct clinical entity among herpetic eye diseases. *Ophthalmology* 2000;**107**:1164–70.
11. van der Lelij A, Rothova A. Diagnostic anterior chamber paracentesis in uveitis: a safe procedure? *Br J Ophthalmol* 1997;**81**:976–9.
12. Almanzar G, Schwaiger S, Jenewein B, Keller M, Herndler-Brandstetter D, Würzner R, et al. Long-term cytomegalovirus infection leads to significant changes in the composition of the CD8+ T-cell repertoire, which may be the basis for an imbalance in the cytokine production profile in elderly persons. *J Virol* 2005;**79**:3675–83.
13. McVoy MA, Adler SP. Immunologic evidence for frequent age-related cytomegalovirus reactivation in seropositive immunocompetent individuals. *J Infect Dis* 1989;**160**:1–10.
14. Fletcher JM, Vukmanovic-Stejic M, Dunne PJ, Birch KE, Cook JE, Jackson SE, et al. Cytomegalovirus-specific CD4+ T cells in healthy carriers are continuously driven to replicative exhaustion. *J Immunol* 2005;**175**:8218–25.