

STATE-OF-THE-ART PAPER

The Dilated Aorta in Patients With Congenital Cardiac Defects

Anji T. Yetman, MD, FACC,* Thomas Graham, MD, FACC†

Salt Lake City, Utah; and Nashville, Tennessee

Many patients with congenital cardiac disease are at risk for progressive aortic dilation. The mechanisms underlying aortic dilation in this patient cohort are described, and the similarities to the pathophysiologic alterations seen in Marfan syndrome are highlighted. Indications for treatment are discussed. (J Am Coll Cardiol 2009;53:461-7) © 2009 by the American College of Cardiology Foundation

Over the last decade there has been an accumulating body of published data documenting progressive aortic dilation in patients with both repaired and unrepaired congenital cardiac defects (1-5). Several explanations might account for this rise in disease recognition, including a growing number of patients with congenital cardiac defects surviving into adulthood, improvements in cardiac imaging, and perhaps most importantly, a shift in the framework in which we conceptualize ascending aortic dilation; moving from a paradigm of aortic dilation as “post stenotic dilation” (6) to one of primary aortopathy (7).

Although the natural history of aortic dilation has been documented in certain genetic disorders, namely Marfan syndrome (8), the natural history and functional significance of aortic dilation in patients with congenital heart disease remains less well defined. While a number of patients with congenital cardiac defects will go on to develop progressive aortic dilation and the attendant complications of aortic valve insufficiency, dissection, or rupture, the risk of these complications in any individual patient remains unknown. As a result of this uncertainty, questions regarding the need for, and timing of, medical and/or surgical therapies have arisen. This review will outline those patients at risk for progressive dilation of the thoracic aorta and explore the common pathophysiologic alterations present in an otherwise seemingly disparate patient group. The role of therapies for preventing aortic dilation will be explored.

Marfan Syndrome: The Prototype for All Other Aortopathies?

Marfan syndrome occurs as a result of a mutation in the *FBN-1* gene encoding for the glycoprotein fibrillin (9).

From the *Adult Congenital Cardiology Program, Departments of Pediatrics and Medicine, Division of Cardiology, Primary Children's Medical Center, The University of Utah, Salt Lake City, Utah; and the †Department of Pediatrics, Division of Cardiology, Vanderbilt University, Nashville, Tennessee.

Manuscript received June 5, 2008; revised manuscript received October 21, 2008, accepted October 26, 2008.

Fibrillin is an integral component of the microfibrils that act as connectors within the aortic media linking vascular smooth muscle cells to the surrounding elastic laminae (10). These connections allow the vessel to retain elasticity, expanding with each cardiac contraction. Fibrillin-1 contains calcium-binding sites that are important in stabilizing the microfibril against degradation by matrix metalloproteinases (MMPs) (10). In the face of an altered or deficient fibrillin product, these connections are lost, resulting in impaired elasticity, vascular smooth muscle cell apoptosis, and vulnerability to further destruction of the surrounding extracellular matrix by MMPs (10). Aneurysm formation is the result.

Maladaptive remodeling of the vascular extracellular matrix is not unique to Marfan syndrome. Altered vascular structure, irrespective of etiology, may lead to an increased propensity for dilation, dissection, or rupture of the aortic wall (11). In 1930, Erdheim (12) coined the term “cystic medial necrosis” to describe the histologic changes seen in the aortic media of patients with Marfan syndrome. Referring to the finding of patchy areas of apoptosis and loss of the surrounding extracellular matrix, “cystic medial necrosis” is now known to be common in patients, both adult and child, with conotruncal defects (13). Abnormalities of the aortic media in these conotruncal defects have been found to be both qualitatively similar and quantitatively identical to Marfan syndrome (13). Whereas an *FBN-1* mutation accounts for the fibrillin deficiency in patients with Marfan syndrome, fibrillin content is also reduced in both the aorta and pulmonary artery of children and adults with a bicuspid aortic valve (BAV) (10,14). The reduction in fibrillin content is not related to the functional state of the valve (14). In addition, the reduction in fibrillin is not typical of aortic aneurysms resulting from excessive shear stress, which typically result in increased fibrillin (10). The reason for fibrillin reduction remains elusive. Mutations in the *FBN-1* gene have not been described in association with BAV.

Abbreviations and Acronyms

ACE = angiotensin-converting enzyme

BAV = bicuspid aortic valve

MMP = matrix metalloproteinase

TGF = transforming growth factor

TIMP = tissue inhibitors of matrix metalloproteinase

Rather, a gene defect involved in regulating the processing of fibrillin-1 into an intact stable matrix component of the vessel wall has been postulated (10). Other gene defects that result in disruption of the extracellular matrix, thereby initiating a cascade of vascular smooth muscle cell apoptosis and MMP-mediated vascular damage, have been implicated in the development of both thoracic aortic and intracranial aneurysms (15).

The MMPs are a family of proteolytic enzymes that degrade various components of the extracellular matrix. Pro-MMPs are cleaved into active forms that promote degradation of matrix proteins. Endogenous tissue inhibitors of metalloproteinases (TIMPs) reduce excessive proteolytic matrix degradation by MMPs. The balance between MMPs and TIMPs is thought to play a critical role in both aortic and intracerebral aneurysm formation, in both patients with and without Marfan syndrome (15,16).

The transforming growth factor (TGF) β superfamily of cytokines plays an important role in vascular remodeling. TGF β is required for maintenance of vascular health (17). Alterations in signaling activity might enhance matrix degradation (11). In its inactive state TGF β -1 is bound to latency-associated protein. It has been theorized that fibrillin plays a key role in sequestering TGF β -1, binding it in an inactive form (18). In this regard, it has been speculated that the vascular damage observed in Marfan syndrome is initiated as a result of a deficient amount of normal fibrillin capable of binding TGF β -1 (18). In support of this theory, administration of TGF β -1-neutralizing antibodies to fibrillin-1-deficient mice prevents vascular damage (18).

Increased TGF β signaling is not limited to the fibrillin-1-deficient mouse but is present in aneurysms of diverse etiology and in diverse locations (11,15,16). Transforming growth factor β -1 might be activated—through cleavage from latency-associated protein—by other substances, including an angiotensin II-mediated increase in thrombospondin-1 and reactive oxygen species (17,19). Extracellular matrix disruption from a variety of causes might result in the presence of fibrillin fragments, which themselves have been shown to be potent stimulators of TGF β (19). Inhibition of vascular damage—and thus reduction of free fibrillin fragments—by inhibition of angiotensin II or inhibition of MMPs results in a reduction in TGF β -1 expression and a reduction in aneurysm formation (17). Conversely, administration of angiotensin II results in aneurysm formation and increased TGF β -1 expression (17).

TGF β -1 Signaling in Cardiac Embryogenesis

Although the role of TGF β in congenital heart disease-related aortopathy has yet to be well-defined, perturbations

in TGF β signaling have been strongly implicated in cardiac neural crest cell migration and the formation of the cardiac outflow tracts (20). It has been postulated that these initial alterations in the TGF β signaling pathway lead to the underlying conotruncal defect and set the stage for future aneurysmal dilation. Lines of support of an underlying embryologic insult responsible for congenital heart disease-associated aortopathy include: 1) patients with BAV have an increased incidence of aneurysms in a variety of neural crest cell derivatives including ascending aortic aneurysm, cervicocephalic aneurysms, and intracranial aneurysms (21); 2) patients with other cardiac defects prone to aortopathy have an increased incidence of cervicocephalic and intracranial aneurysms (22); 3) deletion of the TGF β -1 receptor ALK5 in mouse neural crest cells leads to conotruncal abnormalities associated with progressive aortopathy (20); and 4) histologic abnormalities of the aorta, in those with congenital heart disease-associated aortopathy, are present as early as the neonatal period (13).

Functional Aortic Impairment in Patients With Aortopathy

The aorta, irrespective of size, is stiffer and less distensible in the patient with Marfan syndrome versus a control subject. Impaired distensibility is present in childhood and becomes progressively worse with age. Increased stiffness leads to increased pulse wave reflectance from the periphery, thereby placing a greater stress on the ascending aorta. Whether aortic stiffness merely reflects the degree of histologic abnormality or is in itself responsible for disease progression remains unknown. However, it has been shown that aortic stiffness as measured by magnetic resonance imaging correlates with the rate of aneurysm progression and adverse outcome in patients with Marfan syndrome (23).

Until recently, the vascular properties of the aorta in patients with congenital cardiac defects had not been well-elucidated. Accumulating evidence suggests a similar impairment in aortic distensibility in patients with BAV (24) and tetralogy of Fallot (25). Aortic stiffness is significantly greater in patients with BAV than in control subjects, and this difference remains significant after adjusting for aortic size and blood pressure. Thus, impaired aortic stiffness does not result from aortic dilation but rather exists before dilation and might be instrumental in furthering aneurysmal development (24). In addition to predicting further aortic dilation, increased aortic stiffness in patients with repaired tetralogy of Fallot has been shown to correlate with impaired left ventricular cardiac output (25).

Congenital Cardiac Defects Associated With Aortopathy

BAV. In 1957, McKusick et al. (26) described 4 patients with BAV, “cystic medial necrosis” of the ascending aorta, and associated aortic rupture/dissection. He posited, “The

association of BAV and cystic medial necrosis was more than coincidence" (27). He likened the observed histologic alterations to those seen in Marfan syndrome. Numerous publications of aortic dissection in association with BAV followed. In 1954, Holman (6) coined the term "post-stenotic dilation" to refer to the dilated ascending aorta seen in patients with BAV. This term became part of our daily nomenclature, affecting not only our description of this anatomic alteration but also our conceptualization of the pathologic process. Post-stenotic dilation was not considered a disease entity in itself, and this finding did not invoke the same concern as an identical-sized aorta in a patient with Marfan syndrome. Aortic valve replacement in isolation was commonly performed for aortic valvar dysfunction despite the presence of a dilated aorta. Left untreated, freedom from aorta-related complications after isolated aortic valve replacement in patients with aortic diameters of ≥ 4.5 cm was only 43% at 15 years (28).

More recently, BAV has received greater respect among clinicians (3,7,10,24,28). Given a disease incidence of 1% to 2% of live births (7), a frequency of concomitant aortic dilation of 45% to 50% (3,24,29), and an 8% incidence of dissection or rupture in those with dilation (30), global morbidity and mortality rates associated with BAV aortopathy are staggering. Our understanding of this common disease entity has only begun to evolve. Current research has focused on BAV and thoracic aortic aneurysm as 2 different manifestations of a single embryologic alteration. Data to support this theory include the fact that: 1) patients with BAV have a larger ascending aortic diameter compared with age-matched subjects, irrespective of altered valvar hemodynamics; and 2) in patients with a normally functioning BAV, ascending aortic dilation is seen as early as infancy, and the rate of ascending aortic growth is greater than that of matched control subjects (29). Identified risk factors for aortic dissection in this patient group include: greater aortic stiffness (24), male sex (7), hypertension (30,31), aortic size (32,33), Turner syndrome (32), family history of aortic disease (31), and prior coarctation repair (7).

In light of the silent and asymptomatic nature of aortic dilation and given the high mortality rate associated with aortic dissection (7,30,32), at least annual follow-up for all patients with BAV has been recommended (31) to assess for progressive aortic enlargement. Because the point of maximal dilation is often more cranial than that seen in Marfan syndrome (31,34), imaging modalities other than echocardiography might be required to fully interrogate the ascending aorta. Other recommendations include echocardiographic screening of all first-degree family members with a BAV given a 9% to 16% chance of identifying another affected family member (7,31).

Historically, aortic replacement was performed when the aorta reached 6.0 cm (33). More refined estimates of annual risk of aortic dissection/rupture are now available that take into account not only aortic diameter but patient size (33). Aortic size relative to body size has been found to be a

greater predictor of aortic complications than absolute aortic size (33). For example, a 1.3-m² person with an aortic dimension of 4 cm has a greater risk of dissection than a 2-m² person with an aortic diameter of 6 cm (33). Plotting aortic size for body surface area allows for classification of patients into low, medium, or high risk of developing aortic complications, thus, allowing for more timely surgical intervention (33).

In general terms, the recommendations for patients with BAV and ascending aortic aneurysm are the same as those for patients with Marfan syndrome. The rationale behind such recommendations lies in the fact that aortic dissection occurs at a similar aortic diameter irrespective of whether dilation is due to Marfan syndrome or BAV (35). Surgical intervention for the aorta is indicated at a diameter of 5.0 cm (36). If the aortic valve itself functions normally and is expected to have a longevity of >10 years, it should not be replaced (36). If the indication for surgical intervention is valvar dysfunction, concomitant ascending aortic replacement should be performed if the diameter is 4.5 cm or greater, given the high likelihood of repeat surgical intervention at this diameter (28).

There are accumulating data suggesting that the tensile strength of the aorta is not to be independent of body size. Aortic dilation has previously been underestimated in patients with Turner syndrome, due in large part to the application of the standard adult criteria of >4 cm being used to define the presence of aortic dilation. Recent work has demonstrated a cutoff value of 2 cm/m² for the upper limits of normal for ascending aortic size in women. In patients with Turner syndrome this equates to an absolute value of 3.4 cm above which aortic dissection has been reported to occur (32).

It remains a source of controversy as to whether patients with BAV should undergo a Ross procedure in the event that valve replacement is needed. Progressive aortic dilation, out of keeping with somatic growth, is common in children after the Ross procedure (37). At 6 years out, freedom from aortic dilation (z -score >4) is only 3%, freedom from moderate or greater aortic insufficiency is 60%, and freedom from neo-aortic reintervention is 88% (37). Risk factors for progressive neo-aortic dilation include preoperative ascending aortic diameter, male sex, and post-operative hypertension (38).

Aortic coarctation. The propensity for dilation and dissection of both the ascending and descending aorta in patients with coarctation has long been recognized, with aortic rupture noted to be the most common cause of death occurring in 19% of patients before the current surgical era (39). Average life expectancy for patients with both coarctation and BAV operated on until 1981 was 38 years (40).

Patients remain at risk for ascending aortic dissection or rupture, despite timely and successful relief of arch obstruction. (4). Type of surgical repair, age at initial repair, presence of residual Doppler pressure gradient, or systemic hypertension have not been noted to predict late aneurysm

formation (4). Aneurysms may occur in the ascending aorta formation, the coarctation repair site, or in the descending thoracic aorta, distal to the repair site (4). "Cystic medial necrosis" is visible within the aortic media in the first 24 h after birth, again supporting a primary aortopathy (39).

The only predictors of ascending aortic aneurysm in patients with repaired coarctation include the presence of a BAV and age at follow-up with a risk ratio of 1.4 for every decade followed (4). Aneurysm formation at or adjacent to the coarctation site relates to presence of a BAV, patch angioplasty, and older age at repair with a cutoff value of >13.5 years (4).

Because BAV is present in >50% of patients with coarctation, close surveillance of the ascending aorta as well as the descending aorta is required. Magnetic resonance or computed tomographic angiography is required for adequate imaging in the older patient.

Tetralogy of Fallot. Single case reports of progressive ascending aortic dilation began appearing in the early 1970s (41). Small case series followed. It was not until the 1990s that the frequency of ascending aortic dilation was described as occurring in 48% of patients (42).

Histologic abnormalities of the aortic media in patients with tetralogy of Fallot are similar to that seen in patients with Marfan syndrome (17) and have been noted as early as a few days of age (43). Histologic alterations are present irrespective of the size of the ascending aorta (43). Increased aortic stiffness has been documented in both children and adults with repaired tetralogy of Fallot (25).

Risk factors for progressive aortic dilation include the presence of pulmonary atresia, right aortic arch, history of an aortopulmonary shunt, male sex, and the presence of a 22q11 deletion (44).

Clinical data on the clinical relevance of these histologic and functional abnormalities are accumulating. Whereas prior to this decade only rare case reports of progressive aortic dilation in tetralogy of Fallot existed, recent reports have quantitated the problem. Niwa et al. (1) noted marked ascending aortic dilation in 15% of adults with repaired tetralogy of Fallot, with the need for surgical intervention in 12%. The ascending aorta should be imaged on a yearly basis in all patients with tetralogy of Fallot if a progressive increase in aortic diameter, defined as an increase in aortic z-score, has been noted.

The risk of dissection in this patient cohort is being increasingly recognized (1). All dissections have occurred in patients with aortic diameters >5.5 cm, thus begging the question as to whether ascending aortic replacement should be undertaken in those patients with an aortic diameter of ≥ 55 mm. Measurement of aortic stiffness (25) and aortic curvature as well as consideration of patient body size (33) might enable us to further risk-stratify such patients.

D-transposition of the great arteries. It is only of late that a large group of patients with d-TGA are surviving into adulthood. Although pathologic aortic dilation and dysfunction have been reported after the Mustard procedure

(7), this problem has been largely overshadowed by progressive ventricular dysfunction, arrhythmias, and sudden death. The incidence of neo-aortic dysfunction has been better quantitated after the arterial switch operation (45), but given its relative infancy, the magnitude of this problem cannot be fully appreciated.

Schwartz et al. (46) assessed 335 patients after a median follow-up of 5 years and found that at 10 years post-operation only one-half of patients were free from dilation of the neo-aortic root, defined as a z-score >3. Risk factors for dilation included previous pulmonary artery banding and later date of surgery. Predictors of neo-aortic insufficiency include coronary re-implantation technique, discrepancy in great vessel size, ventricular septal defect, and rapid development of aortic dilation (45). Some patients have gone on to require neo-aortic valvar repair or replacement (45). Aortic dilation, in addition to carrying the risk of aortic rupture, might affect coronary geometry and impair coronary perfusion (47). Because of the relatively recent recognition of this medical problem, clear guidelines for surgical reintervention are lacking. Progressive aortic insufficiency and established size criteria used for BAV might be applicable. Aortic geometry might play, as in the patient with BAV, a key role in predisposing to progressive aortic dilation (48). Patients with acute angulation of the aortic arch after an arterial switch operation have greater pulse wave reflection, aortic dilation, and insufficiency (48).

Other lesions. Aortic and pulmonary arterial dissection have been reported in association with other cardiac outflow tract defects, including unrepaired truncus arteriosus (49), aortopulmonary window (50), and patent ductus arteriosus (51), highlighting the importance of the histologic abnormalities identified in the pulmonic trunk if placed under systemic pressure.

Medical Management

Given the relative frequency and the striking histologic and functional similarities in aortic pathology between patients with Marfan syndrome and patients with congenital heart disease-related aortopathy, it seems reasonable to adopt a medical regimen that has proven beneficial to patients with Marfan syndrome. Unfortunately, there continues to be great controversy as to what, if any, medical treatments are beneficial to the patient with Marfan syndrome. Historically, β -blocker drugs were routinely used to treat patients with Marfan syndrome. However, critical review of the published data (52) demonstrates a complete absence of studies demonstrating a reduction in risk of aortic dissection, rupture, or aortic insufficiency in patients treated with β -blockade. This class of drugs is associated with a relatively high incidence of side effects (53), and given the paucity of data suggesting clinical benefit, their use seems largely unwarranted. Despite this, β -blocker drugs remain the mainstay of therapy in many centers. This practice largely reflects the lack of other well-studied medications. Unfor-

tunately, the routine practice of β -blockade in patients with Marfan syndrome is, in itself, what has prevented other drugs from being evaluated.

Both enhanced TGF β -1 and MMP-2 expression and other downstream events of angiotensin-II signaling point to angiotensin-II signaling pathways as targets for prevention of aneurysm formation (17). Data on the use of angiotensin-converting enzyme (ACE) inhibitors in humans with Marfan syndrome have shown short- and medium-term clinical benefit (53,54). ACE inhibitors block formation of angiotensin-II, thereby decreasing TGF β -1 activity both directly and indirectly through reduction of reactive oxygen species and thrombospondin, as well as decrease MMP activation, restore MMP/TIMP balance, and increase the vasodilator bradykinin (Fig. 1).

Angiotensin receptor blocker drugs have been shown to improve aortic wall architecture in the Marfan mouse model in association with a reduction in TGF β activity (18).

However, in vitro studies demonstrate only ACE inhibitor and not angiotensin receptor blocker drugs to be effective in preventing histologic abnormalities and normalizing TGF β activity (55,56).

Doxycycline has been demonstrated to be an effective inhibitor of MMPs. It has been shown to affect aneurysm progression in adults with abdominal aortic aneurysms and recently has been shown to have a beneficial role in reduction in aortic MMP levels in Marfan animal models (57).

Summary

Over the last decade there has been exponential growth in documentation of progressive aortic pathology in patients with congenital cardiac disease. As this cohort of patients continues to survive into adulthood, the magnitude of this problem will be better clarified. With improved understanding of the underlying pathophysiology, we are now better

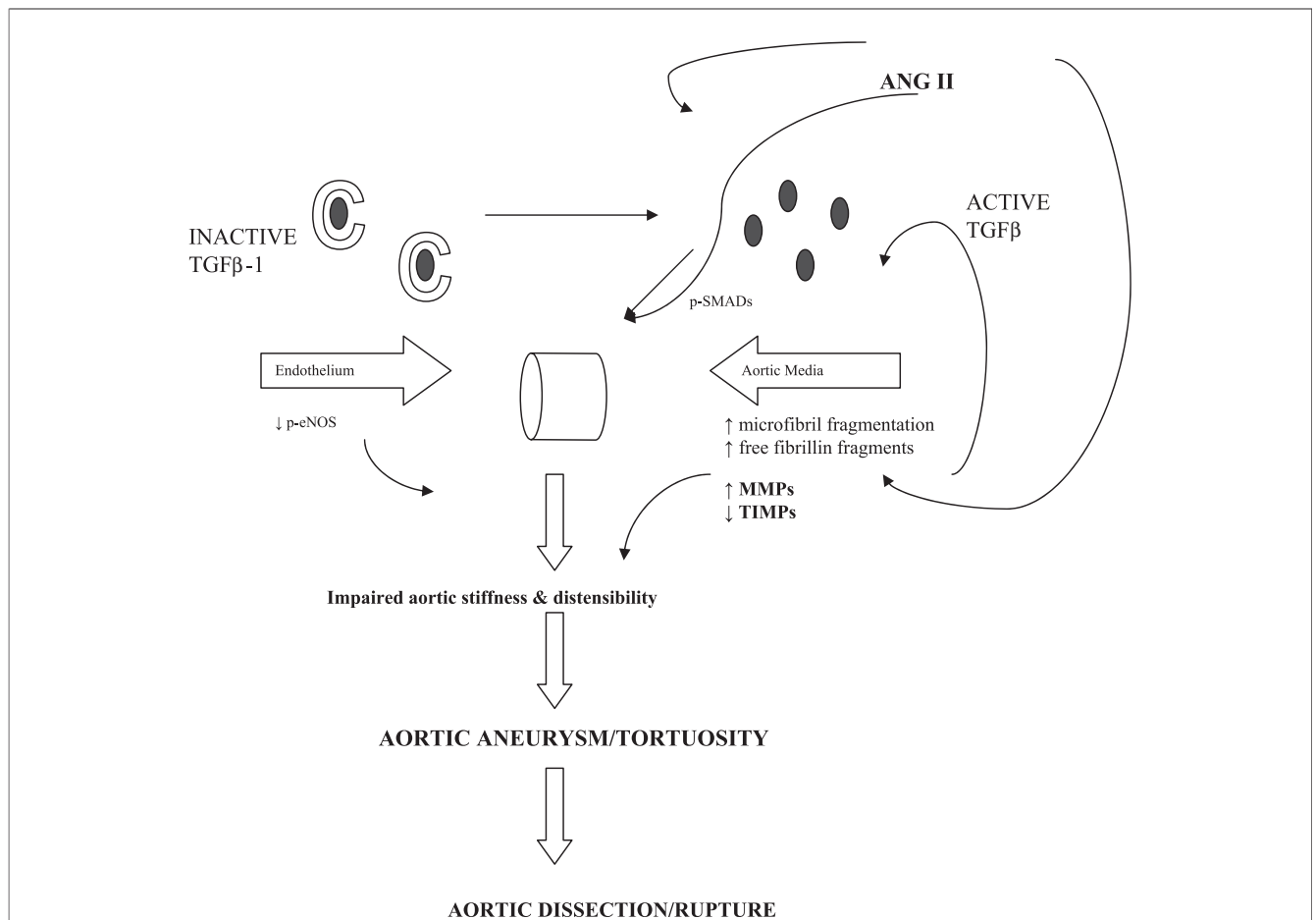


Figure 1 Summary of Proposed Aneurysm-Promoting Mechanisms and Sites of Medical Therapies

Active transforming growth factor (TGF) β plays a key role in aneurysm formation. Increased active TGF β occurs in the setting of fibrillin deficiency (bicuspid aortic valve, Marfan syndrome) or in the presence of substances that cleave TGF β from latency-associated protein (angiotensin II [ANG II]-dependent thrombospondin and reactive oxygen species). The TGF β and ANG II activity leads to matrix metalloproteinase (MMP)-mediated alterations in vascular endothelium and aortic media, resulting in impaired aortic distensibility. Aortic dilation presenting as aneurysm or increased tortuosity follows. At a critical relative aortic diameter, dissection/rupture occurs. p-eNOS = phosphorylated endothelial nitric oxide synthase; p-SMAD = phosphorylated SMAD protein; TIMP = tissue inhibitors of matrix metalloproteinase.

equipped to study potentially effective medical therapies in these patients. However, despite this realization, there remains a paucity of data assessing the use of any medical therapy in this patient cohort. The many histological and functional similarities between these patients and those with Marfan syndrome behoove us to study, in the former group of patients, the impact of medical treatments found beneficial in the latter. Multicenter trials of medical therapies to prevent progressive aortic pathology in patients with congenital heart disease-related aortopathy are greatly needed.

Reprint requests and correspondence: Dr. Anji T. Yetman, Professor of Pediatrics, Adjunct Professor, Medicine, Director, Marfan Cardiology Program, Director, Adult Congenital Cardiology Program, University of Utah, Primary Children's Medical Center, 100 N. Mario Capecchi Drive, Salt Lake City, Utah, 84108. E-mail: Angela.Yetman@imail.org.

REFERENCES

1. Niwa K, Siu SC, Webb GD, Gatzoulis MA. Progressive aortic root dilatation in adults later after repair of tetralogy of Fallot. *Circulation* 2002;106:1374-8.
2. McMahan CJ, Ravekes WJ, Smith EO, et al. Risk factors for neo-aortic root enlargement and aortic regurgitation following arterial switch operation. *Pediatr Cardiol* 2004;25:329-35.
3. Tzemos N, Therrien J, Yip J, et al. Outcomes in adults with bicuspid aortic valves. *JAMA* 2008;300:1317-25.
4. Oliver JM, Gallego P, Gonzalez A, Aroca A, Bret M, Mesa JM. Risk factors for aortic complications in adults with coarctation. *J Am Coll Cardiol* 2004;44:1641-7.
5. Ono M, Goerler H, Boethig D, Westhorr-Bleck M, Hartung D, Breyman T. Valve-sparing operation for aortic root aneurysm late after Mustard procedure. *Ann Thorac Surg* 2007;83:2224-6.
6. Holman E. The obscure physiology of poststenotic dilatation; its relation to the development of aneurysms. *J Thorac Surg* 1954;28:109-33.
7. Friedman T, Mani A, Elefteriades JA. Bicuspid aortic valve: clinical approach and scientific review of a common clinical entity. *Expert Rev Cardiovasc Ther* 2008;6:235-48.
8. Silverman DI, Burton KJ, Gray J, et al. Life expectancy in the Marfan syndrome. *Am J Cardiol* 1995;75:157-60.
9. Dietz HC, Cutting GR, Pyeritz RE, et al. Marfan syndrome caused by a recurrent de novo missense mutation in the fibrillin gene. *Nature* 1991;352:337-9.
10. Fedak PW, de Sa MP, Verma S, et al. Vascular matrix remodeling in patients with bicuspid aortic valve malformations: implications for aortic dilation. *J Thorac Cardiovasc Surg* 2003;126:797-806.
11. Jones JA, Barbour JR, Stroud RE, et al. Altered transforming growth factor-beta signaling in a murine model of thoracic aortic aneurysm. *J Vasc Res* 2008;45:7-68.
12. Erdheim J. Medionecrosis aortae idiopathica cystic. *Virchows Arch Pathol Anat* 1930;276:187-229.
13. Niwa K, Perloff JK, Bhuta SM, et al. Structural abnormalities of great arterial walls in congenital heart disease. *Circulation* 2001;103:393-413.
14. Huang P, Wang HW, Li Y, et al. Expression of fibrillin-1 in congenital bicuspid aortic valves. *Zhonghua Yi Xue Za Zhi* 2007;87:1549-52.
15. Ruijgrok YM, Rinkel GJ, van't Slot R, Wolfs M, Tang S, Wijmenga C. Evidence in favor of the contribution of genes involved in the maintenance of the extracellular matrix of the arterial wall to the development of intracranial aneurysms. *Hum Mol Genet* 2006;15:3361-8.
16. Ikonomidis D, Jones JA, Barbour JR, et al. Expression of matrix metalloproteinases and endogenous inhibitors within ascending aortic aneurysms of patients with Marfan syndrome. *Circulation* 2006;114:1365-70.
17. Gordon KJ, Blobel GC. Role of transforming growth factor-beta superfamily signaling pathways in human disease. *Biochimica et Biophysica Acta* 2008;1782:197-228.
18. Habashi JP, Judge DP, Holm TM, et al. Losartan, an AT1 antagonist, prevents aortic aneurysm in a mouse model of Marfan syndrome. *Science* 2006;312:117-21.
19. Chaudhry SS, Cain SA, Morgan A, Dallas SL, Shuttleworth A. Fibrillin-1 regulates the bioavailability of TGF-beta-1. *J Cell Biol* 2007;176:355-67.
20. Wang J, Nagy A, Larsson J, et al. Defective ALK5 signaling in the neural crest leads to increased postmigratory neural crest apoptosis and severe outflow tract defects. *BMC Dev Biol* 2006;6:51-60.
21. Schievink WI, Mokri B. Familial aorto-cervicocephalic arterial dissections and congenitally bicuspid aortic valve. *Stroke* 1995;26:1935-40.
22. Schievink WI, Mokri B, Piepgras DG, Gittenberger-de-Groot AC. Intracranial aneurysms and cervicocephalic arterial dissections associated with congenital heart disease. *Neurosurgery* 1996;39:685-9.
23. Nollen GJ, Groenink M, Tjissen JG, et al. Aortic stiffness and diameter predict progressive aortic dilatation in patients with Marfan syndrome. *Eur Heart J* 2004;25:1146-52.
24. Nistri S, Grande-Allen J, Noale et al. Aortic elasticity and size in bicuspid aortic valve syndrome. *Eur Heart J* 2008;29:472-9.
25. Senzaki H, Iwamoto Y, Ishido H et al. Arterial haemodynamics in patients after repair of tetralogy of Fallot: influence on left ventricular after load and aortic dilation. *Heart* 2008;94:70-4.
26. McKusick VA, Logue RB, Bahnson HT. Association of valvular disease and cystic medial necrosis of the ascending aorta; report of four instances. *Circulation* 1957;16:188-94.
27. McKusick VA. Association of congenital bicuspid aortic valve and Erdheim's cystic medial necrosis. *Lancet* 1972;1:1026-7.
28. Borger MA, Preston M, Ivanov J, et al. Should the ascending aorta be replaced more frequently in patients with bicuspid aortic valve disease? *J Thorac Cardiovasc Surg* 2004;128:677-83.
29. Beroukhi RS, Kruzick TL, Taylor AL, Gao D, Yetman AT. Progression of aortic dilation in children with a functionally normal bicuspid aortic valve. *Am J Cardiol* 2006;98:828-30.
30. Davies RR, Kaple RK, Mandapati D, et al. Natural history of ascending aortic aneurysm in the setting of an unreplaced bicuspid aortic valve. *Ann Thorac Surg* 2006;83:1338-44.
31. Boyer JK, Gutierrez F, Braverman AC. Approach to the dilated aortic root. *Curr Opin Cardiol* 2004;19:563-9.
32. Matura LA, Ho VB, Rosing DR, Bondy CA. Aortic dilation and dissection in Turner syndrome. *Circulation* 2007;116:1663-70.
33. Davies RR, Gallo A, Coady MA, et al. Novel measurement of relative aortic size predicts rupture of thoracic aortic aneurysms. *Ann Thorac Surg* 2006;81:169-77.
34. Beroukhi RS, Roosevelt G, Yetman AT. Comparison of the pattern of aortic dilation in children with the Marfan's syndrome versus children with a bicuspid aortic valve. *Am J Cardiol* 2006;98:1094-5.
35. Januzzi JL, Isselbacher EM, Fattori R, et al. Characterizing the young patient with aortic dissection: results from the international registry of aortic dissection (IRAD). *J Am Coll Cardiol* 2004;43:665-9.
36. Bonow RO, Carabello B, Chatterjee K, et al. ACC/AHA 2006 guidelines for the management of patients with valvular heart disease: a report of the American College of Cardiology/American Heart Association Task Force on Practice Guidelines (Writing Committee to Develop Guidelines for the Management of Patients With Valvular Heart Disease). *J Am Coll Cardiol* 2006;48:e1-148.
37. Pasquali SK, Shera D, Wernovsky G, et al. Midterm outcomes and predictors of reintervention after the Ross procedure in infants, children, and young adults. *J Thorac Cardiovasc Surg* 2007;133:893-9.
38. Brown JW, Ruzmetov M, Rodefeld MD, Mahomed Y, Turrentine MW. Incidence of and risk factors for pulmonary autograft dilation after Ross aortic valve replacement. *Ann Thorac Surg* 2007;83:1781-7.
39. Vogt M, Kuhn A, Baumgartner D, et al. Impaired elastic properties of the ascending aorta in newborns before and early after successful coarctation repair: proof of a systemic vascular disease of the pre-stenotic arteries? *Circulation* 2005;111:3269-73.
40. Cohen M, Fuster V, Steele PM, et al. Coarctation of the aorta. Long-term follow-up and prediction of outcome after surgical correction. *Circulation* 1989;80:840-5.
41. Peters RM. Total repair of tetralogy of Fallot and replacement of aortic valve with Starr-Edwards prosthesis. Case report. *J Thorac Cardiovasc Surg* 1971;61:599-601.

42. Jonsson H, Ivert T, Brodin LA. Echocardiographic findings in 83 patients 13-26 years after intracardiac repair of tetralogy of Fallot. *Eur Heart J* 1995;69:1255-63.
43. Tan JL, Davlouros PA, McCarthy KP, Gatzoulis MA, Ho SY. Intrinsic histologic abnormalities of aortic root and ascending aorta in tetralogy of Fallot 2005;112:961-8.
44. Niwa K. Aortic root dilatation in tetralogy of Fallot long-term after repair-histology of the aorta in tetralogy of Fallot: evidence of intrinsic aortopathy. *Int J Cardiol* 103:117-9.
45. Cohen MS, Wernovsky G. Is the arterial switch operation as good over the long term as we thought it would be? *Cardiol Young* 2006;16:117-24.
46. Schwartz ML, Gauvreau K, del Nido P, Mayer JE, Colan SD. Long-term predictors of aortic root dilation and aortic regurgitation after arterial switch operation. *Circulation* 2004;110:128-32.
47. McMahon CJ, Nihill MR, Denfield S. Neoartical root dilation associated with left coronary stenosis following arterial switch procedure. *Pediatr Cardiol* 2003;24:43-6.
48. Agnoletti G, Ou P, Celermajer DS, et al. Acute angulation of the aortic arch predisposes a patient to ascending aortic dilation and aortic regurgitation late after the arterial switch operation for transposition of the great arteries. *J Thorac Cardiol Surg* 2008;135:568-72.
49. Gutierrez PS, Binotto MA, Aiello VD, Mansur AJ. Chest pain in an adult with truncus arteriosus communis. *Am J Cardiol* 2004;93:272.
50. Le Bret E, Lupoglazoff JM, Bachet, et al. Pulmonary artery dissection and rupture associated with an aortopulmonary window. *Ann Thorac Surg* 2004;78:e67-8.
51. Khush KK, Randhawa R, Israel E. A full house: complications from an uncorrected patent ductus arteriosus *Curr Cardiol Rep* 2005;7:310-3.
52. Gersony DR, McClaughlin MA, Jin Z, Gersony WM. The effect of beta-blocker therapy on clinical outcome in patients with Marfan's syndrome: a meta-analysis. *Int J Cardiol* 2007;114:303-8.
53. Yetman AT, Bornemeier RA, McCrindle BW. Usefulness of enalapril versus propranolol or atenolol for prevention of aortic dilation in patients with the Marfan syndrome. *Am J Cardiol* 2005;95:1125-7.
54. Ahimastos AA, Aggarwal A, D'Orsa KM, et al. Effect of perindopril on large artery stiffness and aortic root diameter in patients with Marfan syndrome: a randomized controlled trial. *JAMA* 2007;298:1539-47.
55. Redondo S, Ruiz E, Padilla E, Gordillo-Moscoso A, Tejerina T. Role of TGF β -1 in vascular smooth muscle cell apoptosis induced by angiotensin II. *Eur J Pharm* 2007;556:36-44.
56. Nagashima H, Uto K, Sakomura Y, et al. An angiotensin-converting enzyme inhibitor, not an angiotensin II type-1 receptor blocker, prevents beta-aminopropionitrile monofumarate-induced aortic dissection in rats. *J Vasc Surg* 2002;36:818-23.
57. Chung AWY, Yang HHC, Radomski MW, van Breemen C. Long term doxycycline is more effective than atenolol to prevent thoracic aortic aneurysm in Marfan syndrome through the inhibition of matrix metalloproteinase-2 and -9. *Circulation Res* 2008;102:1-13.

Key Words: aneurysm ■ aorta ■ dissection.