

## Reduced parietal activation in cervical dystonia after parietal TMS interleaved with fMRI

Paulien M. de Vries<sup>a,b,\*</sup>, Bauke M. de Jong<sup>a,b</sup>, Daryl E. Bohning<sup>c,d</sup>, Vanessa K. Hinson<sup>e,f</sup>, Mark S. George<sup>c,d,g</sup>, Klaus L. Leenders<sup>a,b</sup>

<sup>a</sup> Department of Neurology, University Medical Center Groningen, University of Groningen, The Netherlands

<sup>b</sup> Neuroimaging Center, Institute of Behavioral and Cognitive Neuroscience, University of Groningen, The Netherlands

<sup>c</sup> Center for Advanced Imaging Research, Medical University of South Carolina, Charleston, SC, USA

<sup>d</sup> Department of Radiology, Medical University of South Carolina, Charleston, SC, USA

<sup>e</sup> Department of Neurosciences, Medical University of South Carolina, Charleston, SC, USA

<sup>f</sup> Murray Center for Research on Parkinson's Disease and Related Disorders, Medical University of South Carolina, Charleston, SC, USA

<sup>g</sup> Brain Stimulation Laboratory, Medical University of South Carolina, Charleston, SC, USA

### ARTICLE INFO

#### Article history:

Received 20 December 2010

Received in revised form 4 February 2012

Accepted 6 February 2012

Available online 2 March 2012

#### Keywords:

Parietal cortex  
Interleaved TMS/fMRI  
Hand movement  
Cervical dystonia

### ABSTRACT

**Objective:** Clinically normal hand movement with altered cerebral activation patterns in cervical dystonia (CD) may imply cerebral adaptation. Since impaired sensorimotor integration appears to play a role in dystonia, left superior parietal cortex modulation with repetitive transcranial magnetic stimulation (TMS) was employed to further challenge adaptation mechanisms reflected by changes in cerebral activation.

**Methods:** Seven CD patients and ten healthy controls were scanned on a 3T magnetic resonance imaging (MRI) scanner with 1 Hz inhibitory interleaved TMS. They executed and imagined right wrist flexion/extension movements. Each task was preceded by a 10-s period with or without TMS.

**Results:** The activations of both tasks after TMS in controls showed a similar pattern as found in CD without TMS, i.e. activation increases in bilateral prefrontal and posterior parietal regions during both tasks and decreases in right anterior parietal cortex during imagery ( $P < 0.001$ ). The activations of both tasks after TMS in CD were weaker but with a similar trend in activation changes. Only in the right angular gyrus, TMS significantly failed to induce an activation increase in CD as was seen in the controls ( $P < 0.001$ ).

**Conclusion:** The similarity between TMS effects on the distribution of cerebral activations in controls and the pattern seen in CD may support the concept that CD make use of compensatory circuitry enabling clinically normal hand movement. The fact that a similar but weaker TMS effect occurred in CD could suggest that the capacity of compensation is reduced. Particularly for the right angular gyrus, this reduction was statistically significant.

© 2012 Elsevier B.V. Open access under the [Elsevier OA license](#).

### 1. Introduction

Cervical dystonia (CD) is defined as a movement disorder with abnormal involuntary muscle contractions and postures of head and neck. The execution of hand movement seems clinically normal. However, we have recently demonstrated with functional magnetic resonance imaging (fMRI) that the cerebral organization underlying hand movements in CD differs from normal [1], while subtle changes in muscle contraction were also found by electromyography [2]. The association of apparent normal hand

function and deviant distribution of cerebral activation might suggest a flexibility of the brain to adapt to impaired cortical function by recruiting other cortical areas to perform the desired task. This issue was further addressed in the present study.

The cause of CD is unknown, although, neuroimaging studies have reported abnormal function of brain areas during task performance in dystonic body parts. Basal ganglia and prefrontal cortex were overactivated in a positron emission tomography (PET) study with joystick movement in patients with idiopathic torsion dystonia [3] and in a review of PET studies with hand movement in focal hand dystonia [4]. Two fMRI studies employing finger tapping in focal hand dystonia [5] and movement and imagery of wrist flexion/extension movements in dystonia associated with complex regional pain syndrome [6] showed underactivation in the primary sensorimotor cortex and adjacent sensorimotor-related areas. In contrast, in other fMRI and PET studies performing hand

\* Corresponding author at: Free University Medical Center, Department of Neurology (VNEU), PO Box 7057, 1007 MB Amsterdam, The Netherlands.  
Tel.: +31 20 4442800; fax: +31 20 4441988.

E-mail address: [pm.devries@vumc.nl](mailto:pm.devries@vumc.nl) (P.M. de Vries).

movements in task-specific dystonia these regions were overactivated [7,8].

The parietal cortex plays an important role in the higher-order sensory processing by integrating information on (visuo)spatial perception, body scheme and proprioception in order to prepare (spatial) movement [9,10]. Changes in activation may reflect deficits in processing and integration of this sensory information. This concept is supported by various observations. A sudden deficit in sensory signaling is reflected in 5–21% of CD who had an injury in the neck prior to the onset of dystonic symptoms [11]. Changing sensory or proprioceptive feedback is demonstrated in the use of sensory tricks in CD. Performance of these maneuvers can temporarily alleviate dystonic symptoms. Interestingly, imagery of sensory tricks alone can be sufficient to modulate these sensorimotor networks and improve symptoms [12]. One might thus infer that there is a lack of sufficient sensory information processing in CD. Naumann et al. argued that adding sensory information by applying a sensory trick particularly enables antero-ventral parts of the parietal cortex, containing the secondary sensory areas, to temporarily switch of the dystonic drive [13]. Interestingly, in CD voxel-based morphometric structural changes have also been reported in the specific parts of the parietal cortex containing the integration of sensory information [14]. Thus, impaired sensorimotor function seems to play an important role in the aetiology of dystonia [1,15].

These wide-spread cerebral network changes seen in parietal, prefrontal cortices and basal ganglia in CD may seem at odds with the fact that dystonic symptoms are usually only localized in one body part, particularly in the neck, while movements in other body parts seem clinically normal. However, investigation of CD with fMRI during movement of a non-dystonic body part resulted in similar abnormal cerebral activations as during dystonic movement [1]. It was hypothesized that this association between reduced activation in movement-associated brain regions and clinically normal movement performance may imply effective compensation mechanisms in CD. The brain's ability to adapt to new situations can be observed in clinical neurological conditions [16,17]. Another way to explore these adaptation mechanisms is to modulate neural networks with transcranial magnetic stimulation (TMS). TMS is produced by a magnetic pulse that can induce an electric current in the brain. It creates an action potential in the cells that can have either a stimulatory or inhibitory effect on neural networks depending on the stimulation parameters. By applying a 1 Hz inhibitory train of pulses TMS can disrupt cerebral activity (e.g. creating a temporary virtual lesion) in order to explore the functional relevance of the targeted area and reorganization of its connected neural networks [18]. Compensational activation to TMS applied virtual lesions has been demonstrated in target areas as primary motor cortex [19], dorsal premotor regions [20] and dorsolateral prefrontal cortex [21]. Compensation also appears to

occur after TMS induced modulation of the superior parietal cortex in healthy controls (HC); 'compensatory' increases were seen in posterior parietal and prefrontal networks during hand movement execution and imagery [22].

As similar patterns of changed activation were observed in CD and HC after TMS, a mechanism of compensation is suggested indeed. The present study aimed to investigate whether such compensation can be further challenged by TMS in CD. We expected increased activation with maintained ability to perform clinically normal movement in a non-dystonic body part. We therefore introduced movement execution and imagery tasks. Movement imagery is in the same class of neural processing as movement preparation, neural circuits required prior to movement execution are expected to be activated during movement imagery. These circuits contain precentral sulcus, prefrontal, posterior superior parietal, subcortical and cerebellar regions, while little imagery-related activity is expected in primary motor and sensory areas [1,23]. The advantage of a movement imagery task is that it enables the study of these circuits without the blurring effect of sensory feedback, as seen during movement execution [24]. In order to challenge possible compensatory networks, we chose to induce virtual TMS lesions on the superior parietal cortex. Effects of changes in activation during the motor tasks were measured directly with fMRI (interleaved TMS/fMRI [25]). The choice of the superior parietal cortex was based on fMRI studies which show underactivation in this specific area [1,5]. Further inhibition of this region with TMS might stress compensatory networks even more. These compensatory networks are assumed to contain (i) the prefrontal cortex, previously seen overactivated in CD, presumably as adaptation to impaired parietal function, and (ii) posterior parietal regions, showing adaptive increases in HC after superior parietal cortex modulation.

## 2. Materials and methods

### 2.1. Subjects

Seven CD patients (mean age  $57 \pm 16$  (SD), 6 females) and ten age-matched HC (mean age  $53 \pm 11$  (SD); 8 females) were studied. Six patients had CD (one with concurrent spasmodic dysphonia), one had generalized dystonia (DYT1 mutation carrier negative). All patients presented with CD as leading symptom (Table 1). Subjects signed informed consent approved by the Medical University of South Carolina institutional review board. All were right-handed (Annett Handedness Scale [26]). No subject had a medical history of neurological disorders except primary dystonia. Each subject underwent one 15-min session during which the effect of interleaved TMS/fMRI was assessed.

**Table 1**  
Subject characteristics.

|                   | Gender | Age | Predominant dystonic movement | Additional symptoms    | Treatment for dystonia   |
|-------------------|--------|-----|-------------------------------|------------------------|--|
| Cervical dystonia |        |     |                               |                        |  |
| 1                 | F      | 48  | Left laterocollis             | Upper extremity tremor | Botulinum toxin (18 days <sup>a</sup> )  |
| 2                 | F      | 79  | Right laterocollis            | None                   | None   |
| 3                 | F      | 65  | Left laterocollis             | Generalized dystonia   | Botulinum toxin (91 days <sup>a</sup> )  |
| 4                 | F      | 71  | Left laterocollis             | Upper extremity tremor | Botulinum toxin (24 days <sup>a</sup> )  |
| 5                 | F      | 25  | Right laterocollis            | None                   | Botulinum toxin (48 days <sup>a</sup> ), trihexyphenidyl, tizanidine, clonazepam |
| 6                 | M      | 54  | Anterocollis                  | Spasmodic dysphonia    | Trihexyphenidyl  |
| 7                 | F      | 66  | Right laterocollis            | None                   | Clonazepam   |
| Mean $\pm$ SD     |        |     | 57 $\pm$ 16                   |                        |  |
| Healthy controls  |        |     |                               |                        |  |
| 1–10              | 8F, 2M |     |                               |                        |  |
| Mean $\pm$ SD     |        |     | 53 $\pm$ 11                   |                        |  |

<sup>a</sup>The time between botulinum toxin injections and MRI scan.

## 2.2. Behavioral task

Subjects performed both movement execution and imagery tasks to assess parietal TMS-induced activation changes in circuitry supporting higher-order motor control. Although movement imagery has been used before in neuroimaging studies [23], it remains difficult to check such task performance during MR scanning. We determined imagery performance of subjects during a visit to the clinic a few weeks prior to the start of the experiment. Recruited subjects had an average image performance based on the Vividness of Movement Imagery Questionnaire [27] and the speed of performance task. The questionnaire was based on two self-report lists that evaluate the ability to imagine several movements as done by themselves (first-person perspective) or others (third-person perspective) [28]. Although CD had a higher score on the questionnaire than controls, this difference was not significant (Table 2). In the speed of performance task, two cycles of 10 movement executions and 10 imagery movements were timed. This test showed that it took CD significantly longer to imagine 10 cycles of hand movement than controls ( $P=0.013$ ; Table 2).

During fMRI, subjects performed right-hand tasks successively in executive, imagery or rest mode. Tasks were monitored with EMG recording of the right hand. Before the experiment started, subjects practiced the tasks for 5 min. During practice, right after scanning (to evaluate the tasks during scanning) and 30 min after scanning, respectively, subjects scored the task difficulty on a 1–5 scales (impossible–normal). Both groups rated movement execution during scanning significantly harder than during practice ( $P=0.037$ ; Table 2(A)).

## 2.3. Experimental procedure

We used interleaved TMS/fMRI in a 3T MRI scanner (Philips, Best, the Netherlands) with specially built head coil for TMS (Nova Medical Inc., Wakefield, MA, USA). BOLD sensitive single-shot echo-planar imaging (EPI)-fMRI images were acquired continuously (repetition time (TR)=2300 ms, FOV=23 cm, 23 slices of 3.5 mm thickness with  $64 \times 64$  matrix for 392 time points). The stimulation was performed using a Magstim Rapid® (The Magstim Company Ltd, Whitland, Wales, UK) with special non-ferromagnetic, figure-of-eight TMS coil. The coil was connected to an eight meter long cable and a custom filter box outside the magnet room [25]. During scanning, individual TMS pulses at an inhibitory frequency of 1 Hz and 115% of motor threshold intensity were applied over the left superior parietal cortex [Montreal Neurological Institute (MNI) stereotactic space coordinates  $x -24, y -60, z 68$ ] in trains of 10 pulses.

### 2.3.1. Synchronization TMS with fMRI

The synchronization of TMS and the fMRI acquisition was determined by a pulse sent out by the MRI at the beginning of each TR period. Lab View software (National Instruments, Austin, TX, USA) picked up these pulses and maintained a pulse count. It then triggered the TMS pulse based on an event list with the TR period and the delay in milliseconds into that TR period for insertion of the TMS pulse. The TR period was 2300 ms divided into 23 slices scanned at 100 ms intervals. In order to prevent the firing of the TMS pulse during the fMRI acquisition radio frequency excitation pulse, the TMS pulses were always inserted 19 ms after the start of a 100 ms slice acquisition period. Each series of TMS pulses consisted of a train of 10 pulses, one each second, at 1 Hz frequency. For example, if the first TMS came at 19 ms into the first TR, the second pulse would come at 1019 ms, the third at 2019 ms, and the fourth at 3019 ms, or  $3019-2300=719$  ms into the second TR. Despite the firing of the TMS so that it missed the radio frequency excitation pulses, the after-effects of the pulse sometimes resulted in partial compromising of the slice currently being acquired. By either increasing the TR, or reducing the number of slices we could have made the slice acquisition interval long enough to insert the TMS pulse without compromising those images, but that would have made either the scan too long or would have forced us to use slices that were too thick.

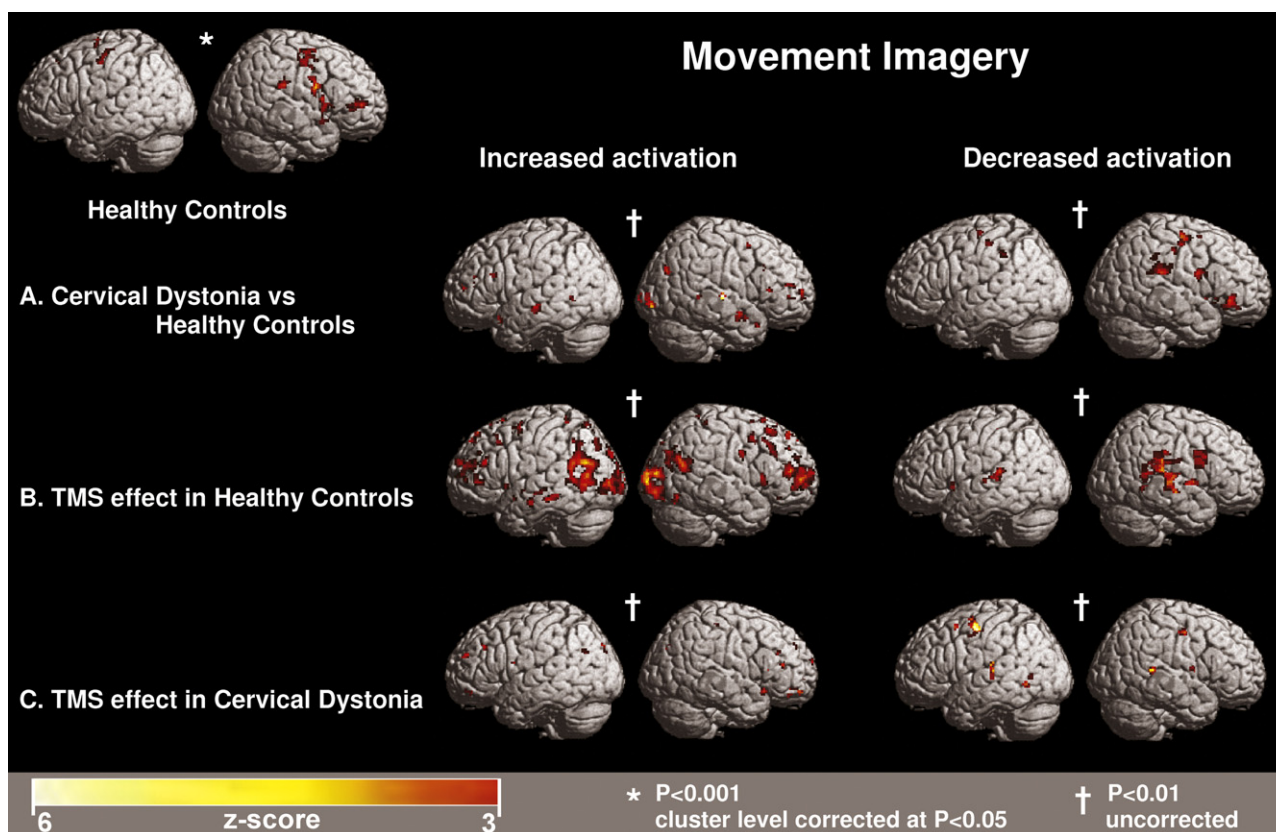
To position and fixate the TMS coil inside the MRI head coil a TMS/MRI holder was designed [29]. This device allowed the operator to manually move the TMS coil in 6 scaled degrees of freedom to a point on the subject's scalp and set its orientation so as to stimulate the selected target in the cortex. The MNI normalization space coordinates for the target [left superior parietal cortex,  $x -24, y -60, z 68$ ] were based on results from a pilot study [1]. Before positioning of the coil, all subjects underwent a T1-weighted anatomical scan (TR=8.04 ms, FOV=25.6 cm  $\times$  25.6 cm  $\times$  16 cm, 160 slices of 1 mm thickness). This scan was loaded into a MRI-guided positioning software package and fitted on a MNI template. The software placed the MNI target coordinates as a virtual marker on the scalp in the anatomical images. The resulting images with the marker were refitted on the subjects anatomical scan followed by the computing of the TMS/fMRI holder settings needed to position the coil over the actual target area for stimulation [29].

### 2.3.2. Data pre-processing

The interleaved TMS/fMRI set-up resulted in two forms of image compromises. The first compromise is due to a short TR during which the effects of the TMS pulse did not have time to dissipate. This is consistent in all subjects since paradigm and synchronization are not changed during the experiment. The second compromise is due to the occasional and somewhat variable leakage of current from the Magstim TMS generator. This leakage caused

**Table 2**  
Task performance ratings.

|                               | Healthy controls  | Cervical dystonia | Between group difference |
|-------------------------------|-------------------|-------------------|--------------------------|
| Questionnaire (scores 48–240) |                   |                   |                          |
| Movement imagery              | 109 $\pm$ 58      | 163 $\pm$ 63      | NS                       |
| Speed of performance (s)      |                   |                   |                          |
| Movement execution            | 23 $\pm$ 13       | 20 $\pm$ 9        | NS                       |
| Movement imagery              | 17 $\pm$ 7        | 34 $\pm$ 21       | 0.013                    |
| Subjective task rating (1–5)  |                   |                   |                          |
| Movement execution            |                   |                   |                          |
| Practice                      | 4.6 $\pm$ 1.0     | 4.2 $\pm$ 1.6     | NS                       |
| During scan                   | 4.2 $\pm$ 1.0 (A) | 4.0 $\pm$ 1.5 (A) | NS                       |
| After scan                    | 4.7 $\pm$ 0.9     | 4.3 $\pm$ 1.6     | NS                       |
| Movement imagery              |                   |                   |                          |
| Practice                      | 3.9 $\pm$ 1.4     | 4.2 $\pm$ 1.2     | NS                       |
| During scan                   | 3.8 $\pm$ 1.4     | 3.8 $\pm$ 1.2     | NS                       |
| After scan                    | 4.3 $\pm$ 1.1     | 4.2 $\pm$ 1.3     | NS                       |



**Fig. 1.** Activation patterns in CD and HC during movement imagery. Two thresholds are used to demonstrate the characteristic (changes in) activation patterns. In the left upper corner is the normal activation pattern depicted during imagery in HC. A: activation changes in CD compared to HC during imagery without TMS vs rest without TMS. B: TMS induced dystonic activation pattern in HC (contrast: imagery with TMS vs imagery without TMS). C: TMS on left superior parietal cortex in CD further intensifies activation changes (contrast: imagery with TMS vs imagery without TMS).

additional scan compromises not related to the firing of the TMS. During the pre-processing of the data, compromised images were identified and replaced. First, all images underwent pre-processing alignment. This resulted in a plot of alignment correction as a function of fMRI image volume. Compromised slices showed large alignment shifts because of their abrupt changes in image intensity. The mask file of each slice that showed large alignment shifts was visually inspected to ensure that slices with movement artifacts were not mistaken for compromised slices by TMS. If a slice was compromised by TMS, a partial blackening of the mask was seen on the left parietal area. The set with identified compromised slices was loaded into a pre-processing batch file created in MATLAB 6.5 (The MathWorks Inc., Natick, MA, USA) and running in SPM2 (Wellcome Dept. Cognitive Neurology, London, UK). It removed the compromised slices and replaced them with an average of the corresponding slices before and after the compromised slice. A visual check of the volume of interest time series was performed afterwards to ascertain that no large negative numbers, related to compromised slices, were still present. This pre-processed data set was then loaded in SPM2 for final processing containing final image alignment, transformation into standard stereotactic space (MNI template), smoothing (6 mm × 6 mm × 6 mm) and statistical analysis.

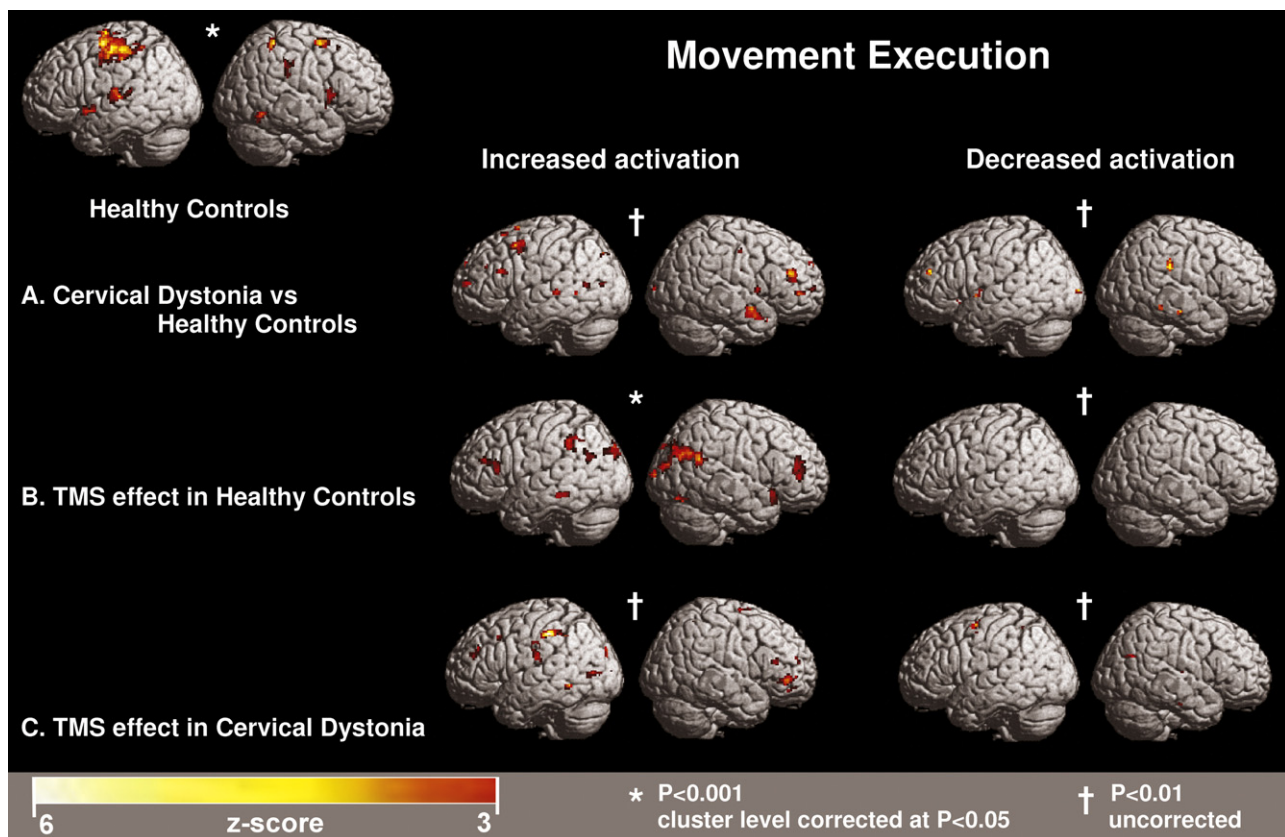
#### 2.4. Statistical analysis

A first-level analysis with one-sample *t*-test was used for initial comparisons. First, basic cerebral activation patterns were determined by comparing each condition (execution, imagery) without preceding TMS with the rest period without preceding TMS (e.g.

execution without TMS vs rest without TMS). Second, assessment of changes in cerebral activity after TMS was done by comparison of each condition after TMS to the same condition without TMS (e.g. execution after TMS vs execution without TMS). Statistical significance was set at  $P < 0.001$  (voxel height response), with cluster size above 8 voxels and cluster-level correction of  $P < 0.05$ . A second-level analysis was performed with a two-sided *t*-test to (i) compare the task without preceding TMS vs rest without preceding TMS in HC and CD (e.g. [execution without TMS vs rest without TMS]<sub>HC</sub> vs [execution without TMS vs rest without TMS]<sub>CD</sub>) and (ii) compare in a similar way the effects of preceding TMS per task in each group vs the TMS effects in the other group (e.g. [execution after TMS vs execution without TMS]<sub>HC</sub> vs [execution after TMS vs execution without TMS]<sub>CD</sub>). For assessment of statistical significance the analysis included a threshold of  $P < 0.001$  (voxel height response), with cluster size above 8 voxels and cluster-level correction of  $P < 0.05$ . Additionally, a relaxed threshold (further called subthreshold) of  $P < 0.01$  voxel height response threshold ( $P < 0.05$  cluster corrected) was applied in order to determine the extension of significant foci as well as to assess expected trends in activation changes. These trends may show more prominently the regional extension of putative compensation mechanisms in both HC and CD after TMS-induced virtual lesioning of the left superior parietal cortex.

### 3. Results

None of the subjects reported side-effects of the experiment apart from slight head discomfort due to pressure of the TMS coil. CD patients did not notice any changes in their dystonic symptoms.



**Fig. 2. Activation patterns in CD and HC during movement execution.** Two thresholds are used to demonstrate the characteristic (changes in) activation patterns. In the left upper corner is the normal activation pattern depicted during execution in HC. A: activation changes in CD compared to HC during execution without TMS vs rest without TMS. B: TMS induced dystonic activation pattern in HC (contrast: execution with TMS vs execution without TMS). C: TMS on left superior parietal cortex in CD further induces activation increases (contrast: execution with TMS vs execution without TMS).

With the help of padding around the head, subjects had no difficulty maintaining a neutral head position.

### 3.1. Task performance without preceding TMS

The results of HC are reported elsewhere [22] and summarized in Figs. 1 and 2 left upper corner.

*Movement imagery* (vs rest without preceding TMS). The distribution of imagery-related activations in CD was dominated by right prefrontal and left cingulate gyrus activation. Right-sided cerebellum and left-sided thalamus activation was also present in CD (Table 3). Formal comparison between the two subject groups did not reveal significant activation differences. Subthreshold decreased activations in CD were distributed over the sensorimotor cortex, extending in the premotor and inferior parietal cortex (Fig. 1A). Subthreshold increases of activation in CD included antero-lateral prefrontal cortices and right posterior parietal cortex ( $P < 0.01$ ) (Fig. 1A).

*Movement execution* (vs rest without preceding TMS). CD presented a pattern of activations that was dominated by bilateral prefrontal activations including cingulate gyrus, pre-supplementary motor area (SMA) and precentral gyrus. Subcortical activation was seen in left thalamus, parahippocampal gyrus and right white matter (bordering right middle frontal gyrus). The group comparisons confirmed this bilateral prefrontal dominance in CD at subthreshold ( $P < 0.01$ , Fig. 2A). Subthreshold decreased activation in CD was seen in the right anterior parietal cortex (Fig. 2A).

### 3.2. Task performance with preceding TMS

*Movement imagery.* In CD, the comparison of imagery after preceding TMS vs imagery without preceding TMS resulted in subthreshold activation increase in the left medial frontal gyrus. Additionally, a subthreshold trend of bilateral prefrontal increases was seen in CD (Fig. 1C). On subthreshold level, TMS-induced decreased activations were seen in dorsal premotor cortex, particularly the left hemisphere (Fig. 1C). A formal comparison of TMS effect on movement imagery did not reveal significant differences in activation between both groups.

*Movement execution.* When compared to execution of movement without preceding TMS, execution after preceding TMS in CD showed significantly enhanced activations in left inferior parietal cortex [ $x -46, y -30, z 46; Z 4.03$ ]. On subthreshold level, activated areas were also found in right prefrontal cortex and precuneus (Fig. 2C). The between-group comparison of execution after preceding TMS vs execution without preceding TMS showed decreased activation in the right angular gyrus in CD [ $x 48, y -72, z 28; Z 5.66$ ]. In other words, the only statistically significant difference between the TMS effects in both groups was reduced right angular gyrus activation in CD during execution.

## 4. Discussion

Aim of this study was to investigate whether abnormal activation patterns seen in CD during clinically normal hand movement are the result of flexible changes in cortical activation based on compensation mechanisms. The abnormal cortical activations in CD comprised subthreshold bilateral prefrontal increases and

**Table 3**

Task performance without preceding TMS compared to rest without preceding TMS.

| Brain region (Brodmann areas)                             |   | Left |     |    |      | Right |     |     |         |
|---|---|------|-----|----|------|-------|-----|-----|---------|
|   |   | x    | y   | z  | Z    | x     | y   | z   | Z score |
| <i>Within-group comparison cervical dystonia</i>          |   |      |     |    |      |       |     |     |         |
| Movement imagery: increased activation                    |   |      |     |    |      |       |     |     |         |
| Frontal lobe  | Middle frontal gyrus (BA46)                 |      |     |    |      | 34    | 34  | 22  | 3.63    |
|   |   |      |     |    |      | 26    | 30  | 18  | 3.55    |
|   | Medial frontal gyrus (BA8,6)                |      |     |    |      | 8     | 26  | 42  | 4.26    |
|   |   |      |     |    |      | 8     | 2   | 60  | 3.96    |
|   | Cingulate gyrus (BA32)                      | –14  | 8   | 42 | 4.04 |       |     |     |         |
| Cerebellum  | Anterior                                    |      |     |    |      | 16    | –50 | –10 | 3.65    |
| Subcortical   | Thalamus                                    | –18  | –12 | 18 | 3.66 |       |     |     |         |
| Movement imagery: decreased activation: not significant   |   |      |     |    |      |       |     |     |         |
| Movement execution: increased activation                  |   |      |     |    |      |       |     |     |         |
| Frontal lobe  | Superior frontal gyrus (BA10)               |      |     |    |      | 28    | 46  | 22  | 4.26    |
|   | Middle frontal gyrus (BA9)                  | –34  | 36  | 28 | 3.72 |       |     |     |         |
|   | Middle frontal gyrus (premotor)             | –36  | –12 | 66 | 5.24 |       |     |     |         |
|   | Medial frontal gyrus (preSMA;BA6)           |      |     |    |      | 0     | 14  | 58  | 4.35    |
|   | Cingulate gyrus (BA32)                      | –4   | –30 | 38 | 4.05 | 0     | 38  | 22  | 4.47    |
|   |   |      |     |    |      | 6     | 14  | 42  | 4.27    |
|   | Precentral gyrus (BA4)                      | –30  | –24 | 54 | 4.14 |       |     |     |         |
| Subcortical   | Inferior frontal gyrus (BA47)               |      |     |    |      | 34    | 20  | –14 | 3.91    |
|   | Thalamus                                    | –14  | –10 | 18 | 3.93 |       |     |     |         |
|   | Parahippocampal gyrus                       | –18  | –52 | –4 | 4.27 |       |     |     |         |
|   | White matter bordering middle frontal gyrus |      |     |    |      | 30    | 12  | 32  | 3.92    |
| Movement execution: decreased activation: not significant |   |      |     |    |      |       |     |     |         |

Activations resulting from within-group comparisons in CD during right hand flexion/extension execution and imagery compared to rest, without preceding left superior parietal TMS. Threshold for response height at voxel-level was  $P < 0.001$  with subsequent cluster-level correction of  $P < 0.05$ .

decreases in bilateral anterior parietal regions and SMA with significant reduction in right angular gyrus. Recently, our group found similar decreases in dystonia associated with complex regional pain syndrome [6]. Moreover, left superior parietal cortex TMS in HC resulted in significant bilateral prefrontal and posterior parietal activation increases, while decreased activation was found in the anterior parietal area during the same tasks [22]. Similarities between the activation changes in CD and HC after TMS may support the idea of compensation. Especially prefrontal and posterior parietal cortices seem to be recurrent elements of this adaptation mechanism. In the present study, we examined to what extent such compensation can be challenged. Virtual lesioning of the parietal cortex with TMS in CD showed a trend partly similar to activation changes in HC. Subthreshold bilateral prefrontal cortex activations were present, but bilateral posterior parietal cortex activations were not apparent. When comparing both groups, the right angular gyrus in the parietal region was significantly decreased in the patient group during execution after TMS. So, TMS in CD may challenge the flexibility of cerebral networks further but the resulting changes in activation were clearly less than in HC.

We hypothesize that task-related activation changes in CD may reflect compensation evoked by impaired function of the anterior parietal cortex. The brain tries to compensate the latter by extra recruitment of other regions to maintain the requested task performance. The recruitment strategy depends on vast connections between these areas and the anterior parietal cortex, along a hierarchical organization within motor control networks [30,31]. Simple movement execution tasks are coordinated in highly specialized movement related areas in and directly bordering primary motor areas. More complex movement tasks require additional input from less specialized secondary areas as ventral premotor and anterior parietal cortices to achieve adequate task accomplishment. If this input is insufficient, robust activation of tertiary areas as prefrontal and posterior parietal regions are recruited [32]. This principle of hierarchical organization has been demonstrated with TMS. Applying a virtual lesion in the primary motor region shows compensation in the dorsal premotor region [19], while a TMS lesion in the dorsal premotor region leads to compensation

in cingulate motor area and SMA [20]. When TMS manipulation is targeted at remote locations from the motor cortex, such as the dorsolateral prefrontal region, the brain can still compensate the lesion with robust activation increases in prefrontal and parietal cortices respectively [21]. To further explore such region-specific involvement in compensatory mechanisms, future studies might employ TMS at various target sites during similar scanning protocols.

Comparison between groups during movement execution after TMS resulted in a significant difference in activation in the right angular gyrus. This is a novel and interesting result. The only other fMRI study in CD, performed by our own group, did not show activation changes in the angular region during movement execution in CD compared to HC [1]. Interestingly, in a writer's cramp study with fMRI during attention for tactile stimuli, increased right intraparietal activation was seen suggesting increased awareness for sensory stimuli in this dystonia group [33]. Thus, it could be hypothesized that the awareness for movement execution was decreased after TMS. The right angular gyrus is associated with movement awareness. For each voluntary movement, the parietal cortex contains an internal representation of the desired movement (efference copy) and uses it to predict the movement to be performed and its sensory consequences (sensory feedforward model) [34,35]. Sensory feedback is necessary to correct this feedforward model, any discrepancies between this internal model and actual consequences of a movement are reflected by angular gyrus activation [36]. Discrepancies can result from lesions in the right angular gyrus, which seems to affect the neural processes to generate an efference copy. Patients with a right angular gyrus lesion can report when they start to move, but not when they first became aware of their intention to move [37]. Discrepancies may also occur by impaired feedback loops from either the moving body part or other cortical areas as the prefrontal cortex [38]. When we extrapolate this to our results, impairments in adaptive activation increases in CD after TMS could result from impaired function of right angular gyrus. As mentioned before, angular gyrus activation was not abnormal during execution and imagery of right hand movement without TMS modulation in CD [1]. It seems more reasonable that impaired feedback networks might alter adaptation processes. In

addition, flawed mental motor representations derived from former improper feedback from a moving body part may not allow for a correct compensation. Nevertheless, since movement imagery seems to reflect movement preparation [24], efference copies are required for movement imagery as well [34]. It is therefore puzzling why the right angular gyrus did not show activation changes during movement imagery after TMS. While CD did show subthreshold decreased activation of the right inferior parietal region during imagery without TMS, this seems to be in contrast to earlier findings of our group [1]. We can only speculate that the group size may not be large enough to point out activation changes during imagery. It could also be that CD found the imagery task more difficult to perform, as is reflected in the extended speed of movement performance compared to HC. The task may not be robust enough to demonstrate any lack of adaptive mechanisms in CD.

We agree that both initial hypothesis and methodological issues may cause debate. The choice for the TMS target region was based on the reduced activation in the left superior parietal cortex in CD compared to HC in our fMRI study [1]. Although not a specific motor region, parietal regions are widely implicated in cerebral motor control. A downside of the paradigm, however, is that TMS on this region did not induce clinical dystonia in the hand neither in HC nor CD. In addition, direct feedback on correct positioning of TMS on the target region was lacking. Targeting a motor region for example shows jerking of the hand or changes in movement performance [18,39]. It can be asserted that the chosen region may not be strongly enough connected to the regions that were assumed to play a role in compensation strategies. However, results of our TMS/fMRI study is consistent with the literature supporting the notion that modulation of a non-motor site is robust enough to induce remote activation changes [21,22]. Second, the patient group may have been too diverse to result in a homogenous enough effect in activation changes. Due to the small group size, large age difference, extent of dystonia, use of medication or duration of dystonia, the CD results may have generated too much noise. Third, although our task concerned performance with a non-dystonic body part, previous EMG study showed subclinical changes in muscle activation [2] and our fMRI study demonstrated significant activation changes during this particular task in CD compared to HC [1]. If modulation of cerebral activation would be imposed during movement of a dystonic body part, this might show stronger activation changes.

## 5. Conclusion

We speculate that the results of this study note that abnormal activation patterns seen in CD may be (partly) explained by adaptive mechanisms of the brain. Impaired anterior parietal function in CD may trigger compensatory activation increases in higher-order motor control regions in prefrontal and posterior parietal cortices in order to still perform the requested movement. Further TMS-induced modulation of the left anterior parietal region in CD might increasingly challenge these adaptive regions.

## Acknowledgments

The authors thank Kevin Johnson, Stew Denslow and Dave Ramsey for their technical support and data storage possibilities and Jennifer Zimmerman for her help in the recruitment of dystonia patients.

## References

- [1] de Vries PM, Johnson KA, de Jong BM, Gieteling EW, Bohning DE, George MS, et al. Changed patterns of cerebral activation related to clinically normal hand movement in cervical dystonia. *Clin Neurol Neurosurg* 2008;110(2):120–8.
- [2] de Vries PM, Leenders KL, van der Hoeven JH, de Jong BM, Kuiper AJ, Maurits NM. Abnormal surface EMG during clinically normal wrist movement in cervical dystonia. *Eur J Neurol* 2007;14(11):1244–50.
- [3] Playford ED, Passingham RE, Marsden CD, Brooks DJ. Increased activation of frontal areas during arm movement in idiopathic torsion dystonia. *Mov Disord* 1998;13(2):309–18.
- [4] Ceballos-Baumann AO, Brooks DJ. Basal ganglia function and dysfunction revealed by PET activation studies. *Adv Neurol* 1997;74:127–39.
- [5] Blood AJ, Flaherty AW, Choi JK, Hochberg FH, Greve DN, Bonmassar G, et al. Basal ganglia activity remains elevated after movement in focal hand dystonia. *Ann Neurol* 2004;55(5):744–8.
- [6] Gieteling EW, van Rijn MA, de Jong BM, Hoogduin JM, Renken R, van Hilten JJ, et al. Cerebral activation during motor imagery in complex regional pain syndrome type 1 with dystonia. *Pain* 2008;134(3):302–9.
- [7] Odergren T, Stone-Elander S, Ingvar M. Cerebral and cerebellar activation in correlation to the action-induced dystonia in writer's cramp. *Mov Disord* 1998;13(3):497–508.
- [8] Pujol J, Roset-Llobet J, Rosines-Cubells D, Deus J, Narberhaus B, Valls-Sole J, et al. Brain cortical activation during guitar-induced hand dystonia studied by functional MRI. *Neuroimage* 2000;12(3):257–67.
- [9] de Jong BM, van der Graaf FH, Paans AM. Brain activation related to the representations of external space and body scheme in visuomotor control. *Neuroimage* 2001;14(5):1128–35.
- [10] Rushworth MFS, Johansen-Berg H, Gobel SM, Devlin JT. The left parietal and premotor cortices: motor attention and selection. *Neuroimage* 2003;20: S89–100.
- [11] Jankovic J. Can peripheral trauma induce dystonia and other movement disorders? Yes! *Mov Disord* 2001;16(1):7–12.
- [12] Schramm A, Reiners K, Naumann M. Complex mechanisms of sensory tricks in cervical dystonia. *Mov Disord* 2004;19(4):452–8.
- [13] Naumann M, Magyar-Lehmann S, Reiners K, Erbguth F, Leenders KL. Sensory tricks in cervical dystonia: perceptual dysbalance of parietal cortex modulates frontal motor programming. *Ann Neurol* 2000;47(3):322–8.
- [14] Zoons E, Booij J, Nederveen AJ, Dijk JM, Tijssen MA. Structural, functional and molecular imaging of the brain in primary focal dystonia – a review. *Neuroimage* 2011;56(3):1011–20.
- [15] Abbruzzese G, Berardelli A. Sensorimotor integration in movement disorders. *Mov Disord* 2003;18(3):231–40.
- [16] Calautti C, Baron JC. Functional neuroimaging studies of motor recovery after stroke in adults: a review. *Stroke* 2003;34(6):1553–66.
- [17] Staffen W, Mair A, Zauner H, Unterrainer J, Niederhofer H, Kutzelnigg A, et al. Cognitive function and fMRI in patients with multiple sclerosis: evidence for compensatory cortical activation during an attention task. *Brain* 2002;125(Pt 6):1275–82.
- [18] Siebner HR, Rothwell J. Transcranial magnetic stimulation: new insights into representational cortical plasticity. *Exp Brain Res* 2003;148(1):1–16.
- [19] Lee L, Siebner HR, Rowe JB, Rizzo V, Rothwell JC, Frackowiak RS, et al. Acute remapping within the motor system induced by low-frequency repetitive transcranial magnetic stimulation. *J Neurosci* 2003;23(12):5308–18.
- [20] O'Shea J, Johansen-Berg H, Trief D, Gobel S, Rushworth MF. Functionally specific reorganization in human premotor cortex. *Neuron* 2007;54(3):479–90.
- [21] Rounis E, Stephan KE, Lee L, Siebner HR, Pesenti A, Friston KJ, et al. Acute changes in frontoparietal activity after repetitive transcranial magnetic stimulation over the dorsolateral prefrontal cortex in a cued reaction time task. *J Neurosci* 2006;26(38):9629–38.
- [22] de Vries PM, de Jong BM, Bohning DE, Walker JA, George MS, Leenders KL. Changes in cerebral activations during movement execution and imagery after parietal cortex TMS interleaved with 3T MRI. *Brain Res* 2009;1285:58–68.
- [23] Hanakawa T, Immisch I, Toma K, Dimyan M, van Gelderen P, Hallett M. Functional properties of brain areas associated with motor execution and imagery. *J Neurophysiol* 2003;89:989–1002.
- [24] Ehrsson HH, Geyer S, Naito E. Imagery of voluntary movement of fingers, toes, and tongue activates corresponding body-part-specific motor representations. *J Neurophysiol* 2003;90(5):3304–16.
- [25] Bohning DE, Shastri A, Nahas Z, Lorberbaum JP, Andersen SW, Dannels WR, et al. Echoplanar BOLD fMRI of brain activation induced by concurrent transcranial magnetic stimulation. *Invest Radiol* 1998;33(6):336–40.
- [26] Annett M. A classification of hand preference by association analysis. *Br J Psychol* 1970;61:303–21.
- [27] Isaac A, Marks DF, Russell DG. An instrument for assessing imagery of movement: the Vividness of Movement Imagery Questionnaire (VMIQ). *J Mental Imagery* 1986;10(3):23–30.
- [28] Jeannerod M, Decety J. Mental motor imagery: a window into the representational stages of action. *Curr Opin Neurobiol* 1995;5(6):727–32.
- [29] Bohning DE, Denslow S, Bohning PA, Walker JA, George MS. A TMS coil positioning/holding system for MR image-guided TMS interleaved with fMRI. *Clin Neurophysiol* 2003;114(11):2210–9.
- [30] Johnson PB, Ferraina S, Bianchi L, Caminiti R. Cortical networks for visual reaching: physiological and anatomical organization of frontal and parietal lobe arm regions. *Cereb Cortex* 1996;6(2):102–19.
- [31] Fang PC, Stepniewska I, Kaas JH. Ipsilateral cortical connections of motor, premotor, frontal eye, and posterior parietal fields in a prosimian primate, *Otolemur garnetti*. *J Comp Neurol* 2005;490(3):305–33.

- [32] Rizzolatti G, Luppino G. The cortical motor system. *Neuron* 2001;31(6):889–901.
- [33] Peller M, Zeuner KE, Munchau A, Quartarone A, Weiss M, Knutzen A, et al. The basal ganglia are hyperactive during the discrimination of tactile stimuli in writer's cramp. *Brain* 2006;129(Pt 10):2697–708.
- [34] Cullen KE. Sensory signals during active versus passive movement. *Curr Opin Neurobiol* 2004;14(6):698–706.
- [35] Blakemore SJ, Goodbody SJ, Wolpert DM. Predicting the consequences of our own actions: the role of sensorimotor context estimation. *J Neurosci* 1998;18(18):7511–8.
- [36] Farrer C, Frey SH, Van Horn JD, Tunik E, Turk D, Inati S, et al. The angular gyrus computes action awareness representations. *Cereb Cortex* 2008;18(2):254–61.
- [37] Sirigu A, Daprati E, Ciancia S, Giraux P, Nighoghossian N, Posada A, et al. Altered awareness of voluntary action after damage to the parietal cortex. *Nat Neurosci* 2004;7(1):80–4.
- [38] Leiguarda RC, Marsden CD. Limb apraxias: higher-order disorders of sensorimotor integration. *Brain* 2000;123(Pt 5):860–79.
- [39] Wassermann EM, Pascual-Leone A, Hallett M. Cortical motor representation of the ipsilateral hand and arm. *Exp Brain Res* 1994;100(1):121–32.