



Cairo University

International Journal of Veterinary Science and Medicine

www.vet.cu.edu.eg  
www.sciencedirect.com



Full Length Article

# Camel milk inhibits murine hepatic carcinogenesis, initiated by diethylnitrosamine and promoted by phenobarbitone



Hala M.F. El Miniawy <sup>a</sup>, Kawkab A. Ahmed <sup>a</sup>, Mohamed A. Tony <sup>b</sup>,  
Sameeh A. Mansour <sup>c</sup>, Marwa M. Salah Khattab <sup>a,\*</sup>

<sup>a</sup> Department of Pathology, Faculty of Veterinary Medicine, Cairo University, El Giza Square, Giza, Egypt

<sup>b</sup> Department of Animal Nutrition and Clinical Nutrition, Faculty of Veterinary Medicine, Cairo University, El Giza Square, Giza, Egypt

<sup>c</sup> Department of Toxicology, National Research Center, El Dokki, Giza, Egypt

Received 2 September 2014; revised 27 October 2014; accepted 28 October 2014

Available online 27 November 2014

## KEYWORDS

Diethylnitrosamine;  
Camel milk;  
Alpha fetoprotein;  
Immunohistochemistry;  
Hepatocellular carcinoma

**Abstract** This study was carried out in order to investigate the possible inhibitory effect of camel milk (CM) on induced hepatocarcinogenesis in rats. Twenty-eight male rats were assigned into 4 groups (7 rats per group). Group I served as control negative. Group II treated with camel milk. Group III was injected I/P with diethylnitrosamine (DENA) (200 mg/kg) as a single dose and after one week received 500 ppm phenobarbitone in drinking water. Group IV injected with DENA as group III and treated with camel milk. Estimation of AST, ALT, albumin, total protein and alpha fetoprotein (AFP) in the serum of euthanized rats was performed. Histopathological examination and immunohistochemical staining of AFP and placental glutathione s transferase of the liver were carried out. Biochemical result at 38th week revealed an increase in serum AFP and a decrease in serum albumin on group III although no significance was detected. Histopathologically, the size of altered hepatic foci was smaller in the milk treated group (group IV). The number of mitotic figures observed in group IV was lower than group III. Hepatocellular carcinoma developed only in group III but not group IV. Immunohistochemical staining of AFP demonstrated an intense positive staining in group III and a weak positive staining in group IV. Similarly, the area percent of pre-neoplastic P-GST positive foci in liver was higher in group III than group IV. In conclusion, camel milk halted the progression of hepatocellular carcinoma.

© 2014 Production and hosting by Elsevier B.V. on behalf of Faculty of Veterinary Medicine, Cairo University. This is an open access article under the CC BY-NC-ND license (<http://creativecommons.org/licenses/by-nc-nd/3.0/>).

\* Corresponding author. Tel.: +20 100 127 64 69.

E-mail addresses: [Marwakhattab@cu.edu.eg](mailto:Marwakhattab@cu.edu.eg), [maimar\\_topaz@yahoo.com](mailto:maimar_topaz@yahoo.com) (M.M. Salah Khattab).

Peer review under responsibility of Faculty of Veterinary Medicine, Cairo University.

<http://dx.doi.org/10.1016/j.ijvsm.2014.10.004>

2314-4599 © 2014 Production and hosting by Elsevier B.V. on behalf of Faculty of Veterinary Medicine, Cairo University. This is an open access article under the CC BY-NC-ND license (<http://creativecommons.org/licenses/by-nc-nd/3.0/>).

## 1. Introduction

Hepatocellular carcinoma (HCC) which is considered as primary cancer of liver remains the fifth common cancer and

the third leading cause of cancer mortality in the world [1]. The occurrence of HCC has been reported in several regions of the world such as Asia, sub-Saharan Africa, as well as parts of Europe and the North American continent [2]. Over the past decade, there was a progressive increase in the incidence of HCC among chronic liver disease patients in Egypt [3]. Many risk factors such as inflammation have been incriminated in the occurrence of HCC [4].

Diethylnitrosamine (DEN) is a potent hepatocarcinogen that, at low doses, acts only as an initiating agent in the rat liver [5] but when its combined with a promoting agent such as phenobarbital, development and progression of experimental liver cancer takes place as reported in the past 2 decades [6]. Many side effects have been associated with chemotherapy for cancer and the therapeutic outcome remains very poor [7].

Currently, camel milk has been used as a traditional medicine in Egypt in order to treat cancer and HCV infected patients. Camel milk contains numerous proteins in which caseins account for 80% (w/w) of the total milk protein content [8] and whey contains numerous proteins such as immunoglobulins,  $\alpha$ -lactalbumin, lactoperoxidase, lysozyme and lactoferrin, among other proteins with biological functions [9]. In addition it contains the whey acidic protein [10] which is not found in ruminant or primate milk [11]. A wide range of biological activities have been exhibited by camel milk including antimicrobial, antioxidative, antithrombotic, antihypertensive, and immuno-modulatory effect [12,13].

Several studies have investigated the effect of camel milk and its constituents on tumor cell lines [14] and provided hopeful results. Therefore it was important to investigate the possible anti tumor potential of camel milk in vivo as well.

## 2. Materials and methods

### 2.1. Animals

Twenty-eight male Wister rats, weighing 100–120 g, were purchased from the animal house of the National Research Center (El Dokki, El Giza, Egypt). This experimental work was approved by Ethics of Animal Use in Research Committee (EAURC), Faculty of Veterinary Medicine, Cairo University, Egypt. The animals were housed in metal wire mesh cages (4–5 rats per cage) and were left for two weeks before beginning the experiment for acclimatization. The housing conditions including temperature  $25 \pm 2^\circ\text{C}$ , relative humidity 50–60%, and 12 h photoperiods were set. The rats were supplied with a pelleted diet and water ad libitum.

### 2.2. Chemicals

Diethyl nitrosamine (DENA) was purchased from Sigma Chemical Co. (St. Louis, MO, USA). Phenobarbitone was kindly supplied by the Egyptian International Pharmaceutical Industry Co. (EIPICO).

### 2.3. Camel milk

Camel milk of *Camelus dromedarius* was purchased from Ibn Sina camel farm (Ras sedr, South of Sinai, Egypt) and was transferred frozen to our laboratory.

### 2.4. Experimental design

28 male rats were divided into four groups (7 rats each).

*Group I:* served as a negative control group.

*Group II:* was treated with camel milk 5 ml by oral intubation after 28 weeks of experimental commence.

*Group III:* was injected intraperitoneally with a single dose (200 mg/kg body weight) of diethylnitrosamine dissolved in saline to initiate hepatocarcinogenesis. After one week, phenobarbitone was added to drinking water at a concentration of 0.05% (500 ppm) for 27 weeks.

*Group IV:* was treated as group III followed by treatment with camel milk after 28 weeks.

Three rats from each group were then euthanized after 34 weeks of DENA injection (6 weeks of camel milk treatment). The rest of the rats were euthanized after 38 weeks (9 weeks of CM treatment).

### 2.5. Biochemical analysis

Serum AST, ALT, albumin and total protein were analyzed spectrophotometrically using commercially available kits (spectrum, Egypt). Estimation of serum AFP was also carried out using rat alpha-fetoprotein ELISA kit (WKEA Med supplies corp., China).

### 2.6. Histopathology

Liver samples were fixed for 48 h in 10% neutral buffered formalin and processed by paraffin embedding technique. Sections of 5–6  $\mu\text{m}$  thick were prepared and stained with H&E stain for microscopic examination [15]. Liver specimens from three different lobes were examined for each rat and lesion score for altered hepatocellular foci was performed. Diagnosis of liver cell foci and neoplasms was performed according to the histological criteria of the Institute of Laboratory Animal Resources [16] on the hematoxylin and eosin-stained sections. The mean area of foci was measured in group III and IV using image analyzer Leica Quin 500 (Pathology department, NRC).

### 2.7. Immunohistochemical detection of Alfa Fetoprotein

Liver paraffin tissue sections were stained by immunoperoxidase technique using anti alpha fetoprotein antibody (Pierce Biotech., USA) and the avidin biotin peroxidase complex method (UltraVision Detection System Anti-Mouse, HRP/DAB, Lab Vision Corp., USA). 3,3-diaminobenzidine (DAB) was used for color development. All staining procedure was carried out according to manufacturer protocol. The optical density of immunohistochemically stained AFP was measured using image analyzer Leica Quin 500, Pathology department, NRC.

### 2.8. Immunohistochemical staining of placental glutathione s transferase

Paraffin embedded liver tissue sections were immunohistochemically stained by using Anti-GST-P polyclonal antibody prepared in rabbit (MBL Co., LTD, USA) and the avidin biotin peroxidase complex method according to kit manufacturer protocol (Dako, LSAB + system-HRP, North America, Inc.).

The area percent and count/area of P GST positive foci were measured using image analyzer Leica Quin 500, Pathology department, NRC.

### 2.9. Statistical analysis

Statistical analysis was carried out using statistical package SPSS, version 8.0 (SPSS Inc., Chicago, IL, USA). Statistical analysis of data was carried out using one-way analysis of variance (ANOVA) followed by LSD and Duncan test. Results were expressed as mean  $\pm$  standard error (mean  $\pm$  SE). *P* values less than 0.05 were considered significant.

## 3. Results

### 3.1. Biochemical analysis

At the 34th week, there was no significant difference in total protein, albumin, ALT, AST and AFP between groups

(Table 1). However, there was a significant increase in ALT in group IV at 38th week compared to other groups. The serum albumin was low and AFP was high in group III at 38th week although no significant difference has been detected.

### 3.2. Histopathology

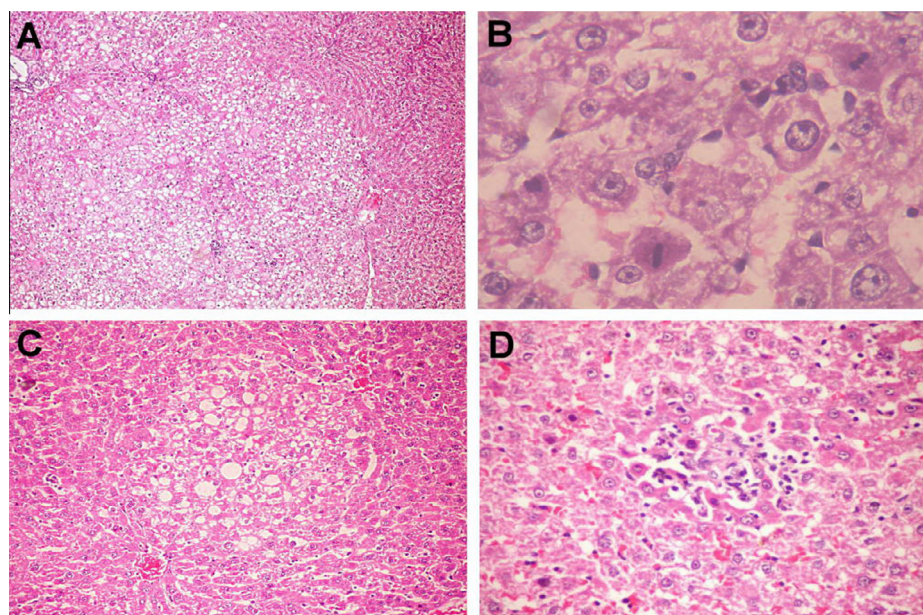
The liver of rats treated with DENA exhibited different degenerative changes taking the form of cytoplasmic vacuolation progressing into single cell necrosis and foci of necrosis with few inflammatory cells infiltration. The cellular necrosis led to hepatic dissociation and sinusoidal dilatation. Portal area showed biliary hyperplasia and collagen deposition. In addition, to the previous histological picture, altered hepatocellular foci including clear cell, eosinophilic and basophilic foci were observed. At the 34th week, large clear hepatocellular adenoma with multiple mitotic divisions at the periphery was evident. It was well demarcated by compression of the adjacent tissue and altered staining properties (Fig. 1A). At 38th week, the number and size of altered hepatocellular foci and the

**Table 1** Levels of serum variables after 34 and 38 weeks of DENA injection.

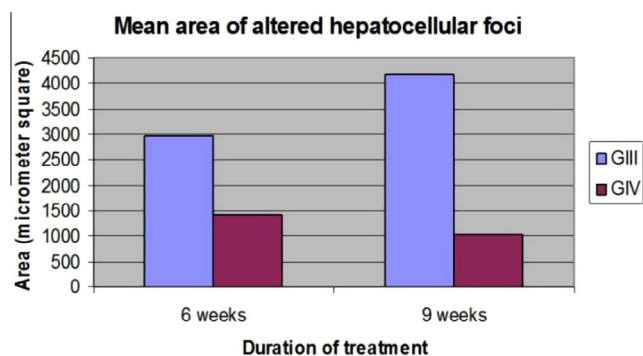
Group		Total protein (g/dl)	Albumin (g/dl)	ALT (U/L)	AST (U/L)	AFP ( $\mu$ g/l)
I	34 W	11.49 $\pm$ 1.12	4.33 $\pm$ 0.24	23.6 $\pm$ 1.3	23.3 $\pm$ 4.3	2.17 $\pm$ 0.008
	38 W	10.26 $\pm$ 1.0	3.1 $\pm$ 0.24	14.5 $\pm$ 2.8	39 $\pm$ 7.9	0.58 $\pm$ 0.23
II	34 W	11.5 $\pm$ 1.9	4.39 $\pm$ 0.1	23.6 $\pm$ 1.3	37.6 $\pm$ 2.8	1.42 $\pm$ 0.23
	38 W	10.07 $\pm$ 0.6	3.4 $\pm$ 0.25	26.25 $\pm$ 5.2	19.5 $\pm$ 5.8	1.2 $\pm$ 0.005
III	34 W	10.5 $\pm$ 1.5	4.33 $\pm$ 0.05	22.3 $\pm$ 1.3	30.3 $\pm$ 11	2.16 $\pm$ 0.61
	38 W	14.64 $\pm$ 0.008	2.5 $\pm$ 0.005	21 $\pm$ 2.3	24 $\pm$ 6.65	1.45 $\pm$ 0.34
IV	34 W	7.78 $\pm$ 0.4	4.36 $\pm$ 0.16	21 $\pm$ 0.0	38.5 $\pm$ 16.6	0.54 $\pm$ 0.34
	38 W	10.47 $\pm$ 1.79	3.2 $\pm$ 0.33	32.7 $\pm$ 1.25*	34.5 $\pm$ 8.83	1.01 $\pm$ 0.24

Values were represented as mean  $\pm$  SE (n = 3–4).

\* Indicate significant difference at *P* < 0.05.



**Figure 1** Photomicrograph of liver showing (A) clear cell hepatocellular adenoma at 34th week (X 100) and (B) hepatocellular carcinoma with multiple mitotic figures (arrows) at 38th week in group III (B X 1000), (C) focus of hepatocellular alteration (X 100) and (D) focal area of necrosis with inflammatory cell infiltration (X 200) in group IV. (H and E stain.)



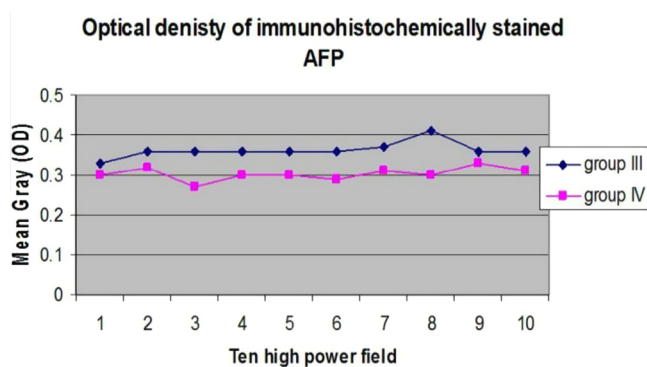
**Figure 2** Chart showing the mean area of hepatocellular altered foci in group III and group IV.

number of mitotic figures in these altered foci (Fig. 2) were obviously increased compared to those observed at 34th week. Moreover, hepatocellular adenoma and hepatocellular carcinoma were demonstrated (Fig. 1B).

On the other hand, liver of rats in group IV at 34th week showed focal areas of microvesicular steatosis but in overall there was less cytoplasmic vacuolation compared to group III. Minute foci of necrosis associated with mononuclear inflammatory cell infiltration and foci of hepatocellular alterations were evident (Fig. 1C and D). At 38th week, few sporadic cell necrosis and apoptotic bodies were observed. Based on the lesion score performed, the number and size of hepatocellular altered foci was lesser than those detected in group III and there was only one small eosinophilic hepatocellular adenoma (Fig. 2).

### 3.3. Immunohistochemical detection of AFP

Alfa Fetoprotein stained positive in group III and group IV as seen in Fig. 3. Brown granules of alpha fetoprotein were

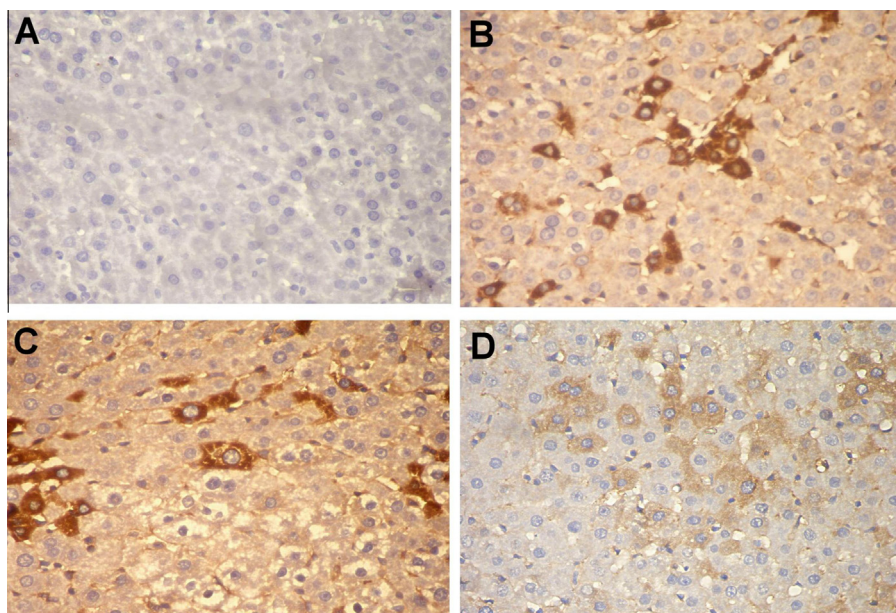


**Figure 4** Chart showing the optical density of immunohistochemically stained AFP in ten high power microscopic fields.

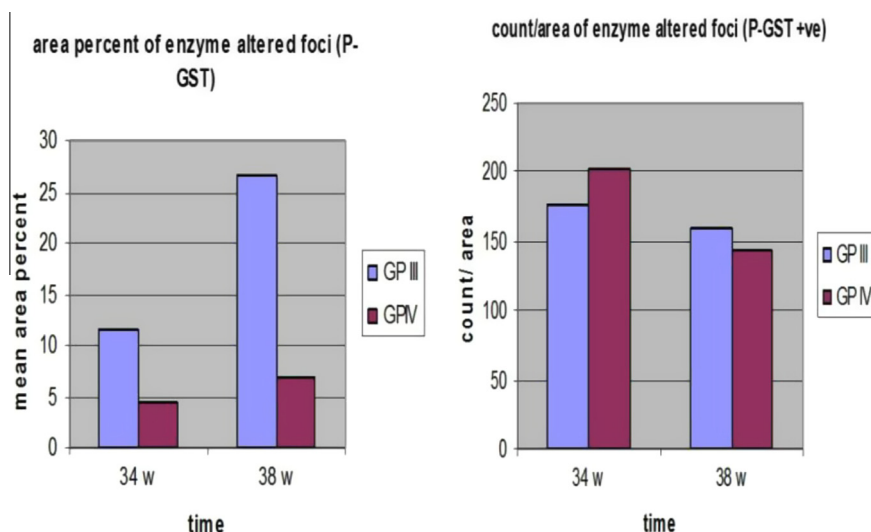
evident in the cytoplasm of hepatocytes. Never the less, the optical density of staining intensity measured by image analyzer increased in group III than group IV (Fig. 4).

### 3.4. Immunohistochemical staining of P-GST

Multiple foci of brown positive reaction in hepatic tissue representing enzyme altered foci have been demonstrated in group III and group IV at 34th week and 38th week post injection whereas group I and group II showed negative staining for P-GST. Remarkably, there was a variation in size and number of these enzyme altered foci. Large strongly positive enzyme altered foci were detected in group III. On the other hand, group IV showed small and moderate sized foci of positively stained enzyme altered foci. This variation was clearer at 38th week post injection than at 34th week. The mean area percent of enzyme altered foci in different groups at 34th and 38th week which was measured by image analysis is demonstrated in (Fig. 5).



**Figure 3** Photomicrograph of rat liver showing immunostaining of AFP (A) negative staining in group I, (B and C) strong positive cells (arrow) in group III and (D) weak positive cells (arrow) in group IV (IP X 400).



**Figure 5** Chart showing the mean area percent and count/area of enzyme altered foci (P-GST positive).

#### 4. Discussion

DENA acting through a variety of mechanisms such as DNA alkylation [17] and free radical generation [18] induces hepatocarcinogenesis. Number of investigations is being carried out to discover natural products that can interrupt the carcinogenesis process [19,20]. DENA was found to elevate the activities of liver specific enzymes AST and ALT and also total bilirubin [21] which however disagreed with the current study in which there was no elevation detected at 34th week. The time elapse between the DENA injection and the serum analysis might be the factor for such insignificance.

Although, serum level of alpha fetoprotein (AFP) showed insignificant difference between groups at 34th and 38th week, group III showed a relative elevation and a strong positive immunohistochemical staining for AFP. Alpha fetoprotein was found to contribute somehow in hepatocellular proliferation and for that reason it was considered as a liver tumor marker [22,23].

Increased collagen deposition in the portal area was evident in group III which agrees with previous research work [24–25]. Liver injury induced by chemicals such as nitrosamines can proceed to hepatic vacuolization, necrosis, fibrosis, bile duct or hepatocyte hyperplasia and neoplasia [26]. In this respect, the present study, recorded decrease in mononuclear inflammatory cell infiltration, hyperplasia of bile duct epithelium and fibrosis in group IV which is in accordance with Darwish et al. [27], who pointed out that decreased degeneration of some hepatocytes as well as reduced collagen accumulation following the CM feeding to rats with ethanol induced liver injury were evident.

Several studies have been conducted on the relation between the expression of placental glutathione transferases and hepatocarcinogenesis [28–29]. The initiation potential of several carcinogens has been demonstrated by the induction of preneoplastic glutathione-s-transferase P-form positive liver cell foci [30].

Hepatoprotection due to feeding on camel milk has been previously documented by Shamanov et al., [31] who indicated that patients with chronic active hepatitis showed positive shifts in the clinical and laboratory findings after being

supplemented with whole camel milk. The anti tumor effect of camel milk presented in this study can be attributed to its antioxidant properties and scavenging effects on free radicals. CM was found to contain high concentrations of vitamins A, B2, C and E [32]. These vitamins act as antioxidants and have been effective in preventing toxicant-induced tissue injury [33].

A recent work have shown the ability of camel milk to significantly inhibit the induction of the cytochrome P4501A1 (*Cyp1a1*), a cancer-activating gene, and to induce the NAD(P)H: quinone oxidoreductase 1 (*NQO1*), cancer chemopreventive gene in murine hepatoma Hepa 1c1c7 cells at the transcriptional and posttranscriptional levels [34]. Camel milk was found to cease tumor cell lines (HepG2 and MCF7 cells) survival and proliferation through the activation of both the extrinsic and intrinsic apoptotic pathways [35]. Several milk proteins were incriminated in the apoptotic potential of camel milk including camel casein and lactoferrin. Camel casein was reported to induce apoptosis and in turn reduce the viability of tumor cell lines [14]. Lactoferrin as well which is found in high concentration in camel milk [36], was thought to cause apoptosis of tumor cells by the activation of the Fas signaling pathway. However the exact mechanism has not yet been discovered [37].

#### 5. Conclusion

Camel milk protected the liver against toxicity induced by DENA, prevented the development of hepatocellular carcinoma and halted the growth of hepatocellular altered foci.

#### References

- [1] Thun MJ, DeLancey JO, Center MM, Jemal A, Ward EM. The global burden of cancer: priorities for prevention. *Carcinogenesis* 2010;31:100–10.
- [2] Jemal A, Bray F, Center MM, Ferlay J, Ward E, Forman D. Global cancer statistics. *CA Cancer J Clin* 2011;61:69–90.
- [3] El-Zayadi AR, Badran HM, Barakat EM, Attia MD, Shawky S, Mohamed MK, Selim O, Saeid A. Hepatocellular carcinoma in Egypt: a single center study over a decade. *World J Gastroenterol* 2005;11:5193–8.

- [4] Pan MH, Lai CS, Ho CT. Anti-inflammatory activity of natural dietary flavonoids. *Food Funct* 2010. <http://dx.doi.org/10.1039/c0fo00103a>.
- [5] Goldsworthy TL, Pitot HC. The quantitative analysis and stability of histochemical markers of altered hepatic foci in rat liver following initiation by diethylnitrosamine administration and promotion with phenobarbital. *Carcinogenesis* 1985;6(9):1261–9.
- [6] Bishayee A, Dhir N. Resveratrol-mediated chemoprevention of diethylnitrosoamine-initiated hepatocarcinogenesis: inhibition of cell proliferation and induction of apoptosis. *Chem Biol Interact* 2009;179:131–44.
- [7] Ahles TA, Saykin AJ, Furstenberg CT, Cole B, Mott LA, Skalla K, et al. Neuropsychologic impact of standard-dose systemic chemotherapy in long-term survivors of breast cancer and lymphoma. *J Clin Oncol* 2002;20:485–93.
- [8] Shah NP. Effects of milk-derived bioactives: an overview. *Br J Nutr* 2000;84:3–10.
- [9] El-Agamy EI. Effect of heat treatment on camel milk proteins with respect to antimicrobial factors: a comparison with cow's and buffalo milk. *Food Chem* 2000;68:227–32.
- [10] Beg OU, Bahr-Lindstrom HV, Zaidi ZH, Jornvall H. A small camel-milk protein rich in cysteine/half-cysteine. *Biosci Rep* 1984;4:1065–70.
- [11] Nukumi N, Seki M, Iwamori T, Yada T, Naito K, Tojo H. Analysis of the promoter of mutated human whey acidic protein (WAP) gene. *J Reprod Dev* 2006;52:315–20.
- [12] FitzGerald RJ, Meisel H. Milk protein-derived peptide inhibitors of angiotensin-I-converting enzyme. *Br J Nutr* 2000;84:33–7. <http://dx.doi.org/10.1017/S0007114500002221>.
- [13] Kohonen H, Pihlanto A. Milk protein-derived bioactive peptides-novel opportunities for health promotion. *IDF Bull* 2003;363:17–26.
- [14] Almahdy O, EL-Fakharany EM, EL-Dabaa E, Ng TB, Redwan EM, Redwan EM. Examination of the activity of camel milk casein against hepatitis C virus (genotype-4a) and its apoptotic potential in hepatoma and Hela cell lines. *Hepat Mon* 2011;11:724–30.
- [15] Bancroft JD, Suvarna K, Layton C. Bancroft's theory and practice of histological techniques. 7th ed. E book; 2012, ISBN: 978-0-7020-5032-9.
- [16] Stewart HL, Williams G, Keysser CH, Lombard LS, Montali RJ. Histologic typing of liver tumors of the rat. *J Natl Cancer Inst* 1980;64:177–207.
- [17] Scherer E, Van DenBerg T, Vermeulen E, Winterwerp HH, Den Engelse L. Immunocytochemical analysis of O6-alkylguanine shows tissue specific formation in and removal from esophageal and liver DNA in rats treated with methylbenzyl nitrosamine, dimethylnitrosamine, diethylnitrosamine, and ethylnitrosourea. *Cancer Lett* 1989;46:21–9.
- [18] Yamada K, Yamamiya I, Utsumi H. In vivo detection of free radicals induced by diethylnitrosamine in rat liver tissue. *Free R Biol Med* 2006;40:2040–6.
- [19] Aggarwal BB, Kumar A, Bharti AC. Anticancer potential of curcumin: preclinical and clinical studies. *Anticancer Res* 2003;23:363–98.
- [20] Cheng YL, Chang WL, Lee SC, Liu YG, Chen CJ, Lin SZ, et al. Acetone extract of *Angelica sinensis* inhibits proliferation of human cancer cells via inducing cell cycle arrest and apoptosis. *Life Sci* 2004;75:1579–94.
- [21] Rezaie A, Haghi Karamolah M, Shahriari A, Najaf Zadeh H, Pashmforosh M. Effects of *Echinacea purpurea* on hepatic and renal toxicity induced by diethylnitrosamine in rats. *Jundishapur J Nat Pharm Prod* 2013;8(2):60–4. <http://dx.doi.org/10.5812/jnpp.9686>.
- [22] Song Y, Jin S, Cui L, Ji X, Yang F. Immunomodulatory effect of *Stichopus japonicus* acid mucopolysaccharide on experimental hepatocellular carcinoma in rats. *Molecules* 2013;18:7179–93.
- [23] Sell S, Nichols M, Becker FF, Leffert H. Hepatocyte proliferation and  $\alpha$ -fetoprotein in pregnant, neonatal, and partially hepatectomized rats. *Cancer Res* 1974;34:865–71.
- [24] El-Shahat M, El-Abd S, Alkafafy M, El-Khatib G. Potential chemoprevention of diethylnitrosamine-induced hepatocarcinogenesis in rats: myrrh (*Commiphora molmol*) vs. turmeric (*Curcuma longa*). *Acta Histochem* 2012;114(5):421–8.
- [25] Sun H, Yu L, Wei H, Liu G. A novel antihepatitis drug, bicyclol, prevents liver carcinogenesis in diethylnitrosamine-initiated and phenobarbital-promoted mice tumor model. *J Biomed Biotechnol* 2012;9. <http://dx.doi.org/10.1155/2012/584728>. Article ID 584728.
- [26] Boorman GA, Eustis SL, Elwell MR, Montgomery CA, Mackenzie WF. Pathology of the Fisher rat. United Kingdom: Academic press; 1990.
- [27] Darwish HA, Abd Raboh NR, Mahdy A. Camel's milk alleviates alcohol-induced liver injury in rats. *Food Chem Toxicol* 2012;50:1377–83.
- [28] Sato K. Glutathione transferases as markers of preneoplasia and neoplasia. *Adv Cancer Res* 1989;52:205–55.
- [29] Tsuchida S, Sato K. Glutathione transferases and cancer. *Crit Rev Biochem Mol Biol* 1992;27:337–84.
- [30] Tsuda H, Matsumoto K, Ogino H, Ito M, Hirono I, Nagao M, et al. Demonstration of initiation potential of carcinogens by induction of preneoplastic glutathione S-transferase P-form-positive liver cell foci: possible *in vivo* Assay system for environmental carcinogens. *Jpn J Cancer Res* 1993;84:230–6.
- [31] Sharmanov TS, Zhangabylov AK, Zhaksylykova RD. Mechanism of the therapeutic action of whole mare's and camel's milk in chronic hepatitis. *Vopr Pitan* 1982;1:17–23.
- [32] Zhang H, Yao J, Zhao D, Liu H, Li J, Guo M. Changes in chemical composition of Alxa bactrian camel milk during lactation. *J Dairy Sci* 2005;88(10):3402–10.
- [33] Yousef MI. Aluminum-induced changes in hematobiochemical parameters, lipid peroxidation and enzyme activities of male rabbits: protective role of ascorbic acid. *Toxicology* 2004;199:47–57.
- [34] Korashy HM, El Gendy MA, Alhaider AA, El-Kadi AO. Camel milk modulates the expression of aryl hydrocarbon receptor-regulated genes, Cyp1a1, Nqo1, and Gst1a2, in murine hepatoma hepa 1c1c7 cells. *J Biomed Biotech* 2012;10. <http://dx.doi.org/10.1155/2012/782642>. Article ID 782642.
- [35] Korashy HM, Maayah ZH, Abd-Allah AR, El-Kadi AOS, Alhaider AA. Camel Milk Triggers Apoptotic Signaling Pathways in Human Hepatoma HepG2 and Breast Cancer MCF7 Cell Lines through Transcriptional Mechanism. *J Biomed Biotech* 2012;9. <http://dx.doi.org/10.1155/2012/593195>. Article ID 593195.
- [36] Konuspayeva G, Serikbayeva A, Loiseau G, Narmuratova M, Faye B. Desertification combat and food safety: the added value of camel producers. In: Bernard Faye, Palmated Esenov, editors. Amsterdam, Ashgabat, Turkmenistan: IOS Press; 2004. p. 158–67.
- [37] Fujita K, Matsuda E, Sekine K, Iigo M, Tsuda H. Lactoferrin enhances Fas expression and apoptosis in the colon mucosa of azoxymethane-treated rats. *Carcinogenesis* 2004;25:1961–6.