



ELSEVIER

Contents lists available at ScienceDirect

International Journal for Parasitology: Parasites and Wildlife

journal homepage: www.elsevier.com/locate/ijppaw

Brief Report

Fatal systemic toxoplasmosis in Valley quail (*Callipepla californica*)

Renata A. Casagrande ^a, Hilda F.J. Pena ^b, Aline D. Cabral ^b, Veronica M. Rolim ^a,
Luiz G.S. de Oliveira ^a, Fabiana M. Boabaid ^a, Angelica T.B. Wouters ^a, Flademir Wouters ^a,
Cláudio E.F. Cruz ^a, David Driemeier ^{a,*}



^a Departamento de Patologia Clínica, Faculdade de Veterinária, Universidade Federal do Rio Grande do Sul (FaVet/UFRGS), Avenida Bento Gonçalves 9090, Agronomia, Porto Alegre-RS, 91540-000, Brazil

^b Departamento de Medicina Veterinária Preventiva e Saúde Animal, Faculdade de Medicina Veterinária e Zootecnia, Universidade de São Paulo (FMVZ/USP), Avenida Orlando Marques de Paiva, 87, Cidade Universitária, São Paulo-SP, 05508-900, Brazil

ARTICLE INFO

Article history:

Received 27 October 2014

Revised 25 February 2015

Accepted 14 April 2015

Keywords:

Toxoplasma gondii

Captive bird

Pathology

Immunohistochemistry

Genotyping

ABSTRACT

An adult, captive raised male Valley quail (*Callipepla californica*) acquired by a southern Brazilian aviary suddenly showed severe apathy, dyspnea and diarrhea, and died 18 hours after the onset of illness. At necropsy, pale muscles and whitish areas in the heart, splenomegaly, hepatomegaly, and consolidated red lungs were observed. Histological findings were mainly mononuclear inflammation with necrosis of liver, heart, spleen, bone marrow and lung. There were large numbers of *Toxoplasma gondii* tachyzoite organisms in the liver, heart, spleen, bone marrow, lungs, trachea, kidneys, adrenal glands, testes, intestines, and pancreas. These organisms were seen free in the organs' stroma or within macrophages and stained positively with polyclonal antiserum to *T. gondii*. Genomic DNA was extracted from the tissues and PCR was used to target the B1 gene of *T. gondii*. The genotypic characterization by PCR-RFLP with 11 markers (SAG1, SAG2 and alt. SAG2, SAG3, BTUB, GRA6, c22-8, c29-2, L358, PK1, Apico and CS3) revealed the ToxoDB-PCR-RFLP #87 genotype, the same as previously identified in a backyard chicken (TgCkBr156) in Rio Grande do Sul, Brazil.

© 2015 The Authors. Published by Elsevier Ltd on behalf of Australian Society for Parasitology. This is an open access article under the CC BY-NC-ND license (<http://creativecommons.org/licenses/by-nc-nd/4.0/>).

1. Introduction

Toxoplasmosis is a cosmopolitan infectious disease caused by the intracellular parasite *Toxoplasma gondii* and affects a large range of mammals and birds (Dubey et al., 1998; Dubey, 2002). Domestic cats and wild felids are definitive hosts that excrete the oocysts in their feces. In intermediate hosts, including birds, asexual parasite reproduction takes place, sometimes in association with the development of the clinical disease, which can be acute, chronic, or subclinical (Dubey et al., 1998). In birds, the disease is usually subclinical, with formation of tissue cysts (bradyzoites) that may persist throughout life (Dubey, 2002). Subclinical disease is most commonly described in Galliformes (Dubey et al., 1993a, 2006, 2007; Dubey, 2002); however, fatal cases have also been occasionally reported in these birds (Howerth and Rodenroth, 1985; Quist et al., 1995; Jones et al., 2012). While spontaneous toxoplasmosis has not been reported in quail and partridges, Japanese quail (*Coturnix coturnix japonica*) and Bob White quail (*Colinus virginianus*) were

highly susceptible to experimental infection with a pathogenic *T. gondii* isolate (Dubey et al., 1993b, 1994).

The Valley quail (*Callipepla californica*) belongs to the order Galliformes, family Odontophoridae. These small ground birds were originally found in western North America, where they inhabit the shrubby areas and open woodlands. They have been subsequently introduced in several other countries where they are maintained in captivity as an ornamental bird or commercially bred as a game bird (Calkins et al., 1999). This communication describes the anatomopathological findings and the immunohistochemical and molecular characterization in a systemic and fatal case of toxoplasmosis that affected a Valley quail. As far as we are aware, this is the first description of fatal toxoplasmosis in the species.

2. Materials and methods

A small exotic bird conservation center located in Porto Alegre municipality, Rio Grande do Sul State (RS), southern Brazil (Lat: -30° 7' 30,2" and Long: -51° 14' 2,8") had recently acquired two pairs of captive raised Valley quail (*Callipepla californica*). After 35 days in the quarantine cage (1.5 × 0.60 × 0.45 m), birds were released in an outside 63 m³ aviary. The bird's diet included seed mixture, commercial ration, green vegetables and insects (*Tenebrio molitor* and

* Corresponding author. Avenida Bento Gonçalves 9090, Agronomia 91540-000, Porto Alegre-RS, Brazil. Tel.: +55 (51) 330861107; fax: +55 (51) 330861116.

E-mail address: davetpat@ufrgs.br (D. Driemeier).

Acheta domesticus). All the birds were treated with anthelmintics and coccidiostats drugs during the quarantine period.

On the 10th day after quarantine period, an adult male became severely ill with sudden and severe apathy, dyspnea and diarrhea. The bird was treated with an oral antibiotic formulation (tetracycline, chloramphenicol, and furazolidone) and placed in a heated (28 °C) hospital cage. However, the bird died 18 h after the onset of the clinical signs. The bird was sent for necropsy in the Veterinary Pathology Department, School of Veterinary Medicine, Federal University of Rio Grande do Sul. Portions of organs were collected, fixed in 10% buffered formalin, processed for routine histopathological analysis and stained by hematoxylin–eosin (H&E). Additional samples of the tissues were frozen at –20 °C for molecular studies.

Immunohistochemical (IHC) studies were performed on paraffin-embedded sections of all tissues to detect *T. gondii* using the polyclonal antibody (VRMD, Pullman, WA, USA) (dilution 1:1000) with 0.1% trypsin for 10 min for antigen retrieval, as well as a modified avidinbiotin peroxidase complex method (LSAB Universal kit, Dako Cytomation, Glostrup, Denmark) using diaminobenzidine (DAB, Dako Cytomation, Glostrup, Denmark) or 3-amino-9-ethylcarbazol (AEC, K3469, Dako Cytomation, Glostrup, Denmark) as chromogen.

Frozen tissue samples of the liver, spleen, lungs and kidneys of the quail were sent to the Department of Preventive Veterinary Medicine and Animal Health of the School of Veterinary Medicine and Animal Science of the University of São Paulo, São Paulo, Brazil, for molecular detection and genotyping of *T. gondii* by PCR-RFLP. The quail tissue samples were homogenized separately using a pestle and mortar, and 0.85% saline (v/v) was added to the homogenates, which were distributed into 2.0-mL microtubes and kept at –70 °C until processing. After defrosting, 300 µL of each tissue homogenate was washed two or three times in tris-EDTA buffer (q.s.p. 1.500 µL), pH 8.0 (Tris-HCl 10 mM, EDTA 1 mM), by centrifuging at 12,000 g for 5 min. DNA was extracted using a commercial kit (Wizard Genomic DNA Purification Kit/cat. A1125, Promega, Madison, WI, USA), according to the manufacturer's instructions, via columns under vacuum and stored at –20 °C until use. A negative control for DNA extraction was included. Molecular detection of *T. gondii* was performed using nested PCR, targeting the amplification of a 155-bp fragment from the B1 gene as previously described by Yai et al. (2003).

Strain typing by PCR-RFLP was performed using DNA extracted from liver, spleen, lung and kidney fragments. *T. gondii* reference clonal strains RH (Type I), PTG (Type II) and CTG (Type III) and *T. gondii* atypical strains (TgCgCa1, MAS and TgCatBr5) were included as positive controls in all reactions. The following markers and protocols were as previously described: SAG1, 5'3'SAG2 and alt. SAG2, SAG3, BTUB, GRA6, c22-8, c29-2, PK1, L358, Apico (Su et al., 2006; Dubey et al., 2007) and CS3 (Pena et al., 2008). Ultrapure water and HFF (human foreskin fibroblast cells) were included as negative controls.

3. Results and discussion

The necropsy of the Valley quail revealed good body condition, markedly pale skeletal muscles, heart with focal pale areas (Fig. 1A), lungs diffusely red and consolidated, marked splenomegaly and diffuse hepatomegaly (Fig. 1B). On histopathological examination, liver (Fig. 1C), heart (Fig. 1D), spleen, lungs and bone marrow showed multifocal to coalescent severe necrosis associated with inflammatory infiltrate of macrophages, lymphocytes and plasma cells. Focal moderate necrotic tracheitis, multifocal discrete interstitial nephritis, esophagitis and proventriculitis, and multifocal discrete gliosis in the brain associated with inflammatory infiltrate of macrophage, lymphocyte and plasma cells were also detected. Among lesions observed in heart, liver, bone marrow, lungs, trachea and kidneys, large numbers of tachyzoites of *T. gondii* were observed free in the organs' stroma or within macrophages. Anti-*T. gondii* IHC

showed intense immunoreactivity of protozoal clusters of tachyzoites associated with inflammatory foci in liver (Fig. 1E), heart, spleen, lungs, bone marrow (Fig. 1F), kidneys, esophagus, trachea and lamina propria of intestines. *T. gondii*-specific immunoreactivity was also observed within monocytes in the blood vessel lumina of the liver, lung, heart, bone marrow, kidneys, adrenal glands, testis and pancreas. Small numbers of free tachyzoites were occasionally visible within these tissues. The brain, spinal medulla, crop, skeletal muscle and skin showed no *T. gondii*-specific immunoreactivity.

Many studies have demonstrated infection by *T. gondii* in several bird species using serological and molecular techniques. Yet in most bird species, this infection is subclinical (Dubey, 2002; Dubey et al., 2006, 2007). Fatal clinical toxoplasmosis is an important disease for Columbiformes and Passeriformes (Work et al., 2000; Williams et al., 2001; Dubey, 2002). The systemic and fatal manifestation of the disease has also been described in Psittaciformes (Howerth et al., 1991; Hartley et al., 2008; Ferreira et al., 2012), Anseriformes (Dubey et al., 2001), Falconiformes (Szabo et al., 2004), Strigiformes (Mikaelian et al., 1997), Sphenisciformes (Mason et al., 1991; Ploeg et al., 2011), Piciformes (Gerhold and Yabsley, 2007; Jokelainen and Vikoren, 2014) and Suliformes (Work et al., 2002).

Mortality may be high in toxoplasmosis outbreaks in birds (Work et al., 2000, 2002; Williams et al., 2001; Hartley et al., 2008; Ploeg et al., 2011; Jones et al., 2012). However, in the present case, only one of the four quails died. Birds affected by the disease normally die without showing any clinical signs (Howerth and Rodenroth, 1985; Dubey et al., 2001; Jokelainen and Vikoren, 2014) or, when these are detected, they are nonspecific, such as prostration (Mikaelian et al., 1997; Ferreira et al., 2012). Some affected birds may exhibit respiratory difficulties (Howerth et al., 1991; Szabo et al., 2004), as observed in the present case, and neurological signs (Gerhold and Yabsley, 2007; Ploeg et al., 2011). In most reports, death occurred within one day after clinical signs appear (Hartley et al., 2008; Ploeg et al., 2011; Ferreira et al., 2012).

Infection with *T. gondii* can cause a generalized disease, with necrotic lesions in several organs, like lungs, heart, liver, spleen, kidneys, air sacs, encephalon, adrenal glands, bursa of Fabricius, pancreas, intestines and eye globe (Howerth et al., 1991; Mason et al., 1991; Quist et al., 1995; Mikaelian et al., 1997; Work et al., 2000, 2002; Dubey et al., 2001; Williams et al., 2001; Szabo et al., 2004; Hartley et al., 2008; Ploeg et al., 2011; Ferreira et al., 2012; Jones et al., 2012; Jokelainen and Vikoren, 2014). In the quail analyzed, histological lesions were disseminated, and the presence of the parasite was detected by anti-*T. gondii* IHC in several organs and in the lumen of blood vessels. The presence of pulmonary consolidation, splenomegaly and hepatomegaly observed in this report are similar to those described in other toxoplasmosis cases (Howerth et al., 1991; Mikaelian et al., 1997; Work et al., 2000, 2002; Dubey et al., 2001; Szabo et al., 2004; Hartley et al., 2008; Ferreira et al., 2012; Jokelainen and Vikoren, 2014).

All quail tissues (liver, spleen, lung and kidney) analyzed were *T. gondii* positive by nested PCR of a 155-bp fragment of B1 target gene. A complete PCR-RFLP genotyping for the 11 markers was possible with lung and kidney fragments. The alleles observed are described in Table 1. This is an atypical genotype, corresponding to ToxoDB-PCR-RFLP #87. This genotype has already been described in an isolate from a free-range chicken from Canguçu municipality, also in the state of RS, 250 km from the location where the quail examined in this study died (Dubey et al., 2007). This *T. gondii* strain from the quail was named PS-TgValquBr1 (PS meaning primary sample, nature of *T. gondii* isolates).

There is little information on the distribution and prevalence of this strain in the state of RS or throughout Brazil. However, limited studies on the genetic and phenotypic nature of *T. gondii* isolates from Brazil and other countries in South America suggest that they are distinct from those in Europe and North America (Pena et al.,

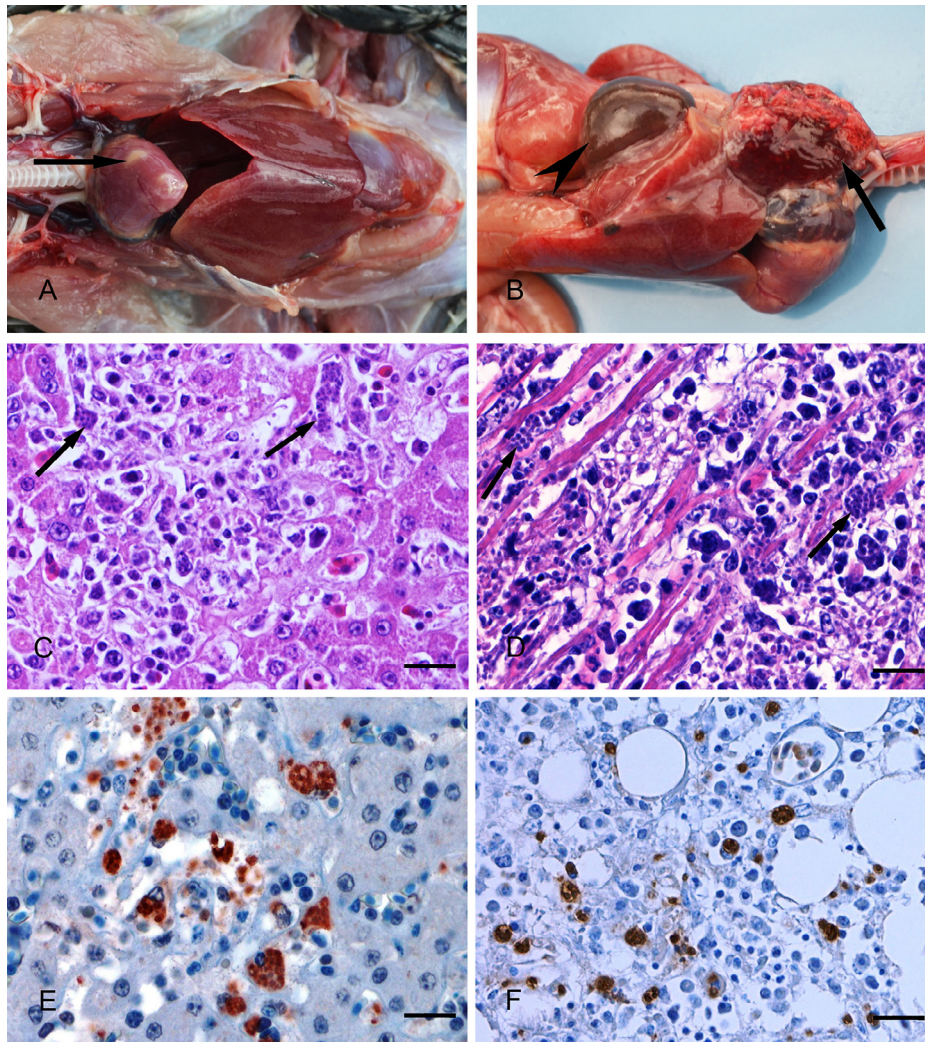


Fig. 1. Toxoplasmosis in Valley quail. (A) Heart with whitish areas (arrow). (B) Lungs diffusely red and consolidated (arrow) and splenomegaly (arrowhead). Liver (C) and heart (D) with multifocal to coalescent severe necrosis associated with *Toxoplasma gondii* tachyzoites (arrows) (H&E stain). Toxoplasma-positive immunohistochemistry in liver (E) and bone marrow (F). Streptavidine-biotine ligated to peroxidase (Bars 100 µm).

2008; Shwab et al., 2014). The identification of this strain of *T. gondii* from quail increases our understanding of the possible relationships between *T. gondii* genotypes and development of clinical manifestations in different hosts. Several factors may contribute to the emergence of clinical toxoplasmosis, such as host genotype and nutritional and immune status, as well as aspects associated with the parasite, like load, stage, and genotype (Sibley et al., 2002).

In summary, the anatomopathological findings and the results of anti-*T. gondii* IHC allow to conclude that the death of the quail analyzed was due to acute disseminated toxoplasmosis. Toxoplasmosis has been reported in captive birds (Howerth et al., 1991; Dubey et al., 2001; Williams et al., 2001; Ferreira et al., 2012), in birds with a history of contact with feces of domestic cats (Hartley et al., 2008), and in free birds (Quist et al., 1995; Work et al., 2000; Szabo et al., 2004).

The presence of cats in the surroundings of the aviaries raises the possibilities of fecal contamination inside the Valley quail aviary. Nevertheless, the bird breeder still keeps cats close, because rat

predation has long been a top cause of bird losses in this as in other aviaries worldwide (Karsten, 2007). All dead birds in this breeding have systematically been submitted to *post-mortem* examinations as well as all the management, breeding and health records have been stored and occasionally published (Cruz et al., 2011). In over twenty years of operation, this center has had no record of bird loss by cat attack and only one dead bird by toxoplasmosis. Although controversial, since the aviaries are adequately installed (comfort zones, pet guards, and double wire mesh curtains), the owner believes that domestic cats may help to manage the rat population within the center grounds. These quails were moved from small indoor cages (prior owner) to an outside planted aviary. Also, their diet has changed from a unique commercial quail ration to a balanced one. It is likely that the stress linked to the modification of the bird's maintenance conditions has been associated with enhanced disease susceptibility and the condition described here. Future studies should be conducted to determine the real prevalence

Table 1
Toxoplasma gondii PCR-RFLP genotyping from Valley quail.

ToxoDB PCR-RFLP genotype #87											
SAG1	3'5'SAG2	SAG2	SAG3	BTUB	GRA6	C22-8	C29-2	L358	PK1	APICO	CS3
I	I	I	III	III	III	I	I	III	I	III	III

and the importance of toxoplasmosis in wild birds breeding farms, as well as in free bird populations in Brazil.

Conflict of interest

The authors declared that there is no conflict of interest.

References

- Calkins, J.D., Hagelin, J.C., Dale, F.L., 1999. *California quail* (*Callipepla californica*). In: Poole, A. (Ed.), *The Birds of North America*. The Birds of North America Online, Ithaca, New York, p. 473.
- Cruz, C.E.F., Oliveira, L.G.S., Boabaid, F.M., Zimmermann, F.C., Stein, G., Marks, F., et al., 2011. Management, breeding, and health records from a captive colony of Pekin Robins (*Leiothrix lutea*), 2001–2010. *J. Zoo Wildl. Med.* 42, 451–459.
- Dubey, J.P., 2002. A review of toxoplasmosis in wild birds. *Vet. Parasitol.* 106, 121–153.
- Dubey, J.P., Ruff, M.D., Camargo, M.E., Shen, K., Wilkins, G.L., Kwok, O.C., et al., 1993a. Serologic and parasitologic responses of domestic chickens after oral inoculation of *Toxoplasma gondii* oocysts. *Am. J. Vet. Res.* 54, 1668–1672.
- Dubey, J.P., Ruff, M.D., Kwok, O.C., Shen, S.K., Wilkins, G.C., Thulliez, P., 1993b. Experimental toxoplasmosis in bobwhite quail (*Colinus virginianus*). *J. Parasitol.* 79, 935–939.
- Dubey, J.P., Goodwin, M.A., Ruff, M.D., Kwok, O.C.H., Shen, S.K., Wilkins, G.C., et al., 1994. Experimental toxoplasmosis in Japanese quail. *J. Vet. Diagn. Invest.* 6, 216–221.
- Dubey, J.P., Lindsay, D.S., Speer, C.A., 1998. Structures of *Toxoplasma gondii* tachyzoites, bradyzoites, and sporozoites and biology and development of tissue cysts. *J. Clin. Microbiol.* 11, 267–299.
- Dubey, J.P., Garner, M.W., Willette, M.M., Batey, K.L., Gardner, C.H., 2001. Disseminated toxoplasmosis in magpie geese (*Anseranas semipalmata*) with large numbers of tissue cysts in livers. *J. Parasitol.* 87, 219–223.
- Dubey, J.P., Gennari, S.M., Labruna, M.B., Camargo, L.M.A., Vianna, M.C.B., Marcet, P.L., et al., 2006. Characterization of *Toxoplasma gondii* isolates in free-range chickens from Amazon, Brazil. *J. Parasitol.* 92, 36–40.
- Dubey, J.P., Sundar, N., Gennari, S.M., Minervino, A.H.H., Farias, N.A.R., Ruas, J.L., et al., 2007. Biologic and genetic comparison of *Toxoplasma gondii* isolates in free-range chickens from the northern Pará state and the southern state Rio Grande do Sul, Brazil revealed highly diverse and distinct parasite populations. *Vet. Parasitol.* 143, 182–188.
- Ferreira, F.C., Jr., Donatti, R.V., Marques, M.V.R., Ecco, R., Preis, I.S., Shivaprasad, H.L., et al., 2012. Fatal toxoplasmosis in a vinaceous amazon parrot (*Amazona vinacea*). *Avian Dis.* 56, 774–777.
- Gerhold, R.W., Yabsley, M.J., 2007. Toxoplasmosis in a red-bellied woodpecker (*Melanerpes carolinus*). *Avian Dis.* 51, 992–994.
- Hartley, J., Booth, R., Slocombe, R.F., Dubey, J.P., 2008. Lethal toxoplasmosis in an aviary of kakarikis (*Cyanoramphus* spp.) in Australia. *J. Parasitol.* 94, 1424–1425.
- Howerth, E.W., Rodenroth, N., 1985. Fatal systemic toxoplasmosis in a wild turkey. *J. Wildl. Dis.* 21, 446–449.
- Howerth, E.W., Rich, G., Dubey, J.P., Yogasundram, K., 1991. Fatal toxoplasmosis in a red lory (*Eos bornea*). *Avian Dis.* 35, 642–646.
- Jokelainen, P., Vikoren, T., 2014. Acute fatal toxoplasmosis in a Great Spotted Woodpecker (*Dendrocopos major*). *J. Wildl. Dis.* 50, 117–120.
- Jones, K.H., Wilson, F.D., Fitzgerald, S.D., Kiupel, M.A., 2012. Natural outbreak of clinical toxoplasmosis in a backyard flock of guinea fowl in Mississippi. *Avian Dis.* 56, 750–753.
- Karsten, P., 2007. *Pekin Robins and Small Softbills – Management and Breeding*. Hancock House Publishers Ltd, Surrey, Canada.
- Mason, R.W., Hartley, W.J., Dubey, J.P., 1991. Lethal toxoplasmosis in a little penguin (*Eudyptula minor*) from Tasmania. *J. Parasitol.* 77, 328.
- Mikaelian, I., Dubey, J.P., Martineau, D., 1997. Severe hepatitis resulting from toxoplasmosis in a barred owl (*Strix varia*) from Québec, Canada. *Avian Dis.* 41, 738–740.
- Pena, H.F.J., Gennari, S.M., Dubey, J.P., Su, C., 2008. Population structure and mouse-virulence of *Toxoplasma gondii* in Brazil. *Int. J. Parasitol.* 38, 561–569.
- Ploeg, M., Ultee, T., Kik, M., 2011. Disseminated Toxoplasmosis in black-footed penguins (*Spheniscus demersus*). *Avian Dis.* 55, 701–703.
- Quist, C.F., Dubey, J.P., Luttrell, M.P., Davidson, W.R., 1995. Toxoplasmosis in wild turkeys: a case report and serologic survey. *J. Wildl. Dis.* 31, 255–258.
- Shwab, E.K., Zhu, X.Q., Majumdar, D., Pena, H.F.J., Gennari, S.M., Dubey, J.P., et al., 2014. Geographical patterns of *Toxoplasma gondii* genetic diversity revealed by multilocus PCR-RFLP genotyping. *Parasitology* 141, 453–461.
- Sibley, L.D., Mordue, D.G., Su, C., Robben, P.M., Howe, D.K., 2002. Genetic approaches to studying virulence and pathogenesis in *Toxoplasma gondii*. *Philos. Trans. R. Soc. Lond. B. Biol. Sci.* 357, 81–88.
- Su, C., Zhang, X., Dubey, J.P., 2006. Genotyping of *Toxoplasma gondii* by multilocus PCR-RFLP markers: a high resolution and simple method for identification of parasites. *Int. J. Parasitol.* 36, 841–848.
- Szabo, K.A., Mense, M.G., Lipscomb, T.P., Felix, K.J., Dubey, J.P., 2004. Fatal toxoplasmosis in a bald eagle (*Haliaeetus leucocephalus*). *J. Parasitol.* 90, 907–908.
- Williams, S.M., Fulton, R.M., Render, J.A., Mansfield, L., Bouldin, M., 2001. Ocular and encephalic toxoplasmosis in canaries. *Avian Dis.* 45, 262–267.
- Work, T.M., Massey, J.G., Rideout, B.A., Gardner, C.H., Ledig, D.B., Kwok, O.C.H., et al., 2000. Fatal toxoplasmosis in free-ranging endangered ‘alala from Hawaii. *J. Wildl. Dis.* 36, 205–212.
- Work, T.M., Massey, J.G., Lindsay, D., Dubey, J.P., 2002. Toxoplasmosis in three species of native and introduced Hawaiian birds. *J. Parasitol.* 88, 1040–1042.
- Yai, L.E.O., Vianna, M.C.B., Soares, R.M., Cortez, A., Freire, R.L., Richtzenhain, L.J., et al., 2003. Evaluation of experimental *Toxoplasma gondii* (Nicolle and Manceaux, 1909) infection in pigs by bioassay in mice and polymerase chain reaction. *Braz. J. Vet. Res. Anim. Sci.* 40, 227–234.