

REVIEW TOPIC OF THE WEEK

Mitral Annulus Calcification



Yigal Abramowitz, MD,* Hasan Jilaihawi, MD,* Tarun Chakravarty, MD,* Michael J. Mack, MD,†
 Raj R. Makkar, MD*

ABSTRACT

Mitral annulus calcification (MAC) is a chronic, degenerative process in the fibrous base of the mitral valve. Although MAC was initially thought to be an age-related degenerative process, there is accumulating evidence that other mechanisms, such as atherosclerosis and abnormal calcium-phosphorus metabolism, also contribute to the development of MAC. Despite its frequency, the clinical relevance of MAC is grossly underappreciated. Indeed, MAC is associated with an increased incidence of cardiovascular disease, mitral valve disease, arrhythmias, and mortality. MAC also influences the outcomes of cardiac surgery and interventions, and its clinical relevance may well increase substantially in the forthcoming era of transcatheter mitral valve replacement. In this paper, we review the available published data to provide a consistent, clinically relevant description of MAC on the basis of contemporary imaging. We describe the pathophysiological mechanisms contributing to the formation of MAC and the clinical implications of this disease entity. (J Am Coll Cardiol 2015;66:1934-41) © 2015 by the American College of Cardiology Foundation.

Mitral annulus calcification (MAC) is a chronic, degenerative process of the fibrous support structure of the mitral valve (1,2). The reported prevalence of MAC is between 8% and 15%, but it significantly increases with age and in patients with multiple cardiovascular risk factors or chronic kidney disease (CKD) (3-7). Although calcification of the mitral annulus was initially thought to be an age-related process, there is accumulating evidence that it is a tightly regulated, active process, with features similar to both medial and atherosclerotic cardiovascular calcification (8). Its clinical relevance comes from MAC's association with an increased rate of mortality and cardiovascular disease (CVD) (9). MAC has also been found to increase the incidence of mitral valve disease and arrhythmias and to influence the outcome of cardiac surgery (2,10,11). We reviewed the available published data to seek: 1) a consistent, clinically relevant

definition of MAC on the basis of contemporary imaging; 2) a firm understanding of its pathogenesis and associations; and 3) the clinical implications of this disease entity.

DEFINITION AND DIAGNOSIS

The mitral annulus separates the left atrium from the left ventricle (LV). It has a complex saddle shape that is divided into anterior and posterior portions. The anterior annulus spans the left and right fibrous trigones and is anatomically coupled to the aortic annulus. The posterior annulus encompasses the remainder of the annular perimeter and is composed of a discontinuous rim of fibrous tissue periodically interrupted by fat (12). MAC is defined as a chronic degenerative process in the fibrous base of the mitral valve (1,2,13). In 1910, Dewitzky recognized noninflammatory calcific disease of the mitral annulus

Listen to this manuscript's audio summary by JACC Editor-in-Chief Dr. Valentin Fuster.



From the *Cedars-Sinai Heart Institute, Los Angeles, California; and the †Department of Cardiovascular Surgery, Heart Hospital Baylor Plano, Baylor Health Care System, Plano, Texas. Dr. Jilaihawi is a consultant for Edwards Lifesciences Corporation, St. Jude Medical, and Venus MedTech. Dr. Mack is a member of the executive committee of the PARTNER trial of Edwards Lifesciences Corporation but is uncompensated; and is coprincipal investigator of the COAPT Trial of Abbott Vascular. Dr. Makkar has received grant support from Edwards Lifesciences Corporation and St. Jude Medical; is a consultant for Abbott Vascular, Cordis, and Medtronic; and holds equity in Entourage Medical. Drs. Abramowitz and Chakravarty have reported that they have no relationships relevant to the contents of this paper to disclose.

Manuscript received June 30, 2015; revised manuscript received August 22, 2015, accepted August 25, 2015.

fibrosus as an entity, presented a detailed pathological description of 36 cases, and likened the lesion to a similar process in the aortic valve described by Mönckeberg in 1904 (1). Large historical autopsy studies found MAC in approximately 10% of patients (3,14). MAC more commonly affects the posterior annulus than the anterior annulus (15,16).

Occasionally, a chest x-ray might reveal calcific demarcation of the mitral annulus. MAC is usually seen as a C-, J-, U- or O-shape, with the open part lying at the site of the aortic outflow tract (2). Lateral projection usually better demonstrates mitral calcification because the overlying spine and main left lower lobe arteries in the posteroanterior view may mask its visualization. Fluoroscopy during coronary angiography can also show mitral calcification, but is not an accurate modality for assessment of the extent of MAC.

Previously, echocardiography was considered to be the best method to demonstrate MAC (17). MAC can be recognized by M-mode echocardiography as an echo-dense band beneath the posterior mitral leaflet, with motion paralleling that of the free ventricular wall (2). The 2-dimensional technique more clearly demonstrates the localization of MAC to the angle between the LV posterior wall and the posterior mitral leaflet (18). MAC is usually visualized as an echo-dense, shelf-like structure with an irregular, lumpy appearance involving the mitral valve annulus, with associated acoustic shadowing. In a subanalysis of the Framingham Heart Study, MAC was assessed by M-mode echocardiography and defined as an echo-dense band visualized throughout systole and diastole, distinguishable from the posterior mitral valve leaflet, and located anterior and parallel to the posterior LV wall (9). In the Cardiovascular Health Study, MAC was defined by an intense echocardiograph-producing structure located at the junction of the atrioventricular groove and posterior mitral leaflet (19). Severity was qualitatively determined in parasternal short-axis view at the level of the mitral annulus as mild (focal, limited increase in echodensity of the mitral annulus), moderate (marked echodensity involving one-third to one-half of the ring circumference), or severe (marked echodensity involving more than one-half of the circumference of the ring or with intrusion into the LV inflow tract). Maximal MAC thickness measured from the anterior to the posterior edge at its greatest width is also used to assess MAC severity, with a value >4 mm defining severe MAC (20).

It has been suggested that echocardiography is probably not an ideal method for detection of valvular calcification because of its relatively low

specificity in distinguishing between calcification and dense collagen (5). Electron-beam computed tomography (CT) and multislice (spiral) CT are effective, noninvasive techniques for cardiac, coronary, and aortic calcification imaging (4,21). Cardiac CT is a useful tool to predict the extent and location of MAC (22) and to quantify MAC objectively in order to assess the severity and associations of this entity (23). Allison et al. (4) assessed CT scans of 1,242 subjects without known coronary artery disease (CAD) (4). MAC was defined as calcification located at the junction between the left atrium and LV. Quantification of MAC with sufficient reproducibility can also be performed using the Agatston method with calculation of calcification in every level of the mitral annulus (23). Examples of the various diagnostic modalities in a patient with MAC are presented in [Figure 1](#).

PATHOGENESIS AND ASSOCIATIONS

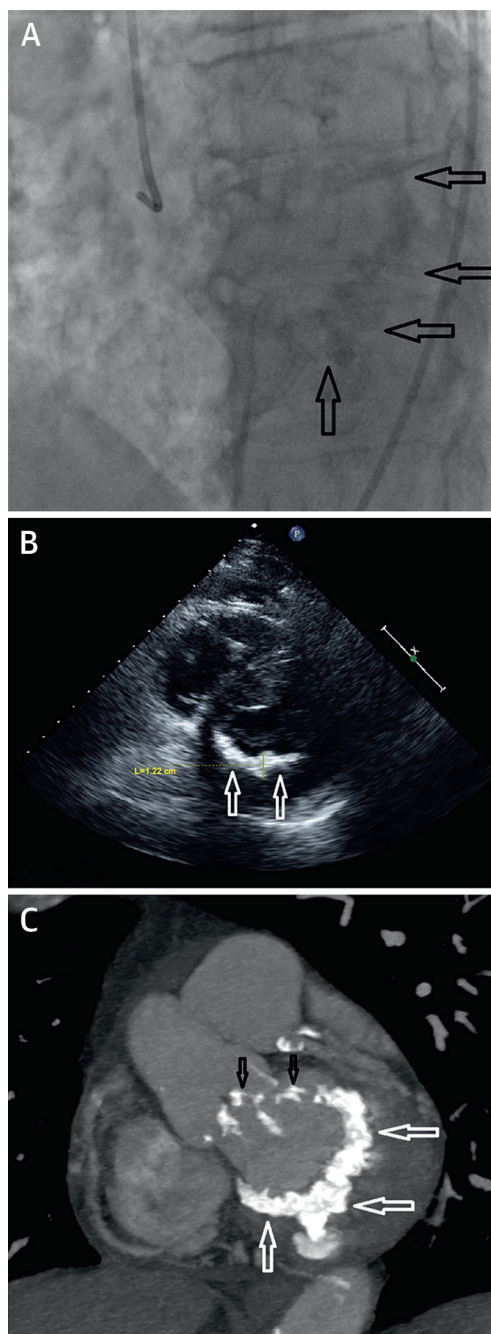
The pathophysiological mechanisms contributing to the formation of MAC are not fully understood. Previous autopsy histological and clinicopathological studies have shed light on the pathogenesis of MAC. Large, contemporary imaging studies that examined the association between MAC and other disease entities, such as atherosclerosis and CKD, have further enhanced our knowledge and enabled a better understanding of this process and its clinical importance ([Central Illustration](#)). Although MAC was first considered a passive, degenerative, age-related process (1,13), accumulating evidence now points toward a tightly regulated process with features similar to both medial and atherosclerotic cardiovascular calcification (8). A comprehensive description of the pathogenesis and associations of MAC can be found in the [Online Appendix](#).

A DEGENERATIVE, AGE-RELATED PROCESS. Sell et al. (13) described calcification of the mitral annulus as a chronic, age-related, degenerative, noninflammatory process in the fibrous support structure of the mitral valve. Kanjanauthai et al. (5) evaluated 6,814 CT scans of participants enrolled in MESA (Multi-Ethnic Study of Atherosclerosis). The overall prevalence of MAC was 9%, and multivariable analysis found increased age to be independently associated with MAC in all ethnicities.

ATHEROSCLEROSIS. On the basis of pathological features seen in specimens from more than 300 patients with MAC (e.g., finding foam cells in early mitral annular lesions) and the strong association

ABBREVIATIONS AND ACRONYMS

AF	= atrial fibrillation
CAD	= coronary artery disease
CKD	= chronic kidney disease
CT	= computed tomography
CVD	= cardiovascular disease
LV	= left ventricle/ventricular
MAC	= mitral annulus calcification
MR	= mitral regurgitation
MVP	= mitral valve prolapse

FIGURE 1 Diagnosis of MAC

A 76-year-old female patient presented for evaluation of severe aortic stenosis. **(A)** Fluoroscopy before selective injection to the right coronary artery in the left anterior oblique projection showing heavily calcified mitral annulus (**black arrows**). **(B)** Transthoracic echocardiography in parasternal short-axis view, demonstrating calcification of the posterior mitral annulus (**white arrows**). The maximal MAC thickness (L) is 1.22 cm. **(C)** Cardiac computed tomography with double oblique view at the mitral annular level, demonstrating C-shaped severe MAC (**white arrows**). There is also calcification in the left ventricular outflow tract and the aortic valve (**black arrows**). MAC = mitral annulus calcification.

between the coexistence of MAC and cardiovascular risk factors, Roberts (24) suggested that MAC and vascular atherosclerosis are different forms of the same disease.

Many studies have shown a strong association between MAC and cardiovascular risk factors (5,17,25). A strong correlation was also demonstrated between MAC and aortic atheroma, carotid atherosclerotic disease, peripheral artery disease, and CAD (17,19). These studies further support the hypothesis that calcification of the mitral annulus is strongly associated with the pathogenesis of atherosclerosis.

CONDITIONS WITH INCREASED MITRAL VALVE STRESS. Degenerative calcification of the mitral annular area is accelerated by conditions that increase mitral valve stress: hypertension, aortic stenosis, and hypertrophic cardiomyopathy (2,15,26). In these conditions, LV peak systolic pressure (and therefore mitral valve closing pressure) is increased, resulting in excess annular tension and subsequent annulus degeneration. Elmariah et al. (27) found recent support for this association by demonstrating a strong correlation between LV hypertrophy and the prevalence, severity, and incidence of MAC. Calcification of the mitral annulus is also associated with the excess tension encountered in disorders of mitral valve motion: mitral valve prolapse (MVP) and mitral valve replacement (2,16,28,29).

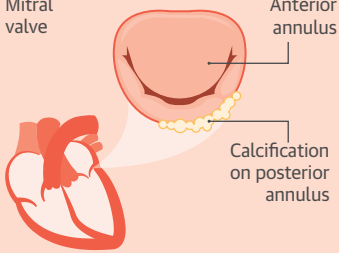
ABNORMAL CALCIUM-PHOSPHORUS METABOLISM. MAC is a common finding in patients with CKD. This association may be partially explained by an increased prevalence and severity of cardiovascular risk factors and atherosclerotic disease in these patients (30). Nonetheless, there is growing evidence that the abnormal calcium-phosphorus metabolism observed in patients with chronic renal failure has a direct role in the pathogenesis of MAC (2,26,31).

CONGENITAL METABOLIC DISORDERS ASSOCIATED WITH MAC. Marfan syndrome. In the past, MAC at <40 years of age was considered a minor diagnostic criterion for Marfan syndrome (32). Aortic root dilation and MVP are common cardiovascular features of this disease (33). It remains unclear whether the mitral annulus calcifies because of increased mitral stress caused by MVP or due to an intrinsic abnormality of the connective tissue composing the annulus.

Hurler syndrome. Calcification of the mitral annulus has been reported in children with Hurler syndrome (34). Abnormal fibroblasts and accelerated collagen degeneration may cause the early appearance of MAC in these patients (2).

SEX-RELATED DIFFERENCES. Contrary to the atherosclerosis paradigm, several studies have found

CENTRAL ILLUSTRATION Mitral Annulus Calcification Overview: Diagnosis, Risk Factors, and Clinical Implications

MITRAL VALVE CALCIFICATION	DIAGNOSTIC IMAGING	RISK FACTORS FOR MAC	CLINICAL IMPLICATIONS
 <p>Definition: chronic degenerative process in the fibrous base of the MV, more commonly in the posterior annulus than the anterior annulus</p>	<ul style="list-style-type: none"> • Echocardiography: MAC is visualized as an echodense structure with an irregular, lumpy appearance and an associated acoustic shadowing. • Computed tomography: Highly effective for cardiac, coronary, and aortic calcification imaging. A useful tool to evaluate the extent and location of MAC. 	<ul style="list-style-type: none"> • Increased age • Female • Chronic kidney disease • Multiple cardiovascular risk factors (hypertension, diabetes mellitus, dyslipidemia, smoking) • Increased MV stress (hypertension, aortic stenosis, hypertrophic cardiomyopathy, MV prolapse) • Metabolic disorders (Marfan syndrome, Hurler syndrome) • Osteoporosis 	<ul style="list-style-type: none"> • Increase in cardiovascular disease and mortality • Increase in MV disease (mitral regurgitation, mitral stenosis, endocarditis) • Increase in arrhythmias (conduction system disease, atrial fibrillation) • Increase in MV surgery complications and mortality

Abramowitz, Y. et al. J Am Coll Cardiol. 2015; 66(17):1934-41.

Histological, clinicopathological, and contemporary imaging studies that examined the association between mitral annulus calcification and other disease entities enhanced our knowledge of the pathogenesis of MAC and enabled a better understanding of this process and its clinical importance. MAC = mitral annulus calcification; MV = mitral valve.

that female sex is associated with an increased risk of developing MAC (5,25,35). On the basis of his systematic pathological evaluation of 200 patients with MAC, Roberts (36) concluded that larger deposits are more frequent in women, although MAC of any degree appears to occur with similar frequency in men and women. It has been suggested that MAC in elderly women can be attributed to ectopic calcium deposits related to the severe bone loss caused by post-menopausal osteoporosis (37).

CLINICAL IMPLICATIONS

MAC is usually an incidental finding in patients being evaluated for cardiovascular or pulmonary diseases. The presence of a calcified mitral annulus is asymptomatic, which precludes true evaluation of the prevalence of MAC in the general population. In large historical autopsy studies, MAC was found in approximately 10% of patients (3,14). CT scans or echocardiography assessments of MAC without defining its severity revealed calcification in 8% to 15% of patients without known CVD (4,5,7,9). The prevalence of MAC was 42% in elderly patients with known CVD (19).

Several clinical implications have been associated with MAC, including CVD, mitral valve disease, and arrhythmias (2,9,11,19,38-40) (Table 1). When severe,

MAC also has implications for the complexity of mitral valve operations (10,16).

MAC AND CARDIOVASCULAR RISK. As discussed earlier, MAC is associated with cardiovascular risk factors as well as with CKD and osteoporosis. There is growing evidence that identification of a calcified

TABLE 1 Summary of the Clinical Implications of MAC

<p>Cardiovascular disease</p> <ul style="list-style-type: none"> ↑ Cardiovascular events (9,42) ↑ Cardiovascular mortality (9,41,43) ↑ CAD (44) ↑ Stroke (47,48)
<p>Mitral valve disease</p> <ul style="list-style-type: none"> ↑ Mitral regurgitation (2,38,52) ↑ Mitral stenosis (only with severe MAC) (1,52) ↑ Endocarditis (39,53,54)
<p>Arrhythmias</p> <ul style="list-style-type: none"> ↑ Conduction system disease (AVB, BBB) (2,39,40) ↑ Atrial fibrillation (11,57)
<p>Cardiac surgery and interventions</p> <ul style="list-style-type: none"> ↑ Complications following mitral valve surgery (10,16) ↑ Intraoperative conversion from mitral valve repair to replacement (29) ↑ PPM implantation and ↓ MR improvement following TAVR (61,62)

↑ = increase in; ↓ = decrease in; AVB = atrioventricular block; BBB = bundle branch block; CAD = coronary artery disease; MAC = mitral annulus calcification; MR = mitral regurgitation; PPM = permanent pacemaker; TAVR = transcatheter aortic valve replacement.

mitral annulus can also be related independently to a higher risk of cardiovascular events and mortality (9,19,41-43). Fox *et al.* (9) examined the association between MAC and CVD among 1,197 subjects over 16 years of follow-up in the Framingham Heart Study. In multivariable adjustment for traditional cardiovascular risk factors, MAC was associated with an increased risk of incident CVD (hazard ratio [HR]: 1.5; 95% confidence interval [CI]: 1.1 to 2.0), cardiovascular death (HR: 1.6; 95% CI: 1.1 to 2.3), and all-cause death (HR: 1.3; 95% CI: 1.04 to 1.6). Interestingly, Atar *et al.* (44) found that MAC is associated with an increased prevalence of severe obstructive CAD. Possible explanations for these findings are that MAC may be a marker for atherosclerotic disease burden or that other unmeasured factors, such as metabolic, inflammatory, and hemostatic risk factors, might be responsible for the increased risk of CVD and mortality in patients with MAC (9,17).

There are inconsistent findings with respect to the association between MAC and the risk for clinical stroke (45-49). Rodriguez *et al.* (49) found that MAC is associated with increased risk for brain infarcts, but this association diminished after adjustments for potential confounders. However, Kizer *et al.* (48) found that the presence of MAC is a strong risk factor for stroke after adjustments for other predictors. Possible explanations for the association between MAC and clinical stroke may derive from the increased incidence of carotid atherosclerotic disease, aortic atheroma, and atrial fibrillation (AF) among patients with MAC (11,17), or from direct embolization of mobile calcified annular components that may cause brain infarcts (50).

MAC AND MITRAL VALVE DISEASE. MAC generally has little or no effect on LV inflow or mitral valve function because, unlike in rheumatic mitral involvement, there is usual sparing of the leaflet commissures in these patients (2). Nonetheless, severe calcification of the mitral annulus may occasionally cause mitral regurgitation (MR) or mitral stenosis (2,38,51,52).

There is limited evidence that MAC is associated with an increased risk of MR and that it may exacerbate MR in some cases (2,38,52). Movahed *et al.* (38) examined 24,380 echocardiograms and found MAC to be present in 11.7% of patients with MR versus 4.3% without MR. A possible mechanism for this association is that calcium infiltration of the base of the posterior leaflet reduces leaflet mobility, increases traction on the chordae, and elevates the leaflets. This facilitates chordal elongation or rupture, causing secondary MR. An alternative mechanism is failure of the calcified annulus to contract at the end of diastole (52).

Mitral stenosis due to annular calcification is reported to be quite rare (2). Nonetheless, it was demonstrated that severe MAC could produce a significant resting gradient across the mitral valve, thus causing mitral stenosis (1,52). This process was seen in approximately 0.5% of unselected outpatient echocardiograms and appeared to be mechanically linked to restriction of anterior mitral leaflet motion, such that the leaflet's hinge becomes displaced toward its free margin (51).

The risk of endocarditis in patients with MAC is unknown. In a review of 80 patients with MAC, Fullerson *et al.* (39) reported 3 cases of endocarditis (4%). Endocarditis lesions included vegetation on the mitral valve leaflets and, less commonly, on the calcified annulus, as well as paravalvular abscesses in the region of MAC (53). Poor clinical outcomes and increased mortality were associated with mitral annulus lesions, rather than leaflet lesions. Limited data also suggest high mortality (29%) among patients with MAC undergoing surgery for MR due to infective endocarditis (54).

MAC AND ARRHYTHMIAS. Conduction system disease.

The association between MAC and conduction system abnormalities was noted in the earliest reports of this entity (2). Patients with MAC have higher prevalence of atrioventricular block, bundle branch block, and intraventricular conduction delay (2,39). Nair *et al.* (40) examined 104 patients with MAC and compared them with 121 matched control subjects. Conduction defects were found to be prevalent in 70% of patients with MAC versus 34% of control patients. The higher incidence of conduction disease may be partially due to direct extension of calcific deposits to the region of the atrioventricular node and the bundle of His (55). Nonetheless, the prevalence of conduction disturbances in patients with MAC, even among those with MAC remote from the primary conduction system (40), and the prevalence of remote conduction disease (e.g., atrial conduction delay) (56) suggest that diffuse degenerative conduction system disease is frequently associated with MAC.

Atrial fibrillation. Several large-scale, community-based cohort studies observed a strong association between the presence of MAC and AF. This association is independent of baseline clinical risk factors for AF and of the development of interim myocardial infarction or heart failure (11,57). In a multivariable-adjusted analysis of 1,126 patients from the cohort of the Framingham Heart Study, MAC was associated with an increased risk of AF (HR: 1.6; 95% CI: 1.1 to 2.2) (57). This association was further supported by a recent large analysis of the ethnically diverse

population of MESA. Among 6,641 participants, the multivariable model revealed a strong and consistent association between MAC and AF (HR: 1.9; 95% CI: 1.5 to 2.5) (11). The mechanisms by which MAC predisposes to AF incidence are likely multifactorial, but appear to be partially mediated through left atrial enlargement (57). MAC might also interrupt the interatrial and intra-atrial conduction processes, leading to conduction system and atrial conduction defects, thus resulting in AF (56).

MAC AND CARDIAC SURGERY/INTERVENTIONS. Severe calcification of the mitral annulus can pose significant challenges to the surgeon undertaking mitral valve replacement or repair. It is a contributing factor in cardiac rupture at the atrioventricular junction, in rupture of the LV free wall, and in injury to the circumflex artery when debridement of MAC is performed (10,16). Fusini et al. (29) found MAC to be present among 24% of patients (99 of 410) referred for mitral valve surgery. MAC was associated with increased intraoperative conversion from valve repair to replacement (8% of patients with MAC vs. 3% of patients without MAC; $p = 0.04$). In contrast, in a series published by Chan et al. (58), MAC was present in 19% of patients (119 of 625) referred for mitral valve surgery and was not found to be a significant risk factor for conversion to mitral valve replacement.

A variety of surgical procedures have been proposed to avoid the surgical complications mentioned earlier. One approach is to perform mitral valve replacement without annular calcium debridement, securing the prosthetic valve inside the calcified annulus (10). This approach may be complicated by periprosthetic leakage or by the inability to place an adequately sized prosthetic valve without some debridement. Another approach is to perform mitral valve edge-to-edge repair without annulus reconstruction; however, this can lead to unacceptable mitral valve gradients post-procedure (59). The main disadvantage of this technique is reduced durability, resulting in an increased need for reoperation. The preferred approach is complete decalcification and reconstruction of the mitral annulus using methods that have evolved from the treatment of annular abscesses (10,16). In this approach, the calcified annulus is dissected, followed by reconstruction, which can be achieved using annular suturing, an atrial flap, or an autologous pericardial patch (16). This technique is preferably followed by mitral valve repair, if possible, or by implantation of a prosthetic valve.

MAC also has clinical implications for rapidly evolving transcatheter valve procedures. In past

years, severe MAC has been frequently considered a contraindication for percutaneous mitral repair (60). Nonetheless, a recent small case series suggested that percutaneous mitral repair with the MitraClip (Abbott Vascular, Santa Clara, California) in the setting of severe MAC is feasible, safe, and acceptably effective (60). MAC was found to be an independent predictor of permanent pacemaker implantation and of reduction in MR improvement following transcatheter aortic valve replacement (61,62). Manipulation of wires and large balloons during this procedure may increase calcium debris, resulting in brain or coronary emboli in patients with severe MAC, although this association has not yet been properly evaluated. In the future, transcatheter mitral valve replacement may become a valuable alternative to mitral valve surgery for patients with severe MR and a high surgical risk (63). Among the many challenges faced by the developers of these devices are lack of complete, circumferential annular calcification, preventing stable anchoring, and severe MAC, predisposing to annular rupture during valve deployment. Experience with this technique has been mixed to date, with some successes but a high rate of prosthesis embolization.

CONCLUSIONS

Initially, MAC was considered a passive, degenerative, age-related process, but there is now accumulating evidence that it can also result from an active atherosclerotic process. Other mechanisms, such as increased mitral valve stress caused by aortic stenosis or by hypertension and abnormal calcium-phosphorus metabolism caused by CKD, may also contribute to the development of MAC. There is growing evidence that identification of a calcified mitral annulus can also be related to a higher risk of cardiovascular events, arrhythmias, mitral valve disease, and mortality. Patients with MAC undergoing conventional mitral valve surgery require procedural modifications to attenuate periprocedural risk of complications. Routine use of chest CT in the work-up of all patients evaluated before cardiac surgery or transcatheter valve interventions may help elucidate the true incidence and clinical implications of MAC.

REPRINT REQUESTS AND CORRESPONDENCE: Dr. Raj R. Makkar, Cedars-Sinai Heart Institute, 127 South San Vicente Boulevard, AHSP, Suite A3600, Los Angeles, California 90048. E-mail: Raj.Makkar@cshs.org.

REFERENCES

- Korn D, Desanctis RW, Sell S. Massive calcification of the mitral annulus. A clinicopathological study of fourteen cases. *N Engl J Med* 1962;267:900-9.
- Nestico PF, Depace NL, Morganroth J, et al. Mitral annular calcification: clinical, pathophysiology, and echocardiographic review. *Am Heart J* 1984;107:989-96.
- Fertman MH, Wolff L. Calcification of the mitral valve. *Am Heart J* 1946;31:580-9.
- Allison MA, Cheung P, Criqui MH, et al. Mitral and aortic annular calcification are highly associated with systemic calcified atherosclerosis. *Circulation* 2006;113:861-6.
- Kanjanauthai S, Nasir K, Katz R, et al. Relationships of mitral annular calcification to cardiovascular risk factors: the Multi-Ethnic Study of Atherosclerosis (MESA). *Atherosclerosis* 2010;213:558-62.
- Asselbergs FW, Mozaffarian D, Katz R, et al. Association of renal function with cardiac calcifications in older adults: the cardiovascular health study. *Nephrol Dial Transplant* 2009;24:834-40.
- Foley PW, Hamaad A, El-Gendi H, et al. Incidental cardiac findings on computed tomography imaging of the thorax. *BMC Res Notes* 2010;3:326.
- Johnson RC, Leopold JA, Loscalzo J. Vascular calcification: pathobiological mechanisms and clinical implications. *Circ Res* 2006;99:1044-59.
- Fox CS, Vasan RS, Parise H, et al. Mitral annular calcification predicts cardiovascular morbidity and mortality: the Framingham Heart Study. *Circulation* 2003;107:1492-6.
- Okada Y. Surgical management of mitral annular calcification. *Gen Thorac Cardiovasc Surg* 2013;61:619-25.
- O'Neal WT, Efrid JT, Nazarian S, et al. Mitral annular calcification and incident atrial fibrillation in the Multi-Ethnic Study of Atherosclerosis. *Europace* 2015;17:358-63.
- Silbiger JJ, Bazaz R. Contemporary insights into the functional anatomy of the mitral valve. *Am Heart J* 2009;158:887-95.
- Sell S, Scully RE. Aging changes in the aortic and mitral valves. Histologic and histochemical studies, with observations on the pathogenesis of calcific aortic stenosis and calcification of the mitral annulus. *Am J Pathol* 1965;46:345-65.
- Simon MA, Liu SF. Calcification of the mitral valve annulus and its relation to functional valvular disturbance. *Am Heart J* 1954;48:497-505.
- Roberts WC, Perloff JK. Mitral valvular disease: a clinicopathologic survey of the conditions causing the mitral valve to function abnormally. *Ann Intern Med* 1972;77:939-75.
- Carpentier AF, Pellerin M, Fuzellier JF, et al. Extensive calcification of the mitral valve annulus: pathology and surgical management. *J Thorac Cardiovasc Surg* 1996;111:718-29, discussion 729-30.
- Adler Y, Fink N, Spector D, et al. Mitral annulus calcification—a window to diffuse atherosclerosis of the vascular system. *Atherosclerosis* 2001;155:1-8.
- D'Cruz I, Panetta F, Cohen H, et al. Submitral calcification or sclerosis in elderly patients: M mode and two dimensional echocardiography in "mitral annulus calcification." *Am J Cardiol* 1979;44:31-8.
- Barasch E, Gottdiener JS, Larsen EKM, et al. Clinical significance of calcification of the fibrous skeleton of the heart and aortosclerosis in community dwelling elderly. The Cardiovascular Health Study (CHS). *Am Heart J* 2006;151:39-47.
- Kohsaka S, Jin Z, Rundek T, et al. Impact of mitral annular calcification on cardiovascular events in a multiethnic community: the Northern Manhattan Study. *J Am Coll Cardiol Img* 2008;1:617-23.
- Eisen A, Tenenbaum A, Koren-Morag N, et al. Calcification of the thoracic aorta as detected by spiral computed tomography among stable angina pectoris patients: association with cardiovascular events and death. *Circulation* 2008;118:1328-34.
- Higgins J, Mayo J, Skarsgard P. Cardiac computed tomography facilitates operative planning in patients with mitral calcification. *Ann Thorac Surg* 2013;95:e9-11.
- Hamirani YS, Nasir K, Blumenthal RS, et al. Relation of mitral annular calcium and coronary calcium (from the Multi-Ethnic Study of Atherosclerosis [MESA]). *Am J Cardiol* 2011;107:1291-4.
- Roberts WC. The senile cardiac calcification syndrome. *Am J Cardiol* 1986;58:572-4.
- Boon A, Cheriex E, Lodder J, et al. Cardiac valve calcification: characteristics of patients with calcification of the mitral annulus or aortic valve. *Heart* 1997;78:472-4.
- Silbiger JJ. Anatomy, mechanics, and pathophysiology of the mitral annulus. *Am Heart J* 2012;164:163-76.
- Elmariah S, Delaney JAC, Bluemke DA, et al. Associations of LV hypertrophy with prevalent and incident valve calcification: Multi-Ethnic Study of Atherosclerosis. *J Am Coll Cardiol Img* 2012;5:781-8.
- Newcomb AE, David TE, Lad VS, Bobiarski J, Armstrong S, Maganti M. Mitral valve repair for advanced myxomatous degeneration with posterior displacement of the mitral annulus. *J Thorac Cardiovasc Surg* 2008;136:1503-9.
- Fusini L, Ghulam Ali S, Tamborini G, et al. Prevalence of calcification of the mitral valve annulus in patients undergoing surgical repair of mitral valve prolapse. *Am J Cardiol* 2014;113:1867-73.
- Fox CS, Larson MG, Vasan RS, et al. Cross-sectional association of kidney function with valvular and annular calcification: the Framingham heart study. *J Am Soc Nephrol* 2006;17:521-7.
- Umana E, Ahmed W, Alpert MA. Valvular and perivalvular abnormalities in end-stage renal disease. *Am J Med Sci* 2003;325:237-42.
- Correia J, Rodrigues D, da Silva AM, et al. Massive calcification of the mitral valve annulus in an adolescent with Marfan syndrome. A case report. *Rev Port Cardiol* 2006;25:921-6.
- Radke RM, Baumgartner H. Diagnosis and treatment of Marfan syndrome: an update. *Heart* 2014;100:1382-91.
- Schieken RM, Kerber RE, Ionasescu VV, et al. Cardiac manifestations of the mucopolysaccharidoses. *Circulation* 1975;52:700-5.
- Elmariah S, Budoff MJ, Delaney JAC, et al. Risk factors associated with the incidence and progression of mitral annulus calcification: the Multi-Ethnic Study of Atherosclerosis. *Am Heart J* 2013;166:904-12.
- Roberts WC. Morphologic features of the normal and abnormal mitral valve. *Am J Cardiol* 1983;51:1005-28.
- Sugihara N, Matsuzaki M. The influence of severe bone loss on mitral annular calcification in postmenopausal osteoporosis of elderly Japanese women. *Jpn Circ J* 1993;57:14-26.
- Movahed MR, Saito Y, Ahmadi-Kashani M, et al. Mitral annulus calcification is associated with valvular and cardiac structural abnormalities. *Cardiovasc Ultrasound* 2007;5:14.
- Fulkerson PK, Beaver BM, Auseon JC, et al. Calcification of the mitral annulus: etiology, clinical associations, complications and therapy. *Am J Med* 1979;66:967-77.
- Nair CK, Runco V, Everson GT, et al. Conduction defects and mitral annulus calcification. *Br Heart J* 1980;44:162-7.
- Völzke H, Haring R, Lörbecker R, et al. Heart valve sclerosis predicts all-cause and cardiovascular mortality. *Atherosclerosis* 2010;209:606-10.
- Gondrie MJA, van der Graaf Y, Jacobs PC, et al., for the PROVIDI Study Group. The association of incidentally detected heart valve calcification with future cardiovascular events. *Eur Radiol* 2011;21:963-73.
- Ramaraj R, Manrique C, Hashemzadeh M, et al. Mitral annulus calcification is independently associated with all-cause mortality. *Exp Clin Cardiol* 2013;18:e5-7.
- Atar S, Jeon DS, Luo H, et al. Mitral annular calcification: a marker of severe coronary artery disease in patients under 65 years old. *Heart* 2003;89:161-4.
- Gardin JM, McClelland R, Kitzman D, et al. M-mode echocardiographic predictors of six- to seven-year incidence of coronary heart disease, stroke, congestive heart failure, and mortality in an elderly cohort (the Cardiovascular Health Study). *Am J Cardiol* 2001;87:1051-7.
- Boon A, Lodder J, Cheriex E, et al. Mitral annulus calcification is not an independent risk factor for stroke: a cohort study of 657 patients. *J Neurol* 1997;244:535-41.
- Benjamin EJ, Plehn JF, D'Agostino RB, et al. Mitral annular calcification and the risk of stroke in an elderly cohort. *N Engl J Med* 1992;327:374-9.

48. Kizer JR, Wiebers DO, Whisnant JP, et al. Mitral annular calcification, aortic valve sclerosis, and incident stroke in adults free of clinical cardiovascular disease: the Strong Heart Study. *Stroke* 2005;36:2533-7.
49. Rodriguez CJ, Bartz TM, Longstreth WT Jr., et al. Association of annular calcification and aortic valve sclerosis with brain findings on magnetic resonance imaging in community dwelling older adults: the Cardiovascular Health Study. *J Am Coll Cardiol* 2011;57:2172-80.
50. Willens HJ, Ferreira AC, Gallagher AJ, et al. Mobile components associated with rapidly developing mitral annulus calcification in patients with chronic renal failure: review of mobile elements associated with mitral annulus calcification. *Echocardiography* 2003;20:363-7.
51. Muddassir SM, Pressman GS. Mitral annular calcification as a cause of mitral valve gradients. *Int J Cardiol* 2007;123:58-62.
52. Labovitz AJ, Nelson JG, Windhorst DM, et al. Frequency of mitral valve dysfunction from mitral annular calcium as detected by Doppler echocardiography. *Am J Cardiol* 1985;55:133-7.
53. Eicher JC, De Nadai L, Soto FX, et al. Bacterial endocarditis complicating mitral annular calcification: a clinical and echocardiographic study. *J Heart Valve Dis* 2004;13:217-27.
54. Vistarini N, d'Alessandro C, Aubert S, et al. Surgery for infective endocarditis on mitral annulus calcification. *J Heart Valve Dis* 2007;16:611-6.
55. Takamoto T, Popp RL. Conduction disturbances related to the site and severity of mitral annular calcification: a 2-dimensional echocardiographic and electrocardiographic correlative study. *Am J Cardiol* 1983;51:1644-9.
56. Pekdemir H, Cansel M, Yağmur J, et al. Assessment of atrial conduction time by tissue Doppler echocardiography and P-wave dispersion in patients with mitral annulus calcification. *J Electrocardiol* 2010;43:339-43.
57. Fox CS, Parise H, Vasan RS, et al. Mitral annular calcification is a predictor for incident atrial fibrillation. *Atherosclerosis* 2004;173:291-4.
58. Chan V, Ruel M, Hynes M, et al. Impact of mitral annular calcification on early and late outcomes following mitral valve repair of myxomatous degeneration. *Interact Cardiovasc Thorac Surg* 2013;17:120-5.
59. Maisano F, Caldarola A, Blasio A, et al. Midterm results of edge-to-edge mitral valve repair without annuloplasty. *J Thorac Cardiovasc Surg* 2003;126:1987-97.
60. Buzzatti N. Percutaneous mitral repair in the setting of severe mitral annular calcification: midterm results from a single centre experience. Paper presented at: EuroPCR 2015; May 20, 2015; Paris, France.
61. Boerlage-Van Dijk K, Kooiman KM, Yong ZY, et al. Predictors and permanency of cardiac conduction disorders and necessity of pacing after transcatheter aortic valve implantation. *Pacing Clin Electrophysiol* 2014;37:1520-9.
62. Durst R, Avelar E, McCarty D, et al. Outcome and improvement predictors of mitral regurgitation after transcatheter aortic valve implantation. *J Heart Valve Dis* 2011;20:272-81.
63. De Backer O, Piazza N, Banai S, et al. Percutaneous transcatheter mitral valve replacement: an overview of devices in preclinical and early clinical evaluation. *Circ Cardiovasc Interv* 2014;7:400-9.

KEY WORDS calcified, cardiovascular diseases, mitral annular calcification, mitral valve, valvular calcification

APPENDIX For a further description of the pathogenesis and associations of MAC, please see the online version of this article.