

Available online at www.sciencedirect.com**ScienceDirect**

Journal of the Chinese Medical Association 78 (2015) 424–426

www.jcma-online.com

Case Report

Acute simultaneous multiple lacunar infarcts as the initial presentation of cerebral autosomal dominant arteriopathy with subcortical infarcts and leukoencephalopathy

Cheng-Tsung Hsiao ^a, Yun-Chung Chen ^a, Yo-Tsen Liu ^{a,b}, Bing-Wen Soong ^{a,b,c},
Yi-Chung Lee ^{a,b,c,*}^a Department of Neurology, Taipei Veterans General Hospital, Taipei, Taiwan, ROC^b Department of Neurology, National Yang-Ming University School of Medicine, Taipei, Taiwan, ROC^c Brain Research Center, National Yang-Ming University, Taipei, Taiwan, ROC

Received August 28, 2014; accepted January 6, 2015

Abstract

Cerebral autosomal dominant arteriopathy with subcortical infarcts and leukoencephalopathy (CADASIL) is an adult-onset, dominantly inherited small-vessel disease of the brain caused by *NOTCH3* mutations and characterized by recurrent subcortical infarctions, dementia, migraine with aura, and mood disturbance. We report a patient with unusual presentation of CADASIL with acute simultaneous multiple subcortical lacunar infarcts as the first manifestation. A 69-year-old man developed confusion, drowsiness, right hemiparesis, and slurred speech following orthopedic surgeries. Brain magnetic resonance imaging revealed diffuse leukoencephalopathy and multiple acute subcortical lacunar infarcts. Brain magnetic resonance angiography, echocardiography and 24-hour electrocardiography were unremarkable. The symptoms improved quickly after treatment with fluid hydration and antiplatelet agent, and his consciousness and mentality totally recovered within 3 days. The *NOTCH3* genetic testing showed a heterozygous missense mutation, c.1630C>T (p. Arg544Cys). The experience in this case suggests that brain imaging is important in managing postoperative confusion, and any patient with diffuse leukoencephalopathy of unknown etiology may need to be tested for *NOTCH3* mutations. Surgery is an important factor of encephalopathy and acute infarction in individuals with *NOTCH3* mutations. Comprehensive presurgical evaluations and proactive perioperative precautions to avoid dehydration and anemia are necessary for patients with CADASIL who are about to receive anesthesia and surgery.

Copyright © 2015 Elsevier Taiwan LLC and the Chinese Medical Association. All rights reserved.

Keywords: CADASIL encephalopathy; multiple lacunar infarcts; *NOTCH3*

1. Introduction

Cerebral autosomal dominant arteriopathy with subcortical infarcts and leukoencephalopathy (CADASIL), the most

Conflicts of interest: The authors declare that there are no conflicts of interest related to the subject matter or materials discussed in this article.

* Corresponding author. Dr. Yi-Chung Lee, Department of Neurology, Taipei Veterans General Hospital, 201, Section 2, Shih-Pai Road, Taipei 112, Taiwan, ROC.

E-mail address: ycli@vghtpe.gov.tw (Y.-C. Lee).

<http://dx.doi.org/10.1016/j.jcma.2015.01.007>

1726-4901/Copyright © 2015 Elsevier Taiwan LLC and the Chinese Medical Association. All rights reserved.

common monogenic small-vessel disease of the brain, is caused by mutations in the *NOTCH3* gene. It is an adult-onset, dominantly inherited disease with main manifestations of recurrent subcortical ischemic events, dementia, migraine with aura, and mood disturbance.^{1,2} While acute simultaneous multiple lacunar infarcts have never been reported in any patient with CADASIL before, CADASIL also rarely presents with an acute encephalopathy.^{3–6} Here we report a patient presenting with acute simultaneous multiple subcortical lacunar infarcts and acute encephalopathy as the first manifestation of CADASIL, following orthopedic surgeries.

2. Case report

A 69-year-old man was admitted to our hospital for total knee arthroplasties on both sides. His past history was remarkable only for osteoarthritis in both knees. His mother and younger brother had strokes at age 76 years and 59 years, respectively. Four days after the operation, he had a fall and had a left medial femoral condylar periprosthetic fracture. Then, he received a surgical revision for the prosthetic. After the second surgery, the patient manifested acute confusion, which spontaneously subsided within 1 day. Four days after that event, he had another episode of consciousness deterioration, with Glasgow coma scale of E4V2M5, right hemiparesis and slurred speech. Brain magnetic resonance imaging (MRI) featured diffuse leukoencephalopathy on fluid-attenuated inversion recovery imaging and multiple acute lacunar infarcts over bilateral centrum semiovale and corona radiata presenting as hyperintense diffusion-weighted imaging (DWI) lesions coinciding with reduced apparent diffusion coefficient signals (Fig. 1A–F). Brain magnetic resonance angiography demonstrated that all the major intracranial vessels were patent. Echocardiography and 24-hour electrocardiography were unremarkable. The symptoms improved hours after their onset with supportive treatment with fluid hydration

and antiplatelet agent, and the patient's consciousness and mentality totally recovered within 3 days. Because the patient had both diffuse leukoencephalopathy and family history of stroke, we arranged genetic testing of the *NOTCH3* gene and found a heterozygous missense mutation, c.1630C>T (p.Arg544Cys), in exon 11 (Fig. 1G).

3. Discussion

CADASIL is a small-vessel disease of the brain that compromises cerebral circulation, and which may be further worsened under certain circumstances, such as dehydration, blood loss, anemia, or cerebral vasoconstriction. The orthopedic surgeries on this patient put stress on his circulation and might have provoked generalized cerebral hypoperfusion, which caused acute simultaneous multiple lacunar infarctions and acute reversible encephalopathy. Acute simultaneous multiple small ischemic stroke is usually attributed to cardiac or carotid arterial emboli,^{7–9} which were unlikely to be the cause of acute lacunar infarcts in our patient because of the normal results on cardiac evaluation and brain magnetic resonance angiography. In two recent studies, small-vessel diseases of the brain have been proved to be an important cause of acute multiple lacunar infarcts.^{10,11} These findings

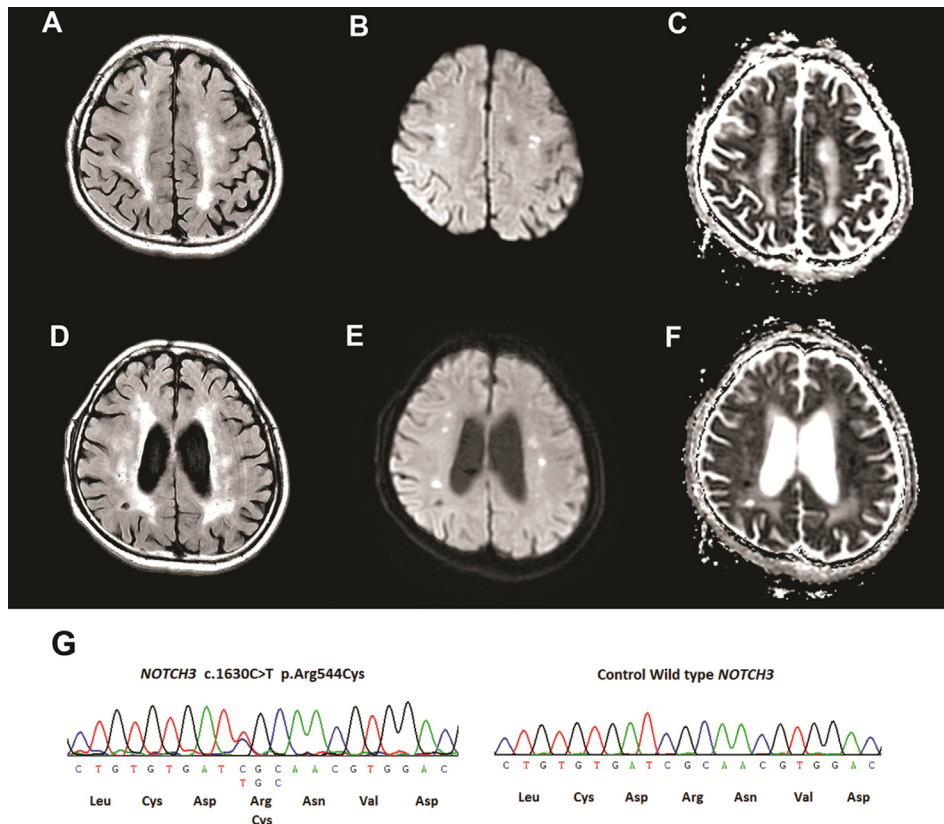


Fig. 1. Brain magnetic resonance imaging demonstrating diffuse leukoencephalopathy on fluid-attenuated inversion recovery images (A and D) and multiple acute lacunar infarcts over bilateral centrum semiovale and corona radiata presenting as hyperintense diffusion-weighted imaging lesions (B and E) coinciding with reduced apparent diffusion coefficient signals (C and F). (G) Electropherogram demonstrating a heterozygous c.1630C>T mutation in the *NOTCH3* gene, with a limited reading frame depicting the corresponding amino acid substitution (p.Arg544Cys).

support that acute simultaneous multiple lacunar infarcts in the patient was a rare presentation of CADASIL.

Acute encephalopathy is an uncommon manifestation of CADASIL.^{3–6} Patients with CADASIL encephalopathy have a variable degree of confusion, amnesia, agitations, consciousness change, fever or no fever, persistent aura, or other focal neurological signs. The symptoms are usually reversible and last from 2 hours to 14 days. During an attack of CADASIL encephalopathy, the brain MRI usually reveals no acute cerebral infarcts but instead diffuse leukoaraiosis featuring CADASIL. Preceding the occurrence of almost all reported CADASIL encephalopathy, there was always migraine or recurrent aura.^{3–6} In these cases, cerebral vasoconstriction accompanied with migraine might have been the cause precipitating the attacks of CADASIL encephalopathy.¹² Acute encephalopathy in our patient with CADASIL and acute multiple lacunar infarctions suggests that, in addition to migraine, any factors compromising brain circulation may also be capable of provoking CADASIL encephalopathy.

While the first symptom of CADASIL generally occurs in mid-adult age,¹ the clinical onset in this case was at age 69 years. In our previous study, the mean age at symptom onset of the 22 Taiwanese patients with CADASIL was 48.6 years, and two patients had a disease onset later than 70 years (72 years and 77 years).² There were also two reports in literature about two CADASIL patients with minimal symptoms at age 79 years and 86 years, respectively.^{13,14} All the above cases displayed a typical course of insidious onset, progressive mental decline and/or recurrent cerebral vascular events. However, the present patient experienced an acute reversible encephalopathy with multiple lacunar infarcts, which is a very rare clinical presentation of CADASIL. The late onset of symptoms of this patient and others further emphasizes that it is still important to consider CADASIL as a diagnostic possibility in elderly patients with small ischemic stroke and leukoencephalopathy.

Our experience with this patient implicates that brain imaging is warranted in patients with postoperative consciousness alteration, and any patient with diffuse leukoencephalopathy of unknown etiology may need to be tested for *NOTCH3* mutation. Surgery is an important factor of CADASIL encephalopathy and acute infarction in individuals with mutations in *NOTCH3*. Comprehensive pre-surgical evaluations and proactive perioperative precautions to avoid dehydration and anemia are necessary for patients with CADASIL who are about to receive anesthesia and surgery.

Acknowledgments

We would like to thank the patient who participated in this study. We also thank the High-throughput Genome Analysis Core Facility of the National Core Facility Program for Biotechnology, Taiwan (NSC 102-2319-B-010-001), for sequencing. This work was supported by a Taipei Veterans General Hospital, Taipei, Taiwan research grant (V102C-017).

References

- Chabriat H, Joutel A, Dichgans M, Tournier-Lasserre E, Bousser MG. Cadasil. *Lancet Neurol* 2009;**8**:643–53.
- Lee YC, Liu CS, Chang MH, Lin KP, Fuh JL, Lu YC, et al. Population-specific spectrum of *NOTCH3* mutations, MRI features and founder effect of CADASIL in Chinese. *J Neurol* 2009;**256**:249–55.
- Kleinig TJ, Kimber T, Thompson PD. Acute encephalopathy as the initial symptom of CADASIL. *Intern Med J* 2007;**37**:786–7.
- Le Ber I, Carlier L, Derache N, Lalevée C, Ledoze F, Defer GL. Unusual presentation of CADASIL with reversible coma and confusion. *Neurology* 2002;**59**:1115–6.
- Sathe S, DePeralta E, Pastores G, Kolodny EH. Acute confusional migraine may be a presenting feature of CADASIL. *Headache* 2009;**49**:590–6.
- Schon F, Martin RJ, Prevett M, Clough C, Enevoldson TP, Markus HS. “CADASIL coma”: an underdiagnosed acute encephalopathy. *J Neurol Neurosurg Psychiatry* 2003;**74**:249–52.
- Seifert T, Enzinger C, Storch MK, Pichler G, Niederkorn K, Fazekas F. Acute small subcortical infarctions on diffusion weighted MRI: clinical presentation and aetiology. *J Neurol Neurosurg Psychiatry* 2005;**76**:1520–4.
- Ay H, Oliveira-Filho J, Buonanno FS, Ezzeddine M, Schaefer PW, Rordorf G, et al. Diffusion-weighted imaging identifies a subset of lacunar infarction associated with embolic source. *Stroke* 1999;**30**:2644–50.
- Takahashi K, Kobayashi S, Matui R, Yamaguchi S, Yamashita K. The differences of clinical parameters between small multiple ischemic lesions and single lesion detected by diffusion-weighted MRI. *Acta Neurol Scand* 2002;**106**:24–9.
- Lee JH, Kim YJ, Moon Y, Cho HJ, Kim HY. Acute simultaneous multiple lacunar infarcts: a severe disease entity in small artery disease. *Eur Neurol* 2012;**67**:303–11.
- Wolf ME, Sauer T, Kern R, Szabo K, Hennerici MG. Multiple subcortical acute ischemic lesions reflect small vessel disease rather than cardiogenic embolism. *J Neurol* 2012;**259**:1951–7.
- Pezzini A, Del Zotto E, Gioffi A, Volonghi I, Grassi M, Padovani A. The migraine-ischemic stroke connection: potential pathogenic mechanisms. *Curr Mol Med* 2009;**9**:215–26.
- Lee YC, Yang AH, Soong BW. The remarkably variable expressivity of CADASIL: report of a minimally symptomatic man at an advanced age. *J Neurol* 2009;**256**:1026–7.
- Pescini F, Bianchi S, Salvadori E, Poggessi A, Dotti MT, Federico A, et al. A pathogenic mutation on exon 21 of the *NOTCH3* gene causing CADASIL in an octogenarian paucisymptomatic patient. *J Neurol Sci* 2008;**267**:170–3.