

Contents lists available at [ScienceDirect](http://www.sciencedirect.com)

International Journal of Surgery Case Reports

journal homepage: www.casereports.com

Concomitantly intra-articular fracture of proximal condylar second and third proximal phalanges: A rare case report

Baran Kömür^{a,*}, Olcay Güler^b, Serhat Mutlu^a, Barış Yılmaz^c, Bülent Yücel^a, Tahir Mutlu Duymuş^a^a Kanuni Sultan Süleyman Training and Research Hospital, Istanbul, Turkey^b Medipol Medical Faculty, Istanbul, Turkey^c Fatih Sultan Mehmet Training and Research Hospital, Istanbul, Turkey

ARTICLE INFO

Article history:

Received 2 March 2016

Received in revised form 6 May 2016

Accepted 7 May 2016

Available online 12 May 2016

Keywords:

Proximal phalange fracture
Condylar fracture of phalanx
Conservative treatment

ABSTRACT

INTRODUCTION: A rare case of proximal phalange fractures has been presented in this study.**PRESENTATION OF CASE:** A 29-year-old male patient from Turkey was admitted to the orthopedics and traumatology clinic with a complaint of left hand pain, which had persisted for 10 days. He described a rotational trauma that had occurred right after hitting his hand on the wheel of a car as a result of an in-car traffic accident 10 days ago. Radiological work-ups were requested. In the anteroposterior (AP) graph of the case in which the fracture line could not be observed in the oblique graph, unicondylar fractures in the proximal section of the second and third proximal phalanges have been observed. Surgical treatment was not planned because 10 days had passed since the trauma. In the control graphs taken after 3 weeks, healing at the fracture site was observed, and he was referred to physiotherapy after the removal of the splint. A good result was observed after physiotherapy.**DISCUSSION:** Because of the extension of tendons is important over the bone, the goal of the treatment is not only to heal the fracture, but also to preserve the sliding mechanism of these tendons. Regarding to lack of soft tissue trauma, favored joint movements after the healing of the fracture can be achieved more easily with conservative treatment; however, the fracture must be closely followed up.**CONCLUSION:** Condylar fractures of proximal phalanges those nondisplaced can be conservatively treated with closed methods.© 2016 The Author(s). Published by Elsevier Ltd on behalf of IJS Publishing Group Ltd. This is an open access article under the CC BY-NC-ND license (<http://creativecommons.org/licenses/by-nc-nd/4.0/>).

1. Introduction

Phalangeal fractures are the most common fractures of the hand. When they are not treated appropriately, they can cause limitation of movement ability. In total, 13% of hand fractures are proximal phalangeal fractures. They are commonly seen in males in the age group 20–29. Although the exact mechanism leading to the injury is unknown, it can be caused by the avulsion of collateral ligament or tilt and shear of the joint as a result of axial overload. In majority of such fractures, fixation is needed because of instability. Improper healing of fractures of this type can lead to deformities and arthroses. Treatment of proximal phalangeal fractures can sometimes be troublesome. As a result of soft tissue trauma that occurs during the surgical treatment can lead to lim-

itation of movement ability of joint due to adhesions [1]. On the other hand, reduction can be insufficient with conservative treatment. In hand fractures, the aim is to prevent joint stiffness, which is achieved with joint movement following the healing of the fracture with acceptable alignment. During the surgical treatment of condylar fractures of phalanges, methods such as k-wire, lag screws, and external fixation can be applied [2,3]. Among these methods, no significant difference has been detected in terms of stabilization [4].

In this report, we present a rare case that was not defined before to the best of our knowledge.

2. Presentation of case

A 29-year-old male patient from Turkey was admitted to the orthopedics and traumatology clinic with complaints of left hand pain, which had persisted for 10 days. In his history, he described a rotational trauma that had occurred right after hitting his hand on the wheel of a car as a result of an in-car traffic accident 10 days ago. In physical examination, pain, tenderness, and limitation of movement ability in the region where the proximal phalanges

* Corresponding author at: Kanuni Sultan Süleyman Training and Research Hospital, Turgut Ozal St. No. 1, Istanbul, Turkey.

E-mail addresses: barankomur@gmail.com (B. Kömür), olcayguler77@gmail.com (O. Güler), serhatmutlu@hotmail.com (S. Mutlu), drbyilmaz@yahoo.com (B. Yılmaz), dr2000tr@yahoo.com (B. Yücel), dr.tahirmutlu@gmail.com (T.M. Duymuş).

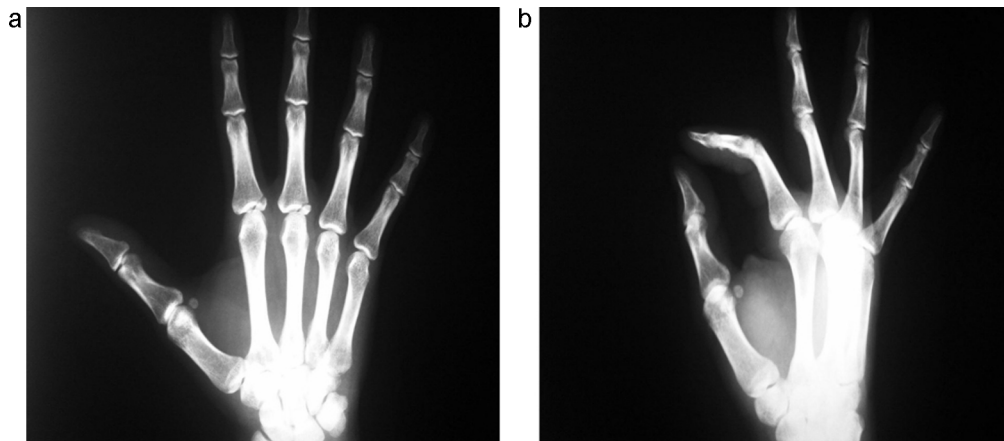


Fig. 1. a and b AP and oblique view of the fracture.

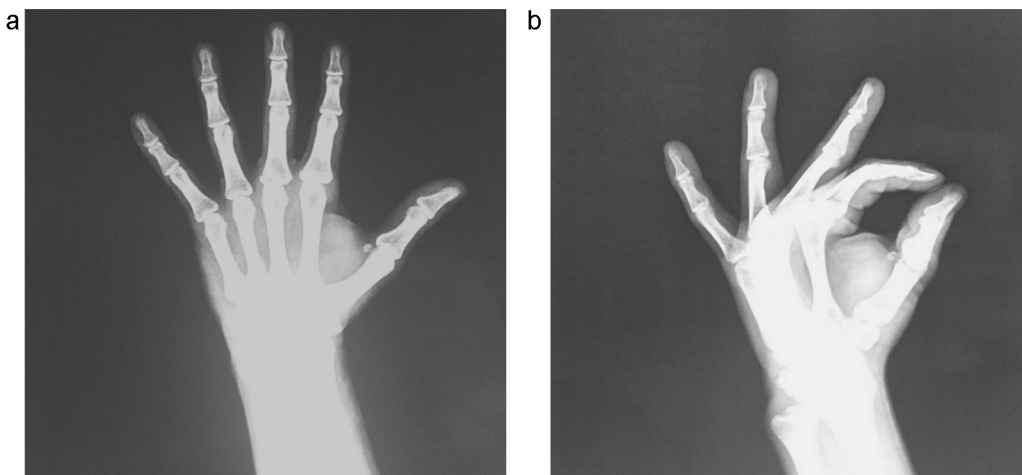


Fig. 2. a and b AP and oblique view of the fracture after conservative treatment.

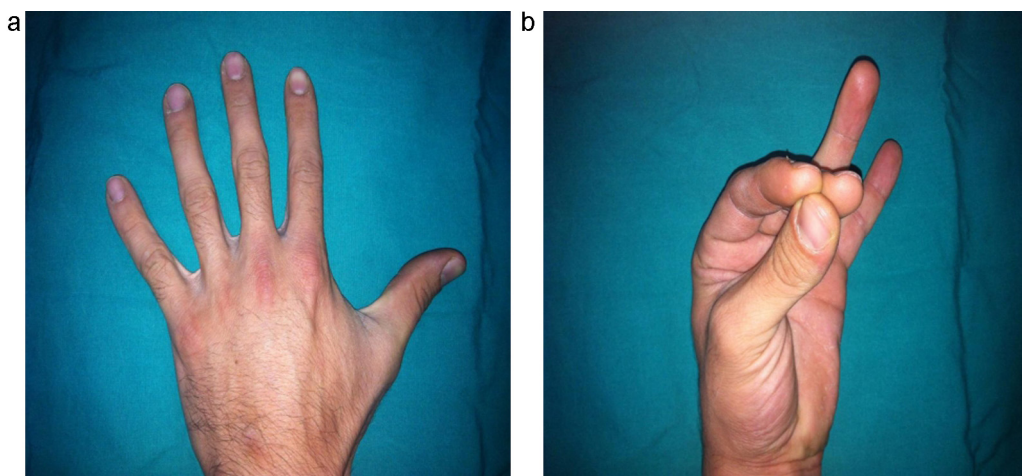


Fig. 3. a and b View of the injured hand while forming fist.

of the second and third fingers articulate with metacarpal bones have been reported. Flexor, extensor tendon and other soft tissue examination was normal. Radiological work-ups were requested. In the AP graph of the case in which the fracture line could not be observed in the oblique graph, unicondylar fractures were observed in the proximal section of the second and third proximal phalanges (Fig. 1a and b). Surgical treatment was not planned because 10 days

had passed since the trauma, because of the risk of adhesion and stiffness of the joint regarding to delayed surgery. After splinting, which included the fingertip, and placing the metacarpophalangeal joint at 70° and the interphalangeal joint at extension, weekly controls were scheduled. In the control graphs taken after 3 weeks, healing at the fracture site was observed, and he was referred to physiotherapy for 4 weeks after the removal of the splint. (Fig. 2a

and b). Following physiotherapy, it was observed that the power of clutching was almost complete, and he had no complaint other than mild pain while forming a fist (Fig. 3a and b).

3. Discussion

Condylar fractures of phalanges of hand are commonly encountered. Such injuries are commonly seen in younger patients [1]. The treatment is not easy in these type of fractures. Surgical treatment of these type of fractures are can be considered when the fragment is large and displaced from the joint. Because of the extension of tendons is important over the bone, the goal of the treatment is not only to heal the fracture, but also to preserve the sliding mechanism of these tendons [2]. When the fracture is appropriately reduced, fixation of the fracture can be achieved by splinting and stabilizing effect of the soft tissues. Open reduction and internal fixation is another option; however, it can lead to the impairment of the sliding mechanism of tendons over soft tissue. Surgical treatment should be commonly chosen in open fractures that are unstable, which are not easily-reduced and have with soft tissue trauma [3,5]. Because of the lack of soft tissue trauma, favored joint movements after the healing of the fracture can be achieved more easily with conservative treatment; however, the fracture must be closely followed up [6].

4. Conclusion

Condylar fractures of proximal phalanges, which are not displaced, can be conservatively treated with closed methods. This enables the healing of the fracture without the occurrence of additional soft tissue trauma. Surgical treatment can be chosen for displaced fractures and open fractures with soft tissue loss.

Conflict of interest

None.

Funding

None.

Ethical approval

Our study is a case report, thus we obtained consent form from the patient.

Consent

Written informed consent was obtained from the patient for publication of this case report and any accompanying images. A copy of the written consent is available for review by the Editor-in-Chief of this journal.

Authors contributions

BK writing, data collection, OG data analyze, SM editing, BY references, BY data processing, writing, TD data processing.

Guarantor

Baran Komur.

References

- [1] D.J. Shewring, A.C. Miller, A. Ghandour, Condylar fractures of the proximal and middle phalanges, *J. Hand Surg. Eur.* 40 (2015) 51–58.
- [2] S. Jehan, T. Chandraprakasam, S. Thambiraj, Management of proximal phalangeal fractures of the hand using finger nail traction and a digital splint: a prospective study of 43 cases, *Clin. Orthop. Surg.* 4 (2012) 156–162.
- [3] M.W. Fok, W.Y. Ip, B.K. Fung, R.K. Chan, S.P. Chow, Ten-year results using a dynamic treatment for proximal phalangeal fractures of the hands, *Orthopedics* 36 (2013) 348–352.
- [4] M.A. Sirota, B.G. Parks, J.P. Higgins, K.R. Means Jr., Stability of fixation of proximal phalanx unicondylar fractures of the hand: a biomechanical cadaver study, *J. Hand Surg. Am.* 38 (2013) 77–81.
- [5] D. Özçelik, G. Toplu, T. Ünveren, F. Kaçağan, C.G. Senyuva, Long-term objective results of proximal phalanx fracture treatment, *Ulus. Travma. Acil. Cerrahi. Derg.* 17 (2011) 253–260.
- [6] A.R. Koul, R.K. Patil, V. Philip, Traction splints: effective nonsurgical way of managing proximal phalanx fractures, *J. Trauma* 66 (2009) 1641–1646.

Open Access

This article is published Open Access at [sciencedirect.com](https://www.sciencedirect.com). It is distributed under the [IJSCR Supplemental terms and conditions](#), which permits unrestricted non commercial use, distribution, and reproduction in any medium, provided the original authors and source are credited.