

available at <http://www.tzuchimedjnl.com/>

Tzu Chi Medical Journal



## Case Report

# Perioperative Stroke Following General Surgery

Chia-Chun Huang<sup>1,2,3</sup>, Jimmy Ong<sup>1,2</sup>, Chia-Ling Lee<sup>1,2</sup>, Tsung-Ying Chen<sup>1,2,3\*</sup>

<sup>1</sup>Department of Anesthesiology, Buddhist Tzu Chi General Hospital, Hualien, Taiwan

<sup>2</sup>Department of Anesthesiology, Tzu Chi University, Hualien, Taiwan

<sup>3</sup>Graduate Institute of Clinical Medicine, Tzu Chi University, Hualien, Taiwan

### Article info

#### Article history:

Received: October 3, 2008

Revised: November 10, 2008

Accepted: December 10, 2008

#### Keywords:

General surgery

Ischemic

Perioperative stroke

Risk factors

### Abstract

Perioperative stroke is rare; however, patients undergoing cardiovascular surgery are considered to be at high risk for perioperative stroke. Here, we outline a case where perioperative stroke occurred following total hip replacement surgery. The risk factors and possible causes of the stroke in this patient are discussed. In addition, we reiterate the appropriate management approaches needed to prevent perioperative stroke. Briefly, the importance of precise preoperative evaluation and of proper intraoperative and postoperative management should not be overlooked. Finally, it is important to realize that decreasing perioperative strokes and the disabilities associated with them will lower the financial burden on families and the community. (*Tzu Chi Med J* 2009;21(4):345–347)

\*Corresponding author. Department of Anesthesiology, Buddhist Tzu Chi General Hospital, 707, Section 3, Chung-Yang Road, Hualien, Taiwan.  
E-mail address: [chenyting@mail.tcu.edu.tw](mailto:chenyting@mail.tcu.edu.tw)

## 1. Introduction

The reported incidence levels of perioperative stroke following general surgery indicate that it is rare (1). No matter what the consequence, a perioperative stroke does impose a heavy financial burden on the family and the community. Therefore, this problem deserves to be paid more vigorous attention by the medical community. Here, we report a case of perioperative stroke following total hip replacement surgery and discuss the possible etiologies and available preventive strategies.

## 2. Case report

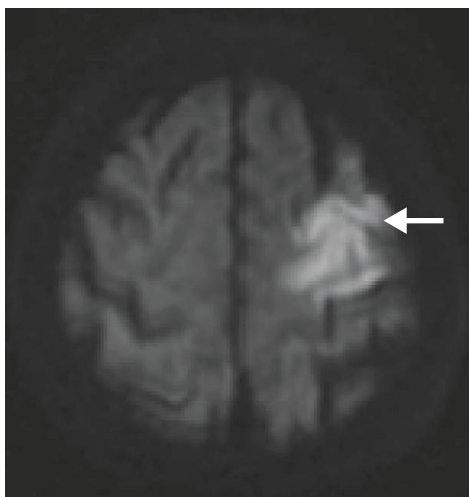
A 72-year-old female was admitted to our hospital to receive total hip replacement for right hip osteoarthritis. The operation was proposed as suitable in view

of the patient's stable vital signs and neurological condition. She was 144 cm in height and weighed 52 kg. Preoperative anesthetic assessment showed that she had a past history of diabetes mellitus and hypertension, both of which had been under medical control for a number of years. In addition, she had received stenting to her left circumflex coronary artery about 5 years previously. A complete electrocardiography examination and chest X-ray were normal and her laboratory data, including hemogram and coagulation time, were also within the normal ranges.

General anesthesia combined with epidural analgesia was planned for the operation. Anesthesia was induced with thiamylal 5.7 mg/kg and fentanyl 1 µg/kg, after which a 3<sup>#</sup> size laryngeal mask airway was inserted. The patient breathed spontaneously during the operation period. Next, an epidural catheter was placed 6 cm cephalad via the L2–3 interspace. Anesthesia was maintained with sevoflurane 2–3% in

100% oxygen at a flow rate of 1 L/min oxygen. In addition, an epidural bolus consisting of 5 mL 1% xylocaine was introduced every 30 minutes. Standard intraoperative monitoring was in place, including electrocardiography, nasal temperature, a noninvasive blood pressure monitoring system, end-tidal CO<sub>2</sub>, and pulse oximetry. During the 2.5 hours of the operation, her systolic blood pressure was maintained at 140–180 mmHg, and her diastolic blood pressure at 90–110 mmHg, except for two episodes of hypotension (80–85/50–55 mmHg), which persisted for less than 3 minutes and which were promptly corrected by intravenously administered ephedrine (8 mg each time). There was no significant blood loss. The patient recovered smoothly from the anesthesia after the operation and her consciousness and activity remained normal in the postanesthesia recovery room.

Seven hours after being transferred to the ward, the patient developed a sudden onset change in consciousness. Immediate physical examination at the bedside found that the patient's eyes showed deviation to the right and that right facial palsy was present. There was also muscle weakness in the right upper and lower extremities. Babinski sign was positive on the right side but her pupil reflex was intact. The patient's vital signs were relatively stable. Nonetheless, her Glasgow coma scale score was determined to be just E2V1M5. Laboratory analysis showed no abnormal findings, except for a mild decrease in hemoglobin level (11.2 g/dL postoperatively compared to 13.8 g/dL preoperatively). A neurologist on consultation indicated a suspected left brain infarction. Brain magnetic resonance imaging later confirmed a diagnosis of acute ischemic infarction of the left frontal lobe (Fig. 1). Heparin infusion was initiated and



**Fig. 1** — Magnetic resonance imaging (diffusion-weighted imaging) of the left frontal infarction (arrow) that had developed in front of the left central sulcus.

warfarin was given. Carotid Doppler was performed on the second day and this showed atherosclerosis of bilateral common carotid arteries, especially on the left side where there was nearly total occlusion. Cardiac echocardiography revealed preserved left ventricular function and no patent foramen ovale. Though the postoperative course after stroke was complicated by a urinary tract infection, this was resolved after a course of antibiotics. Fortunately, the patient underwent gradual recovery and started a rehabilitation program 1 week after the stroke for the sequelae of right hemiparesis, impaired cognition and global aphasia. She was able to perform her daily activities with moderate assistance at the time of discharge.

### 3. Discussion

Perioperative stroke is defined as an episode of focal or global loss of cerebral function with symptoms lasting more than 24 hours or leading to death that occurs intraoperatively or in the postoperative period (2). The postoperative period is not clearly defined, but a duration of 3–30 days is usually considered acceptable. The incidence of perioperative stroke varies with the type and complexity of the surgical procedure (3). However, the reported risk of perioperative stroke associated with general surgery is low and has been reported to range from 0.08% to 0.7% (1). Although perioperative stroke is considered rare, it does have a significant financial impact on the family and the community.

Many risk factors for perioperative stroke have been identified. In a matched case-control study of 61 patients who developed ischemic stroke after various general surgical procedures, Limburg et al found three major factors to be significantly associated with perioperative stroke: previous cerebrovascular disease, chronic obstructive pulmonary disease, and peripheral vascular disease (4). Other identified factors that increase the risk of perioperative stroke in patients undergoing general surgery include age, hypertension, atherosclerosis, smoking, previously existing neurological symptoms, diabetes mellitus, and cardiac arrhythmia (1,5,6). Our patient presented with a history of diabetes mellitus, hypertension, and coronary artery disease, all of which are included in the above previously identified risk factors.

Although the exact mechanism of perioperative stroke remains uncertain, the major sources of perioperative stroke are considered to be either ischemic or embolic (2,3). In this context, this may provide a basis for the event in our patient; specifically, postoperative carotid Doppler ultrasonography showed that there was severe stenosis in the left common carotid artery. Thus, it is possible that manipulation

of the patient's neck during or after surgery led to atheroma dislodgement and this became a source of emboli. Despite the fact that fat emboli from orthopedic procedures may have provided another source for emboli (7), the patient's presentation did not meet the criteria for this (8). In addition, the postoperative cardiac echocardiography failed to identify the presence of a patent foramen ovale. Hence, in this case, the possibility of fat embolism syndrome is lower. Although it has been reported that hypoperfusion itself is generally not a major cause of perioperative stroke (3,4), we are unable to exclude the possibility that the two episodes of intraoperative hypotension might be the main cause of this tragedy. Even though the duration of each hypotensive episode was short, they might have drastically affected the supply of oxygen to the fragile brain in a patient with a history of hypertension and carotid artery stenosis. In addition, the trauma of surgery, the presence of associated tissue injury, the general anesthesia, patient dehydration, together with the fact that the patient underwent bed rest, and thus did not move a great deal, all might render the patient subject to hypercoagulability. We believe that multiple factors contributed to the perioperative stroke in our patient, among which the hypotensive episodes and/or atheroma dislodgement may have contributed the most.

Several studies have suggested preoperative, intraoperative, and postoperative preventive measures in order to prevent a minor reversible neurological deficit from becoming a major irreversible disability (1,2). First of all, it is important that the patient should have received a proper and thorough preoperative evaluation (9). History taking should include the above-mentioned significant risk factors for perioperative stroke as well as any transient ischemic attack-like symptoms in the past. If there have been any symptoms that are suggestive of transient ischemic attack, carotid Doppler should be performed. Furthermore, any preoperative coexisting medical conditions should be optimized and it is suggested that elective surgery be postponed for 4–6 weeks after a moderately large ischemic stroke (7). In the case of any exacerbated

neurological damage, the patient's blood glucose level should be checked and maintained (1). Finally, in the postoperative period, it is recommended that hypotension and dehydration be avoided in order to lessen the possibility of surgical factors inducing a change in the hypercoagulation status.

In conclusion, we report a patient who developed a stroke 7 hours after surgery and anesthesia. This patient had a history of diabetes mellitus, hypertension, and coronary artery disease. We reiterate the importance of a full preoperative evaluation in order to allow the identification of any possible risk factors for a perioperative stroke. At the same time, it is important that hemodynamic stability is maintained during the perioperative period. We believe that detailed evaluation and careful management during and after surgery will result in perioperative strokes being successfully kept to a minimum.

## References

1. Kam PC, Calcroft RM. Peri-operative stroke in general surgical patients. *Anaesthesia* 1997;52:879–83.
2. Menon U, Kenner M, Kelley RE. Perioperative stroke. *Expert Rev Neurother* 2007;7:1003–11.
3. Selim M. Perioperative stroke. *N Engl J Med* 2007;356:706–13.
4. Limburg M, Wijdicks EF, Li H. Ischemic stroke after surgical procedures: clinical features, neuroimaging, and risk factors. *Neurology* 1998;50:895–901.
5. Parikh S, Cohen JR. Perioperative stroke after general surgical procedures. *N Y State J Med* 1993;93:162–5.
6. Wong DH. Perioperative stroke. Part I: General surgery, carotid artery disease, and carotid endarterectomy. *Can J Anaesth* 1991;38:347–73.
7. Blacker DJ, Flemming KD, Link MJ, Brown RD Jr. The preoperative cerebrovascular consultation: common cerebrovascular questions before general or cardiac surgery. *Mayo Clin Proc* 2004;79:223–9.
8. Kuo CP, Lu CC, Chueng CM, et al. Post-operative stroke after dynamic hip screw fixation in a patient with old cerebral infarction and atrial fibrillation. *Acta Anaesthesiol Taiwan* 2004;42:223–6.
9. Kelley RE. Stroke in the postoperative period. *Med Clin North Am* 2001;85:1263–76.