EFFECTS OF THE RESIN OF EUPHORBIUM ON VERRUCAE PLANTARES—HUMAN AND ANIMAL EXPERIMENTATION*

RAYMOND W. GOLDBLUM, M.D. AND ARTHUR C. CURTIS, M.D.

Euphorbium has been used by housewives to eradicate verrucae for many years. The use of Euphorbia resinifera in the treatment of verrucae was suggested by Michon (1) and Hissard (2). It is known to the layman as "wart weed," which name is used loosely to refer to a variety of plants, including the greater Celandine (Chelidonum majus) and the Sun Spurge (Euphorbia helioscopia). Lyell (3) said that "countrymen continue to use such plant juices not only because countrymen are conservative, but because they have rid themselves of warts by these means."

In general, dermatologists will agree that the treatment of verrucae plantares are the most difficult verrucae to treat. Radiation therapy of verrucae plantares is successful in approximately 70% of the cases. This means that 30% of the unsuccessful cases treated by radiation therapy, will be treated locally. The need for good local therapy in the treatment of verrucae plantares, stimulated the investigation of the use of Euphorbium in its treatment.

Euphorbia resinifera (47) is partially soluble in alcohol, ether, petroleum ether and water, and is almost completely soluble in glacial acetic acid. The constituents are 1) Euphorbone (40 per cent) which crystallizes from acetone in colorless, tasteless, acicular crystals; 2) Euphorboresene (20 per cent) a yellowish brown, amorphus and tasteless substance; 3) an acrid tasting substance (10 per cent) to which the physiological action of the drug is ascribed and which has only been isolated in impure form as an amorphous mass; 4) calcium molate (25 per cent); 5) vegetable debris and 6) ash (5 per cent). Its uses were as a vesicant and as a cathartic in veterinary medicine.

METHODS

The verrucae were pared with a scalpel so that most of the hyperkeratotic material was removed. A 30% solution of Euphorbium in 95% alcohol was applied to the central keratotic area of the verruca. This area was covered with adhesive tape to keep the Euphorbium from spreading on to normal tissue. The tape was left in position for 48 hours, and the patients were told not to bathe the feet during the period of application of the agent. After the 48 hour application, the verruca was again pared with a scalpel, and the Euphorbium reapplied. The area was again covered with adhesive tape. After 48 hours, the central keratotic area was pared again. Uusally, the verruca could be entirely removed after 96 hours of treatment. A few patients were treated for 144 hours

* From the Department of Dermatology and Syphilology, University of Michigan Hospital, Ann Arbor, Michigan.

Read before the Thirteenth Annual Meeting of the Society for Investigative Dermatology Inc., Chicago, Illinois, June 8, 1952.

—(three applications). The treated verrucae were observed for four months after treatment.

RESULTS

Sixty patients with verrucae plantares were treated with Euphorbia resinifera. The patients ranged in age from 7 to 78 years. Some patients had 1 and others 2 to 7 verrucae plantares. The verrucae ranged in size from 1 to 3 centimeters in diameter. Half of the verrucae had been previously treated with adequate doses of superficial x-ray radiation, and the other half had been treated with other commonly used medications.

In the sixty patients in whom the 30% Euphorbia resin was applied to the verrucae plantares, the central keratotic area of the verrucae were completely removed in 96 hours. The verruca was considered to be adequately treated when the base of the lesion was erythematous and oozing serum. Of the sixty patients treated with the Euphorbia solution, only two of the verrucae plantares returned over a four month observation period, and both two treatment failures were in patients with mosaic verrucae plantares. These verrucae were approximately 3 cm. in diameter and regrowth of the verrucae occurred two weeks after their apparent removal.

HUMAN AND ANIMAL EXPERIMENTATION

Euphorbium (30% in 95% alcohol) was applied to the scapular area of one patient with normal skin. Twenty-four and forty-eight hour punch biopsies were obtained. The histopathology of the human skin revealed hyperkeratosis and parakeratosis of the stratum corneum. The rete mucosum was acanthotic. There was intercellular and intracellular edema of the rete mucosum. In the corium, a moderate amount of edema of the collagen and a moderate perivascular infiltrate of the lymphocytes and polymorphonuclear leukocytes was observed. The 24 hour biopsies of human skin revealed the same changes but these changes were less marked. There was no evidence of dyskeratosis or increase in the number of mitotic figures in the rete mucosum.

The back of a guinea pig was shaved. A 30% Euphorbium solution in 95% alcohol and a 30% podophyllin solution in 95% alcohol are applied to the shaved guinea pig skin. Twenty-four and forty-eight hour punch biopsies were obtained (Figs. 1 and 2).

The histopathology of the guinea pig skin which was treated with the Euphorbium solution for 48 hours revealed hyperkeratosis and parakeratosis of the epidermis. There was moderately severe acanthosis, intercellular and intracellular edema of the rete mucosum. There was moderate edema of the collagen and a mild perivascular infiltrate of lymphocytes and polymorphonuclear leukocytes. The 24 hour biopsies of the guinea pig's skin treated with the Euphorbium solution revealed essentially the same changes but to a more moderate degree. The guinea pig skin, which was treated with a 30% alcoholic solution of podophyllin revealed the same changes as the 48 hour skin biopsies treated with a 30% alcoholic solution of Euphorbium.

FIG. 1. 48 hr. biopsy of guinea pig's skin treated with a 30% alcoholic solution of euphorbium.

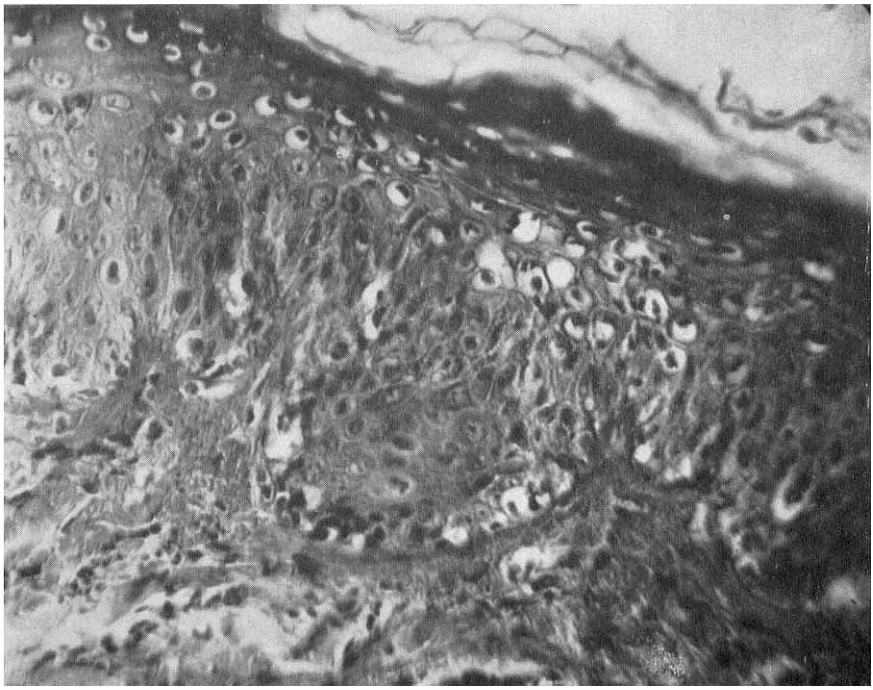

FIG. 2. 48 hr. biopsy of skin from scapular area of human treated with a 30% alcoholic solution of euphorbium.

DISCUSSION

The Arabs collect Euphorbia resinifera from shrubs grown in the mountainous sections of Morocco by cutting incisions deep into the branches of the plants during the rainy season when the flow of the latex is abundant. The white, sticky milk juice which is contained within long, branching, latex cells within the cortex and pith, exudes to the surface of the incision. The part of the plant that is used is the dried resinous latex. Its uses were as a vesicant in veterinary medicine and as a drastic cathartic.

The 30% alcoholic solution of Euphorbia resinifera was very effective in the treatment of verrucae plantares. The treatment was relatively painless and required two to three applications which is a distinct advantage over other local treatments, which require long periods of application.

Euphorbia is a proteolytic agent. Its action on verrucae seems to be due to its lysing action on the cells of the rete mucosum. It also is capable of lysing the collagen of the dermis.

The patients complained of a slight burning sensation, which lasted approximately two hours at the site of application. There were no patients who developed any reaction on the skin except on the immediate site of application.

Sullivan and King (5) patch tested the prepuces of six patients with a 25% resin of podophyllum in liquid petrolatum. Twenty-four and forty-eight hour biopsies were obtained. In the prickle cell layer, the intercellular bridges had disappeared and the cell membranes were thickened and hyalinized. A prominent feature was the presence of enlarged cells with distintegration of their chromatin content. The chromatin may be dispersed in the form of numerous small granules scattered through the spongy cytoplasm suggesting an aborted mitoses, or the nuclear material may be clumped, pyknotic and distorted. Such cells were designated as "podophyllin cells." The dermis revealed only slight edema and a sparse scattering of lymphocytes. Except for the "podophyllin cells" the biopsies of human skin after a 48 hour patch test with 30% Euphorbia solution were essentially the same.

CONCLUSIONS

1) Sixty patients with verrucae plantares were treated with a 30% alcoholic solution of Euphorbia resinifera with complete disappearance of the verrucae in all but two patients, after an observation period of four months.

2) Euphorbium will produce lysis of the cells of the rete mucosum of human and guinea pig skin.

3) It is another hopeful drug added to our existing long list of agents used in the treatment of verrucae.

BIBLIOGRAPHY

1. Michon, M. P.: Herbes and verrues, Bull. Soc. Franc. Derm. Syph. 34, 36, 1927.
2. Hissard, M. P.: Les herbes aux verrues, Bull. Soc. Franc. Derm. Syph. 34, 695, 1927.
3. Lyell, A.: Treatment of Warts; Brit. Med. Jour., Sept. 23, 1950, p. 729.

4. YOUNGHEN, H. W.: Textbook of Pharmacognosy, P. Blakiston's Son and Company, Inc., Phila. Penn.
5. SULLIVAN, M. AND KING, L. S.: Effects of Resin of Podophyllum on Normal Skin, Condylomata Acuminata and Verrucae Vulgaris, Arch. Dermat. & Syph., **56:** 30, 1947.

DISCUSSION

DR. S. J. ZAKON, *Chicago, Ill.:* There are a number of plants that are called Euphorbia and some of their common names are: Large Flowering Spurge, Blooming Spurge, Milk Purslane, Snake Milk, Garden Spurge, Large Spotted Spurge, Cat's Hair, Asthma Weed, etc. Apparently they all contain an active resin which is an irritant to the mucous membranes and, hence, Euphorbia was formerly used as an emetic, laxative or cathartic depending on the dosage.

Chelidonium majus—Linne—known as Celandine or Tetter Wort has been used by medical men and laymen to destroy verrucous growths.

During the period of pioneer medicine in the Middle West when the pioneers used to be warned, "Don't go to Michigan, that land of ills; The word means ague, fever and chills" much of the medical treatments were domestic and primitive, a combination of homemade science, empiricism, and superstition. The Indian influences were strong and great reliance was placed upon the curative properties of plants and roots. A famous botanic Doctor used to advertise like this: "My medicines though made of herbs, doth wondrous cures perform, and yet each one may practice it without producing harm."

It is only in recent years that some of these plant resins like Podophyllum and Euphorbia have been subjected to scientific study. I congratulate Dr. Goldblum for this excellent presentation.

DR. BERNARD R. NEBEL, *Geneva, N.Y.:* About a year ago a biochemist from Dr. McKay's Laboratory at Cornell University, Ithaca, New York, made for me an enzymatic extract of milkweed. This was tested and found positive for its enzyme activity and we used it on verrucae with good success. I mention this because I feel that in the plant juices we have two basic principles combined which are worth separating. One is the enzymatic property and the other is probably an alkaloid which interferes with mitoses. Both factors should be isolated and then tested separately and in combination.

DR. HARVEY BLANK, *New York, N. Y.:* This is an interesting demonstration of a new potent cytoxic agent. In clinical trial, however, other similar drugs have not been too successful when applied to dry verrucae. It is particularly important, therefore, to establish the clinical effectiveness of a new agent beyond any reasonable doubt. It is essential in reporting clinical results in this disease to have control treated material, either treating one of two warts on the same foot, or alternate patients with a placebo solution, because we know that many types of inert therapy will cure some patients. Of course, 58 out of 60 cures is impressive, but it would be better if the authors could report on a similar number of control-treated lesions for comparison.

DR. RAYMOND W. GOLDBLUM, *Ann Arbor, Mich.:* I wish to thank the discussers. As for mitoses, we were looking for them but on repeated search we did not find any cells that had mitotic figures. We have used other drugs in the treatment of this condition. We are looking for a drug which will penetrate the cell membrane and interfere with the enzymatic process in the cells affected by the virus, if verrucae are due to viruses. One drug was methionine sulfoxamine which in vitro was very successful in interfering with oxidation in some of the cells but clinically it had no effect.