



## Aggressive angiomyxoma presenting with back and perineal bulge; a complex surgical approach: A case report



Walid Faraj<sup>a,\*</sup>, Mohamad Houjeij<sup>b</sup>, Ali Haydar<sup>c</sup>, Hussein Nassar<sup>d</sup>, Ghina Nounou<sup>b</sup>, Mohamad Khalife<sup>a</sup>

<sup>a</sup> Liver Transplantation and Hepatopancreaticobiliary Surgery, Department of General Surgery, American University of Beirut Medical Center, P.O. Box 11-0236, Beirut, Lebanon

<sup>b</sup> Department of General Surgery, American University of Beirut Medical Center, P.O. Box 11-0236, Beirut, Lebanon

<sup>c</sup> Department of Radiology, American University of Beirut Medical Center, P.O. Box 11-0236, Beirut, Lebanon

<sup>d</sup> Faculty of Medicine, American University of Beirut Medical Center, P.O. Box 11-0236, Beirut, Lebanon

### ARTICLE INFO

#### Article history:

Received 4 February 2016

Received in revised form 25 May 2016

Accepted 25 May 2016

Available online 28 May 2016

#### Keywords:

Angiomyxoma

Peritoneum

Complex surgery

Case report

### ABSTRACT

**INTRODUCTION:** Aggressive angiomyxoma is a rare mesenchymal tumor occurring predominantly in the pelvi-perineal region. It is more common in females during their reproductive age. Our focus is on the surgical approach for a recurrent angiomyxoma.

**CASE PRESENTATION:** We present a case of a 36-year-old female patient with a recurrent lower back and perineal bulges. One year ago, she had the same presentation and underwent resection of that mass in a peripheral hospital without available information. Five months later, she started to have the same bulge. Computed tomography scan and true cut biopsy were suggestive of angiomyxoma with single lung metastasis. The decision was to proceed with resection through a transabdominal and perineal incision, even in the presence of metastasis since it's a very slow growing tumor with long life expectancy. The pathology was consistent with aggressive angiomyxoma.

**DISCUSSION:** 90% of patients with angiomyxoma are women. Although it is benign, the tumor is still aggressive because of the high rate of local recurrence after resection. Angiomyxoma is a mesenchymal tumor, composed of fibroblasts within a myxoid background. Treatment is usually through wide local excision to achieve an R0 resection. Our approach was through a transabdominal and perineal incision, which allowed full control and mobilization of the tumor without disrupting the capsule. This surgical approach was not described previously in the literature.

**CONCLUSION:** The principle to achieve cure in aggressive angiomyxoma is by optimizing exposure through two different incisions, wide excision while keeping the capsule intact and removing enbloc any invaded organ.

© 2016 The Authors. Published by Elsevier Ltd on behalf of IJS Publishing Group Ltd. This is an open access article under the CC BY-NC-ND license (<http://creativecommons.org/licenses/by-nc-nd/4.0/>).

## 1. Introduction

Angiomyxoma is an uncommon mesenchymal neoplasm occurring predominantly in the pelvi-perineal region of adults [1,2]. The majority of patients are female in the productive age group [3]. Although it is benign, the tumor is considered an aggressive tumor secondary to its high rate of local recurrence. Most of the cases will recur in 2 years post resection. Complete resection with an attempt of a resection margin (R0) should be the aim of the surgery to decrease the rate of recurrence. Our patient is a 36 year old female patient who presented with a recurrent lower back bulge along

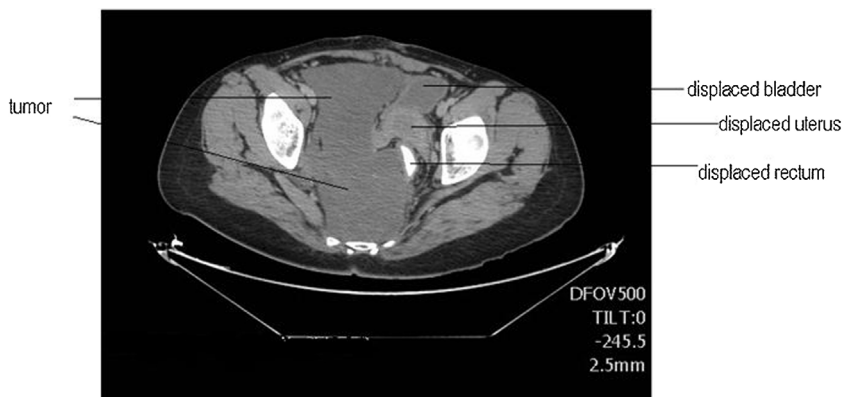
with perineal bulge. Surgery was performed successfully with an abdomino-perineal approach.

## 2. Materials and methods

A 36 year old female patient presented to our institution with a recurrent lower back bulge along with perineal bulge. One year ago, she had the same presentation and she underwent surgery and resection of that mass in a peripheral hospital. There was no available information regarding the pathology of neither that mass nor the surgical details. Five month later she started to have same bulge associated with pelvic heaviness and urinary urgency. Physical examination revealed a non-tender diffuse firm and dull mass over lower back more on the right extending to right perineal area. Computed tomography scan of chest, abdomen and pelvis revealed a 20 cm right pelvic mass extending to right ischiorectal fossa and inferior aspect of right perineum with no definite invasion to rec-

\* Corresponding author.

E-mail address: [wf07@aub.edu.lb](mailto:wf07@aub.edu.lb) (W. Faraj).

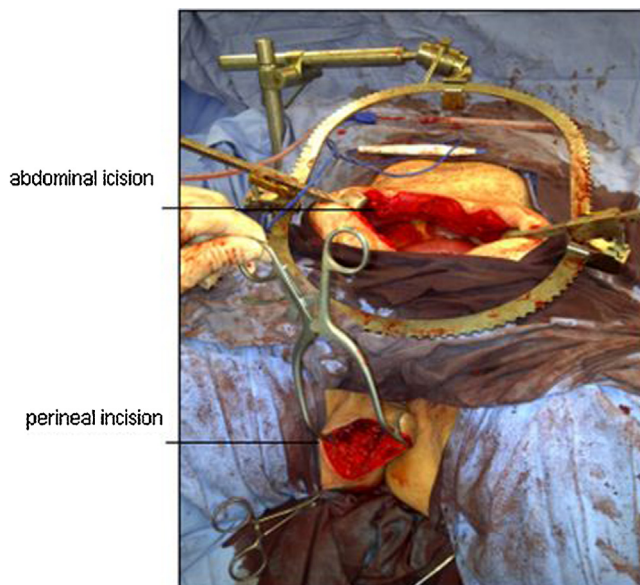


**Fig. 1.** CT scan of the abdomen and pelvis: a figure of a CT scan demonstrating the extension of the angiomyxoma down to the pelvis.

tum; uterus or bladder (Fig. 1). Chest scan revealed a single lung metastasis. True cut biopsy revealed angiomyxoma, so decision was to proceed with resection even in the presence of lung metastasis taking into consideration that since it is a very slow growing tumor with long life expectancy. That decision was backed up by several cases reported in the literature where resection was performed in the presence of metastases [4].

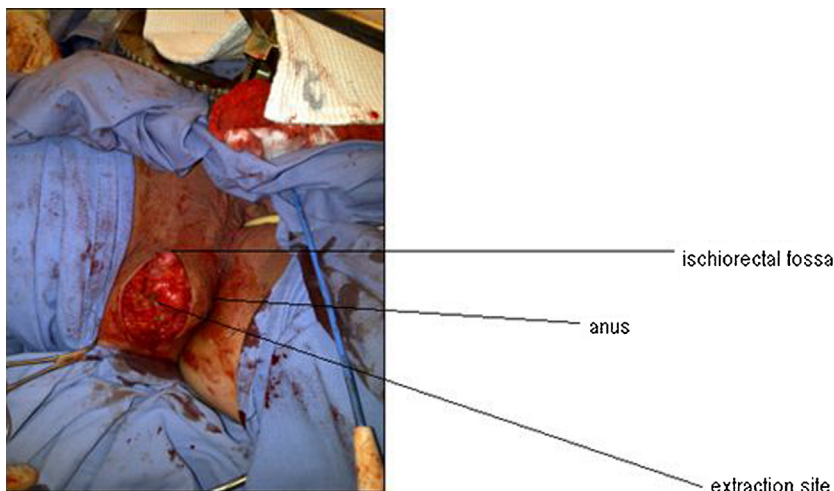
The aim of our surgery was to achieve an R0 resection, the surgical approach was through a transabdominal and perineal incision (Fig. 2). These two incisions will allow a full control and mobilization of the tumor without disrupting the capsule if present. This surgical approach was not described previously in the literature.

The transabdominal incision was used to get access to the tumor anteriorly and to dissect it away from the rectum, bladder, uterus and the ureters. The tumor was not found to be invading those structures. After full dissection in the pelvis and mobilization of the tumor, the perineum attachment of the tumor was not accessible through this incision. So another incision was made in the perineal triangle posteriorly to avoid damaging the urethra that is present in the anterior triangle. The incision was made lateral to anus in the ischio-rectal fossa and lateral to the anal sphincter muscles to avoid incontinence (Fig. 3). The dissection was carried medially and away from the ischial tuberosity to keep the dissection medial to sacrotuberous ligament and to avoid damaging the structures that emerge lateral and under this ligament (pudendal bundle and sciatic nerve). After the dissection in the ischio-rectal fossa was completed, the pelvic floor muscles were split and exposure of the tumor was achieved. The tumor was not found to be invading the

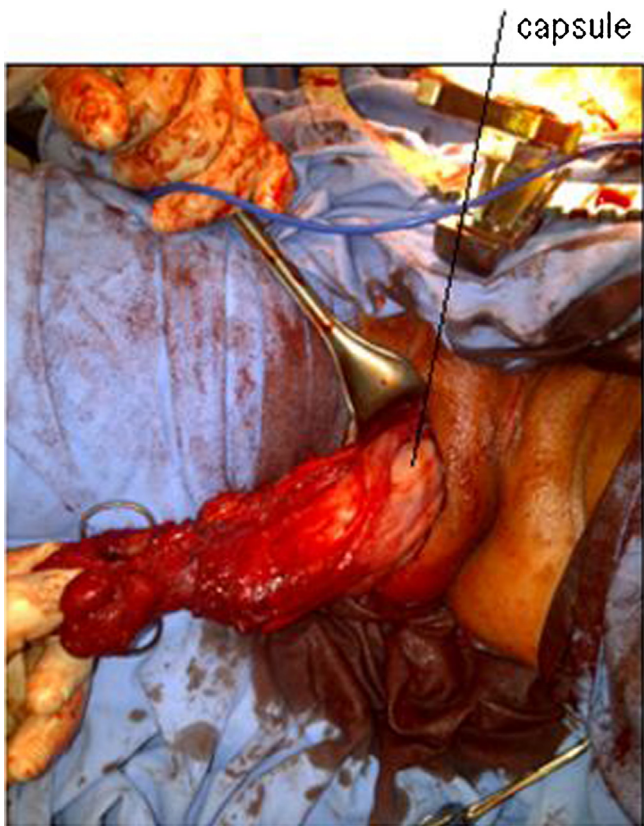


**Fig. 2.** Abdominal and perineal approach: a figure demonstrating both the abdominal and perineal incisions performed.

pelvic floor muscles so it was resected and was fully mobilized and was extracted from the perineal incision (Fig. 4). Since the tumor was intact seeding at the extraction site was not a concern. Most of



**Fig. 3.** Perineal incision and approach: a figure demonstrating the perineal incision performed.



**Fig. 4.** Delivery of the specimen through the perineum: a figure demonstrating the delivery of the tumor resected through the perineal incision.

recurrent cases and tumor seeding were secondary to incomplete resection [1].

### 3. Results

Pathology revealed spindled and stellate bland cells in a fibro-collagenous and markedly myxoid stroma, immunostains show that tumor cells express desmin and smooth muscle actin and are negative for S100. This pattern is consistent with aggressive angiomyxoma.

### 4. Discussion

Aggressive angiomyxoma is an uncommon mesenchymal neoplasm occurring predominantly in the pelvi-perineal region of adults, first described in 1983 by Steeper and Rosai [2]. About 90% of patients are women, usually in the reproductive age [3]. A few cases have been described in males, usually in scrotum. On gross examination the tumors are lobulated, soft to rubbery, solid masses. The gelatinous appearance, greyish discoloration on cross section and the large size of the tumor are common features of AAMs. Although it is benign, the tumor is still called aggressive because of the high rate of local recurrence after resection. Approximately 70% of the cases locally recurred after a period of 2 years. Recurrent tumors show more prominent areas of hemorrhage and fibrosis. Histologically angiomyxoma is a mesenchymal tumor, composed of fibroblasts within a strong myxoid background. Vascular proliferation is also prominent, and virtually no mitoses are present. The vast majority of cases demonstrate positivity for desmin in the myxoid bundles and/or stromal cells, while actins and CD34 may be variably positive. The documented studies for immunohistochemical data in two series showed nearly 97% positive response to desmin,

94% for smooth muscle actin, 93 and 90% for oestrogen and progesterone receptors, respectively, but 0% for S100 protein. The tumor grows slowly, and its benign nature is suggested by the histology and by the fact that it shows no tendency to metastasize. However, it is locally aggressive and tends to recur (36–72%) after resection [5].

Any attempt to fully resect the tumor and to decrease rate of recurrence to achieve cure, should follow the three main principles; first is to use the two incision strategy to fully expose the tumor (transabdominal and perineal incision), second is to keep the capsule intact, third is to remove en bloc any invaded organ. The surgical approach used in our case allow the surgeon to fully expose and mobilize the tumor since it is not limited to abdomen but extend to the pelvis and down to the perineal area. The perineal approach will allow proper dissection of the tumor from its attachment to the pelvic floor. This approach should be performed in multidisciplinary fashion especially when the surgeon is planning for excessive dissection in the perineum where urologist and gynecologists should be on board because urinary incontinence, ureteral, bladder and vaginal injury can occur. the main concern of this approach as mentioned earlier is iatrogenic injury to anal sphincters and pudendal bundle but this can be avoided by keeping the dissection directly lateral to the sphincters and identify them and also by staying medial and away as possible from the ischial tuberosity in the posterior triangle. Aggressive angiomyxoma must be distinguished from other mesenchymal tumors of the genital area which are the angiomyofibroblastoma and the cellular angiofibroma which are well circumscribed and usually do not recur.

On CT scan, the tumor has a well-defined margin and attenuation less than that of muscle. Coronal T2-weighted MR imaging displays a large tumor with high signal intensity interspersed with swirled or layered strands of lower signal intensity. Treatment is usually surgery in form of wide local excision to achieve an R0 resection.

### 5. Conclusion

Although a rare disease, aggressive angiomyxoma can have unusual presentation. Detailed radiological and physical examinations are helpful in suspecting the disease, but histology is gold standard for diagnosis. The principle to achieve cure is based on three main points; first is optimal exposure through two different incisions, second is Wide excision keeping the capsule intact, third is removing en bloc any invaded organ. Follow-up with alternate MRI and sonographic examination at 1–2 yearly intervals should suffice.

### Conflicts of interest

The authors declare no conflict of interest.

### Funding

The authors declare that the research did not receive any funding.

### Ethical approval

This is a case report involving one patient and thus does not require IRB approval.

**Consent**

Written informed consent was obtained from the patient for publication of this case report and accompanying images. A copy of the written consent is available for review by the Editor-in-Chief of this journal on request.

**Author contribution**

Walid Faraj: study design and writing the paper.  
Mohamad Houjeij: contributor.  
Ali Haydar: data analysis.  
Hussein Nassar: data collection.  
Ghina El Nounou: data collection.  
Mohamed Khalifeh: study concept.

**Guarantor**

Dr. Walid Faraj.

**Acknowledgment**

The work has been reported in line with the CARE criteria [6].

**References**

- [1] S.R. Granter, M.R. Nucci, C.D. Fletcher, Aggressive angiomyxoma: reappraisal of its relationship to angiofibrosarcoma in a series of 16 cases, *Histopathology* 30 (1) (1997) 3–10.
- [2] T.A. Steeper, J. Rosai, Aggressive angiomyxoma of the pelvis and perineum: report of nine cases of a distinctive type of gynaecologic soft tissue neoplasm, *Am. J. Surg. Pathol.* 7 (5) (1983) 463–475.
- [3] A. Wiser, J. Korach, W.H. Gottlieb, et al., Importance of accurate preoperative diagnosis in the management of aggressive angiomyxoma: report of three cases and review of the literature, *Abdom. Imaging* 31 (3) (2006) 383–386.
- [4] R.M. Siassi, et al., Metastasizing aggressive angiomyxoma, *New Engl. J. Med.* 341 (23) (1999) 1772.
- [5] S. Blandamura, J. Cruz, L. Faure Vergara, et al., Aggressive angiomyxoma: a second case of metastasis with patient's death, *Hum. Pathol.* 34 (10) (2003) 1072–1074.
- [6] J. Gagnier, G. Kienle, D.G. Altman, D. Moher, H. Sox, D.S. Riley, CARE group, The CARE guidelines: consensus-based clinical case report guideline development, *J. Clin. Epidemiol.* 67 (1) (2013) 46–51.

**Open Access**

This article is published Open Access at [sciencedirect.com](http://sciencedirect.com). It is distributed under the [IJSCR Supplemental terms and conditions](#), which permits unrestricted non commercial use, distribution, and reproduction in any medium, provided the original authors and source are credited.