

Contents lists available at [ScienceDirect](http://ScienceDirect.com)

Journal of Orthopaedics, Trauma and Rehabilitation

Journal homepages: www.e-jotr.com & www.ejotr.org

Case Report

Hip Arthroplasty for Treatment of Atypical Femoral Fracture with Pre-existing Hip Osteoarthritis

用全髖關節置換術來治療同時患有髖骨關節炎和非典型股骨骨折的病人：病例報告

Yee Dennis K.H. ^{a,*}, Cheng H.C. ^b^a Department of Orthopaedics and Traumatology, Queen Mary Hospital, Hong Kong, China^b Department of Orthopaedics and Traumatology, United Christian Hospital, Hong Kong, China

ARTICLE INFO

Article history:

Received 3 February 2015

Received in revised form

17 September 2015

Accepted 2 November 2015

Keywords:

atypical femoral fracture

hip arthroplasty

hip osteoarthritis

ABSTRACT

A 72-year-old woman with bilateral hip dysplasia sustained atypical femoral fracture of the left subtrochanteric region. She underwent left total hip replacement with a long extensively porous coated femoral stem. The fracture healed with incorporation of the strut allograft after 8 months. A painful horizontal radiolucent line at the tip of the femoral stem was noted after 4 years, with resolution of symptoms after a period of protected weight bearing. We believe that total hip replacement for subtrochanteric atypical femoral fracture with pre-existing hip dysplasia is a feasible option and avoids a second operation for the treatment of osteoarthritis.

中文摘要

案例

一位72歲的女病人，本身患有雙側髖關節發育不良，遭受左股骨粗隆下非典型股骨骨折。她接受了左全髖關節置換術，並放置了全孔洞覆蓋式股骨長柄假體。骨折後8個月，骨折成功和結構性異位骨癒合。手術後4年，病人出現疼痛，並在股骨長柄假體末端出現了一條疑見透亮線影。症狀在使用保護性負重一段時間後，得以消除。

結論

我們相信，利用全髖關節置換術來治療同時患有非典型股骨骨折和髖關節發育不良的病人，是一種可行的選擇，並且可以避免進行第二次手術來治療骨關節炎。

Introduction

Bisphosphonate and denosumab have been shown to reduce the occurrence of osteoporotic fractures. However, there are increasing reports of atypical femoral fractures occurring in patients exposed to these medications. Atypical femoral fractures occur in the subtrochanteric or diaphyseal region with a specific radiological appearance.¹ Mainstay of treatment for atypical femoral fractures involves internal fixation with cephalomedullary nails.² Compression plate fixation has been advocated in revision cases.² High complication rates with non-union have been reported in the

treatment of these fractures,³ resulting in implant failure. Hip osteoarthritis can be present in patients suffering from atypical femoral fracture and further complicates the treatment.

We report a case of atypical femoral fracture in a patient with pre-existing hip osteoarthritis treated with total hip replacement. The patient was informed that data concerning her case would be submitted for publication.

Case Report

A 72-year-old woman sustained a left subtrochanteric fracture after she fell on level ground. She was diagnosed with osteoporosis and started on a weekly dose of 70 mg alendronate 4 years before this accident. Past medical history included cataract surgery. She also had bilateral hip osteoarthritis due to hip dysplasia, pending

* Corresponding author.

E-mail: yeedns@gmail.com.

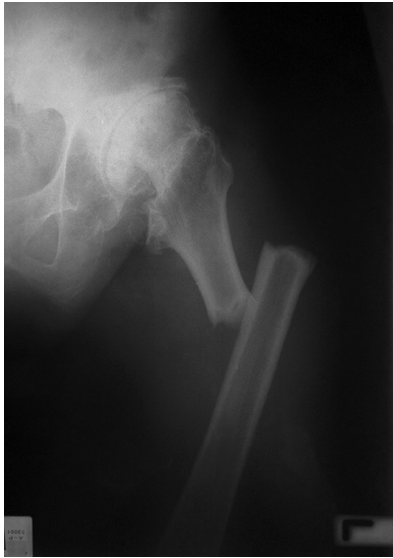

Figure 1. Right transverse subtrochanteric fracture with beaking of the cortex and no comminution. Note the presence of acetabular dysplasia.

bilateral total hip replacement. Radiography showed left transverse subtrochanteric fracture with beaking of the cortex and no comminution (AO/OTA classification 32-A1; [Figure 1](#)). The acetabulum was dysplastic with superolateral uncontained defect (AAOS Type 3 acetabular bone loss). Radiography of the rest of the femur did not show other lesions. Radiography of the contralateral femur showed hip dysplasia with no evidence of stress fracture.

She underwent left total hip replacement 9 days after sustaining the fracture. The patient was placed in the lateral position. A posterior approach was used. U-capsulotomy was performed to dislocate the femoral head. The acetabulum was prepared. The acetabular defect was reconstructed with impaction bone grafting. Ream mesh was applied and fixed with screws. A 50-mm acetabular cemented cup (Trident; Stryker Corp., Mahwah, NJ, USA) was inserted.

The femoral fracture was reduced and temporarily held with a 4.5-mm broad dynamic compression plate. The femoral head was

excised and the femoral canal was reamed. A long extensively porous coated press fit femoral stem was used to bypass the fractured metaphyseal femur (SOLUTION SYSTEM femoral stem; DePuy Synthes, a Johnson & Johnson Company, Warsaw, Indiana). The articulation was metal on polyethylene. Cortical strut allograft was placed lateral to the femur across the fracture site and fixed with multiple cerclage wires. Postoperative radiography showed that the fracture was reduced in the neutral position with a well-aligned total hip prosthesis ([Figure 2](#)). Toe-touch-down weight bearing was allowed for 12 weeks for protection of the impaction bone grafting, followed by full weight bearing walking. A hip spica brace was given in the initial postoperative period to prevent dislocation.

Serial radiographs demonstrated fracture healing and no migration of acetabular or femoral components. The fracture healed and the strut allograft was incorporated at 8 months post-operation ([Figure 3](#)). The patient's right hip was replaced 9 months after the left total hip replacement.

The patient remained symptom free and was able to walk with a frame. Routine follow-up radiography at 4 years post-operation noted a horizontal radiolucent line across the anterior femoral cortex at the tip of the femoral stem on lateral radiography ([Figure 4](#)). There was no pain or local tenderness. The patient was observed with serial follow-up. She developed anterior and lateral mechanical thigh pain 1 year later, which limited her walking. There was local tenderness corresponding to the site of the horizontal radiolucent line on the radiograph. Bone scanning showed mild increased uptake adjacent to distal femoral stem on delayed images ([Figure 5](#)). The patient was treated with protected weight bearing. Her thigh pain gradually resolved after 1 month. She could walk with a frame for 45 minutes. [Figure 6](#) shows the latest radiograph at 5 years 8 months post-operation, with a similar horizontal radiolucent line over the anterior femur. The patient was asymptomatic.

Discussion

The goal of treatment of any geriatric hip fracture is to allow early mobilization while limiting complications.⁴ Consensus exists for hip arthroplasty in displaced femur neck fracture, but the indications in intertrochanteric and subtrochanteric fractures are controversial. A case series of hip arthroplasty for unstable

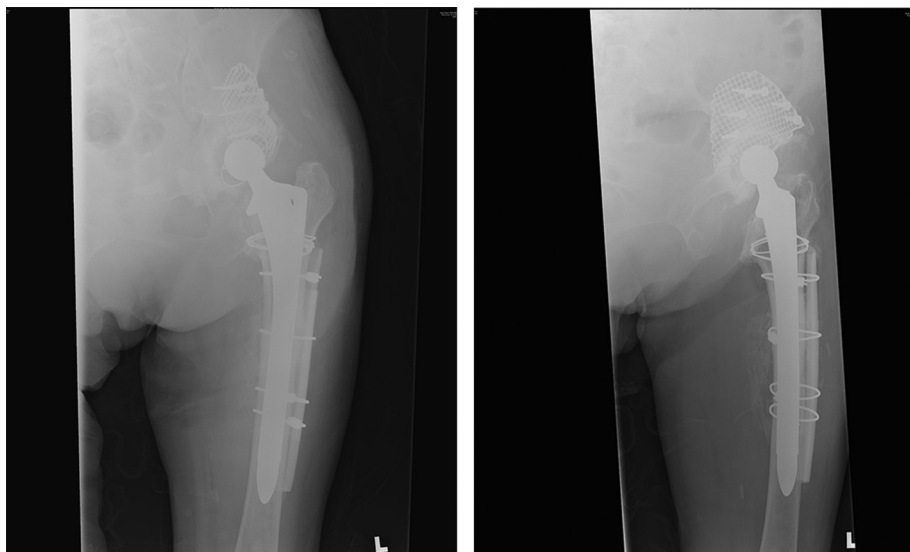


Figure 2. Postoperative anterior–posterior and lateral radiograph showing total hip replacement with cemented acetabular component and impaction bone graft for acetabular bone defect. The subtrochanteric fracture was reduced and an extensively porous coated press fit long femoral stem was used.

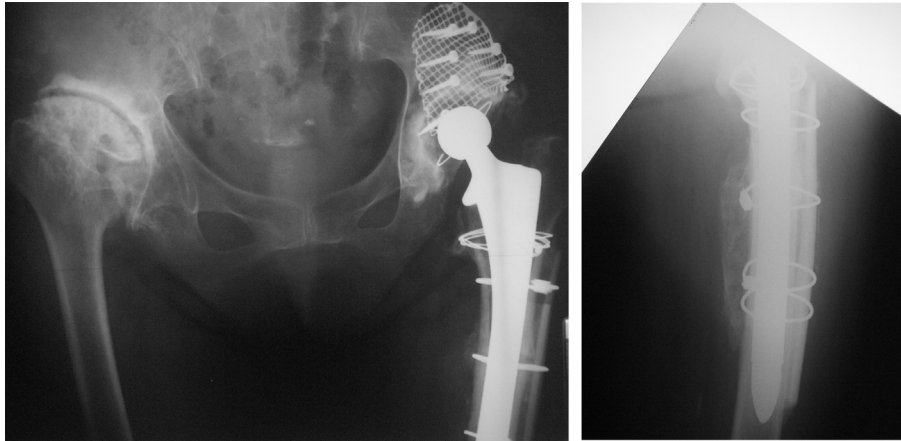


Figure 3. One year postoperative anterior–posterior radiograph showing healing of fracture and incorporation of bone graft.

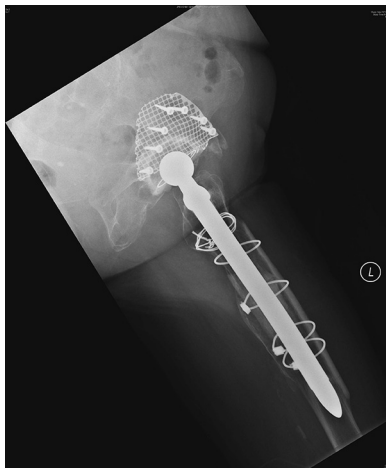


Figure 4. Four years postoperative lateral radiograph showing a horizontal radiolucent line at the anterior femoral cortex at the distal tip of the femoral stem.

intertrochanteric fractures and salvage of failed fixation of intertrochanteric fractures has been reported, but in subtrochanteric fracture this is rare. The advantage for hip arthroplasty is that it allows early weight bearing, as opposed to lengthy protected rehabilitation with internal fixation in unstable fracture patterns.^{5–8}

In patients with proximal femur fracture with pre-existing osteoarthritis of the hip, total hip replacement with cementless long-stem fixation offers a one-off solution to both problems and spares the patient from another operation. Moreover, with hip replacement, the range of movement of the hip will improve and this will decrease the stress on the fracture. By contrast, the disadvantages of such treatment include prolonged operation, increased chance of dislocation, and healing problems with the atypical femoral fracture. The alternative is fracture fixation alone at the first stage and total hip replacement after healing of the atypical femoral fracture.

Hip arthroplasty for subtrochanteric fracture is a technically challenging operation. The operation time and blood loss are expected to be higher than for internal fixation alone. In a series of trochanteric fractures,⁹ the mean blood loss and operation time for

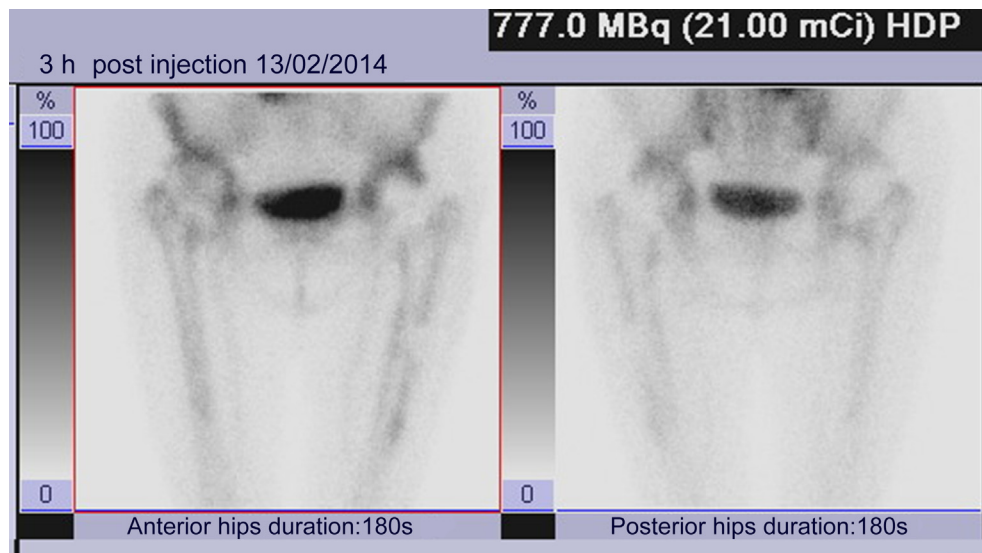


Figure 5. Delayed images of bone scanning showing mild increased uptake at the distal tip of the femoral stem.

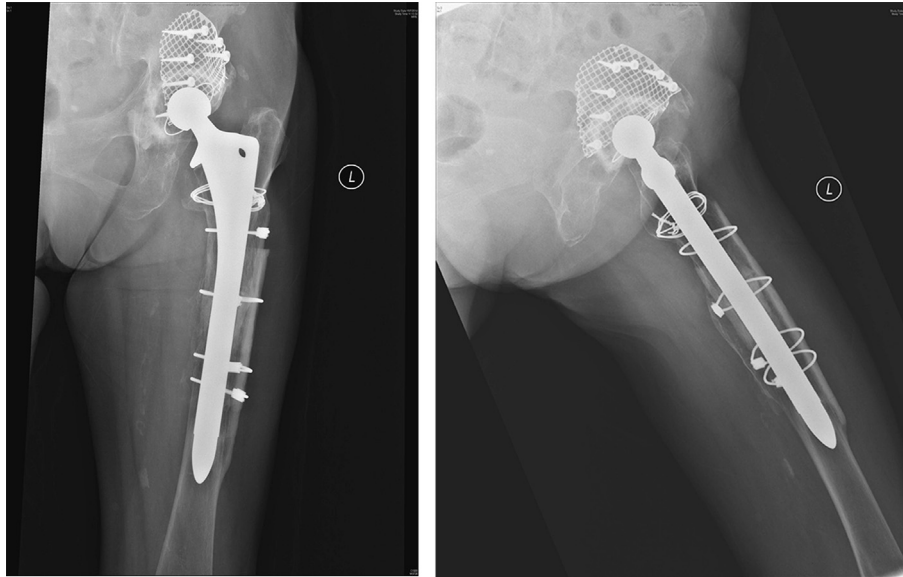


Figure 6. Latest radiograph at 5 years 8 months showing persistence of the horizontal radiolucent line at the distal tip of the femoral stem.

arthroplasty were significantly higher than for fixation with a dynamic hip screw or proximal femoral nail (DePuy Synthes, a Johnson & Johnson Company, Warsaw, Indiana). Fracture complexity also affected the blood loss and operation time in the arthroplasty group, increasing from AO/OTA 31-A1 to 31-A3. The mortality depended only on the age and comorbidity but not on the treatment method.

Dislocation is one of the major complications in hip arthroplasty for proximal femoral fractures.^{9–11} In a meta-analysis of randomized trials comparing total hip replacement versus hemiarthroplasty for displaced femur neck fracture, there is a higher risk of dislocation in patients undergoing total hip replacement (relative risk 1.99).¹² In some series, it has been shown that the rate of dislocation can be as high as 20%.¹¹ It is proposed that the high dislocation rate may be due to the increased risk of falling and poorer soft tissue in this group of patients.¹¹ They may also be less able to comply with the precautions of dislocation. Compared with the patients having arthroplasty for arthritis, these patients have better preoperative range of motion and move their hips more freely in the postoperative period, which jeopardizes soft tissue healing. Hemiarthroplasty has a lower dislocation rate than total hip replacement because of better femur head neck ratio.¹³ In the present case, we performed total hip replacement instead of hemiarthroplasty due to the presence of acetabular dysplasia.

Atypical femoral fracture associated with history of bisphosphonate usage represents a special group of patients among those with subtrochanteric fractures. A much higher failure rate with intramedullary nailing up to 54%, with many requiring revision surgery, has been observed.³ This contrasts with the reported high union rate of 98–99% in intramedullary nailing of femoral shaft fractures.^{14,15} Management of periprosthetic fracture after total hip replacement with revision using long cementless femoral stem has been reported to have a high success rate.^{16–19} By contrast, the use of such a stem in the treatment of atypical femoral fracture has not been reported. It is not known whether the healing will be affected, resulting in failure, as with intramedullary nailing.

One of the advantages of using intramedullary nailing is its ability to splint the whole femur. Atypical femoral fracture occurs at the subtrochanteric as well as diaphyseal region.¹ In our

patient, a new horizontal radiolucent line was noted at the distal fixation site for the femoral stem, which became symptomatic. In nonreplaced femur, the presence of pain symptom and the “dreaded black line” would warrant prophylactic fixation in view of the high risk of completion fracture.²⁰ For our patient, revision of the femoral stem to a longer implant bypassed the radiolucent line but could not splint the whole femur. Additional fixation with a lateral locking plate was another option. As the patient’s pain symptom responded rapidly with conservative treatment, we decided for close clinical and radiological observation.

We reported a case of total hip replacement for atypical femoral fracture associated with bisphosphonate usage with coexisting hip dysplasia. This is the only case report that we could find in the literature to treat a subtrochanteric atypical femoral fracture with total hip replacement. Extensively porous coated press fit long femoral stem and reinforcement with strut allograft allow successful healing of the atypical fracture. We believe that total hip replacement can allow early mobilization and rehabilitation of the patient, decreasing the rate of non-union and implant failure, and avoid reoperation for treatment of osteoarthritis. A larger series will be required to evaluate the success of this treatment method.

Conflicts of interest

The authors have no conflicts of interest to declare.

References

1. Capeci CM, Tejwani NC. Bilateral low-energy simultaneous or sequential femoral fractures in patients on long-term alendronate therapy. *J Bone Joint Surg Am* 2009;**91**:2556–61.
2. Grady MK, Watson JT, Cannada LK. Treatment of femoral fracture nonunion after long-term bisphosphonate use. *Orthopedics* 2012;**35**:e991–5.
3. Weil YA, Rivkin G, Safran O, et al. The outcome of surgically treated femur fractures associated with long-term bisphosphonate use. *J Trauma* 2011;**71**:186–90.
4. Lindskog DM, Baumgaertner MR. Unstable intertrochanteric hip fractures in the elderly. *J Am Acad Orthop Surgeons* 2004;**12**:179–90.
5. Haentjens P, Lamraski G. Endoprosthetic replacement of unstable, comminuted intertrochanteric fracture of the femur in the elderly, osteoporotic patient: a review. *Disabil Rehab* 2005;**27**:1167–80.

6. Kayali C, Agus H, Ozluk S, et al. Treatment for unstable intertrochanteric fractures in elderly patients: internal fixation versus cone hemiarthroplasty. *J Orthop Surg* 2006;**14**:240–4.
7. Sidhu AS, Singh AP, Singh AP, et al. Total hip replacement as primary treatment of unstable intertrochanteric fractures in elderly patients. *Int Orthop* 2010;**34**:789–92.
8. Karthik K, Natarajan M. Unstable trochanteric fractures in elderly osteoporotic patients: role of primary hemiarthroplasty. *Orthop Surg* 2012;**4**:89–93.
9. Geiger F, Zimmermann-Stenzel M, Heisel C, et al. Trochanteric fractures in the elderly: the influence of primary hip arthroplasty on 1-year mortality. *Arch Orthop Trauma Surg* 2007;**127**:959–66.
10. Dorr LD, Glousman R, Hoy AL, et al. Treatment of femoral neck fractures with total hip replacement versus cemented and noncemented hemiarthroplasty. *J Arthroplast* 1986;**1**:21–8.
11. Ravikumar KJ, Marsh G. Internal fixation versus hemiarthroplasty versus total hip arthroplasty for displaced subcapital fractures of femur – 13 year results of a prospective randomised study. *Injury* 2000;**31**:793–7.
12. Yu L, Wang Y, Chen J. Total hip arthroplasty versus hemiarthroplasty for displaced femoral neck fractures: meta-analysis of randomized trials. *Clin Orthop Related Res* 2012;**470**:2235–43.
13. Sah AP, Estok II DM. Dislocation rate after conversion from hip hemiarthroplasty to total hip arthroplasty. *J Bone Joint Surg Am* 2008;**90**:506–16.
14. Winquist RA, Hansen Jr ST, Clawson DK. Closed intramedullary nailing of femoral fractures. A report of five hundred and twenty cases. *J Bone Joint Surg Am* 1984;**66**:529–39.
15. Tornetta III P, Tiburzi D. Antegrade or retrograde reamed femoral nailing. A prospective, randomised trial. *J Bone Joint Surg Br* 2000;**82**:652–4.
16. Fink B, Grossmann A, Singer J. Hip revision arthroplasty in periprosthetic fractures of Vancouver type B2 and B3. *J Orthop Trauma* 2012;**26**:206–11.
17. Munro JT, Garbuz DS, Masri BA, et al. Tapered fluted titanium stems in the management of Vancouver B2 and B3 periprosthetic femoral fractures. *Clin Orthop Related Res* 2014;**472**:590–8.
18. Neumann D, Thaler C, Dorn U. Management of Vancouver B2 and B3 femoral periprosthetic fractures using a modular cementless stem without allografting. *Int Orthop* 2012;**36**:1045–50.
19. O'Shea K, Quinlan JF, Kuttly S, et al. The use of uncemented extensively porous-coated femoral components in the management of Vancouver B2 and B3 periprosthetic femoral fractures. *J Bone Joint Surg Br* 2005;**87**:1617–21.
20. Koh JS, Goh SK, Png MA, et al. Femoral cortical stress lesions in long-term bisphosphonate therapy: a herald of impending fracture? *J Orthop Trauma* 2010;**24**:75–81.