



Contents lists available at ScienceDirect

International Journal of Surgery Case Reports

journal homepage: www.casereports.com

Treatment of delayed jejunal perforation after irreducible femoral hernia repair with open abdomen management and delayed abdominal closure with skin flap approximation



Fahri Yetişir^{a,*}, A. Ebru Sarer^b, Hasan Zafer Acar^c, Omer Yazıcıoğlu^a, Basar Basaran^a

^a Atatürk Research and Training Hospital, General Surgery Department, Turkey

^b Atatürk Research and Training Hospital, Anesthesiology and Reanimation Department, Turkey

^c Lokman Hekim private Hospital, General Surgery Department, Turkey

ARTICLE INFO

Article history:

Received 28 June 2015

Received in revised form 13 August 2015

Accepted 5 September 2015

Available online 16 September 2015

Keywords:

Delayed bowel perforation

Open abdomen

Delayed abdominal closure

Femoral hernia

ABSTRACT

INTRODUCTION: We show the management of a delayed jejunal perforation, after irreducible femoral hernia operation with the help of negative pressure therapy (NPT) and delayed abdominal closure (DAC) with skin flap approximation in an elderly woman for the first time in the literature.

PRESENTATION OF CASE: A 76 year-old woman was admitted to the emergency department with irreducible femoral hernia and ileus. After examining the femoral hernia sac and noting the presence of viable intestine within the hernia sac, a femoral hernia repair with mesh was performed. At postoperative day 1 she started to defecate and oral intake was started. The patient was discharged on postoperative day 3. On postoperative day 8, she was re-admitted to the emergency department with septic shock. The patient underwent reoperation. Septic abdomen and delayed perforation from strangulated part of the jejunum were seen. A jejunostomy was opened and patient was treated with open abdomen management and delayed abdominal closure with skin flap. The ostomy was closed 4 months later.

DISCUSSION: The exact mechanism of delayed presentation of small bowel perforation remains controversial. Delayed intestinal perforation has rarely been reported after blunt abdominal trauma (BAT), conductive burn injuries of the bowel with cautery, or necrosis of strangulated bowel in a hernia sac. Open abdomen (OA) management is a life-saving and challenging strategy in severe generalized peritonitis.

CONCLUSION: Delayed bowel perforation may develop after irreducible femoral hernia surgery. OA management with NPT and DAC with skin flap approximation are optimal treatment modalities for the hemodynamically instable patient.

© 2015 The Authors. Published by Elsevier Ltd. on behalf of IJS Publishing Group Ltd. This is an open access article under the CC BY-NC-ND license (<http://creativecommons.org/licenses/by-nc-nd/4.0/>).

1. Introduction

Delayed bowel perforation has rarely been reported after blunt abdominal trauma (BAT), conductive burn injuries of bowel with cautery or necrosis of strangulated bowel in a hernia sac [1,2]. The exact mechanism of delayed presentation of small bowel perforation remains controversial. In a patient with BAT where the mesenteric injury is not severe and consists of only minor tears and contusions, the clinical presentation would follow a period of normal bowel function and may be delayed by a time period ranging from 2 weeks to 3 months. In the absence of a direct bowel injury, a patient may initially tolerate a diet and display normal bowel function [1]. Bowel perforations due to thermal injuries are fundamentally different from direct mechanical injuries. Contact burn

injuries from cautery may be recognized at the time of surgery and treated appropriately. In contrast, conductive burns are not recognized at all or are recognized when perforation occurs 1–3 weeks after the initial procedure [2]. Furthermore, the consequences of bowel injury can be catastrophic. A delay in diagnosis of bowel perforation can lead to sepsis, and even death, if not diagnosed and treated promptly [3].

Open abdomen (OA) management is a life-saving and challenging strategy in situations such as abdominal compartment syndrome (ACS), damage-control surgery, and severe generalized peritonitis [4,5]. The OA is defined in the World Society of Abdominal Compartment Syndrome guidelines as one that requires a temporary abdominal closure due to the skin and fascia not being closed after laparotomy [6]. Mortality rates up to 50% were reported and were even higher in the infected OA [7,8]. Enteric fistulas are one of the most devastating abdominal complications in abdominal surgery [9].

* Corresponding author. Fax: +90 3123210089.

E-mail address: drfahriyetisir@hotmail.com (F. Yetişir).

Table 1
Laboratory value of patients before femoral hernia operation.

Biochemical analysis			Blood gas		
Glu	170 mg/dL	CRP	3 mg/dL (0–0.8)	pH	7.36
LDH	289 U/L	Sedimentation	46 mm	pCO ₂	26
Lipase	167 U/L	D-dimer	403 ng/mL (0–500)	PO ₂	78
Ure	174 mg/dL	Procalcitonin	0.313 ng/mL (<0.500)	HCO ₃	15
Creatinine	3.1 mg/dL	WBC	11,000 K/uL	BE	–7.7

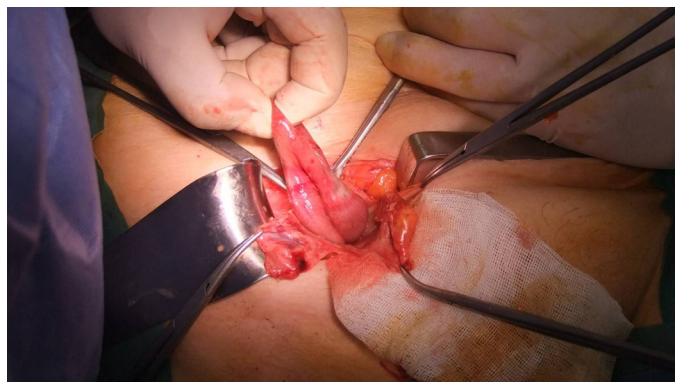

Fig. 1. Presentation of hernia sac and small intestine.

According to our knowledge, there is no report about delayed bowel perforation after the surgery of irreducible femoral hernia in the literature. Here, we report the management of a septic OA patient with the help of negative pressure therapy (NPT) and delayed abdominal closure with skin flap approximation in a 76-year-old woman with delayed jejunal perforation, 8 days after irreducible femoral hernia operation.

2. Presentation of Case

A 76-year-old woman was admitted to the emergency department with complaints of abdominal pain, constipation, vomiting, anuria and shortness of breath. The patient reported abdominal pain especially on the right inferior part of abdomen that had been present for a long time. The severity of the pain had increased in the last 2 days. Comorbidities included hypertension, diabetes, hyperlipidemia, coronary arterial disease and chronic obstructive lung disease. A previous abdominal operation for a perforated appendix occurred 15 years prior. Upon physical examination, the patient’s blood pressure (BP) measured 105/55 mmHg, heart rate (HR) was 96, and temperature was 36.9 °C. The abdominal examination revealed hyperactive bowel sounds and minimal distention. Sensitivity and rigidity were observed in the right inferior quadrant of abdomen. An irreducible femoral hernia was present on the right side of the abdomen. Prerenal acute renal failure and mild metabolic acidosis were present (Table 1). X-rays showed the abdominal air/fluid level.

Consultation with cardiology, internal medicine, endocrinology and anesthesia was performed, and the patient hydrated during this period. During a 3-h period following hydration, urine output was measured at 200 cc; 1400 cc of small intestinal contents were drained via nasogastric tube. The patient underwent an emergency operation for irreducible femoral hernia. The hernia sac and small intestine were isolated, and the small intestine was thought to be viable (Fig. 1). The abdomen was explored from femoral defect after dilating this opening. There was only serous fluid was present without any other pathology. Femoral hernia repair was performed by preperitoneal mesh insertion (Fig. 2), as Yetişir previously described [10]. The patient started to defecate on postoperative day 1, and oral intake was initiated. On postoperative day

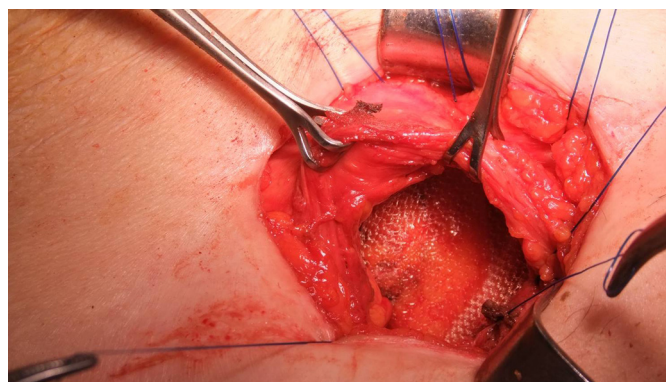


Fig. 2. Mesh was placed under the fascia and over the peritoneum after preperitoneal preparation from dilated femoral opening.

Table 2
Laboratory value of the patients 3 days after the femoral hernia operation.

Biochemical analysis		Total blood count	
Glu	100 mg/dL	WBC	7000 K/uL
LDH	259 U/L		
Lipase	60 U/L		
Ure	104 mg/dL		
Creatinine	0.9 mg/dL		

Table 3
Laboratory value of the patients 8 day after femoral hernia operation.

Biochemical analysis			Blood gas		
Glu	140 mg/dL	CRP	18.4 mg/dL (0–0.8)	pH	7.3
LDH	.357 U/l	Sedimentation	55 mm	pCO ₂	32
Lipase	251 U/L	D-Dimer	5017 ng/mL (0–500)	PO ₂	58
Amylase	253 U/L	Procalcitonin	8,55 ng/mL (<0.500)	HCO ₃	16
Ure	115 mg/dL	INR	1.55	BE	–8
Creatinine	1.2 mg/dL	WBC	22,000 K/uL	Lac	4.1
Alb	1.55 g/dL				
T. protein	3.5 g/dL				

3, the general condition of patient was well; she was conscious and oriented. Prerenal acute renal failure had improved (Table 2), and the patient was discharged from hospital.

The patient was readmitted to the emergency department with the complaint of abdominal pain, vomiting, anuria and shortness of breath on postoperative day 8. Her general condition, consciousness and orientation were not well. In physical examination, her BP measured 80/55 mmHg, HR was 114, respiratory rate was 36, and temperature was 38 °C. The patient’s intra-abdominal pressure (IAP) was 18 mmHg. On her abdominal examination, there were no bowel sounds or distention. The patient was in septic shock and metabolic acidosis. D-Dimer was high (Table 3), and the white blood cell count (WBC), c-reactive protein (CRP), procalcitonin, and lactate levels were increased (Figs. 3 and 4). Air/fluid levels in the small bowel and intra-abdominal fluid collection were present in the abdominal computerized tomography (CT) scan (Fig. 5). The sequential organ failure assessment score (SOFA) of the patient was 15, and her estimated mortality was 80%. The patient was selectively intubated, Clexane 2 × 0.6 was administered, and antibiotic therapy was started. Fluid and electrolyte resuscitation and low vasopressor support were started. The patient underwent an emergency operation where 2–3 liters of enteric influents were present and all intestinal tissue was very edematous and fragile during exploration. The patient’s open abdomen classification was 2C according to the new Björck score (Fig. 6). All intra-abdominal content was washed and irrigated with saline. After gentle dissection, a perforation point of jejunum 150 cm from the ligament

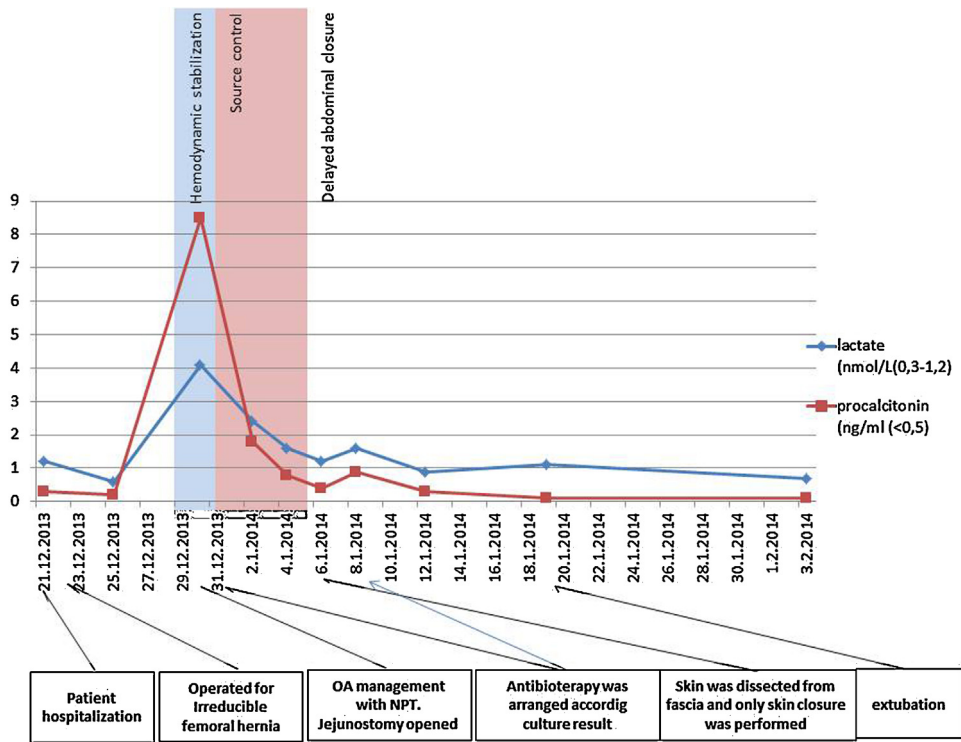


Fig. 3. Change in the lactate and procalcitonin levels from hospitalization to closure of OA are shown.

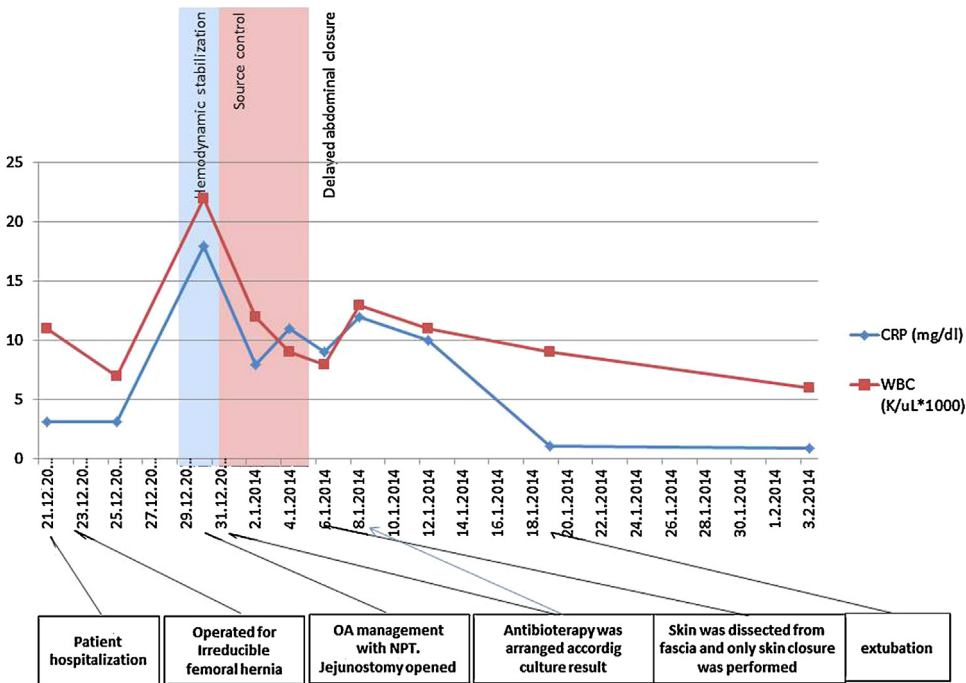


Fig. 4. Change in the white blood cell count and c-reactive protein level from hospitalization to closure of OA are shown.

of Treitz was seen (Fig. 7). The perforated part of jejunum was resected and double barrel jejunostomy was created. Abdominal NPT (ABThera™ Open Abdomen Negative Pressure Therapy System, KCI, an Acelyty company, San Antonio, TX) was applied (Fig. 8). On postoperative day 2, vital and laboratory parameters were improved and vasopressor support was stopped. On postoperative day 6, all the vital and laboratory parameters continued to improve, and intra-abdominal sepsis was resolved (Fig. 9). The

skin was dissected from the fascia, and delayed abdominal closure was performed by approximation of skin flap (Fig. 10). The patient was discharged from the hospital 33 days after the operation with instructions for oral diphenoxylate/atropine 4 × 2 mg (author to confirm dosage units) and 1000 cc iv fluid intake a day. Jejunostomy was closed 4 months later (Fig. 11) without complications. A planned ventral hernia at the end of the 12-month follow-up period (Fig. 12).

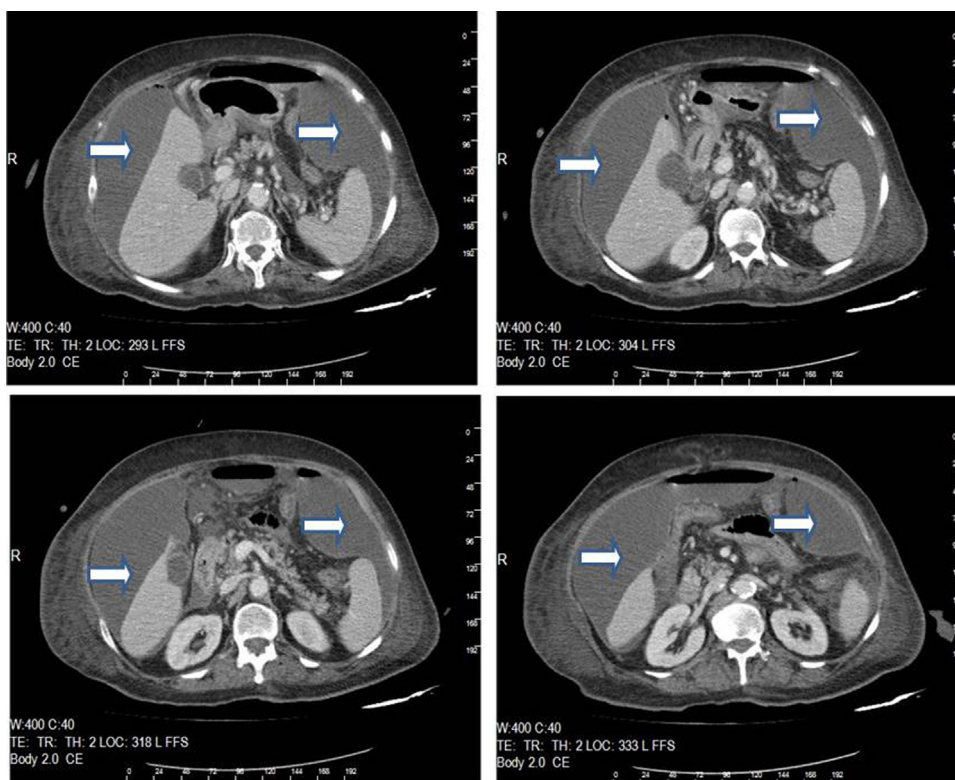


Fig. 5. Abdominal CT shows excessive amount of intra-abdominal free fluid collection.

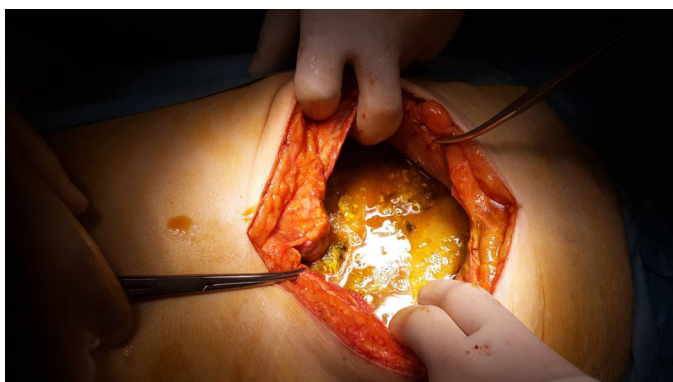


Fig. 6. Excessive amount of enteric influents and edematous bowel are shown.

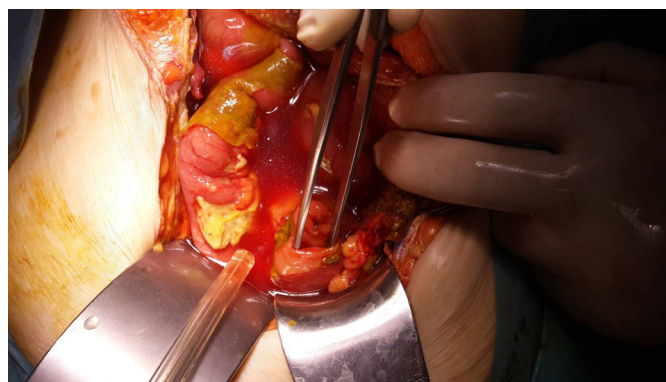


Fig. 7. Proximal and distal parts of perforation point of jejunum are shown.

3. Discussion

In this case, we thought that the occurrence of delayed jejunal perforation approximately 8 days after irreducible femoral hernia surgery was due to necrosis of the strangulated bowel, which was believed to be viable during the initial operation. This necrosis may have been enhanced by unintentional conductive burn injuries of cautery during dissection. The patient's comorbidities may have also contributed to the occurrence of the perforation and worsened the situation. Bovie injury to the bowel can be hidden, causing a slow transmural tissue necrosis, and may also impair local healing and eventually lead to perforation [2]. In cases of Bovie injury, the average time from injury to diagnosis was 10.4 days [2]. Chapron et al. reported that approximately 75% of bowel injuries were diagnosed within the first postoperative week [3].

Mortality within 30 days of groin hernia surgery increases significantly when an emergency operation is needed, ranging from 2.8 to 3.1% [11] and is even higher when bowel resection is needed. Sig-

nificant factors associated with increased mortality in emergency settings are female gender and increasing age [12]. Our case had all these factors. Duration of strangulation is the most important determinant of the outcome regarding gut viability, resection-anastomosis rate, morbidity and mortality [13]. Andrews noted mortality rates of 1.4%, 10% and 21%, for strangulated hernia when presented within 24 h, 24–48 h and after 48 h, respectively [14]. In our case, duration of strangulation was more than 48 h.

In severe hemodynamic instability and physiologic derangements, definitive repair and definitive closure could not be obtained, and restoration of intestinal continuity is postponed to other operations [15]. In our case, a double barrel jejunostomy was preferred over anastomosis; OA management with NPT was also performed instead of direct abdominal closure after fistula control due to the patient's comorbidities, septic abdomen, high IAP and hemodynamic instability. Kubiak et al. examined ischemia reperfusion of the intestine and intra-abdominal sepsis in a porcine model of multiple organ injury and reported that the application of peri-

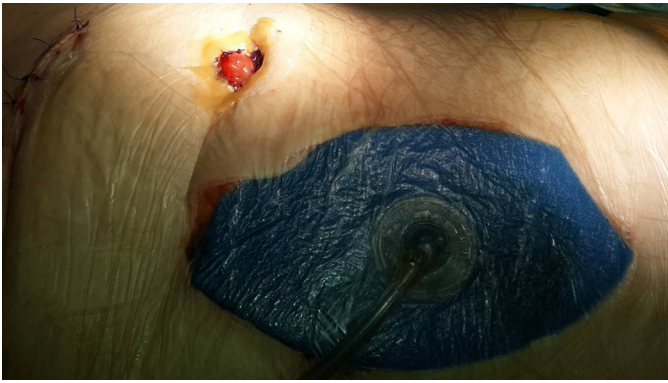

Fig. 8. Application of abdominal NPT with jejunostomy.

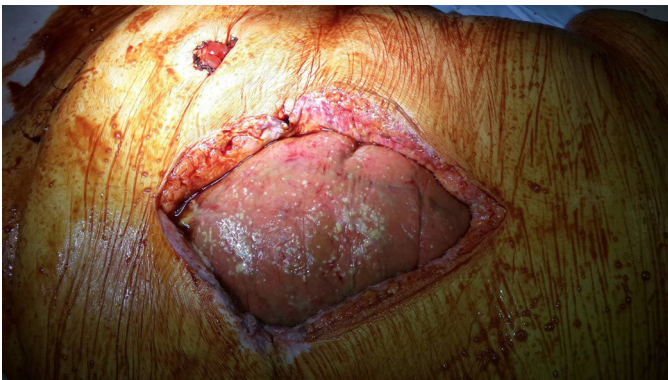

Fig. 9. Intra-abdominal visceral showing no enteric content or sepsis.

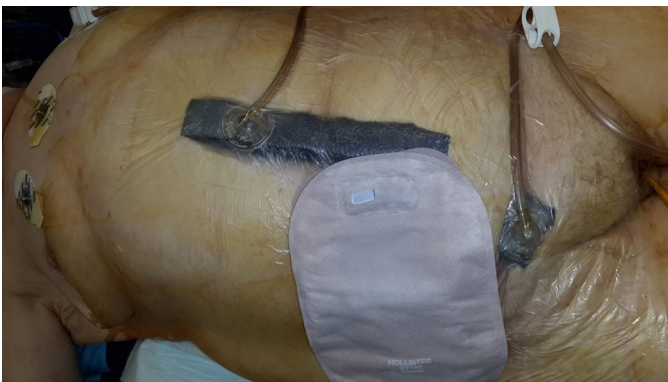

Fig. 10. Delayed abdominal closure by approximation of skin flap and NPT application.

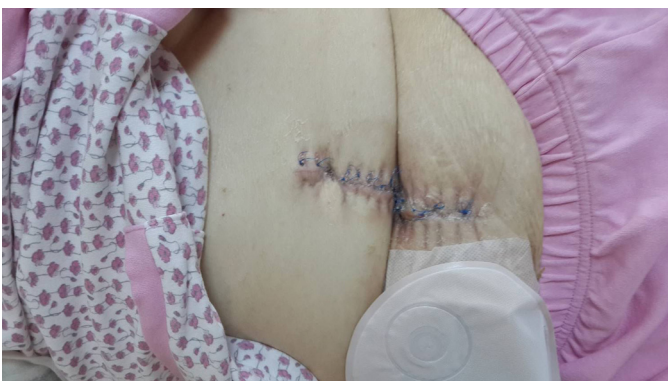

Fig. 11. Closed jejunostomy is shown.

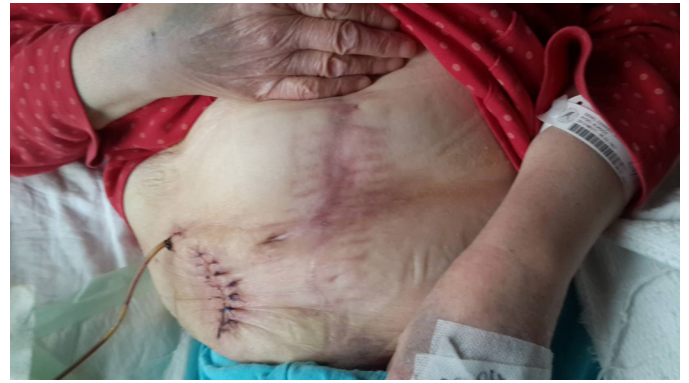

Fig. 12. No complications at 12 month follow-up period.

toneal NPT significantly reduced lung, kidney, liver and intestinal pathology and improved pulmonary parameters, which may have been due to peritoneal cytokine removal [16].

There are lots of different delayed OA closure methods. Some methods deal with fascial closure and use strategies allowing the re-approximation of the fascial edges in conjunction with NPT. This method can lead to high closure rates [4,8,17]. In elderly patients with more comorbid diseases, delayed OA closure is utilized to decrease the number of operations and duration of treatment. Some delayed OA closures employ skin closure with flap approximation and skin grafting, as performed in our case.

4. Conclusion

Delayed bowel perforation may develop after irreducible femoral hernia surgery, even if the bowel was seen as viable during operation, especially in elderly patients with comorbidities. Patients need to be notified of this situation. OA management with NPT is an optimal treatment modality for hemodynamically instable patients with a septic abdomen and high IAP. Delayed OA closure with skin flap approximation may be the most suitable way for closure in these kinds of patients.

Written informed consent was obtained from the patient whose case is discussed in this paper, regarding the publication of this case report and accompanying images.

Conflict of interest

None.

Funding

None.

Ethical approval

None.

Contributors

Fahyi Yetisir: study design, data collection, data analysis or interpretation and writing the paper.

A. Ebru Sarer: data analysis interpretation and writing the paper.

Hasan Zafer Acar: writing the paper.

Omer Yazıcıoğlu: data collection and data analysis.

Basar Basaran: data collection, data analysis or interpretati.

Consent

Fully informed written consent was taken.

Guarantor

Fahri Yetişir.

References

- [1] A.H. Jahromi, L. Johnson, A.M. Youssef, Delayed small bowel perforation following blunt abdominal trauma: a case report and review of the literature, *Asian J. Surg.* (2013) 1–4.
- [2] J.S. Bhullar, J. Gayagoy, S. Chaudhary, R.B. Kolachalam, Delayed presentation of a bowel Bovie injury after laparoscopic ventral hernia repair, *JLS* 17 (2013) 495–498.
- [3] C. Chapron, F. Pierre, Y. Harchaoui, Gastrointestinal injuries during gynaecological laparoscopy, *Hum. Reprod.* 14 (2) (1999) 333–337.
- [4] A.E. Salman, F. Yetişir, M. Aksoy, M. Tokaç, M.B. Yildirim, KiliçM: use of dynamic wound closure system in conjunction with vacuum-assisted closure therapy in delayed closure of open abdomen, *Hernia* 18 (1) (2014) 99–104.
- [5] F. Yetişir, A.E. Salman, F. Özdemir, D. Durak, O. Özlü, M. Kılıç, Modified application of dynamic wound closure system in the management of septic open abdomen, *World J. Trauma Crit. Care Med.* 1 (2013) 1–8.
- [6] A.W. Kirkpatrick, D.J. Roberts, J. De Waele, R. Jaeschke, M.L. Malbrain, B. De Keulenaer, et al., Intra-abdominal hypertension and the abdominal compartment syndrome: updated consensus definitions and clinical practice guidelines from the World Society of the Abdominal Compartment Syndrome, *Intensive Care Med.* 39 (2013) 1190–1206.
- [7] J.L. Regner, L. Kobayashi, R. Coimbra, Surgical strategies for management of the abdomen, *World J. Surg.* 36 (3) (2012) 497–510.
- [8] F. Yetişir, A.E. Salman, M. Aygar, F. Yaylak, M. Aksoy, A. Yalçın, Management of fistula of ileal conduit in open abdomen by intra-conduit negative pressure system, *Int. J. Surg. Case Rep.* 9 (2014) 385–388.
- [9] J.J. Dubose, J.B. Lundy, Enterocutaneous fistulas in the setting of trauma and critical illness, *Clin. Colon Rectal Surg.* 23 (2010) 182–189.
- [10] F. Yetişir, A.E. Salman, O. Özlü, et al., An alternative anterior tension free preperitoneal patch technique by help of the endoscope for femoral hernia repair, *Int. J. Surg.* 11 (9) (2013) 962–966.
- [11] A. Koch, A. Edwards, S. Haapaniemi, et al., Prospective evaluation of 6895 groin hernia repairs in women, *Br. J. Surg.* 92 (2005) 1553.
- [12] H. Nilsson, G. Stylianidis, M. Haapamäki, et al., Mortality after groin hernia surgery, *Ann. Surg.* 245 (2007) 656.
- [13] M.H. Abbas, Outcome of strangulated inguinal hernia, *Pak. J. Med. Sci.* 4 (October–December) (2005) 445–450.
- [14] N.J. Andrews, Presentation and outcome of strangulated external hernia in a district general hospital, *Br. J. Surg.* 68 (1981) 329–332.
- [15] A. Leppaniemi, E.J. Kimball, I. De laet, M.L.N.G. Malbrain, Z.J. Balogh, J.J. Waele, Management of abdominal sepsis—a paradigm shift? *Anesthesiol. Intensive Ther.* (2015), <http://dx.doi.org/10.5603/AIT.a2015.0026>.
- [16] B.D. Kubiak, S.P. Albert, A.L. Gatto, K.P. Snyder, K.G. Maier, J.V. Vieau, et al., Peritoneal negative pressure therapy prevents multiple organ injury in a chronic porcine model of sepsis, *Shock* 34 (2010) 525–534.
- [17] F. Yetişir, A.E. Salman, R. Mamedov, M. Aksoy, A. Yalçin, C. Kayaalp, Intra-abdominal negative pressure system in the management of open abdomen with colorectal fistula: a case report, *Int. J. Surg. Case Rep.* 5 (3) (2014) 164–168.

Open Access

This article is published Open Access at sciedirect.com. It is distributed under the [IJSCR Supplemental terms and conditions](#), which permits unrestricted non commercial use, distribution, and reproduction in any medium, provided the original authors and source are credited.