


HOSTED BY



ELSEVIER

Available at www.sciencedirect.com

ScienceDirect

journal homepage: www.elsevier.com/locate/IJMYCO

Case Report

Tuberculous flexor tenosynovitis of the hand

Mohamed Ali Sbai ^{a,*}, Sofien Benzarti ^a, Monia Boussem ^b, Riadh Maalla ^c^a Orthopedic Surgery and Trauma Department, Maamouri Hospital, Nabeul, Tunisia^b Emergency Department, Mongi Slim Hospital, Tunis, Tunisia^c Plastic Surgery Department, La Rabta Hospital, Tunis, Tunisia

ARTICLE INFO

Article history:

Received 9 June 2015

Received in revised form

17 June 2015

Accepted 18 June 2015

Available online 15 July 2015

Keywords:

Tenosynovitis

Tuberculosis

Mycobacterium tuberculosis

Finger

Hand surgery

ABSTRACT

Tuberculosis is a major public health problem in developing countries. Flexor tenosynovitis of the fingers constitutes an exceptional tuberculosis localization (Gabl et al., 1997; Senda et al., 2011) [1,2]. Unusual presentations, such as tuberculous tenosynovitis, often go undetected and are associated with a diagnostic and therapeutic delay, especially when bacteriological research proves to be negative. Here, we report a case of tuberculous flexor tenosynovitis of the hand.

© 2015 Asian African Society for Mycobacteriology. Production and hosting by Elsevier Ltd. All rights reserved.

Case report

Here, we report the case of a previously healthy 28-year-old female farmer that presented with painful swelling of the left middle finger that had evolved over the course of a month. Local inflammatory signs appeared within 3 days of admission. There was no history of fever, weight loss, loss of appetite, trauma, septic inoculation, and the patient was not immunodeficient. Clinical study indicated painful swelling of the left middle finger following attempts to extend, evoking a phlegmon of the flexor sheath (Fig. 1).

The rest of the clinical study was unremarkable. Biological results showed elevated acute-phase reactants (erythrocyte

sedimentation rate [ESR] = 60) and normal white blood cell count. Radiography of the left hand showed thickening of the soft tissue in the middle finger. The patient underwent emergency surgery, which revealed the intraoperative aspect evoking a flexor tenosynovitis (Fig. 2). A synovectomy and synovial biopsy were performed (Fig. 3) and an intradermal tuberculin reaction test was conducted, which was positive (13 mm). Pathological study revealed a giant-cell granuloma with caseous necrosis and cultures on Löwenstein–Jensen medium suggested the presence of *Mycobacterium tuberculosis*. There was no evidence of concomitant active- or sleeping-tuberculous foci in any other location than the tenosynovitis. Antibacillary chemotherapy administered over an 8-month

* Corresponding author.

E-mail address: mohamedali.sbai@rns.tn (M.A. Sbai).

Peer review under responsibility of Asian African Society for Mycobacteriology.

<http://dx.doi.org/10.1016/j.ijmyco.2015.06.003>

2212-5531/© 2015 Asian African Society for Mycobacteriology. Production and hosting by Elsevier Ltd. All rights reserved.

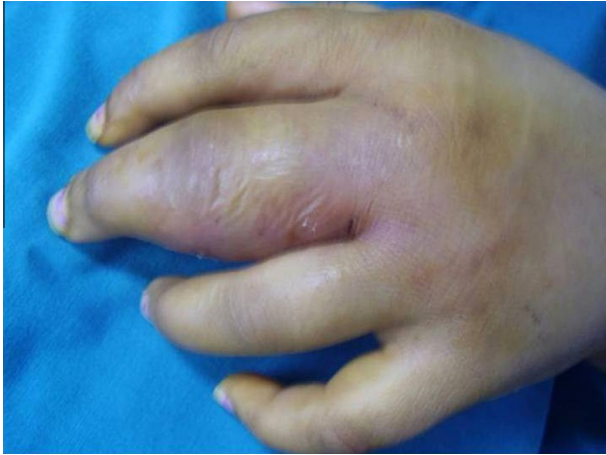

Fig. 1 – Clinical appearance showing the swelling the inflammatory signs of the middle finger.

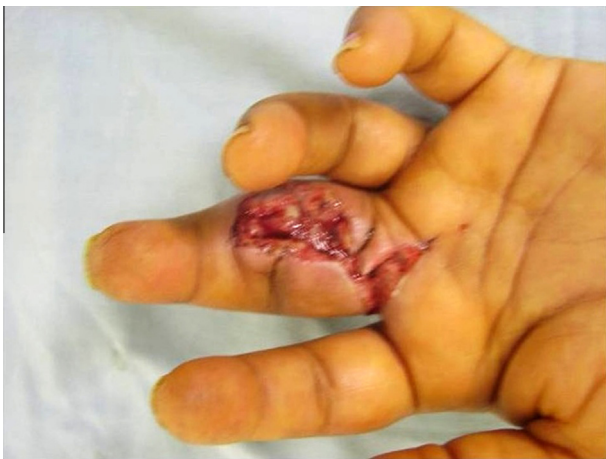

Fig. 2 – Intraoperative view showing the tenosynovitis.

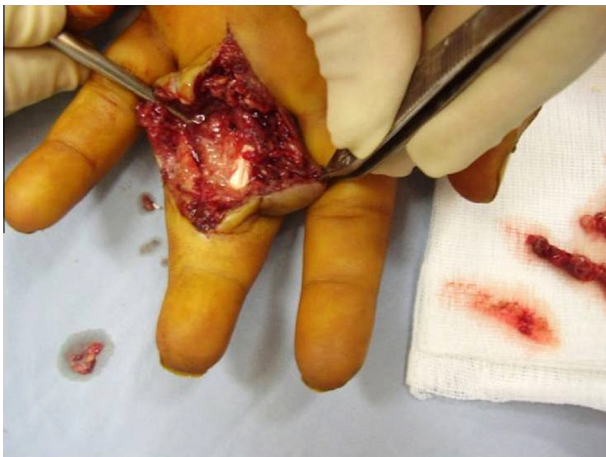


Fig. 3 – Intraoperative view showing the synovectomy and synovial biopsy.

period (associating isoniazid, rifampicin, pyrazinamide, and ethambutol for 2 months, followed by isoniazid and rifampicin for the next 6 months) promoted full healing and positive

results in this patient, including disappearance of the swelling after 2 months of treatment and a normal range of motion after 6 months without recurrence within 3 years (Fig. 4).

Discussion

Musculoskeletal involvement represents 1–5% of extrapulmonary tuberculosis (TB) manifestations. Tuberculous tenosynovitis represents only 5% of bone and joint TB and usually involves the wrist [3,4]. Involvement of the flexor is much more common than that observed with the extensors. TB diagnosis is difficult to evoke in the presence of chronic tenosynovitis and is often delayed. Tuberculous tenosynovitis is characterized by an insidious onset, wherein swelling becomes evident only after several months, mobility becomes limited, and symptoms can evolve to fistulization. Local inflammatory signs may also be discreet. While carpal tunnel syndrome can be observed in cases of an infringement of the wrist flexors [4], the clinical picture can also mimic a De Quervain tenosynovitis [5,6]. The inoculation may be direct or hematogenous from an active or sleeping pulmonary or gastrointestinal source. It is necessary to systematically search for other tuberculous foci, mainly pleuropulmonary, but also in the bones, lymph nodes, or kidneys. In our patient, tenosynovitis was primitive, given that no other TB localization was identified. A recent study highlights possible *M. tuberculosis* transmission from environment to humans, comparing *M. tuberculosis* superfamilies isolated from soil and water to clinical isolates [7]. Some factors may play a role in tuberculous reactivation, including trauma in 30% of cases [4], forced labor, corticosteroid infiltration, immune depression (HIV infection and long-term corticosteroid treatment), alcoholism, or age (>60 years) [3,8]. Biological studies often reveal an inflammatory syndrome with elevated ESRs, which is a nonspecific indicator. Ultrasound is a useful tool for confirming diagnosis of tenosynovitis and discovery of its extension. It allows detection of increases in synovial-sheath volume as it forms a sleeve around the tendon, as well as tendon thickening or fluid collection [6]. Magnetic resonance imaging (MRI) is more powerful and sensitive than ultrasound, allowing visualization of typical granulomatous synovial-tendon sheaths in the intermediate T1 signal with enhancement by gadolinium and an hyperintense T2 signal. MRI is capable of detecting synovial proliferation, abscess formation, and destruction of adjacent bone, however, it is not easily accessible in some countries for socio-economic reasons [9,10]. Bacteriology is positive during direct examination in 20% of the cases and culture is negative in 35–45%. Gene-amplification methods using synovial fluid are more sensitive and allow rapid and specific detection of *M. tuberculosis* [3]. Absence of *M. tuberculosis* in culture should not refute the diagnosis.

Regarding histology, Kanavel (1923) [11] described three evolutionary stages: Stage 1 corresponds to a serous exudate, the second stage is characterized by granulation tissue with or without the appearance of “rice bodies” (in the case of our patient), and the third stage corresponds to fungosities associated with extensive caseous necrosis. The differential diagnosis of tuberculous tenosynovitis could result from an infection with other mycobacteria responsible for

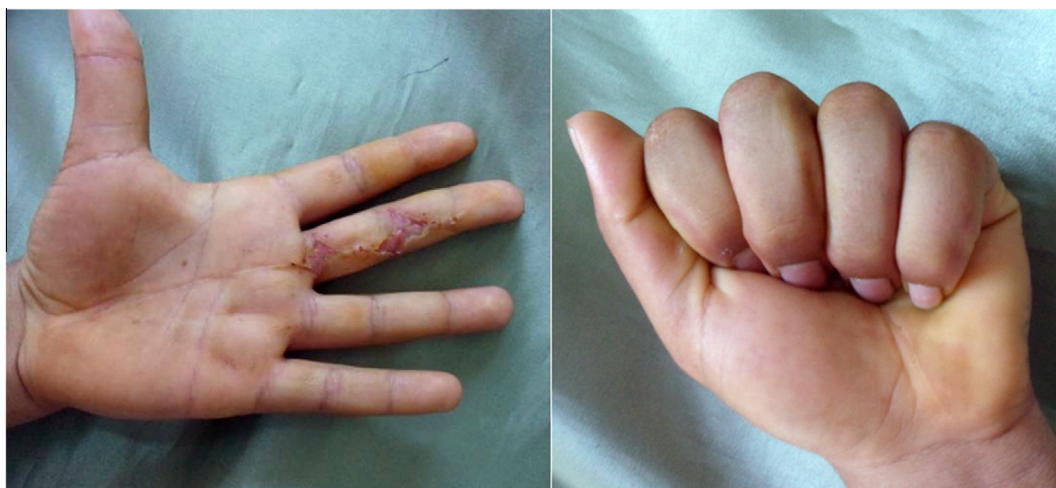

Fig. 4 – Good functional result with no recurrence.

granulomatous tenosynovitis, such as a fungal infection, brucellosis, tenosynovitis of foreign bodies, or sarcoidosis [3,4]. Once diagnosed, treatment is very simple and the patient usually heals with little or no sequelae. Antitubercular treatment is based on an initial quadruple therapy (associating isoniazid, rifampicin, pyrazinamide, and ethambutol) for 2 months. After 2 months and in the absence of resistance, the treatment is continued using a combination of isoniazid and rifampicin. The minimum duration of TB treatment in the bone and joint remains poorly defined.

According to the most recent US guidelines, treatment of musculoskeletal TB using rifampicin for 6–9 months was as effective as that excluding rifampicin for 18 months [12,13]. For our patient, the treatment period was only 8 months with positive results and without any recurrence within 3 years. The surgery is only considered for biopsy, drainage of necrotic extended lesions, or in the event of nerve compression.

Conclusion

Tuberculous infections of the hand, although rare, are still regularly encountered. They evolve in an insidious way with a poor clinical presentation and are difficult to diagnose at an early stage. Biological analysis, ultrasound, and MRI are useful methods to guide the diagnosis, but the final decision is usually made based on histological investigation. Treatment is based on antitubercular chemotherapy and may require surgery in some cases.

Patient consent and ethical approval

Written informed consent was obtained from the patient regarding publication of this case report and any accompanying images. A copy of the written consent is available for review. The study was approved by the institutional review board.

Conflicts of interest

None declared.

REFERENCES

- [1] M. Gabl, S. Pechlaner, H. Hausdorfer, et al, Flexor tenosynovitis in the hand caused by *Mycobacterium malmoense*: a case report, *J. Hand Surg. Am.* 22 (1997) 338–340.
- [2] H. Senda, H. Muro, S. Terada, Flexor tenosynovitis caused by *Mycobacterium arupense*, *J. Hand Surg. Eur.* 36 (2011) 72–73.
- [3] U.A. Walker, J. Gutfleisch, H.H. Peter, Case Number 23: tuberculous tenosynovitis, *Ann. Rheum. Dis.* 61 (2002) 384.
- [4] E. Ortiz, M.J. Moro, M. Diaz-Curiel, Chronic otitis and tenosynovitis in an elderly diabetic woman, *Postgrad. Med.* 75 (1999) 121–123.
- [5] B. Amine, K. Ben Bouazza, R. Bahiri, et al, Multifocal tuberculous tenosynovitis, *J. Bone Spine* 73 (2006) 474–475.
- [6] S. Jaovisidha, C. Chen, K.N. Ryu, et al, Tuberculous tenosynovitis and bursitis: imaging findings in 21 cases, *Radiology* 201 (1996) 507–513.
- [7] A.A. Velayati, P. Farnia, M. Mozafari, et al, Identification and genotyping of *Mycobacterium tuberculosis* isolated from water and soil samples of a metropolitan city, *Chest* 147 (2015) 1094–1102.
- [8] H. Lall, S.K. Nag, V.K. Jain, et al, Tuberculous extensor tenosynovitis of the wrist with extensor pollicis longus rupture: a case report, *J. Med. Case Rep.* 3 (2009) 142.
- [9] S.M. Lee, W.J. Lee, A.R. Song, Tuberculous tenosynovitis and ulnar bursitis of the wrist, *Ann. Rehabil. Med.* 37 (2013) 572.
- [10] E. Sueyoshi, M. Uetani, K. Hayashi, et al, Tuberculous tenosynovitis of the wrist: MRI findings in three patients, *Skeletal Radiol.* 25 (1996) 569–572.
- [11] A.B. Kanavel, Tuberculous tenosynovitis of the hand, *Surg. Gynecol. Obstet.* 37 (1923) 635.
- [12] American Thoracic Society, Center for disease control, infectious diseases society of America, treatment of tuberculosis, *Am. J. Respir. Crit. Care Med.* 167 (2003) 603–662.
- [13] E. Beam, S. Vasoo, P.J. Simner, et al, *Mycobacterium arupense* flexor tenosynovitis: case report and review of antimicrobial susceptibility profiles for 40 clinical isolates, *J. Clin. Microbiol.* 52 (2014) 2706–2708.