



Arthroscopic treatment of synovial chondromatosis in the ankle joint



Ahmet Ozmeric^a, Nevres Hurriyet Aydogan^a, Onur Kocadal^{a,*}, Talip Kara^a,
Murad Pepe^a, Serap Gozel^b

^a Department of Orthopaedics, Traumatology, Ankara Training, Research Hospital, Ankara, Turkey

^b Department of Pathology, Ankara Training and Research Hospital, Ankara, Turkey

ARTICLE INFO

Article history:

Received 6 May 2014

Received in revised form 22 October 2014

Accepted 23 October 2014

Available online 29 October 2014

Keywords:

Synovial chondromatosis

Osteochondromatosis

Ankle

Arthroscopic treatment

ABSTRACT

INTRODUCTION: Synovial chondromatosis is characterized by the presence of metaplastic cartilage nodules originating from the synovia, bursa and tendon sheaths. Although it is extremely rare in the ankle joint, malignant transformation is possible. The choice of treatment is usually open surgery for excision of loose bodies and synovectomy. Limited data is available concerning arthroscopic approaches.

PRESENTATION OF CASE: A 28-year-old male patient was evaluated for pain and swelling of the right ankle joint. Based on the findings of physical examination and radiographic investigations, arthroscopic surgery was performed due to ankle impingement syndrome. A diagnosis of synovial osteochondromatosis was made following the pathological survey.

DISCUSSION: Synovial chondromatosis is slowly progressive and is considered to be a self-limiting situation. Treatment strategies are decided on according to the patient's complaints, age and disease stage. Open or arthroscopic surgery can be performed. Some advantages of arthroscopic surgery are wide visualization areas, easy access to areas difficult to reach, lower morbidity, no necessity for casting and immobilization, early rehabilitation and quick recovery period.

CONCLUSION: In conclusion, arthroscopic management can be successful in selected patients with synovial osteochondromatosis localized to the ankle joint.

© 2014 The Authors. Published by Elsevier Ltd. on behalf of Surgical Associates Ltd. This is an open access article under the CC BY-NC-ND license (<http://creativecommons.org/licenses/by-nc-nd/3.0/>).

1. Introduction

Synovial chondromatosis is a disease with unknown etiology, originating from synovia and characterized by the presence of metaplastic cartilaginous nodules in the synovial cavities, bursa or tendon sheaths.¹ The disease is called synovial osteochondromatosis when the cartilaginous tissue is ossified. Ossification is not seen in approximately 45% of patients.² The disease is commonly seen in men and between the 3rd and 5th decades of life.³ Although the exact etiology is not known; embryologic remnants, infections and trauma are thought to play a role.⁴ The knee, hip and elbow joints are frequently reported to be involved by the condition. However, shoulder and ankle joints are involved extremely rarely.^{1,5–8}

The disease is classified in 3 stages and evaluated according to following criteria: the early stage with intrasynovial differentiation

without loose bodies, the transitional stage by intrasynovial cartilaginous nodules with loose bodies and late stage with multiple loose bodies.⁹ The treatment decision is made according to the patient's age, symptoms and the disease stage.

Nowadays, the arthroscopic approach is frequently preferred for ankle pathologies. The main advantages of the arthroscopic approaches are decreased morbidity, synchronous visualization and treatment feature for intra and extra articular pathologies. The hypertrophic synovia and multiple loose bodies are typical arthroscopic findings.¹⁰

In this case report, we presented an arthroscopically managed adult patient with anteriorly localized right ankle chondromatosis and discussed the potential benefits of arthroscopic surgery.

2. Presentation of case

A twenty-eight year old male patient was admitted to our hospital with decreased range of motion, swelling and increased pain during movement in the right ankle joint. He had experienced progressive pain with reduced range of motion for a year. He had no history of trauma, systemic inflammatory disease or family history

* Corresponding author at: Ankara Training, Research Hospital, Uluçanlar, Ankara, Turkey. Tel.: +90 5323364878.

E-mail address: onurkocadal@gmail.com (O. Kocadal).

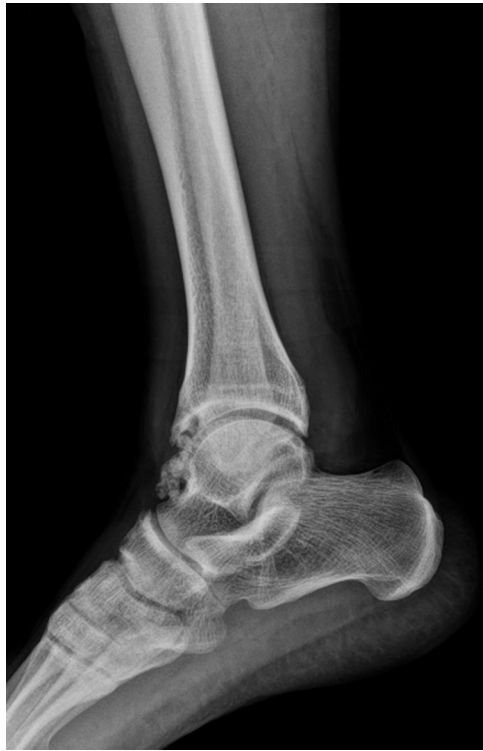

Fig. 1. The lateral plain radiographic image of the ankle joint. Multiple calcified foci are seen on the anterior aspect of the ankle joint.

of bone or joint diseases. The physical examination revealed that he had mild tenderness around the anterior ankle joint on palpation with palpable loose bodies. The plantar flexion and dorsiflexion angles were 25° and 5° , respectively. He had increased pain during dorsiflexion. No sign of instability appeared in the ankle joint. Multiple nodules 3–9 mm in diameter with calcifications were located at the anterior aspect of the right ankle on the plain anteroposterior and lateral X-ray images (Fig. 1). Magnetic resonance imaging (MRI) revealed multiple calcified well-circumscribed loose bodies at the same location and synovitis in the ankle joint (Fig. 2). The laboratory tests were within the normal limits and the patient was

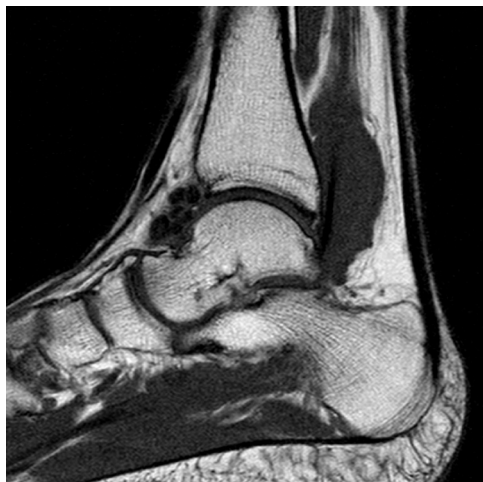

Fig. 2. The loose bodies are demonstrated on the anterior aspect of the ankle joint in the sagittal T1-weighted MRI.

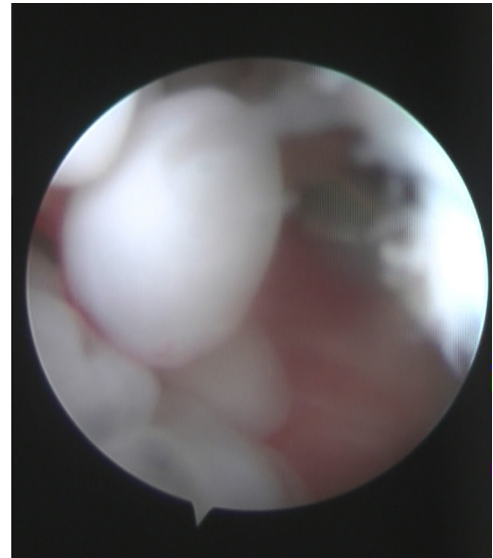


Fig. 3. Arthroscopic view of the anterior ankle compartment showing multiple loose bodies.

scheduled for arthroscopic surgery with the diagnosis of anterior impingement syndrome due to right ankle synovial chondromatosis.

The ankle joint was entered via anteromedial and anterolateral arthroscopic portals during spinal anesthesia and tourniquet application. Multiple loose bodies and hypertrophic synovia around the anterior ankle joint were seen (Fig. 3). Arthroscopic partial synovectomy and excision of loose bodies were performed (Fig. 4). The portals were closed primarily after drain insertion. A compressive bandage was applied. The drain was removed in the 1st postoperative day and the active and passive range of motion exercises was started. The patient was allowed partial weight bearing with crutches and at the 2nd week he was mobilized with full weight.

There were multiple cartilaginous loose bodies, with the biggest and smallest dimensions of $0.9\text{ cm} \times 0.7\text{ cm} \times 0.5\text{ cm}$ and $0.4\text{ cm} \times 0.3\text{ cm} \times 0.2\text{ cm}$ in the permanent pathology report respectively (Fig. 5).

The patient's dorsiflexion and plantar flexion degrees were 25° and 30° , respectively, at the end of the 11th postoperative month. No complications were diagnosed in the follow-up period with no recurrence on the plain X-ray images and MRI.

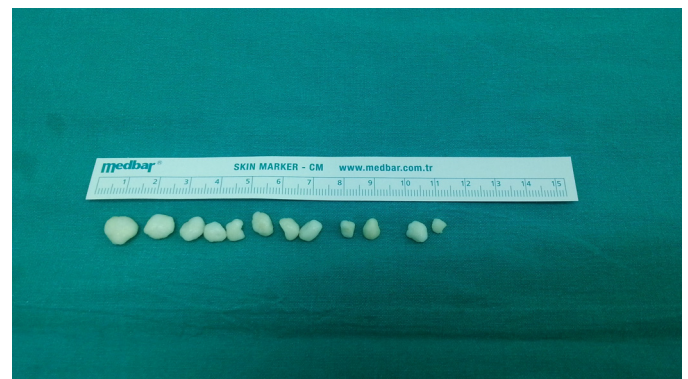

Fig. 4. The macroscopic appearance of the loose bodies after arthroscopic excision.

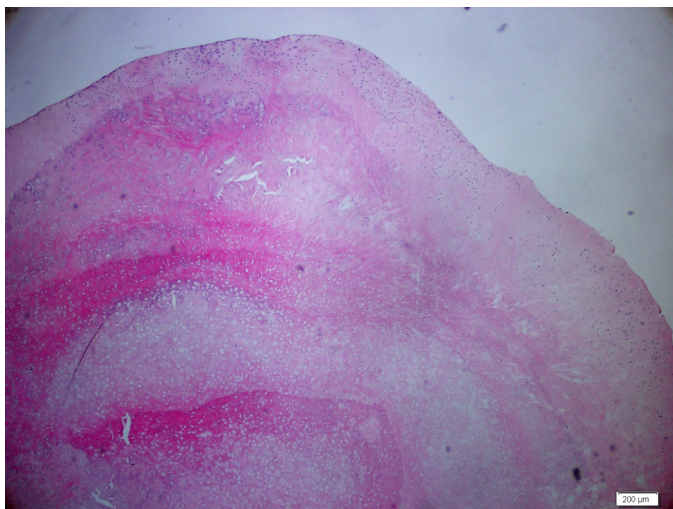


Fig. 5. Cartilage proliferation is diagnosed during histopathologic evaluation of loose bodies with Hematoxylin–Eosin dye.

3. Discussion

Synovial chondromatosis is a disease composed of benign synovial metaplasia and multiple loose bodies. The disease is classified as primary or secondary.⁵ The primary one is characterized by undifferentiated stem cell proliferation of stratum synoviale.¹¹ Trauma, degenerating joint diseases, osteochondritis dissecans, rheumatoid arthritis and tuberculosis arthritis are examples of the secondary form.¹² Our case was evaluated in the primary synovial osteochondromatosis group due to the absence of previous trauma or inflammatory pathologies.

Complaints of pain, swelling of the joint (especially after physical activity) with or without accompanying pain, decreased range of motion, palpable mass, locking paresthesias and joint clicking are main symptoms and signs in patients with synovial chondromatosis.⁵ The suspected diagnosis was confirmed by the appropriate radiologic investigations and pathologic examination after history taking and physical evaluation. The calcified form synovial osteochondromatosis could be seen in the anteroposterior and lateral plain X-ray images. MRI investigation enabled the diagnosis of the disease in the early stage, the exact localization of the disease and intrinsic property of chondroid tissue.¹³ The tenosynovial giant cell tumor, calcifying aponeurotic fibroma, periosteal chondroma, osteocartilaginous loose bodies and soft tissue chondrosarcoma must be kept in mind in the differential diagnosis.¹⁴

The disease is slowly progressive and is considered to be a self-limiting condition.¹⁵ In the early stages of the disease and in asymptomatic patients, treatment can be planned conservatively with frequent follow-up visits.¹⁶ Degenerative changes could occur in the later stages of the disease in patients without appropriate therapy.¹⁷ Symptomatic patients and younger patients are treated surgically.⁴

Although the classical treatment approach for ankle joint chondromatosis is open surgery,^{15,18} arthroscopic surgery is rarely encountered in the literature.^{6,10} Some important advantages of arthroscopic surgery are wide visualization areas, easy access to difficult to reach areas, lower morbidity, no need for casting and immobilization, early rehabilitation and quick recovery period.¹⁰ However, there is the possibility of limited synovectomy and residual loose bodies. The excision of the loose bodies is the standard arthroscopic treatment with synovectomy.⁶ It was suggested in the literature that synovectomy might decrease the transformation into malignancy.⁶

4. Conclusion

In conclusion, arthroscopic management was the successful in selected patients with synovial osteochondromatosis. Arthroscopic surgery enables wide regional visualization, lowers morbidity, promotes early rehabilitation, shortens the recovery period and decreases the immobilization period.

Conflict of interest

None.

Funding

None.

Ethical approval

Written informed consent was obtained from the patient for publication of this case report and accompanying images. A copy of the written consent is available for review by the Editor-in-Chief of this journal upon request.

Author contributions

Nevres Hurriyet Aydogan, Ahmet Ozmeric, Onur Kocadal, Murad Pepe, Talip Kara took part in surgical procedure, literature search, preparation of the paper and review. Serap Gozel took part in pathological investigation.

Key learning points

- Synovial chondromatosis is a disease originating from synovia and characterized by the presence of metaplastic cartilaginous nodules.
- Pain, swelling of the joint especially after physical activity and decreased range of motion are main symptoms.
- Treatment is arranged according to the patient's complaints, age and disease stage.
- There are many advantages of arthroscopic surgery in selected patients.

References

1. Wiedemann NA, Friederichs J, Richter U, et al. Secondary synovial chondromatosis of the ankle joint. *Orthopade* 2011;**40**:807–11.
2. Davis RI, Hamilton A, Biggart JD. Primary synovial chondromatosis: a clinicopathologic review and assessment of malignant potential. *Hum Pathol* 1998;**29**:683–8.
3. Lee DK, Louk Jr L, Bell BL. Synovial osteochondromatosis involvement in post-traumatic ankle injury. *J Am Podiatr Med Assoc* 2008;**98**:70–4.
4. Young-In Lee F, Hornicek FJ, Dick HM. Synovial chondromatosis of the foot. *Clin Orthop Relat Res* 2004:186–90.
5. Shearer H, Stern P, Brubacher A. A case report of bilateral synovial chondromatosis of the ankle. *Chiropr Osteopat* 2007;**15**:18.
6. Bojanic I, Bergovec M, Smoljanovic T. Combined anterior and posterior arthroscopic portals for loose body removal and synovectomy for synovial chondromatosis. *Foot Ankle Int* 2009;**30**:1120–3.
7. Murphey MD, Vidal JA, Fanburg-Smith JC. Imaging of synovial chondromatosis with radiologic–pathologic correlation. *Radiographics* 2007;**27**:1465–88.
8. Aydogan NH, Kocadal O, Ozmeric A. Arthroscopic treatment of a case with concomitant subacromial and subdeltoid synovial chondromatosis and labrum tear. *Case Rep Orthop* 2013;**2013**, <http://dx.doi.org/10.1155/2013/636747>. Article ID 636747.
9. Milgram JW. Synovial osteochondromatosis: a histopathological study of thirty cases. *J Bone Joint Surg Am* 1977;**59**:792–801.
10. Doral MN, Uzumcugil A, Bozkurt M. Arthroscopic treatment of synovial chondromatosis of the ankle. *J Foot Ankle Surg* 2007;**46**:192–5.
11. Leu JZ, Matsubara T, Hirohata K. Ultrastructural morphology of early cellular changes in the synovium of primary synovial chondromatosis. *Clin Orthop Relat Res* 1992:299–306.
12. Chillemi C, Marinelli M, de Cupis V. Primary synovial chondromatosis of the shoulder: clinical, arthroscopic and histopathological aspects. *Knee Surg Sports Traumatol Arthrosc* 2005;**13**:483–8.
13. Walker EA, Murphey MD, Fetsch JF. Imaging characteristics of tenosynovial and bursal chondromatosis. *Skeletal Radiol* 2011;**40**:317–25.
14. Fetsch JF, Vinh TN, Remotti F. Tenosynovial (extraarticular) chondromatosis: an analysis of 37 cases of an underrecognized clinicopathologic entity with a strong predilection for the hands and feet and a high local recurrence rate. *Am J Surg Pathol* 2003;**27**:1260–8.
15. Iossifidis A, Sutarina PD, Pinto T. Synovial chondromatosis of the ankle. *The Foot* 1995;**5**:44–6.
16. Yu GV, Zema RL, Johnson RW. Synovial osteochondromatosis. A case report and review of the literature. *J Am Podiatr Med Assoc* 2002;**92**:247–54.
17. Abolghasemian M, Gharanizadeh K, Kuzyk P. Hips with synovial chondromatosis may display the features of femoroacetabular impingement. *J Bone Joint Surg Am* 2014;**96**:e11.
18. Galat DD, Ackerman DB, Spoon D. Synovial chondromatosis of the foot and ankle. *Foot Ankle Int* 2008;**29**:312–7.

Open Access

This article is published Open Access at sciedirect.com. It is distributed under the [IJSCR Supplemental terms and conditions](#), which permits unrestricted non commercial use, distribution, and reproduction in any medium, provided the original authors and source are credited.