

CONTINUING EDUCATION PROGRAM: FOCUS...

Perfusion in ENT imaging



S. Espinoza*, D. Malinvaud, N. Siauve, P. Halimi

Georges-Pompidou European Hospital, 20, rue Leblanc, 75015 Paris, France

KEYWORDS

Perfusion MRI;
Perfusion CT;
Salivary gland
tumors;
ENT cancers

Abstract Perfusion MRI is an essential part of characterizing salivary gland tumors. The shape of the curves can provide a guide as to the type of lesion: benign (ascending plateau) or malignant (descending plateau), and can also occasionally strongly suggest a histological type such as a Warthin tumor (intense, rapid contrast enhancement with washout > 30%). Perfusion imaging (CT or MRI) for other head and neck tumors is currently being developed and is being assessed. It should be a tool to assist in choosing the most appropriate initial treatment (chemotherapy, radiotherapy or surgery) and should also allow poor responders to conservative treatment to be identified and recurrences to be detected in post-treatment damaged tissues. Aims: (a) to determine when to perform perfusion MRI; (b) to determine the type of perfusion to carry out: CT, T1-weighted MRI; (c) to determine how to position the region of interest to plot the perfusion curve; (d) to know how to interpret MRI curves for salivary gland tumors; (e) to know how to interpret the information obtained from perfusion CT or MRI for the upper aerodigestive tract.

© 2013 Éditions françaises de radiologie. Published by Elsevier Masson SAS. All rights reserved.

Perfusion imaging, with CT or MRI, can provide non-invasive access to the microcirculatory features of tissue lesions. The two methods which can be used in ENT imaging are CT perfusion and T1-weighted perfusion MRI.

Clinicians' requirements differ depending on the disease and the related problems in treating them which are raised. Perfusion methods seek to answer these practical patient care problems. They therefore have differing merits, depending on the type and site of the head and neck tumor.

The question faced by the surgeon for a salivary gland tumor is whether to operate or not. The answer to this depends on the type and site of the lesion. We will see that perfusion MRI provides what have become essential answers for the surgeon from the initial diagnostic and pre-treatment assessment.

* Corresponding author.

E-mail address: sophie.espinoza@gmail.com (S. Espinoza).

The questions which clinicians currently face with upper aerodigestive tract tumors (UADT) are related to the complex nature of the treatments which are available. These include chemotherapy and radiotherapy, and possibly both (conservative treatment) or surgery. Surgery may be carried out first line or as a salvage procedure after conservative treatment has failed. ENT surgery is often mutilating and raises two problems, one functional (voice and swallowing) and the other aesthetic. Organ preservation protocols are therefore becoming more popular and are becoming increasingly complex, in order to avoid initial mutilating surgery. It is essential, therefore, to be able to distinguish those patients who will benefit from conservative treatment from those who need surgery. The following problems arise:

- can we predict which patients will benefit from a conservative radiochemotherapy approach from the initial CT or MRI investigation before any treatment is offered? Also, it is possible to predict which patients who, on the other hand, will not respond and will benefit from surgery from the beginning? Salvage surgery is extremely difficult, particularly after radiotherapy, and carries a high risk of complications and local failure. It is therefore very important to identify, wherever possible from the start, which patients need surgery as, although it is mutilating, initial surgery carries less risk and offers a greater chance of local control of the disease when it is performed first line;
- is it possible to predict the response to conservative treatments (radiotherapy, chemotherapy or a combination of both), in order to determine the optimal treatment on an individual case basis? Do we have information to suggest that a patient will respond well, and what is the patient's likelihood of achieving a complete response after conservative treatment?
- can we objectively quantify and monitor the response to conservative treatments?
- can we detect poor responders to conservative treatment early? In particular, can we detect poor responders to radiotherapy and then stop the radiotherapy, to direct the patient to surgery more quickly?
- can we detect recurrences after treatment early, and distinguish these from inflammatory changes or radiation necrosis?
- can we obtain information which would allow us to optimally assess lymph nodes under a centimeter in size so that the lymph nodes are only removed if they are genuinely diseased?

We shall examine the following issues in succession in this article:

- routine perfusion MRI techniques which are essential for characterizing salivary tumors, in order: to establish when to perform a perfusion sequence, to decide what type of perfusion to perform, how to acquire and analyze the images, how to position the regions of interest and how to plot the perfusion curve in significant areas and be able to interpret the MRI curves to characterize salivary gland tumors;
- techniques which are currently being developed and assessed using CT and MRI for UADT carcinomas, in order: to establish when to carry out a perfusion sequence, to

know which technique to use and to be able to interpret functional parameters from perfusion imaging.

Perfusion imaging for salivary gland tumors

General details

MRI has become an essential further investigation for any space-occupying lesion in a salivary gland. Salivary gland tumor pathology is complicated and includes a large variety of lesions.

In decreasing order of frequency, the salivary gland tumors include:

- benign tumors which, do however need to be excised surgically because of the risk of malignant degeneration: this is the case for pleomorphic adenomas;
- benign tumors which usually do not need any surgery: this is the case for Warthin tumors which are not treated surgically provided that formal evidence of the tumor is obtained by fine needle aspiration and MRI. They are then only treated surgically for aesthetic or comfort reasons;
- low-, intermediate- or high-grade malignant tumors which always require surgical excision: muco-epidermoid squamous cell carcinomas, cystic adenoid carcinomas, adenocarcinomas, squamous cell carcinomas, and undifferentiated carcinomas;
- malignant tumors which require systemic therapy: lymphomas;
- rare benign tumors which do not require surgery: branchial cysts, HIV lympho-epithelial cysts, oncocytomas, hemolymphangiomas and lipomas.

The first question the surgeon needs to answer is therefore whether or not he/she needs to operate. One of the merits of MRI and fine needle aspiration is that they have allowed us to avoid always resorting to surgery to establish the type of lesion. The second question the surgeon faces is the risk of malignancy. In parotid tumors, surgeons also want to assess the risk to the facial nerve. In this case, the aims of MRI are to determine the exact site of the lesion and to provide information in order to characterize it, to assist the surgeon in his/her decision of whether or not to operate and to help him to warn patients of the increased risk of temporary or permanent postoperative facial paralysis if malignant disease is assumed from MRI findings.

In this situation, perfusion MRI provides essential information for preoperative characterization of salivary gland lesions, provided that it is performed and interpreted rigorously.

Technique and image processing

The aim of MRI investigation of a salivary gland lesion is to determine the site, size, margins and T1- and T2-weighted signal characteristics of the lesion (without fat saturation). It has now been clearly established that diffusion imaging is essential and provides information about the cellularity of the lesion and its malignant potential [1–3]. However, the diagnostic accuracy of diffusion-weighted MRI either alone or combined with conventional T1- and T2-weighted sequences is inadequate [4]. This ‘‘conventional’’

approach has particular failings in Warthin tumors and cellular pleomorphic adenomas, both of which can contain a hypercellular component with nodules which greatly reduces diffusion, incorrectly suggesting a malignant tumor which requires surgical excision. As we have seen above, Warthin tumors do not require surgery as they carry no risk whatsoever of malignant degeneration. With cellular pleomorphic adenomas, even if surgery is required, the risk to the facial nerve and the prognosis are different from those of malignant tumors.

Although conventional sequencing and diffusion can be ineffective for Warthin tumors and cellular pleomorphic adenomas, it has now been clearly established that they have highly suggestive and specific enhancement features on T1-weighted perfusion [5,6].

A full investigation of a salivary gland tumor must, therefore, include T1-weighted perfusion MRI sequences in addition to the conventional T1-, T2-weighted and diffusion-weighted sequences [2,7,8].

We shall not describe the T1 perfusion technique here and refer the reader to the techniques chapter.

We would like simply to draw readers' attention to a few specific features of salivary gland imaging:

- it is very important to tell the patient that they must not swallow;
- the FOV must be suitable for the cervical region: a small FOV, i.e. 28 cm;
- the matrix also needs to be increased: 192 × 192;
- section thickness must be suitable for the anatomical region: 4 mm.

A detailed acquisition protocol is proposed in [Boxed text 1](#).

In image processing, it is important to understand that salivary gland tumors are heterogeneous and made up of different components (greater or lesser cell density, a myxoid component, a calcified component and a more or less hemorrhagic fluid content). T1- and T2-weighted signals and diffusion restriction and contrast enhancement vary according to the type of these different components. The choice of the region of interest in which the perfusion curve is constructed (and similarly measurement of the apparent rADC diffusion coefficient) is therefore fundamental:

- clearly the perfusion curve should not be plotted for a non-tissue portion which does not enhance. Hemorrhagic areas or those made up of high protein content fluid which

are hyperintense on an unenhanced T1 sequence are seen very commonly in Warthin tumors and must therefore be excluded ([Fig. 1](#)). It is also essential not to place the region of interest in necrotic areas, which are hyperintense on T2 and produce variable signals on T1 sequences. These are common in malignant tumors. It is also important to be aware of calcified acellular areas or those made up of a myxoid matrix, which are very common in paucicellular pleomorphic adenomas;

- therefore, it is preferable to use areas which are hypointense on T2 and not hyperintense on T1 sequences in order to determine the position of the region of interest ([Fig. 2](#)).

Finally, as contrast is used, we suggest that the investigation be completed by T1-weighted sequences with fat saturation after contrast injection.

Interpretation of MRI images

In light of the above, MRI characterization of a salivary gland tumor should incorporate all of the anatomical, signal and functional information (diffusion and perfusion) which it provides [9].

Morphology of the lesion

The size and position of the lesion (superficial or deep part of the gland), relationships with the stylomastoid foramen and the retrocondylar veins (which are a marker for the path of the facial nerve), well or poorly demarcated outlines and any potential extension to the subcutaneous tissues (particularly fat) and masseter muscle should be reported. The report should state the presence or absence of a contralateral lesion (suggestive of Warthin's tumor or lymph nodal tumors). Lymphadenopathy in zone II should also be investigated.

Signal from the lesion

T1: the main benefit of this sequence is that it allows us to investigate for an unenhanced T1 hyperintensity in the lesion. These T1 hyperintensities are due to a protein component within the lesion or the presence of blood, both of which suggest a diagnosis of Warthin's tumor,

Boxed text 1 Acquisition parameters for MR perfusion sequence.

MR perfusion sequence

Injection: 0.2 mmol/kg via a power injector at a rate of 4 mL/s, followed by injection of 20 mL of normal saline

SPGR 3D; 8 slices

Section thickness: 4 mm

40 phases

Temporal resolution: 3–4 s

Matrix: 192 × 192

FOV: 28 cm

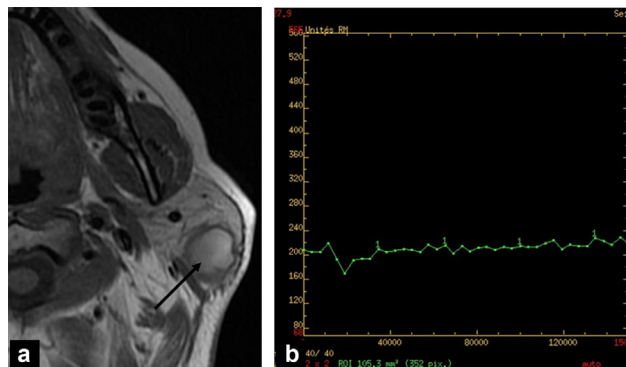


Figure 1. Incorrect choice of the position of the region of interest (ROI). a: axial T1-weighted MRI: unenhanced T1 hyperintensity (black arrow) representing bleeding within the lesion; b: uninformative, flat perfusion curve.

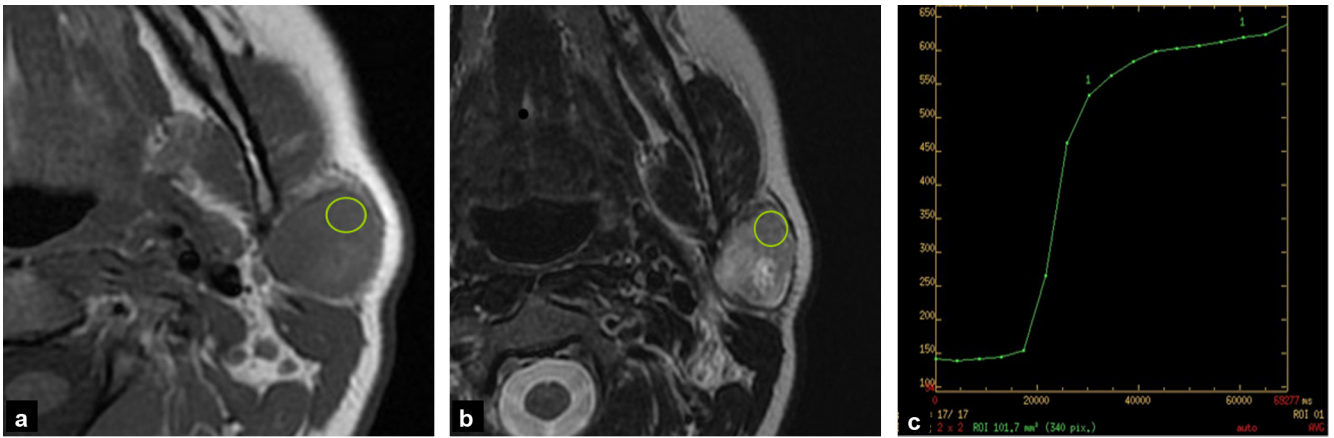


Figure 2. Correct choice of the position of the region of interest. a: axial T1-weighted MRI; b: axial T2-weighted MRI. Green ROI positioned in the tissue portions which are hypointense on T1- and T2-weighted sequences. c: informative enhancement curve.

even if they are limited to within the lesion. Also, it is important to identify these areas before contrast enhancement in order not to be misled by increased uptake and to centre the perfusion sequence away from these areas (Fig. 1).

T2 sequence without fat saturation: this sequence is used to study the signal from the lesion compared to the healthy parotid parenchyma. A strong T2 hyperintensity compared to the healthy parotid parenchyma suggests a benign tumor (pleomorphic adenoma, Fig. 3). An intermediary T2-weighted signal may represent either a cellular pleomorphic adenoma (Fig. 4a), or an intermediary-grade malignant tumor (Fig. 4b). A strong T2 hypointensity compared to the healthy parenchyma suggests a malignant tumor (Fig. 5).

In a diffusion-weighted sequence with rADC measurement, the signal from the lesion should be compared to the healthy neighboring or contralateral parotid parenchyma and the result expressed as an apparent diffusion coefficient ratio (rADC) compared to the healthy parenchyma (tumor ADC/healthy parotid ADC). A strong hyperintense tumor on a diffusion-weighted sequence with an apparent diffusion coefficient ratio of over 1.3 suggests a benign pleomorphic adenoma (Fig. 6b) whereas a tumor with an apparent

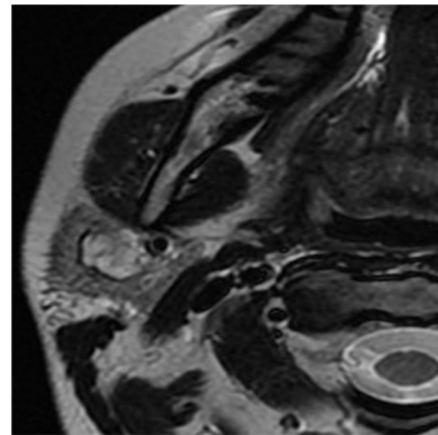


Figure 3. Hyperintense T2 signal. T2 axial MRI: right intraparotid tumor with a pronounced T2-weighted hyperintensity which is greater than the glandular parenchyma and suggestive of a pleomorphic adenoma.

diffusion coefficient ratio of over 1.3 suggests a benign pleomorphic adenoma (Fig. 6b). An ADC ratio of between 1 and 1.3 may represent either a cellular pleomorphic adenoma or an intermediary-grade malignant tumor (Fig. 6c).

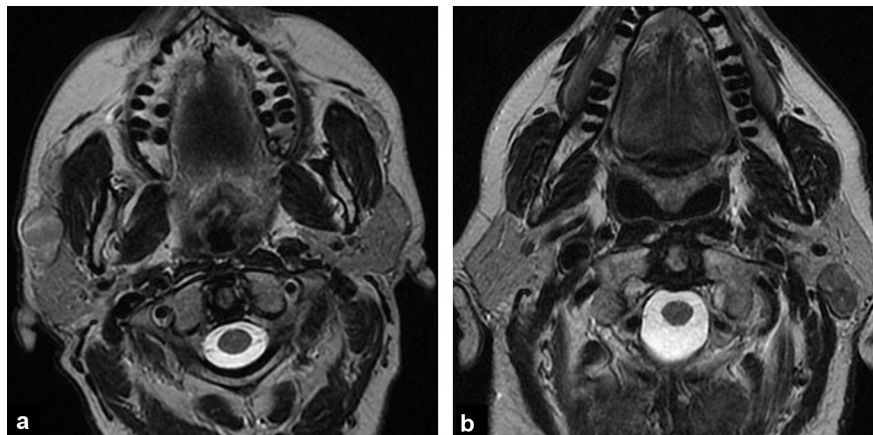


Figure 4. Intermediary T2-weighted signal. a: axial T2-weighted MRI: intermediary T2 signal from a right parotid cellular pleomorphic adenoma; b: axial T2-weighted MRI: intermediary T2 signal from an intermediary-grade malignant left parotid tumor.

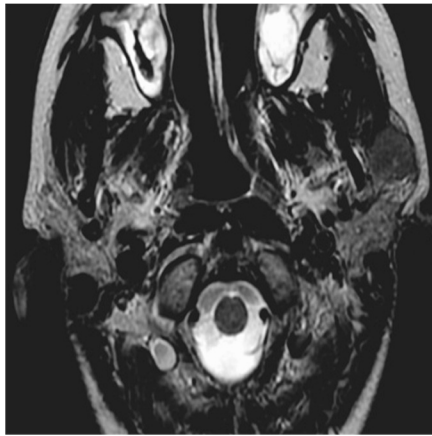


Figure 5. Low T2 signal. Axial T2-weighted MRI: pronounced hypointense T2 sequence compared to the normal glandular parenchyma, suggestive of a high-grade malignancy tumor.

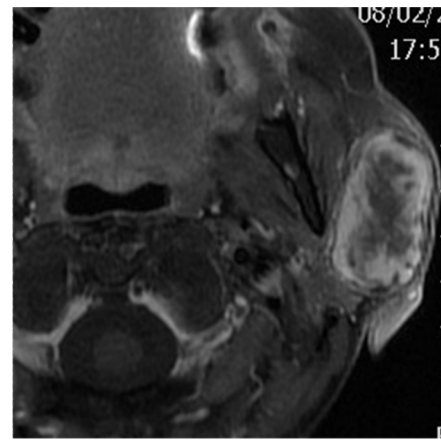


Figure 7. Necrotic area in the tumor. Axial T1-weighted MRI after gadolinium with fat saturation, showing a large central portion which does not enhance. This lesion is very difficult to characterize in a perfusion sequence because of the extensive cystic changes which make unequivocal positioning of the ROI difficult in principle (before injection) in a part of the tissue.

In a T1-weighted sequence after gadolinium injection and fat saturation, the investigation can clearly demarcate the lesion and also distinguish cystic and necrotic components which do not enhance (Fig. 7), which should be excluded retrospectively from the ROI in calculating the rADC and in tracing the perfusion curve – tissue components which enhance late and can be used to calculate the rADC and to obtain the perfusion curve.

Finally, the enhancement curve from the perfusion sequence: on this type of T1-weighted perfusion sequence, a pleomorphic adenoma (regardless of its cellularity) has extensive contrast uptake with an ascending plateau (Fig. 8a), a Warthin tumor has intense and rapid contrast uptake with a high washout of over 30% (Fig. 8b) and intermediary-grade malignant tumors have intense contrast uptake with a horizontal or descending plateau but a washout of under 30% (Fig. 8c).

The place and limitations of perfusion MRI

It has now been clearly established that MRI for the investigation of a salivary gland tumor should include a T1-weighted perfusion sequence with recording of the enhancement curve and that these should be interpreted jointly, taking account of all of the information provided.

Perfusion MRI alone is insufficient for:

- tumors containing a largely cystic component in which positioning the region of interest is difficult or impossible (Fig. 1). rADC measurement has the same limitations in this situation;
- the specificity of the three types of curves obtained is extremely high, but is not pathognomonic for a histological type of tumor (it has a specificity of 80 to 91% for malignancy detection and 90 to 100% for a Warthin tumor) [5];

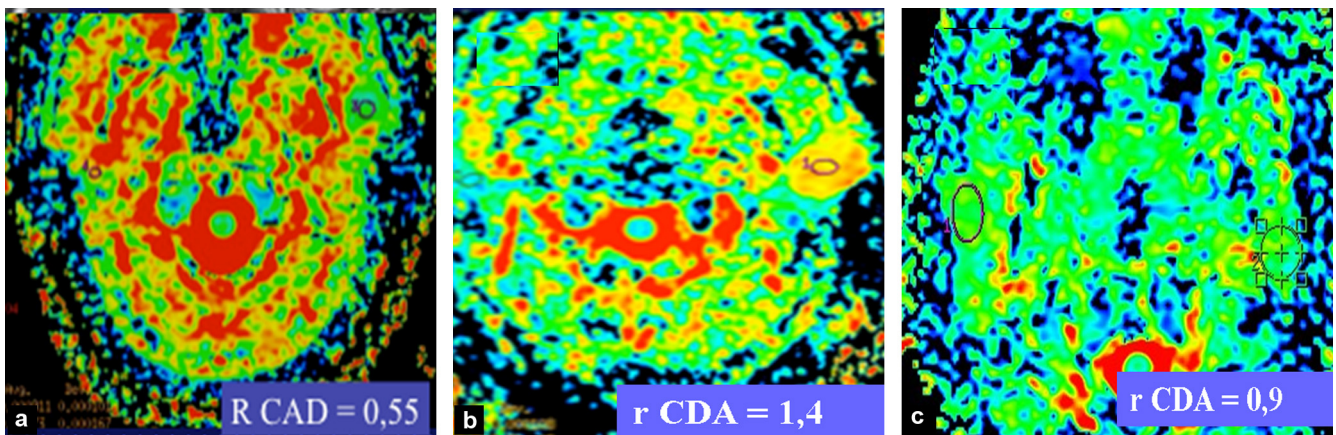


Figure 6. Diffusion mapping with rADC measurement in 3 different patients. a: diffusion mapping showing a very low ADC ratio between the tumor and normal parotid (0.55) suggestive of a malignant tumor; b: diffusion mapping showing a very high ADC ratio between the tumor and normal parotid (1.4) suggestive of a benign pleomorphic adenoma tumor; c: diffusion mapping showing an intermediary ADC ratio between the tumor and normal parotid (0.9) which may represent either a cellular pleomorphic adenoma or an intermediary-grade malignant tumor.

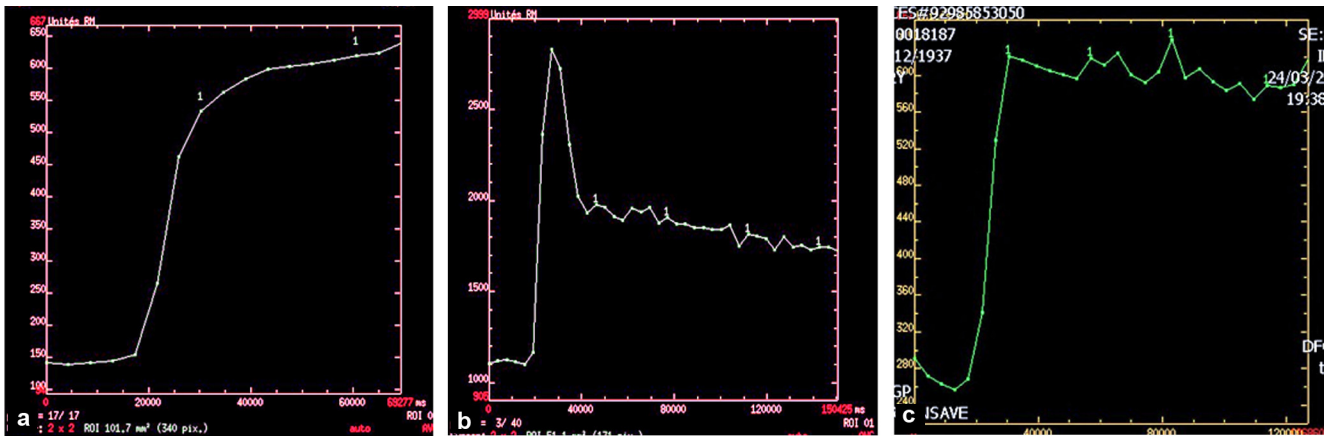


Figure 8. The three possible perfusion curves: a: ascending plateau: curve suggestive of a benign pleomorphic adenoma tumor; b: peak with washout more than 30% typical of a Warthin tumor; c: descending plateau with washout less than 30%: this curve is suggestive of a malignant tumor.

- tumors under 10 mm in size are difficult to characterize on perfusion MRI, although they are also difficult in general even when all of the sequences are considered, because of their small size and probably also because they do not yet express a sufficient number of functional components.

- a perfusion sequence with recording of the enhancement curve.

If it does not, the investigation does not provide all of the essential information to characterize the lesion, and reduces its diagnostic accuracy.

As a result, a salivary gland MRI investigation should contain the following three features:

- a T2-weighted sequence without fat saturation;
- a diffusion-weighted sequence with measurement of the ADC ratio;

Interpretation algorithm

This is shown in Fig. 9.

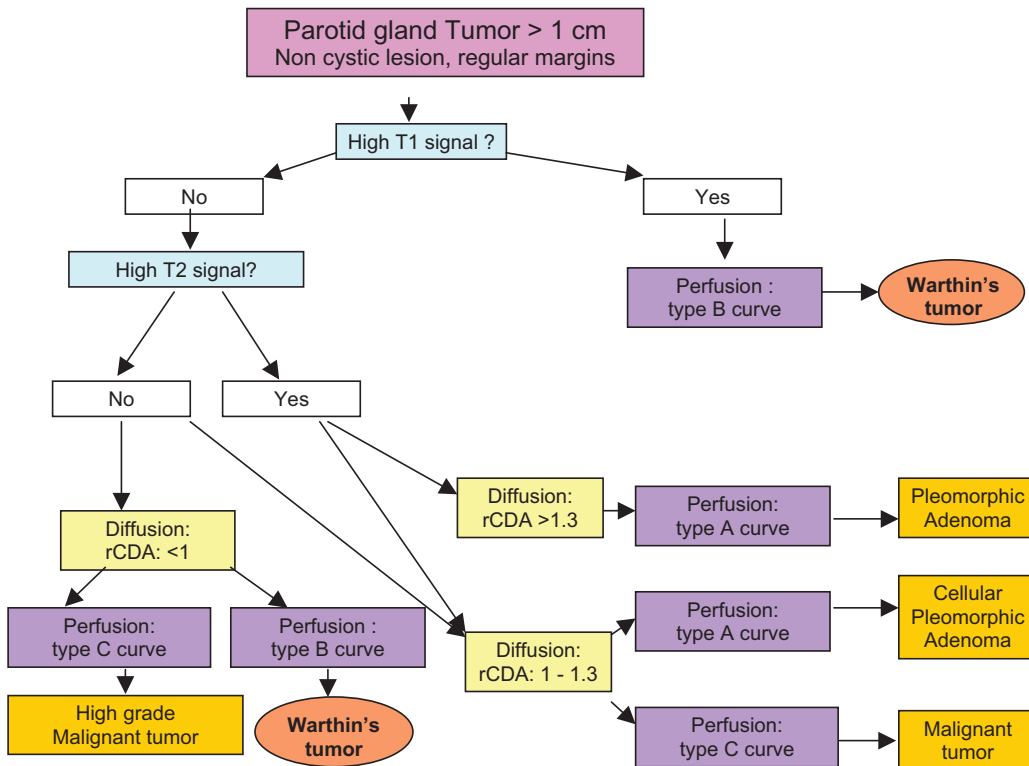


Figure 9. Algorithm used for MRI interpretation.

Diagnosis

The diagnosis should be made consistent with the features of the lesions which are shown in [Table 1](#) and in [Figs. 10–14](#).

Summary

An MRI for the investigation of a salivary gland tumor should contain a T1-weighted perfusion sequence. However,

this sequence alone is not sufficient and the interpretation should incorporate anatomical features, a T2 sequence without fat saturation, the apparent diffusion coefficient ratio (rADC) and the lesion's T1 enhancement curve.

When these procedures are carried out, MRI can predict the histological diagnosis of parotid lesions in over 80% of cases.

Table 1	Diagnostic criteria.			
	T2	ADC ratio	Perfusion	Others
Whartin's tumor	Hypo or Iso	0.8–1	Wash-out > 30%	HighT1 Bilateral Inferior part Man > 50 y Smoker
Pleomorphic adenoma	High	> 1.3	Ascending plateau	
Cellular pleomorphic adenoma	Iso	1–1.3	Ascending plateau	
Malignant tumor: low grade	Iso or Hypo	1–1.3	Wash-out < 30%	
Malignant tumor: high grade	Hypo	< 1	Descending plateau	Ill-defined margins

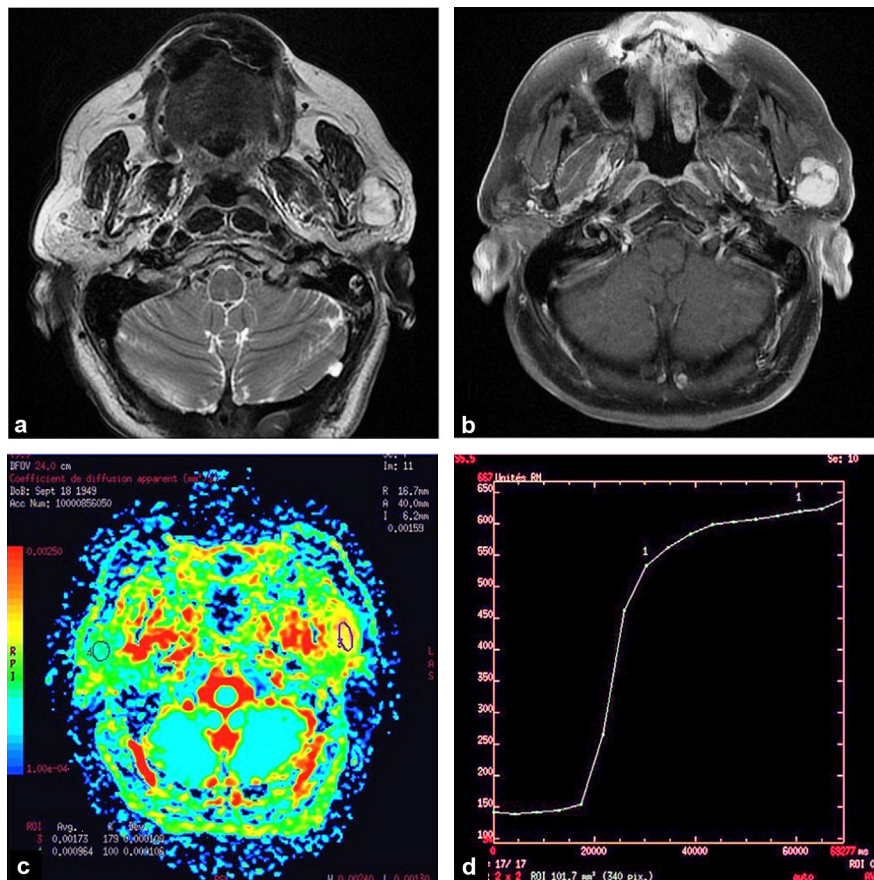


Figure 10. Typical pleomorphic adenoma. Tissue structure in the superficial part of the left parotid gland, measuring 35 mm in size. a: axial T2-weighted MRI: the lesion shows a pronounced hyperintense signal; b: axial T1-weighted MRI with gadolinium and fat saturation: intense contrast enhancement; c: mapping the apparent diffusion coefficient: rADC = 1.7; d: perfusion curve showing intense enhancement, with an ascending plateau.

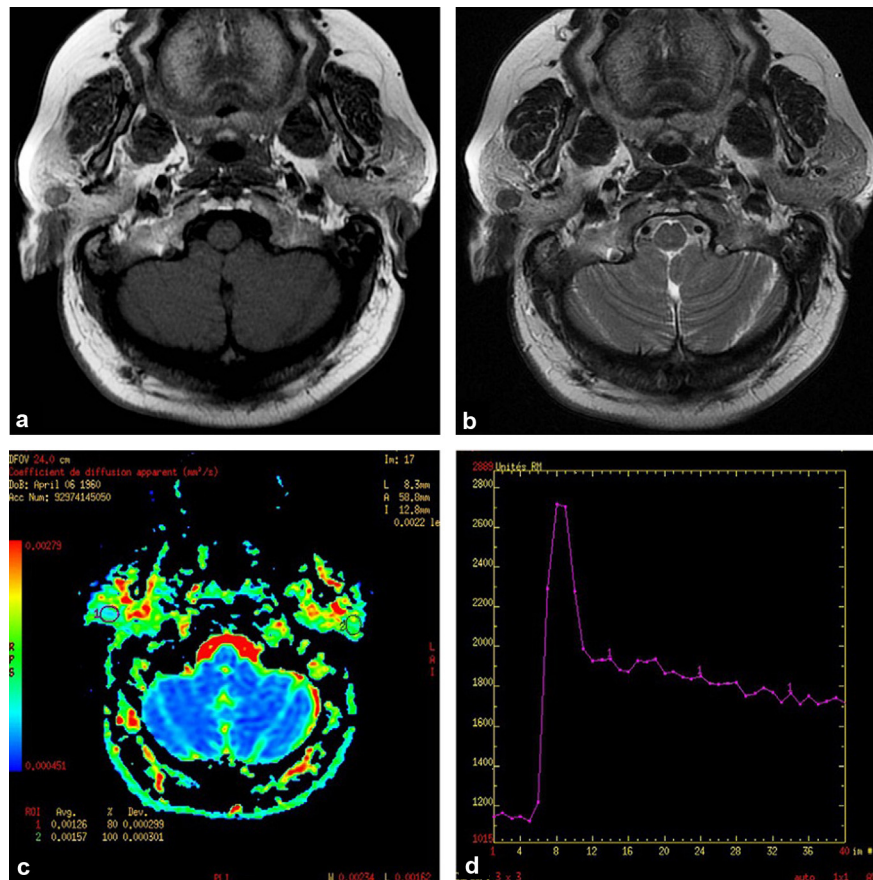


Figure 11. Typical Warthin tumor. Tissue lesion a centimeter in size in the superficial part of the right parotid gland. a: axial T1-weighted MRI: the lesion contains small hyperintense spots without enhancement on the T1-weighted MRI; b: axial T2-weighted MRI: the lesion is hypointense on the T2-weighted sequence; c: mapping of the apparent distribution coefficient: $rADC = 0.8$; d: perfusion curve showing rapid intense contrast enhancement with a washout of over 30%.

Perfusion imaging for UADT cancers

General details

Until now, the choice of ENT oncology treatments has been based on cohort studies' statistics. The recent development of targeted molecules and the wide range of treatments which are now available (chemotherapy, radiotherapy and surgery) make it essential to develop tools with three objectives:

- to predict whether a given tumor is or is not likely to respond to a particular type of non-surgical treatment;
- to monitor and assess response during treatment in order to adjust the treatment as soon as possible. If a patient fails to respond adequately or does not respond to treatment, early detection of the treatment failure allows the care to be changed. This may involve increasing the doses of chemotherapy or radiotherapy or adding adjuvant chemotherapy. It may also involve switching sooner to surgery: whilst this is definitely mutilating, it is more likely to achieve satisfactory local control and a lower likelihood of complications if it is carried out on non-irradiated tissue;
- to detect the presence of residual tumor or a recurrence after conservative treatment as early as possible, in order to organize salvage surgery as soon as possible.

The imaging questions which arise at present are not therefore only anatomical ones but are increasingly functional (such as detection of viable malignant tissue within the scarred tissue). The main purpose of this is to increase local control and survival, at the same time reducing treatment-related complications. This is the context in which perfusion imaging (CT or MRI) is being developed for UADT carcinomas, and in which this new technique is being assessed.

Perfusion imaging provides non-invasive access to the microcirculatory properties of tumors. The perfusion sequence, both in CT and MRI, can be used to calculate microcirculatory parameters which reflect tumor microvascularization. Both CT and MRI can quantify whether the temporal resolution and acquisition time are sufficient, together with tissue blood flow (TBF), tissue blood volume (TBV), mean transit time (MTT) and surface permeability (SP) [10–16].

In the following sections, we will examine how tumor imaging can assist in the following by assessing the microcirculatory properties of tumors:

- the choice of initial treatment which will have most likelihood of success in a given patient (chemotherapy, radiotherapy or surgery);
- identifying poor responders in order to adjust treatment more quickly;

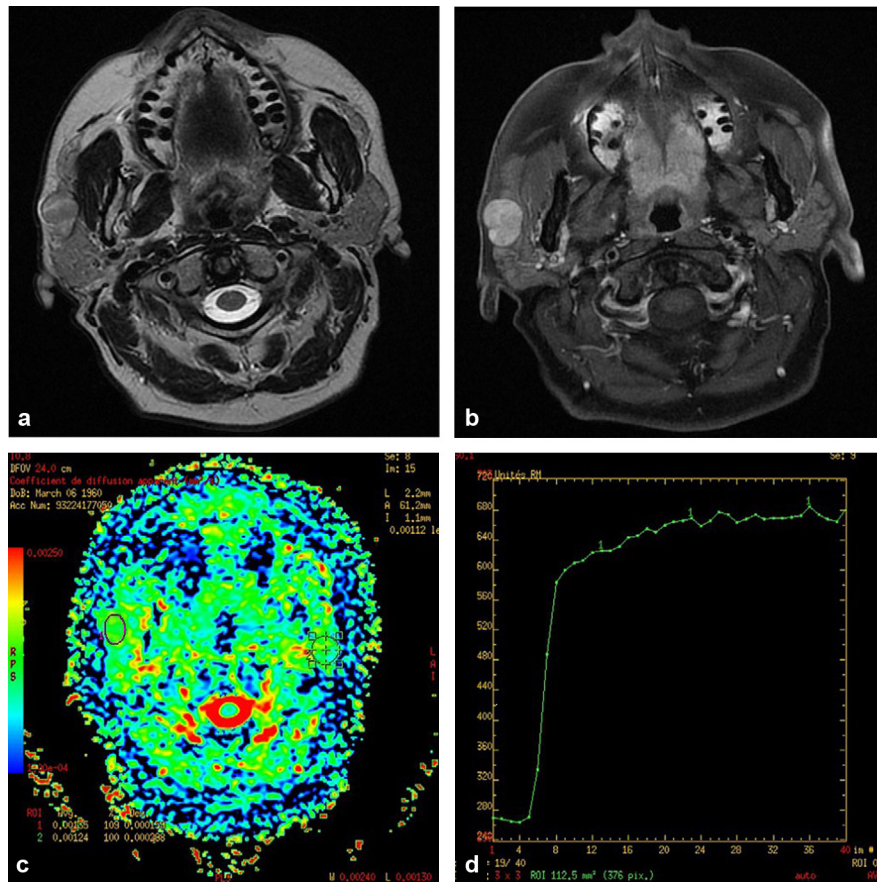


Figure 12. Cellular pleomorphic adenoma. Tissue lesion in the superficial lobe of the right parotid gland, measuring 2 cm in size. a: axial T2-weighted MRI: isointense lesion; b: axial T1-weighted MRI after gadolinium with fat saturation: intense contrast enhancement; c: mapping of the apparent diffusion coefficient: $rADC = 1.09$; d: perfusion curve showing intense contrast enhancement with an ascending plateau.

- quantitative (objective) monitoring of treatment response;
- early detection of recurrences in post-treatment damaged tissue.

Technique and image processing

We will not describe the CT or MRI technique here, and refer the reader to the techniques chapter.

We would simply like to draw the reader's attention to a few specific features of head and neck imaging.

Choice of method, CT or MRI

This is usually dictated by the site of the primary tumor, the patient's past imaging history and the question being asked by the clinician. It should not further complicate the pre-treatment assessment of patients who are already going through a relatively complex staging process (initial CT and/or MRI imaging depending on the site, PET CT investigating for a second primary, biopsy).

Lesions of the cavum, oropharynx, oral cavity and posterior pharyngeal wall should preferably be investigated by MRI. The perfusion MRI sequence is only an additional phase of the investigation (Fig. 15).

Lesions of the hypopharynx and larynx are only investigated by CT (unless there is an exception) and it is reasonable to use a CT perfusion sequence (Fig. 16).

The initial assessment of facial tumors usually requires both MRI (to demarcate the tumor, identify perineural or even intracranial extensions, and to distinguish it from neighboring inflammatory reactions) and CT (to identify cortical bone structures in the facial bone and base of the cranium which are involved). In this situation, the choice of method is guided by the radiologist's personal experience and the patient's past radiological history.

Specific features of the ENT perfusion sequence

On CT [17]:

- 80 kV acquisition with dose modulation (angular and z) between 20 and 100 mA, 2.5 mm sections, FOV=20 cm, soft filter reconstruction;
- injection: 40 mL at 5 mL/s by pulsed bolus, concentration 320 mgI/mL;
- acquisition: 5 s after the start of the injection, minimum time 60 s, temporal resolution: 1/s;
- gentle breathing without swallowing.

On MRI and CT, for UADT carcinomas, the issue of dental artifacts arises: the patient should be tilted to minimize these.

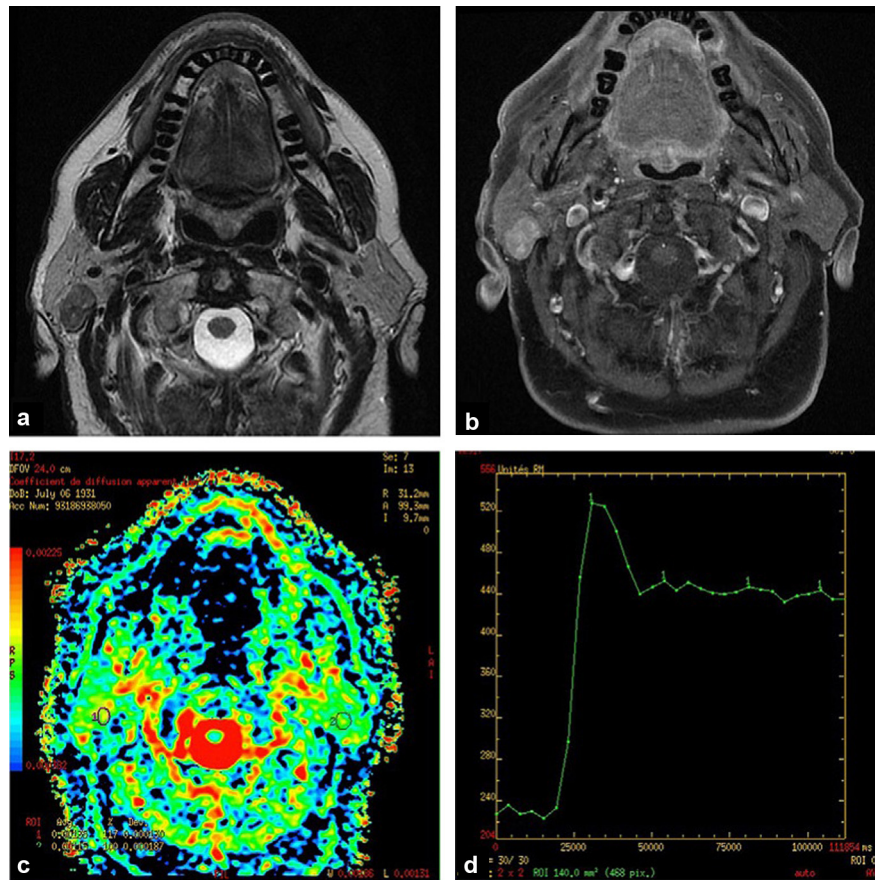


Figure 13. Intermediary-grade malignant tumor. Tissue lesion in the superficial part of the right parotid gland. a: axial T2-weighted MRI: hypointense; b: axial T1-weighted MRI after gadolinium with fat saturation: moderate enhancement; c: mapping of the apparent diffusion coefficient: $rADC = 1.1$; d: perfusion curve showing early contrast enhancement with washout of under 30%.

Boxed text 2 Acquisition parameters for CT perfusion sequence.

Injection: 40 mL via a power injector at a rate of 4 mL/s, followed by injection of 40 mL of normal saline
 80 kV/80 mAs
 Section thickness: 2.5 mm
 Temporal resolution: 1/s during the first min
 Acquisition duration: 4 min 30 s
 Matrix: 192×192
 FOV: 28 cm

Choice of arterial input functional ROI: there is no consensus on this. It would seem reasonable to position this in the ipsilateral external carotid artery, as close as possible to the lesion (Boxed text 2).

Interpretation of microcirculation indices

Pre-treatment

The aim here is to predict the likelihood of local control and complete response to conservative treatment. It has been demonstrated that:

- TBF and TBV predict the level of chemosensitivity. The higher these indices are, the more chemosensitive the

lesion is [15,18]. In particular, a high pre-treatment TBV is a marker of good response to non-surgical treatment, with a greater likelihood of complete response with radiochemotherapy [15];

- TBF, calculated from the perfusion CT, is an independent marker of failure of radiotherapy: hypoperfused tumors respond less well to radiotherapy, as they are poorly oxygenated [19];
- SP predicts the likelihood of local control after non-surgical treatment [18].

It also appears that:

- the MTT correlates with the level of malignancy [13,14]. An MTT of less than 3.5 s is evidence of a malignant lesion, whereas an MTT more than 5.5 s signifies a benign lesion. This reduction is due to neoangiogenesis, with raised perfusion pressure and raised capillary permeability;
- TBF and TBV correlate with microvascular density [16];
- results for SP are discordant, and additional studies are required to establish whether SP is or is not a marker of neoangiogenesis [13,16].

Quantitative assessment of response to treatments and monitoring response to non-surgical treatments

It has been shown that:

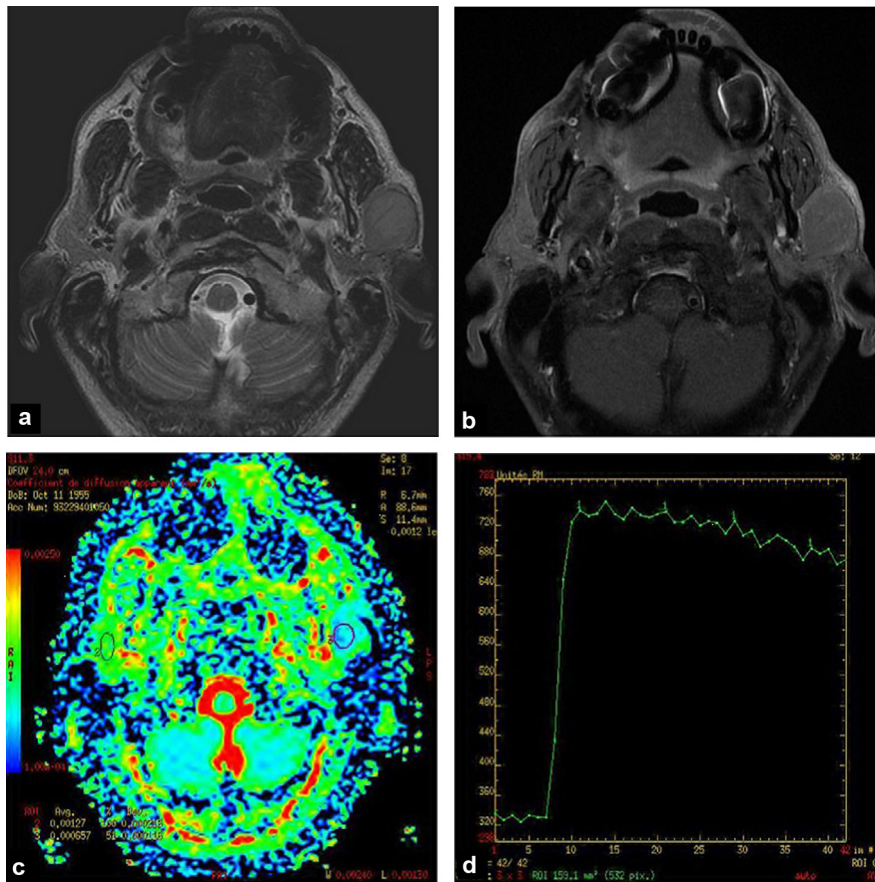


Figure 14. High-grade malignant tumor. Tissue structure in the superficial lobe of the left parotid gland, measuring 3 cm in size. a: axial T2-weighted MRI: isointense; b: axial T1-weighted MRI after gadolinium with fat saturation: moderate contrast enhancement; c: diffusion mapping: rADC = 0.5; d: perfusion curve showing a descending plateau with washout of under 30%.

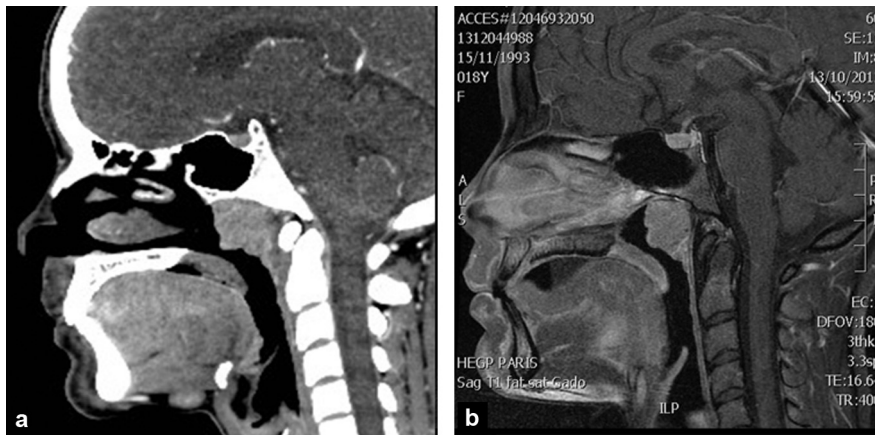

Figure 15. CT versus MRI of the cavum. a: CT: sagittal reconstruction centered on the cavum; b: MRI: sagittal T1-weighted sequence with gadolinium and fat saturation centered on the cavum. Note that the enhancement resolution is better on MRI.

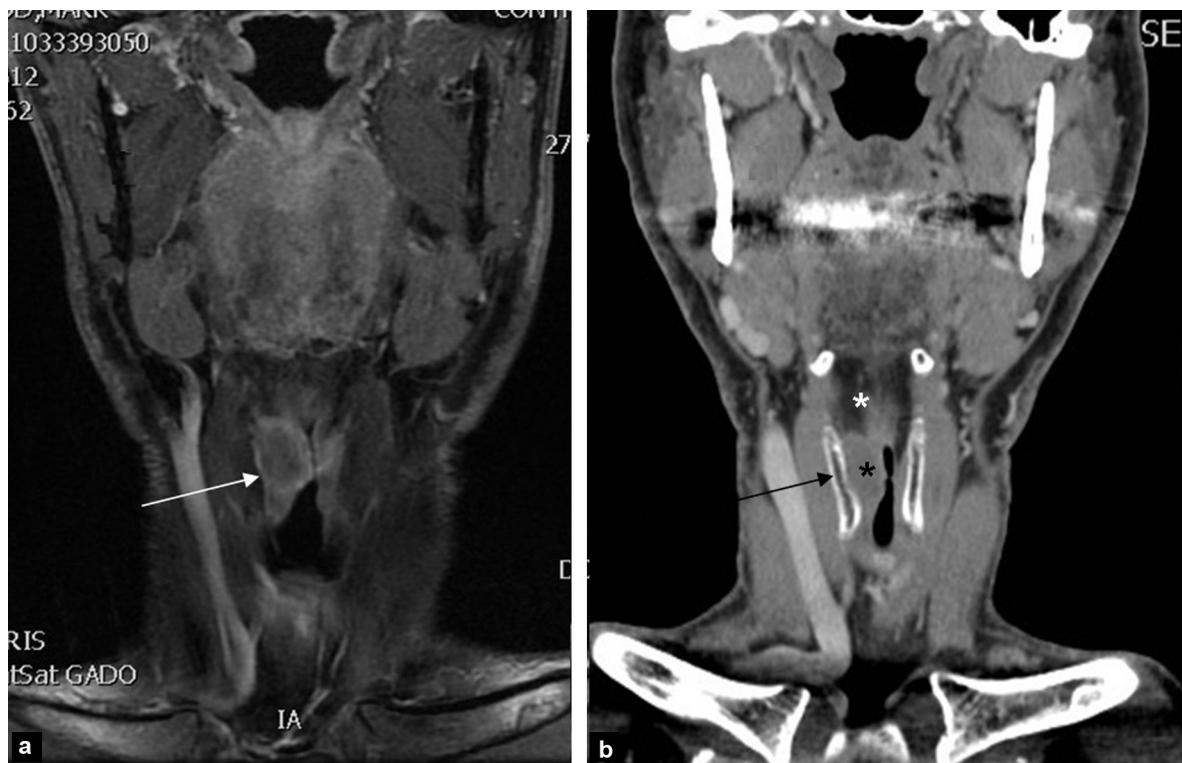


Figure 16. CT versus MRI of the larynx. a: MRI: coronal T1-weighted sequence after gadolinium with fat saturation centered on the larynx. Right supra-glottal structure with peripheral enhancement; b: CT: coronal reconstruction of the larynx. Note that the differentiation between the lesion (black asterisk) and the thyroid cartilage (black arrow) is better, and visualization of the fat in the hyo-thyro-epiglottic cavity (white asterisk) is clear on CT.

- the change in TBV is a good indicator of response: a 20% fall correlates with an endoscopic response of over 50% [20];
- a successive fall in TBV and TBF [21] is an objective, quantitative method to detect tumors which have responded to neo-adjuvant chemotherapy;
- a repeated persistent fall in TBV during treatment is a predictor of response [21];
- a progressive rise in TBV is characteristic of non-responders to radiochemotherapy [21].

Detection of recurrences

The best detection method for detecting recurrences appears to be PET CT with MRI [22], although these preliminary findings need to be confirmed in studies on larger numbers.

A new rise in TBF after radiochemotherapy treatment would appear to help to detect relapse within non-specific post-treatment tissue changes [23,24].

The main established values for microcirculation parameters are summarized in Table 2.

An example of the use of MRI is shown in Fig. 17.

Characterization of lymph nodes under a centimeter in size [22]

There is still a major problem with characterizing lymph nodes under a centimeter in size. Combining PET CT with diffusion-weighted MRI currently appears to be the best option to detect small invaded lymph nodes [22]. Perfusion

imaging does not perform well in this situation because of the small number of sections which can be investigated and the need to decide on the lymph nodes to be examined in advance.

Summary

CT or MRI perfusion imaging can identify the microcirculatory features of tumors. Initial work suggests that this method should help to predict response to non-surgical treatment in order to optimally adjust it, monitor response to the treatment quantitatively and detect relapses after conservative treatment early [25]. Validating this technique therefore appears to be the first stage towards dose modulation for each investigation, allowing individually customized treatment. Technical difficulties remain, however, and are described in the most recent publications which have returned to the physical bases and principles of calculating microcirculatory parameters [26,27].

Conclusion

Perfusion imaging has become a routine MRI tool for salivary gland tumors. A good investigation should include a T2 sequence combined with diffusion-weighted and perfusion sequence. Under these conditions, MRI can predict the type of lesion in over 80% of cases.

Intégrale rehaussement positif

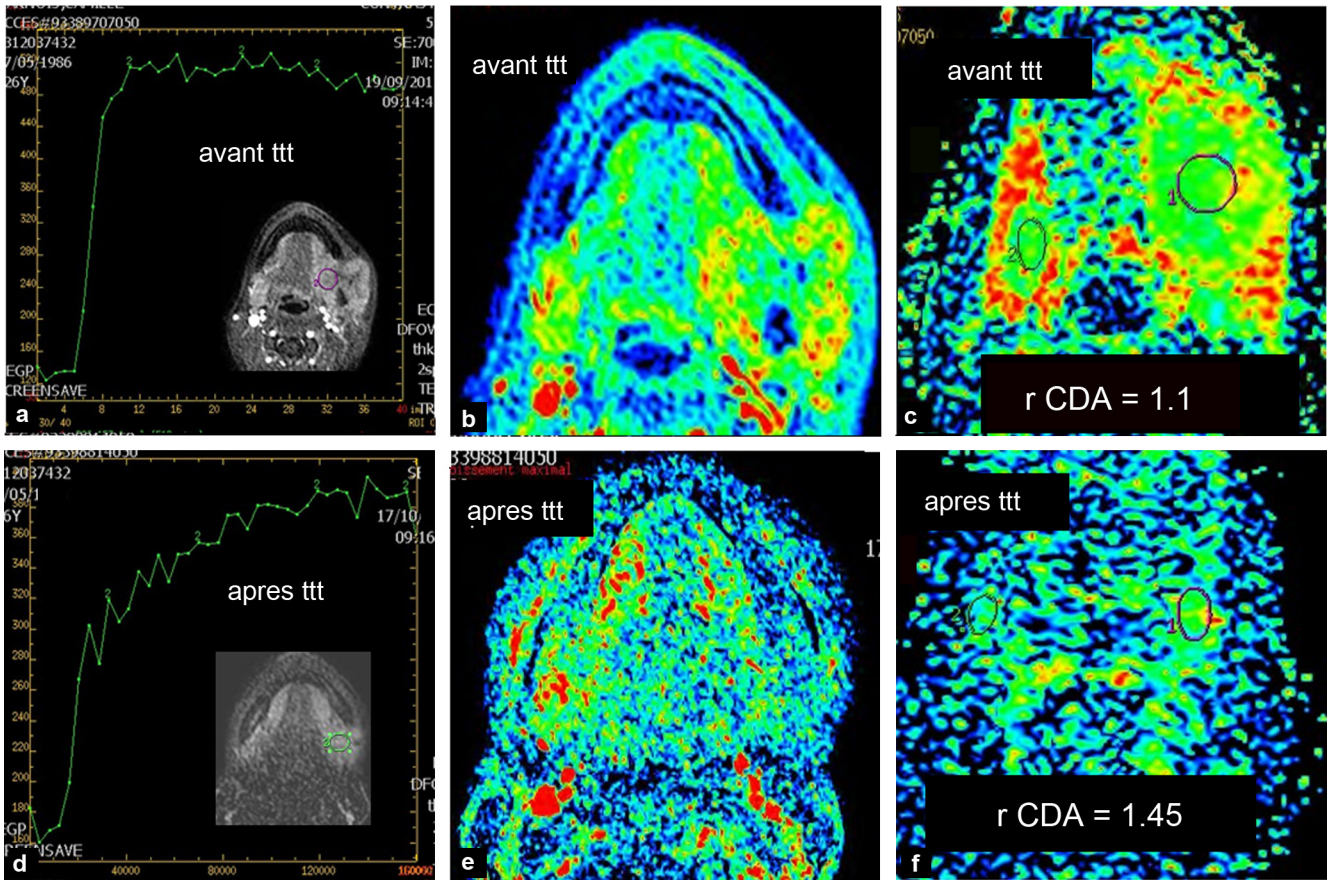


Figure 17. Monitoring a left submaxillary tumor. First line: before treatment: a: perfusion curve before treatment showing a descending plateau suggesting a malignant tumor; b: mapping of the positive enhancement integral before treatment: note the peripheral hypervascular crown shown in yellow and red, indicating extensive vascularization within the lesion; c: ADC mapping before treatment: low rADC of 1.1. Second line: after treatment: d: perfusion curve after treatment showing an ascending plateau; e: mapping of the positive enhancement integral after treatment: note the disappearance of the peripheral hypervascular crown in yellow and red, indicating a reduction in the vascularization within the lesion; f: ADC mapping after treatment: high rADC of 1.45.

Table 2 Literature data.				
	MTT	TBF	TBV	PS
Before treatment		Chemosensitive when high value	Chemosensitive when high value	Predictive local control
During treatment		Decrease with response	Decrease with response Increase with no response	
Other	Correlated to malignancy	Correlated to malignancy and microvascular density	Correlated to malignancy and microvascular density	Correlated to malignancy

Perfusion imaging is a promising tool for other head and neck tumors, particularly UADT carcinomas, which should help us to meet clinicians' expectations in the future. Perfusion imaging is always the first step towards dose modulation and allows treatment to be adapted to the patient.

TAKE-HOME MESSAGES

Salivary glands:

- a T1-weighted perfusion sequence is essential in characterizing salivary gland tumors;
- temporal resolution must involve one set of images every 3 to 4s;
- the sequence should last 4 to 5 min;
- the choice of ROI is very important. This should be positioned:
 - outside of cystic and hemorrhagic areas,
 - outside of T1 hyperintense areas,
 - inside T1 and T2 hypointense areas;
- the curve can only be interpreted in conjunction with conventional imaging:
 - a washout of over 30% is highly suggestive of a Warthin tumor,
 - an ascending plateau with no washout suggests a pleomorphic adenoma,
 - a descending plateau suggests a malignant tumor;
- a full investigation protocol should include T1 and T2 sequences without fat saturation, T1 diffusion and perfusion sequences and a fat saturation gadolinium enhanced T1-weighted sequence;
- interpretation should take all of the anatomical, signal abnormality and functional findings into account.

UADT carcinomas:

- the perfusion sequence appears to be useful for selecting and monitoring treatments;
- the perfusion sequence can be performed by CT or T1-weighted MRI;
- the spatial resolution should be:
 - one set of images per second by CT,
 - one set of images every 3 to 4s by MRI;
- TBV and TBF are the best predictive indicators of response to conservative treatment and can be used to monitor lesions which are currently being treated.

Clinical case report

This 79-year-old patient is being followed up for bladder cancer. PET CT shows right parotid uptake with an SUV of 5.3 (Fig. 18). This is his MRI (Fig. 19).

Questions

1. Describe the abnormalities on MRI.
2. What question should the patient be asked?
3. What is your diagnosis?
4. How do you confirm it?

5. What should you tell the patient and what treatment should be considered?

Answers

1. MRI shows a 15 mm tissue lesion within the right parotid gland, located in the superficial part of the gland. There is a slight unenhanced hyperintensity within the lesion on the T1-weighted sequence. The T2-weighted signal is heterogeneous, with isointense areas and pronounced hypointense areas on a T2-weighted sequence. The lesion is isointense compared to the rest of the glandular parenchyma on the late phase after enhancement. Diffusion mapping shows an ADC of 0.6 and the perfusion curve shows an early peak with a 30% washout.

2. The question to ask the patient is: "Have you done a needle aspiration of the lesion?" A needle aspiration before the MRI could cause bleeding inside the lesion. The T1-weighted hyperintensity is not significant if a needle aspiration was taken before the MRI. In this case, the MRI would need to be repeated a month later. In this case, no needle aspiration had been performed before the MRI.

3. The diagnosis is that of a typical Warthin tumor because of an unenhanced T1-weighted hyperintensity and 30% washout. These lesions often have an rADC of between 0.6 and 1: this is not therefore incompatible with the diagnosis. In addition, the lesions show intense uptake on PET CT. This is an increasingly common diagnosis because of the increased use of this type of investigation in all oncology assessments, particularly in ENT.

4. The diagnosis must be confirmed by a needle aspiration, which did confirm this diagnosis.

5. This is a benign tumor with no risk of malignant degeneration and surgery is not indicated. MRI monitoring alone may be sufficient, although is not really essential. The lesion may change in size and signal as a result of episodes of inflammation or bleeding within the lesion.

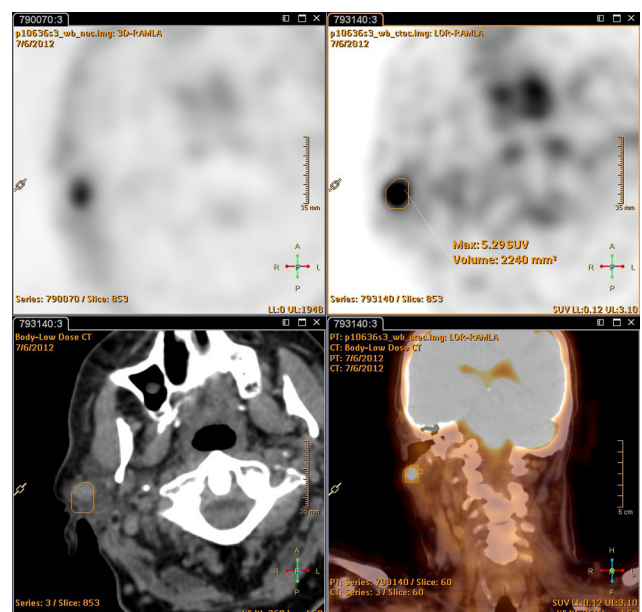


Figure 18. PET CT shows right parotid uptake with an SUV = 5.3.

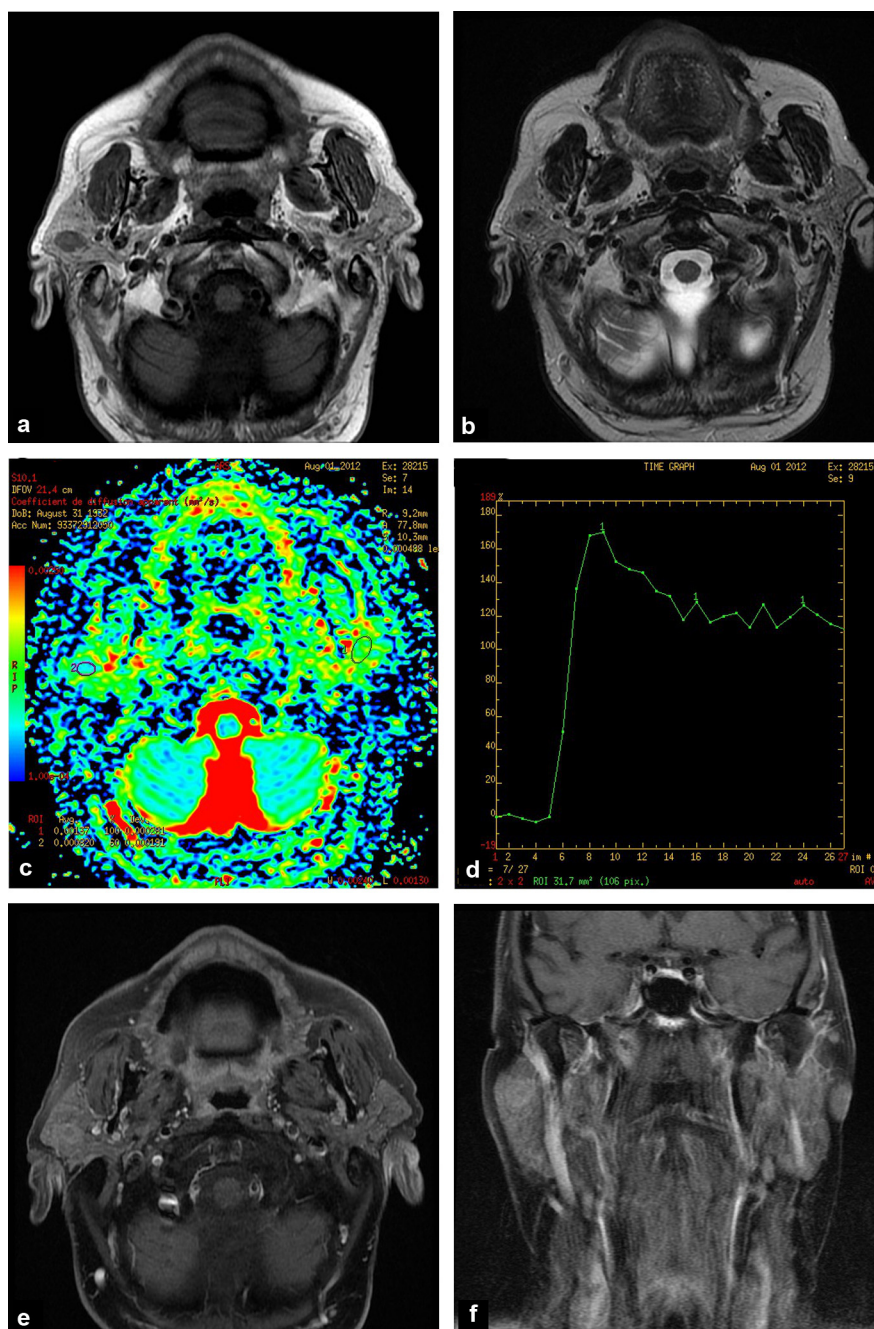


Figure 19. MRI: a: axial T1-weighted MRI; b: axial T2-weighted MRI; c: diffusion mapping; d: T1-weighted perfusion curve; e: axial T1-weighted MRI after enhancement with fat saturation; f: coronal T1-weighted MRI after enhancement with fat saturation.

Disclosure of interest

The authors declare that they have no conflicts of interest concerning this article.

References

- [1] Wang J, Takashima S, Takayama F, Kawakami S, Saito A, Matsushita T, et al. Head and neck lesions: characterization with diffusion-weighted echoplanar imaging. *Radiology* 2001;220:621–30.
- [2] Lechner Goyault J, Riehm S, Neuville A, Gentine A, Veillon F. Interest of diffusion-weighted and gadolinium-enhanced dynamic MR sequences for the diagnosis of parotid gland tumors. *J Neuroradiol* 2010;38(2):77–89.
- [3] Yabuuchi H, Matsuo Y, Kamitani T, Setoguchi T, Okafuji T, Soeda H, et al. Parotid gland tumors: can addition of diffusion-weighted MR imaging to dynamic contrast-enhanced MR imaging improve diagnostic accuracy in characterization? *Radiology* 2008;249(3):909–16.
- [4] Habermann CR, Arndt C, Graessner J, Diestel L, Petersen KU, Reitmeier F, et al. Diffusion-weighted echo-planar MR imaging of primary parotid gland tumors: is a prediction of different histologic subtypes possible? *AJNR Am J Neuroradiol* 2009;30(3):591–6.

- [5] Yabuuchi H, Fukuya T, Tajima T, Hachitanda Y, Tomita K, Koga M. Salivary gland tumor: diagnostic value of gadolinium-enhanced dynamic MR imaging with histopathologic correlation. *Radiology* 2001;220:621–30.
- [6] Alibek S, Zenk J, Bozzato A, Lell M, Grunewald M, Anders K, et al. The value of dynamic MRI studies in parotid tumors. *Acad Radiol* 2007;14(6):701–10.
- [7] Yabuuchi H, Matsuo Y, Kamitani T, Setoguchi T, Okafuji T, Soeda H, et al. Parotid gland tumors: can addition of diffusion-weighted MR imaging to dynamic contrast-enhanced MR imaging improve diagnostic accuracy in characterization? *Radiology* 2008;249(3):909–16 [190].
- [8] Ikeda M, Motoori K, Hanazawa T, Nagai Y, Yamamoto S, Ueda T, et al. Warthin tumor of the parotid gland: diagnostic value of MR imaging with histopathologic correlation. *AJNR Am J Neuroradiol* 2004;25(7):1256–62.
- [9] Espinoza S, Halimi P. Interpretation pearls for MR imaging of parotid gland tumor. *Eur Ann Otorhinolaryngol Head Neck Dis* 2013;130(1):30–5.
- [10] Hermans R, Lambin P, Van den Bogaert W, Haustermans K, Van der Goten A, Baert AL. Non-invasive tumor perfusion measurement by dynamic CT: preliminary results. *Radiother Oncol* 1997;44:159–62.
- [11] Roberts TP. Physiologic measurements by contrast-enhanced MR imaging: expectations and limitations. *J Magn Reson Imaging* 1997;7(1):82–90.
- [12] Knopp MV, Giesel FL, Marcos H, von Tengg-Kobligh H, Choyke P. Dynamic contrast-enhanced magnetic resonance imaging in oncology. *Top Magn Reson Imaging* 2001;12(4):301–8.
- [13] Gandhi D, Hoeffner EG, Carlos RC, Case I, Mukherji SK. Computed tomography perfusion of squamous cell carcinoma of the upper aerodigestive tract: initial results. *J Comput Assist Tomogr* 2003;27:687–93.
- [14] Rumboldt Z, Al-Okaili R, Deveikis JP. Perfusion CT for head and neck tumors: a pilot study. *AJNR Am J Neuroradiol* 2005;26:1178–85.
- [15] Zima A, Carlos R, Gandhi D, Case I, Teknos T, Mukherji SK. Can pretreatment CT perfusion predict response of advanced squamous cell carcinoma of the upper aerodigestive tract treated with induction chemotherapy? *AJNR Am J Neuroradiol* 2007;28:328–34.
- [16] Ash L, Teknos TN, Gandhi D, Patel S, Mukherji SK. Head and neck squamous cell carcinoma: CT perfusion can help noninvasively predict intratumoral microvessel density. *Radiology* 2009;251:422–8.
- [17] Faggioni L, Neri E, Bartolozzi C. CT perfusion of head and neck tumors: how we do it. *AJR Am J Roentgenol* 2010;194:62–9.
- [18] Surlan-Popovic K, Bisdas S, Rumboldt Z, Koh TS, Strojan P. Changes in perfusion CT of advanced squamous cell carcinoma of the head and neck treated during the course of concomitant chemoradiotherapy. *AJNR Am J Neuroradiol* 2010;31:570–5.
- [19] Hermans R, Meijerink M, Van den Bogaert W, Rijnders A, Weltens C, Lambin P. Tumor perfusion rate determined noninvasively by dynamic computed tomography predicts outcome in head-and-neck cancer after radiotherapy. *Int J Radiat Oncol Biol Phys* 2003;57(5):1351–6.
- [20] Gandhi D, Chepeha DB, Miller T, Carlos RC, Bradford CR, Karamchandani R, et al. Correlation between initial and early follow-up CT perfusion parameters with endoscopic tumor response in patients with advanced squamous cell carcinomas of the oropharynx treated with organ-preservation therapy. *AJNR Am J Neuroradiol* 2006;27:101–6.
- [21] Bisdas S, Rumboldt Z, Surlan-Popovic K, Baghi M, Koh TS, Vogl TJ, et al. Perfusion CT in squamous cell carcinoma of the upper aerodigestive tract: long-term predictive value of baseline perfusion CT measurements. *AJNR Am J Neuroradiol* 2010;31:576–81.
- [22] Loeffelbein DJ, Souvatzoglou M, Wankler V, Martinez-Möller A, Dinges J, Schwaiger M, et al. PET-MRI fusion in head-and-neck oncology: current status and implications for hybrid PET/MRI. *J Oral Maxillofac Surg* 2012;70(2):473–83.
- [23] Bisdas S, Baghi M, Smolarz A, Pihno NC, Lehnert T, Knecht R, et al. Quantitative measurements of perfusion and permeability of oropharyngeal and oral cavity cancer, recurrent disease, and associated lymph nodes using first-pass contrast-enhanced computed tomography studies. *Invest Radiol* 2007;42(3):172–9.
- [24] Brizel DM. Head and neck cancer as a model for advances in imaging prognosis, early assessment, and posttherapy evaluation. *Cancer J* 2011;17(3):159–65.
- [25] Mukherji SK, Castelijns JA. CT perfusion of head and neck cancer: why we should care versus why should we care! *AJNR Am J Neuroradiol* 2010;31(3):391–3.
- [26] Craciunescu O, Brizel D, Cleland E, Yoo D, Muradyan N, Carroll M, et al. Dynamic contrast enhanced-MRI in head and neck cancer patients: variability of the precontrast longitudinal relaxation time (T10). *Med Phys* 2010;37(6):2683–92.
- [27] Craciunescu OI, Yoo DS, Cleland E, Muradyan N, Carroll MD, MacFall JR, et al. Dynamic contrast-enhanced MRI in head-and-neck cancer: the impact of region of interest selection on the intra- and interpatient variability of pharmacokinetic parameters. *Int J Radiat Oncol Biol Phys* 2012;82(3):e345–50.