

Available online at
ScienceDirect
www.sciencedirect.comElsevier Masson France
EM|consulte
www.em-consulte.com/en

Original article

Negative-pressure wound therapy for the treatment of pharyngocutaneous fistula

E. Loaec^{a,*}, P.-Y. Vaillant^a, L. Bonne^a, R. Marianowski^b^a Service ORL-CCF, hôpital d'instruction des armées Clermont-Tonnerre, rue Colonel-Fontferrière, CC 41, 29241 Brest, France^b Service d'ORL-CCF, hôpital Morvan, CHRU de Brest, 2, avenue Foch, 29609 Brest cedex, France

ARTICLE INFO

Keywords:

Negative-pressure wound therapy
Pharyngocutaneous fistula
Head and neck cancer
Total laryngectomy
Partial laryngectomy

ABSTRACT

Introduction: Pharyngocutaneous fistula is a well-known complication of head and neck cancer surgery. The purpose of this study was to determine the value of negative-pressure wound therapy (NPWT) for the treatment of these fistulas. NPWT is used in many fields of medicine, but its use in otorhinolaryngology has been rarely reported. NPWT is a cost-effective means to accelerate wound healing.

Patients and methods: A single-centre retrospective study was conducted on 7 patients with pharyngocutaneous fistula following surgery for squamous cell carcinoma between January 2011 and April 2013. These fistulas were treated by negative-pressure wound therapy (NPWT).

Results: This series comprised seven male patients with a mean age of 65 years and 9 months. The mean duration of treatment was 23 days (range: 11 to 42 days). Two patients had a history of radiotherapy for pharyngolaryngeal cancer. Negative-pressure wound therapy achieved cure of the fistula in all patients with satisfactory acceptability. Mean follow-up was 10 months (range: 6 months to 2 years).

Conclusion: Negative-pressure wound therapy represents a valuable treatment option in certain settings for the management of pharyngocutaneous fistula following head and neck cancer surgery.

© 2014 Published by Elsevier Masson SAS.

1. Introduction

Poor wound healing is a common problem in head and neck cancer surgery, generally observed in malnourished patients treated by radiotherapy and/or chemotherapy. The pharyngolaryngeal mucosa and neck tissues present altered trophicity and are submitted to the aggressive action of saliva or even gastro-oesophageal reflux.

Pharyngocutaneous fistula increases morbidity and mortality and prolongs the length of hospital stay. It is frequently located adjacent to the tracheostoma, making tracheostoma care more difficult and sometimes requiring redo surgery. Negative-pressure wound therapy (NPWT) is an alternative treatment option for the management of pharyngocutaneous fistula.

The use of NPWT was first reported by Fleischmann et al. in 1993 [1] and then in 1995 [2]. Many publications have subsequently described the use of NPWT for the treatment of sternal, sacral, upper and lower limb, perineal and abdominal wounds [3]. However, few publications have reported the use of NPWT in head and neck surgery. In 2006, Schuster et al. [4] reported the first successful

use of this therapy on a complex lesion of the face. In the same year, Andrews et al. [5] reported the treatment of complex head and neck injuries and, in 2008, they then demonstrated the value of NPWT for the treatment of pharyngocutaneous fistula in 2 patients with fistula closure in 6 days and 11 days, respectively [6]. In 2005, Rosenthal et al. [7] also used NPWT to treat complications of head and neck cancer surgery in 23 patients, including 4 patients with pharyngocutaneous fistula. The mean duration of treatment was 6.25 days for these 4 patients.

This article describes the use of NPWT to specifically treat pharyngocutaneous fistulas occurring after surgery for pharyngolaryngeal or oral cancer and the results obtained.

2. Patients and methods

A single-centre retrospective study was conducted from January 2011 to April 2013 on patients of the department of otorhinolaryngology and head and neck surgery of our institution with pharyngocutaneous fistula following partial laryngectomy, total laryngectomy transmandibular oropharyngectomy, treated by negative-pressure wound therapy.

Epidemiological data were collected from the patients' medical charts. Pharyngocutaneous fistula was defined as salivary leak in the neck. In doubtful cases, the fistula was demonstrated by

* Corresponding author.

E-mail address: emilye.loaec@gmail.com (E. Loaec).

Table 1
Negative-pressure wound therapy devices and manufacturers.

Name of the medical device	Manufacturers or distributors
ATMOS SO 41	ATMOS Médical, France
Engenex	Boehringer, Phoenix USA
Exsudex	Synergy Healthcare plc, Swindon UK
VAC therapy	KCI, San Antonio USA
RENASYS	Smith & Nephew, London UK
Venturi	Talley, Romsey UK
WOUND assist	HNE Medical, Limonest France

VAC: vacuum-assisted closure.

methylene blue test. No patient was concomitantly treated by hyperbaric oxygen therapy.

The course of wound healing was evaluated at each change of dressing, i.e. every 48 to 72 hours, until complete healing. The dressing was systematically changed by the surgeon or the intern at the patient's bedside. The dressing was maintained until complete healing of the fistula (no discharge visible when changing the dressing and/or negative methylene blue test). Subsequent management consisted of healing by secondary intention.

Several companies currently propose NPWT devices in France: RENASYS, VAC therapy (vacuum-assisted closure) and WOUND ASSIST (Table 1). In this study, we used the Smith and Nephew RENASYS system in continuous mode with negative pressures ranging from -100 to -125 mmHg. This device can be used according to various modes with intermittent or continuous pressure, and pressures ranging from -25 to -200 mmHg. Pharyngocutaneous fistulas require a relatively high pressure to achieve an occlusive seal [7].

Seven patients (7 males with a mean age of 65 years 9 months) with postoperative pharyngocutaneous fistula between January 2011 and April 2013 were included in this study. The following operations had been performed: one total laryngectomy, one total circular pharyngolaryngectomy, two partial laryngectomies, one transmandibular oropharyngectomy and two salvage total laryngectomies. Only these last two patients had a history of external beam radiotherapy for a previous head and neck cancer. Only one patient presented insulin-dependent diabetes.

3. Results

Seven patients were included in this study. The dressing was well-tolerated by all patients, both in the long term and at the time of dressing changes. The mean duration of NPWT was 23 days (range: 11 days to 42 days). All NPWT dressings achieved complete healing of the fistula.

The mean follow-up was 10 months (range: 6 months to 2 years). Early recurrence of a low-output fistula was observed at one week and resolved spontaneously after five days without the use of NPWT.

Patient 1, 77 years old, was treated by total laryngectomy and bilateral neck dissection for stage T3N2aM0 squamous cell carcinoma of the larynx. He developed pneumonia with deterioration of his general condition on postoperative day 3, requiring admission to the intensive care unit for 5 days.

On day 15, a salivary leak was observed in the neck, adjacent to the tracheostoma. Surgery was not proposed in view of the patient's poor general state and it was decided to treat the fistula by NPWT. Seven days after starting NPWT, it was difficult to obtain an airtight dressing due to the proximity of the tracheostoma and skin folds. Tulle gras dressing was then aspirated into the leaking zones to ensure an airtight dressing (Fig. 1). The fistula had closed after 18 days of NPWT. Healing by secondary intention with alginate packing was continued for 7 days until complete skin healing was

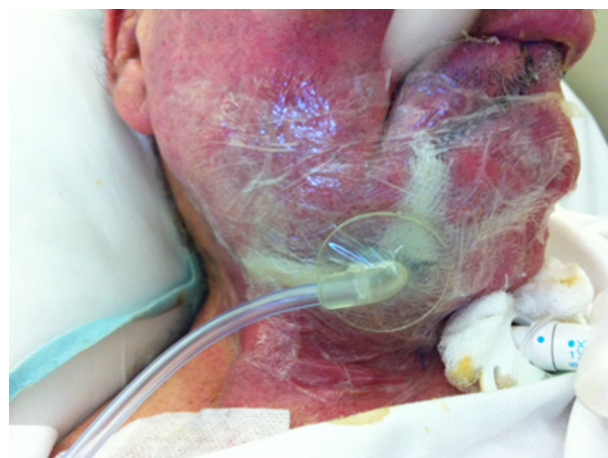

Fig. 1. Tulle gras placed in skin folds.

obtained. Two-year follow-up confirmed the absence of recurrence of the fistula.

Patient 2, 72 years old, a smoker and heavy drinker, was operated by transmandibular oropharyngectomy with ipsilateral functional neck dissection for stage T3N2bM0 squamous cell carcinoma of the right oropharynx. Early wound dehiscence and salivary leak were observed on postoperative day 6. The patient was reoperated for debridement and closure by a right pectoralis major myocutaneous flap.

On day 7, the patient developed cervical cellulitis that was treated medically, leading to the formation of another pharyngocutaneous fistula.

NPWT was installed on postoperative day 12 for 18 days. On day 26, air leaks related to the conformation of the wound and the proximity of the tracheostoma were also observed. This problem was resolved by the use of tulle gras dressing.

The fistula was closed on day 30 and NPWT was stopped. Complete healing was obtained on day 40. Clinical follow-up at 10 months did not reveal any signs of recurrence of the fistula.

Patient 3, 57 years old, an insulin-dependent diabetic with a history of squamous cell carcinoma of the larynx treated by radiotherapy (65 Gy) ten years previously, presented with a stage T3N0M0 carcinoma of the larynx. Salvage total laryngectomy was proposed. The initial course was satisfactory, with no healing problems despite difficulties controlling his diabetes.

On day 30, the patient suddenly developed an infectious complication with a neck abscess responsible for wound dehiscence and right pharyngocutaneous fistula directly adjacent to the tracheostoma. Attempted direct closure by mucosal suture under general anaesthesia was unsuccessful. A left pectoralis major myocutaneous flap was performed on day 39 and it was decided to install NPWT intraoperatively in view of the poor condition of the tissues. NPWT was designed to direct the fistula away from the tracheostoma in order to simplify subsequent dressing changes. Despite these precautions, low left cervical wound dehiscence was observed 3 days later. A second NPWT dressing was inserted on day 42 after the first operation. Closure of the two fistulas was obtained after 21 and 24 days of NPWT, respectively. Dressings were continued by alginate packing for 7 days after stopping NPWT, until complete healing. One-year follow-up demonstrated complete healing and absence of recurrence.

Patient 4, 65 years old, had a history of stage T2N0M0 squamous cell carcinoma of the larynx treated by external beam radiotherapy at a dose of 65 Gy three years previously (refusal of surgery). He presented with a stage T4N2M0 local recurrence requiring salvage

total laryngectomy with closure by a right pectoralis major muscle flap.

On postoperative day 10, a pharyngocutaneous fistula was observed in a context of local and systemic sepsis. Surgical revision for drainage, lavage and mucosal suture allowed closure of the fistula. Flap viability remained satisfactory. In view of the poor local conditions, despite the absence of fistula, it was decided to close the wound over a NPWT device. Foam was placed in the neck wound. The initial postoperative course was favourable, but another fistula appeared at the tracheostoma orifice. As NPWT dressings could not be performed at this site, it was decided to redirect the fistula away from the tracheostoma in order to install the NPWT in a zone allowing the dressings to be performed and to close the distal part of the fistula by the combined action of drainage and tissue apposition induced by negative pressure. A counter-incision above and away from the tracheostoma over the fistula tract were performed under local anaesthetic. This option allowed effective closure of the fistula. NPWT was stopped after a total of 42 days and alginate dressings were continued for 6 days until complete healing. No recurrence of the fistula was observed with a follow-up of 9 months.

Patient 5, 72 years old, with chronic obstructive pulmonary disease, presented a stage T2N2cM0 squamous cell carcinoma of the left vallecula spreading to the epiglottis and to the junctional region of the oropharynx. Treatment consisted of supraglottic laryngectomy with modified bilateral radical dissection, after performing temporary tracheotomy. On postoperative day 7, a neck abscess was observed, associated with wound dehiscence and pharyngocutaneous fistula. NPWT was placed immediately, allowing rapid closure of the fistula, and was removed on day 11. Follow-up at 6 months confirmed the absence of recurrence of the fistula.

Patient 6, 54 years old, a chronic smoker and heavy drinker, presented with stage T3N0M0 squamous cell carcinoma of the right vallecula spreading to the right pyriform sinus as far as the base of the tongue. Horizontal partial laryngectomy with right neck dissection was performed, followed by infection and abscess on postoperative day 1 and then right pharyngocutaneous fistula, treated by NPWT for 25 days to achieve closure of the fistula. Conventional mesh dressings were continued for 7 days. No pharyngocutaneous fistula was observed at 6-month follow-up.

Patient 7, 62 years old, presented with a double T4N2cM0 tumour of the pharyngolaryngeal wall associated with a tumour of the posterior pharyngeal wall. Total circular pharyngolaryngectomy was performed with bilateral neck dissection and reconstruction by radial forearm free flap. On day 1, the patient presented an extensive neck haematoma requiring reoperation to ensure haemostasis. On day 8, a neck abscess was observed, followed by an abundant pharyngocutaneous fistula. The patient was reoperated to ensure debridement and wound closure. The flap presented satisfactory viability with a patent vascular pedicle.

On postoperative day 10 after the initial surgery, two pharyngocutaneous fistulas were observed on each side, away from the tracheostoma. NPWT was installed on day 13 and was stopped after 22 days on the left side and 26 days on the right side.

Wound care was continued with alginate dressings. Another abscess was observed on the right side, associated with a small fistula. This minimally productive fistula was treated by healing by secondary intention using a mixture of honey and rusks ingested twice a day, combined with intravenous amoxicillin. The fistula was closed after 7 days. Follow-up at 6 months did not reveal any recurrence of the pharyngocutaneous fistula.

4. Discussion

Impaired wound healing and the formation of pharyngocutaneous fistula in the context of head and neck cancer can be

explained by a number of interrelated factors. Risk factors for postoperative complications identified in the literature are mainly a history of neoadjuvant radiotherapy, low serum albumin, diabetes and long operating times [8]. There is a higher risk of postoperative fistula in patients undergoing salvage laryngectomy, especially when it is performed within 12 months after high-dose radiation therapy (greater than 65 Gy) or following concomitant chemoradiotherapy [9].

Bohannon et al. tried to identify risk factors for recurrent fistula following salvage laryngectomy. They showed that, apart from radiotherapy, hypothyroidism was a statistically significant risk factor for recurrence of pharyngocutaneous fistula [10]. Chronic corticosteroid therapy and gastro-oesophageal reflux have also been proposed as possible risk factors for fistula, but have not been shown to be statistically significant [10].

Various treatment modalities for pharyngocutaneous fistula have been reported in the literature:

- hyperbaric oxygen therapy, which is not very effective on fistulas [11];
- ingestion of a combination of honey and rusks to fill the fistula [12];
- alginate dressings with intense draining properties [13];
- surgical closure by a pedicled latissimus dorsi flap or a free jejunum flap [14];
- first-line use of Tachosil® on the total laryngectomy T-shaped suture is currently under evaluation [15].

NPWT appears to be a valuable alternative in these settings of impaired healing. In non-oncological head and neck surgery, NPWT is already used to treat deep abscesses of the neck that are difficult to manage by conventional dressings [16,17].

Negative-pressure wound therapy consists of an application of a pressure difference between a wound sealed by an airtight dressing and the external environment, which transforms this open wound into a controlled closed wound allowing management of secretions.

Negative pressure is applied by means of polyurethane foam cut to the dimensions of the wound and placed under an occlusive dressing, in which a hole is made. A soft port is then connected to the hole in the dressing and is then connected to the negative pressure generator by tubing. The soft port is secured hermetically onto the occlusive dressing, with the opening of the soft port positioned over the hole in the dressing. The other end of the tubing is connected to a canister attached to the pump to collect secretions. This battery or main powered portable pump is used to adjust the negative pressure applied to the wound from –25 to –200 mmHg, in continuous or intermittent mode. Dressing instructions are summarized in Fig. 2.

The main expected benefits of NPWT are a reduction of the size and complexity of the wound and consequently decreased complexity of surgical reconstruction, when required. NPWT promotes the formation of granulation tissue and healing [18,19]. Finally, NPWT allows management of secretions in a perfectly airtight closed system with less frequent dressing changes and prevention of infection as a result of the probable reduction of bacterial contamination of the wound [20].

Conventional dressings performed for pharyngocutaneous fistula, comprising irrigation and packing, are often repeated (twice daily), requiring one or two nurses. NPWT decreases the dressing frequency (every 48 to 72 h) and consequently the nurse's workload as well as the patient's discomfort related to dressing changes and stagnation of partially absorbed secretions. In the present series, dressings were performed by a doctor due to the technical difficulties and the need to adapt treatment to the course of the fistula. Outpatient use of this device, as in other surgical specialties, does






Polyurethane foam	Adhesive soft port	Portable pump	Application of foam cut to the site of the fistula	Final dressing connected to the pump
				

Fig. 2. Dressing technique.

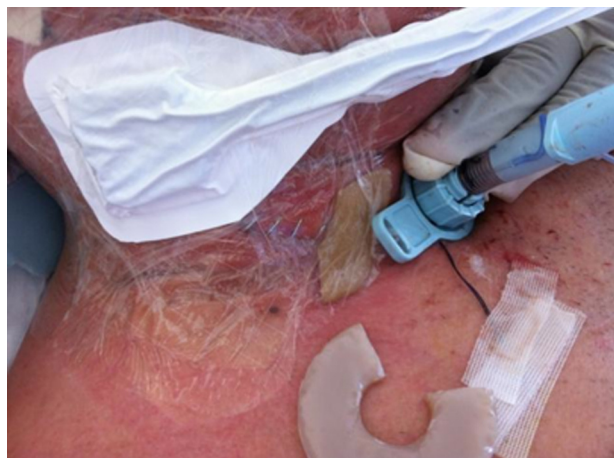

Fig. 3. Use of a colostomy wafer to ensure an airtight seal.

not appear to be very realistic in the specific setting of postoperative fistula.

The use of NPWT in neck dressings, particularly in tracheotomized patients, raises specific problems. Although NPWT is a very flexible device that can be adapted to a wide range of dressings, it is sometimes difficult to maintain an airtight seal due to the position of the fistula. An airtight dressing may be impossible when the fistula is situated too close to the tracheostoma, but an airtight dressing is essential to ensure the efficacy of NPWT. The neck also comprises zones of hair and skin folds, responsible for maceration and detachment of the dressings. Finally, secretions derived from the tracheostoma further complicate the situation. Specific strategies must therefore be defined to manage NPWT in the presence of leaks and poor adhesion in a moist environment, in an anatomically unfavourable zone.

What techniques are available to avoid leaks due to the proximity of the tracheostoma? We have successfully used tulle gras, which is aspirated by NPWT into the leaking zones (Fig. 1). We also systematically use hydrocolloid dressings in the interface between the polyurethane dressing and the skin in order to protect the skin in the context of these repeated dressings associated with a risk of skin avulsion.

Finally, the most appropriate device to maintain an airtight seal appears to be a colostomy wafer, whose very principle is to maintain a watertight seal in a moist environment. It is also associated with excellent skin tolerance (Fig. 3).

The NPWT device is contraindicated in the following situations:

- uncontrolled wound infection [18];
- presence of necrotic tissue requiring debridement;

- absence of interface between the gastrointestinal tract and the negative-pressure system;
- non-revascularized arterial disease;
- residual tumour after resection;
- in the presence of more than 50% of fibrin or in the presence of a pressure ulcer.

Theoretical precautions should also be observed in some situations, but they remain relative and must be adapted to each patient: enterocutaneous fistula and cavities, clotting disorders (risk of bleeding) and the presence of exposed vessels or organs.

Few adverse effects have been reported with NPWT, but they must be kept in mind. The patient may experience varying degrees of pain, especially during dressing changes. A simple method to relieve this pain is to inject 0.2% lidocaine directly into the foam before removal [21]. If the patient experiences pain when negative pressure is applied to the foam, the pressure should be decreased until the pain resolves. Lidocaine injection was not performed in any of the cases of the present series. The system also constitutes a permanent constraint for patients and is constantly noisy.

No precise guidelines have been established concerning the pressure to be applied to the wound. Timmers et al. [22] measured cutaneous blood flow by Doppler in a healthy arm after application of negative pressure via foam, ranging from -25 to -300 mmHg. They observed increased blood flow for negative pressures of up to -300 mmHg, but no reduction of blood flow. A higher negative pressure can therefore be considered to be more effective, especially as a sufficient pressure to obtain an airtight wound must be applied in our patients. However, the main limiting factor is pain. A pressure of about $-100/-125$ mmHg appeared to constitute a good compromise. The continuous or pulsed mode was not studied in this series.

The high cost of NPWT may constitute a drawback: the NPWT device costs €3500 to €15,000 and each dressing costs about €50. However, it has been estimated that the decreased nursing workload, the decreased frequency of dressing changes and the more rapid wound healing would result in shorter hospital stays [23]. A study conducted in Nantes showed that the cost of hospitalisation in the plastic surgery ward was significantly lower for patients treated by NPWT ($P = 0.02$) than for other patients, with a mean cost saving of €6000 per patient [24].

In 2010, in view of the financial stakes for hospitals, the arrival of several competitor devices and user expectations in terms of clinical practice guidelines, the French Haute Autorité de santé decided to evaluate NPWT. Based on a meta-analysis, the HAS [25] showed that, in the presence of extensive wound dehiscence or in an unfavourable site, with or without superinfection, previously debrided, when necessary, NPWT is able to promote more rapid formation of good quality granulation tissue, resulting in decreased complexity and/or dimensions of the wound, avoid retraction of the wound edges, accelerate the possibility of secondary closure

and facilitate drainage of secretions. Although sufficient evidence in favour of NPWT is lacking in the literature, the HAS working party considered that, in view of the severity of the diseases concerned and the efficacy of NPWT observed in routine clinical practice, a randomized trial is not necessary at the present time.

5. Conclusion

Pharyngocutaneous fistulas constitute a dreaded complication of head and neck cancer surgery, particularly total laryngectomies and pharyngolaryngectomies. Factors predisposing to fistula formation are malnutrition, diabetes and neck radiotherapy, a frequent situation in view of the current tendency in favour of larynx preservation strategies.

Management of fistulas must be based on a global approach, starting with prevention by acting on the main risk factors, and then curative management. Although first-line treatment consists of surgical revision for direct closure using muscle flaps if necessary, NPWT is a valuable alternative, particularly in the setting of repeated surgery or an unfavourable benefit/risk balance for surgery.

Disclosure of interest

The authors declare that they have no conflicts of interest concerning this article.

References

- [1] Fleischmann W, Strecker W, Bombelli M, et al. [Vacuum sealing as treatment of soft tissue damage in open fractures]. *Unfallchirurg* 1993;96(9):488–92.
- [2] Fleischmann W, Becker U, Bischoff M, et al. Vacuum sealing: indication, technique, and results. *Eur J Orthop Surg Traumatol Springer* 1995;5(1):37–40.
- [3] Argenta LCL, Morykwas MJM. Vacuum-assisted closure: a new method for wound control and treatment: clinical experience. *Annals of Plastic Surgery* 1997;38(6):563–77.
- [4] Schuster RR, Moradzadeh AA, Waxman KK. The use of vacuum-assisted closure therapy for the treatment of a large infected facial wound. *Am Surg* 2006;72(2):129–31.
- [5] Andrews BT, Smith RB, Goldstein DP, et al. Management of complicated head and neck wounds with vacuum-assisted closure system. *Head Neck* 2006;28(11):974–81.
- [6] Andrews BT, Smith RB, Hoffman HT, et al. Orocutaneous and pharyngocutaneous fistula closure using a vacuum-assisted closure system. *Ann Otol Rhinol Laryngol* 2008;117(4):298–302.
- [7] Rosenthal EL, Blackwell KE, McGrew B, et al. Use of negative pressure dressings in head and neck reconstruction. *Head Neck* 2005;27(11):970–5.
- [8] Schwartz S. Predictors of wound complications after laryngectomy: a study of over 2000 patients. *Otolaryngol Head Neck Surg* 2004;131(1):61–8.
- [9] Dirven R, Swinson BD, Gao K, et al. The assessment of pharyngocutaneous fistula rate in patients treated primarily with definitive radiotherapy followed by salvage surgery of the larynx and hypopharynx. *Laryngoscope* 2009;119(9):1691–5.
- [10] Bohannon IA, Carroll WR, Magnuson JS, et al. Closure of post-laryngectomy pharyngocutaneous fistulae. *Head Neck Oncol* 2011;3:29.
- [11] Cordova A, Corradino B, Pirrello R, et al. Surgical treatment of pharyngostomes in irradiated patients. Our experience with musculocutaneous pectoralis major flap and hyperbaric oxygen therapy. *Acta Otolaryngol* 2005;125(7):759–64.
- [12] Werner A, Laccourreye O. Le miel en oto-rhino-laryngologie: quand, pourquoi et comment? *Ann Fr Otorhinolaryngol Pathol Cervicofac* 2011;128(3):153–7 [Elsevier Masson SAS].
- [13] Diallo BKB, Lacher-Fougere SS, Baltazart BB, et al. [Results of alginate and hypertonic solution in wound healing of head and neck cancers]. *Rev Laryngol Otol Rhinol (Bord)* 2007;129(4–5):289–92.
- [14] Mclean JN, Nicholas C, Duggal P, et al. Surgical management of pharyngocutaneous fistula after total laryngectomy. *Ann Plast Surg* 2012;68(5):442–5.
- [15] Caluraud S, Hibon R, Drahy A, et al. Rôle du Tachosyl® dans la prévention des pharyngostomes et des fistules salivaires post-chirurgicaux. *Ann Fr Otorhinolaryngol Pathol Cervicofac* 2012;129(4):A66.
- [16] Gallo O, Deganello A, Meccariello G, et al. Vacuum-assisted closure for managing neck abscesses involving the mediastinum. *Laryngoscope* 2012;122(4):785–8.
- [17] Dhir K, Reino AJ, Jon L. Vacuum-assisted closure therapy in the management of head and neck wounds. *Laryngoscope* 2009;119(1):54–61.
- [18] Orgill DP, Bayer LR. Update on negative-pressure wound therapy. *Plast Reconstr Surg* 2011;127:105S–15S.
- [19] Morykwas MJ, Simpson J, Pungner K, et al. Vacuum-assisted closure: state of basic research and physiologic foundation. *Plast Reconstr Surg* 2006;117(Supplement):121S–6S.
- [20] Schintler MV. Negative pressure therapy: theory and practice. *Diabetes Metab Res Rev* 2012;28:72–7.
- [21] Franczyk M, Lohman RF, Agarwal JP, et al. The impact of topical lidocaine on pain level assessment during and after vacuum-assisted closure dressing changes: a Double-Blind, Prospective Randomized Study. *Plas Reconstr Surg* 2009;124(3):854–61.
- [22] Timmers MS, Le Cessie S, Banwell P, et al. The effects of varying degrees of pressure delivered by negative-pressure wound therapy on skin perfusion. *Ann Plast Surg* 2005;55(6):665–71.
- [23] Benec A, Arcuri F, Poglio G, et al. Vacuum-assisted closure therapy in reconstructive surgery. *Acta Otorhinolaryngol Ital* 2012;32(3):192–7.
- [24] Le Franc B, Sellal O, Grimandi G, et al. Evaluation coût-efficacité de la thérapie par pression négative dans la préparation chirurgicale des pertes de substance cutanée. *Ann Chir Plast Esthet* 2010;55(3):195–203.
- [25] Haute Autorité de santé. Traitement des plaies par pression négative (TPN): des utilisations spécifiques et limitées, 15. HAS; 2011. p. 1–4.