

Available online at www.sciencedirect.com**SciVerse ScienceDirect**

Journal of the Chinese Medical Association 74 (2011) 473–477

www.jcma-online.com

Case Report

Combination photodynamic therapy and intravitreal bevacizumab used to treat circumscribed choroidal hemangioma

Chih-Chien Hsu^a, Chang-Sue Yang^{a,b,*}, Chih-Han Peng^a, Fenq-Lih Lee^{a,b}, Shui-Mei Lee^{a,b}^aDepartment of Ophthalmology, Taipei Veterans General Hospital, Taipei, Taiwan, ROC^bNational Yang-Ming University School of Medicine, Taipei, Taiwan, ROC

Received January 10, 2011; accepted March 25, 2011

Abstract

Circumscribed choroidal hemangioma (CCH) is an ocular tumor that can result in decreased vision or blindness. Numerous treatment methods have been reported without satisfying results. In recent years, photodynamic therapy (PDT) with verteporfin has been used to treat choroidal hemangioma and resolve the associated exudative retinal detachment, and the results have been inspiring. Here, we report the case of a 36-year-old man with longstanding CCH who suffered from blurred vision for 3 years. He underwent PDT with intravenous infusions of verteporfin, which was a treatment method based on a modified version of the standard macular degeneration PDT protocol, in addition to subsequent intravitreal administrations of bevacizumab as adjuvant therapy for macular edema. Twelve months after treatment, the CCH tumor remained noticeably shrunken, with the complete absorption of the subretinal fluid and the absence of macular edema. In terms of treating subretinal fluid retention, this combination treatment is a safe, effective, and long-lasting therapy for treating established CCH tumors. However, even though the patient's visual field defects improved, the patient's visual acuity remained stable at 6/60 without further improvement. Long-term CCH with prolonged macular edema might have affected the visual prognosis. Patients with CCH still require long-term follow-up examinations after receiving PDT treatments. Copyright © 2011 Elsevier Taiwan LLC and the Chinese Medical Association. All rights reserved.

Keywords: Bevacizumab; circumscribed choroidal hemangioma; exudative retinal detachment; photodynamic therapy

1. Introduction

Choroidal hemangioma is an uncommon, benign ocular tumor. It is usually solitary and circumscribed, but sometimes it can present with diffuse thickening of the choroid, which is associated with Sturge-Weber syndrome. Circumscribed choroidal hemangioma (CCH) is a discrete, smooth, round, orange-red mass in the posterior pole that is mainly confined to the macular and peripapillary regions; however, variations in the anatomic location do exist. The functional symptoms vary from asymptomatic lesions to severe vision loss.¹ Treatment is warranted if the patient's vision decreases or is threatened due to secondary exudative retinal detachment, macular edema, subfoveal fluid,

or a juxtafoveal tumor that could potentially compromise central vision.² Xenon arc, argon laser photocoagulation, transpupillary thermotherapy (TTT), and radiotherapy have been described as CCH treatments in the literature. However, these treatments have limited efficacy because scarring usually affects the fovea near the central lesions and limits the visual outcome.^{3,4} Radiation-associated complications also limit the use of radiation therapies.^{5–7} Recently, photodynamic therapy (PDT) with verteporfin has been shown to be an effective treatment for CCH, with the added benefit of selectively preserving the overlying neuroretinal structures.^{8–10} Here, we report our experience of treating a patient with longstanding CCH using combination PDT and intravitreal administration of bevacizumab.

2. Case report

A 36-year old man visited our clinic and claimed to suffer from progressively blurred vision in his right eye for the past

* Corresponding author. Dr. Chang-Sue Yang, Department of Ophthalmology, Taipei Veterans General Hospital, 201, Sec. 2, Shih-Pai Rd., Taipei 112, Taiwan, ROC.

E-mail address: csyang@vghtpe.gov.tw (C.-S. Yang).

3 years. The ocular tumor in his right eye had been diagnosed in another hospital based on observations alone. The patient came to our hospital for a second opinion because of the lack in visual improvement. The patient's best corrected visual acuity was 3/60 OD and 6/6 OS. Indirect funduscopy revealed a solitary, orange, choroid tumor with overlying sensory retinal detachment over the macula of the right eye (Fig. 1A). Fluorescein angiography (FA) showed rapid dye filling of the tumor in the pre-arterial choroidal phase, a rapid and intense hyperfluorescent vascular filling pattern within choroidal hemangioma, and a flower-petal dye-pooling pattern in the upper fovea (Fig. 1B). Indocyanine green angiography (ICGA) exhibited early and rapid dye filling in the choroid and early arterial phases of the tumor (Fig. 2A), washed-out hypofluorescence of the tumor, and retinal pigment epithelium (RPE) degeneration of the overlying retina at the apex of the tumor in late phase (Fig. 2B). Examination of the visual field revealed a scotoma over the central and partially nasal inferior areas of the right eye. B-scan sonography showed a choroidal, oval-shaped lesion measuring 5.4 mm across by 11.0 mm in diameter that was acoustically solid with a high internal reflectivity (Figs. 3A, 3B). Magnetic resonance imaging (MRI) exhibited a nodular lesion that was hyperintense on T1-weighted imaging and hypointense on T2-weighted imaging. Optical coherence tomography (OCT) showed exudative retinal detachment, cystic macular edema, and subretinal fluid retention over the tumor (Fig. 4A). After excluding the diagnosis of choroidal metastasis and choroidal melanoma, PDT

was recommended as the best course of action for reducing the exudation of the lesion.

A modified version of the standard macular degeneration PDT protocol was applied. Intravenous perfusion of verteporfin was administered at a dosage of 6 mg/m² for 10 minutes. Fifteen minutes after beginning the perfusion, a single-spot diode laser (689 nm) with spot size of 7200 nm² was applied for 113 seconds instead of 83 seconds. This procedure was based on an early ICGA image of the CCH tumor.

One month after PDT, OCT showed residual subretinal fluid retention and cystic macular edema in the right eye (Fig. 4B). An intravitreal injection of bevacizumab (2.5 mg/0.1 mL) (Avastin, Genentech, San Francisco, CA, USA) was administered to treat the chronic macular edema. Rapid resorption of the subretinal fluid and regression of the macular edema was noted 2 weeks after the injection of bevacizumab.

No tumor recurrence was noted 12 months after PDT, and the patient's best corrected visual acuity had improved and remained stable at 6/60 OD. Indirect funduscopy revealed a regressed, gray choroid tumor in the right eye (Fig. 1C). FA showed a mostly hypofluorescent tumor with only slight dye filling and staining after PDT and the absence of macular edema (Fig. 1D). ICGA exhibited less dye filling with tumor regression, and the late phase showed a hypofluorescent tumor with marginal hyperfluorescence (Figs. 2C, 2D). Examination of the visual field revealed a less central scotoma in the right eye. B-scan sonography showed an obvious decrease in the thickness of the hemangioma lesion to 4.0 mm (Fig. 3C). OCT

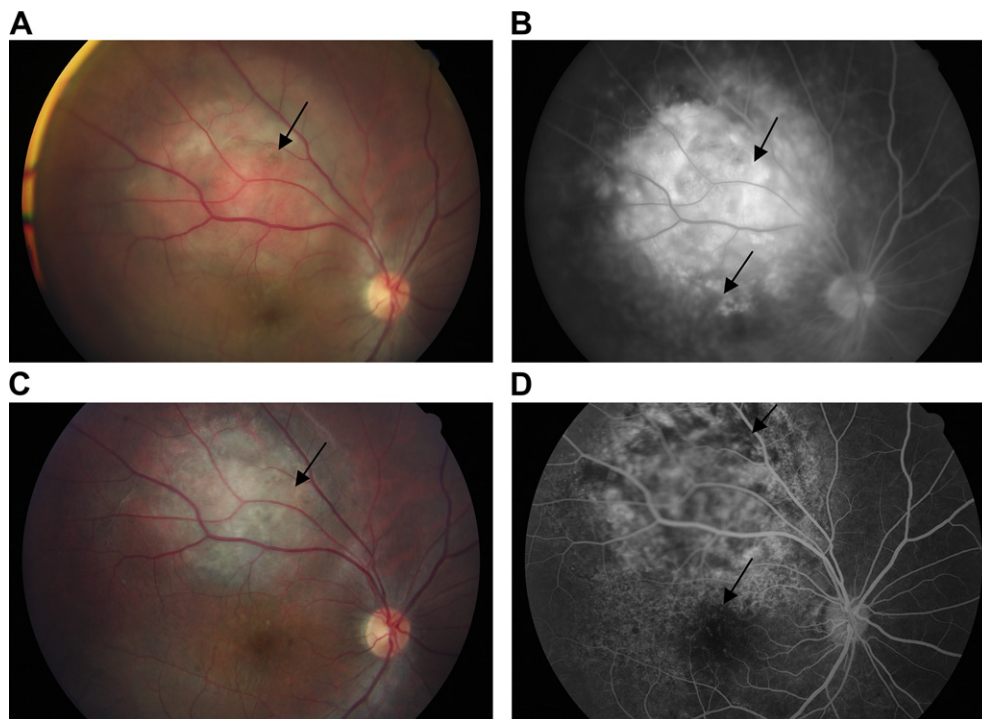


Fig. 1. (A) Fundus photograph showing a solitary, orange, choroid tumor located on the superior vascular arcade of the macula and the associated, overlying, exudative retinal detachment. (B) Fluorescein angiographic image (FA) revealing a rapid and intense hyperfluorescent vascular-filling pattern within the choroidal hemangioma (upper arrow) and flower-petal dye-pooling pattern on the upper fovea (lower arrow). (C) Taken 1 year after photodynamic therapy (PDT), this fundus photograph shows an obviously regressed tumor that has turned gray. (D) FA shows a mostly hypofluorescent tumor with slight dye filling and staining after PDT (upper arrow) and the absence of macular edema (lower arrow).

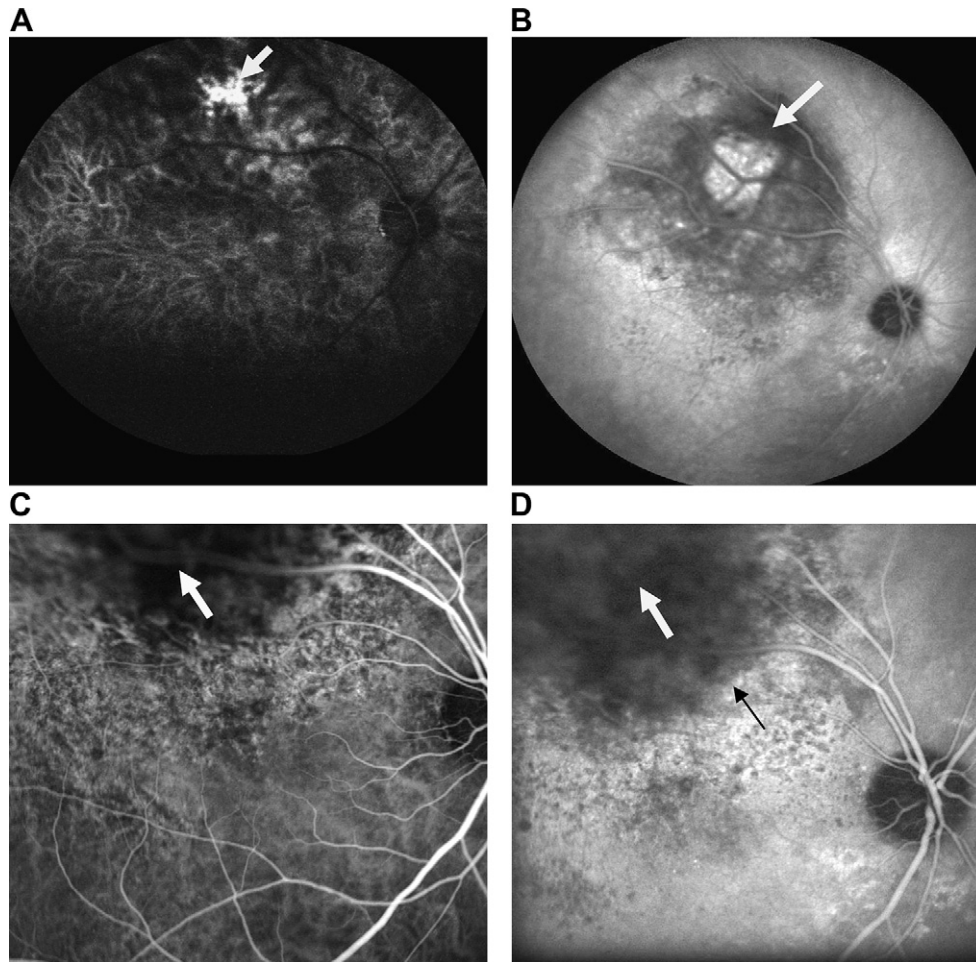


Fig. 2. (A) Early indocyanine angiographic image (ICGA) showing early dye filling of the tumor in the choroid and early arterial phases. (B) Washed-out hypofluorescence of the tumor and RPE degeneration of the overlying retinal structures at the apex of the tumor in late phase. (C) One year after PDT, early-phase ICGA reveals hypofluorescence with only slight dye filling and an obviously regressed tumor. (D) Late-phase ICGA showing a hypofluorescent tumor (upper arrow) with hyperfluorescent staining at the margins (lower arrow).

showed normal foveal contours and the absence of subfoveal fluid retention (Fig. 4C).

3. Discussion

Photodynamic therapy is a safe, rapid, and widely available outpatient procedure for age-related macular degeneration (AMD). PDT only produces selective photochemical injuries to the choroidal vascular endothelial cells without damaging the overlying retina structures. Verteporfin, as a photosensitizer, is injected intravenously. Exposure to a low power diode laser (689 nm) then activates verteporfin and occludes the abnormal vessels of the choroid.^{8–10} Compared with other methods for treating CCH, PDT is more suitable for subfoveal CCH. The use of PDT for treating symptomatic CCH is based on experimental studies on animals with choroidal tumors.⁵ Among the currently available therapeutic modalities, PDT has shown the best clinical results for treating CCH and associated exudative retinal detachment. Previous clinical studies on using PDT to treat CCH have reported decreases in tumor size and improvement in visual acuity.^{8–11} Recently,

a prospective, nonrandomized, multicenter clinical trial enrolled 31 patients to study the effect of PDT on patients with CCH.¹² The CCH thickness decreased and exudative detachment was resolved in all cases, with 69% of patients reporting visual recovery.¹² Patients with symptomatic juxtafoveal CCH who were treated with PDT have shown tumor regression, preservation of the overlying retina, and either stable or improved visual acuity.³ The efficacy and safety of PDT for treating CCH were also reported in a long-term follow-up study.¹³ Repeated PDT sessions can be performed if inadequate tumor regression is noted.¹⁰ However, delayed choroidal atrophy can result from repeated sessions on previously treated areas or overlapping exposure.¹¹ In the current case, PDT treatment was safe and effective in terms of tumor regression and resolution of exudative retinal detachment.

Vascular endothelial growth factor (VEGF) is a potent stimulator of vascular leakage and endothelial proliferation and migration.¹⁴ Moreover, Wang et al. reported that tumor cell-secreted VEGF increases the permeability of the vascular endothelium by affecting occludin expression and the assembly of tight junctions.¹⁵ Anti-VEGF therapy may lead to a reduction

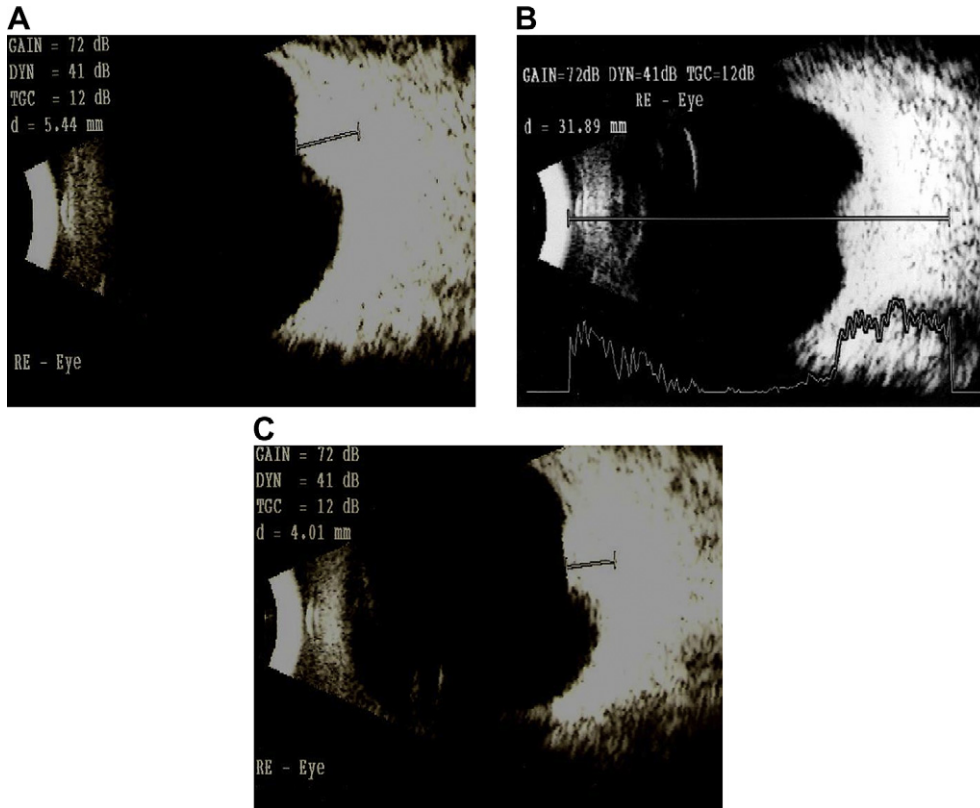


Fig. 3. (A) B-scan ultrasound showing an acoustically solid choroid tumor measuring 5.4 mm in height by 11.0 mm in diameter. (B) A-scan ultrasound showing high internal reflectivity within the tumor. (C) B-scan ultrasound performed 1 year after PDT showing that the tumor thickness has decreased to 4.0 mm.

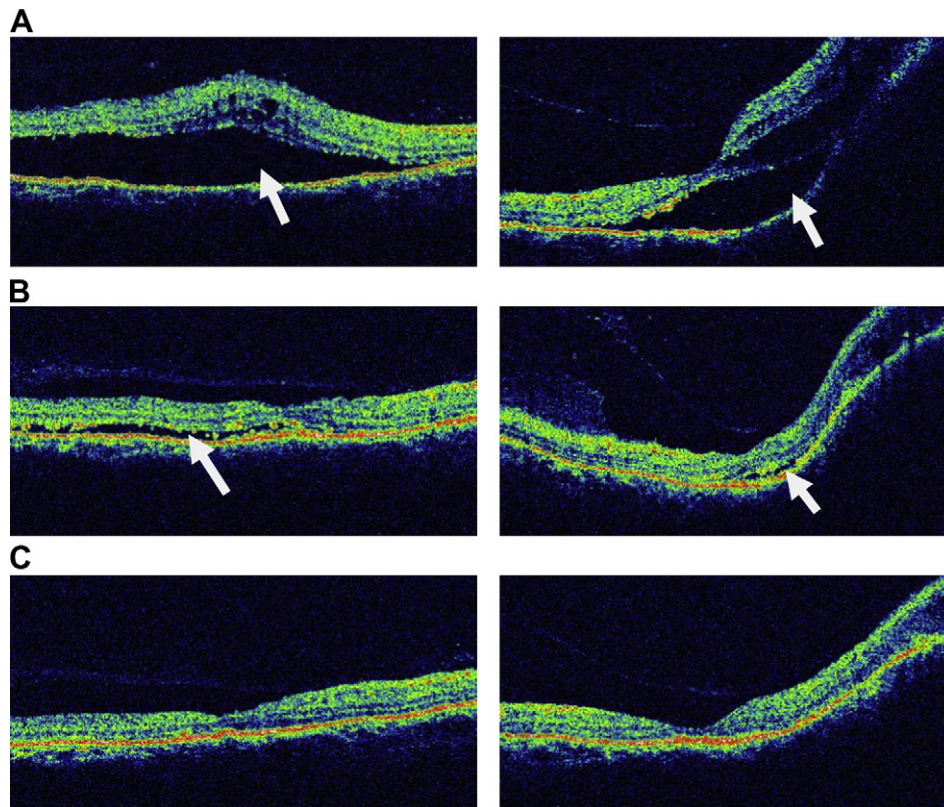


Fig. 4. (A) Pretreatment optical coherence tomography (OCT) showing subfoveal exudative detachment and subretinal fluid retention over the tumor (left picture, horizontal scan; right picture, vertical scan). (B) OCT performed 1 month after PDT revealing minimal residual subfoveal fluid retention and a slightly flattened hemangioma tumor with few exudates. (C) OCT performed 1 year after PDT showing normal foveal contours, the absence of any subfoveal fluid retention, and an obviously thinner hemangioma.

in tumor-associated exudation, presumably by depleting endothelial fenestrae and altering intercellular adhesion molecules.¹⁵ Theoretically, blocking VEGF may reverse macular edema and subretinal fluid complications that result from choroidal hemangioma tumors. Thus, we believe that anti-VEGF therapy could be a promising adjuvant therapy for treating long-standing CCH with macular edema. However, repeated intravitreal injections might be necessary due to the short-term effects of this therapy. Bevacizumab is a recombinant monoclonal antibody that binds all isoforms of VEGF.¹⁶ The systemic administration of bevacizumab is approved for metastatic colon cancer. Recently, Sagong et al. reported intravitreal bevacizumab alone, or when applied in combination therapy with PDT, is a useful alternative for treating symptomatic CCH with subretinal fluid and macular edema in three individual cases.¹⁷ We believe that combination PDT and intravitreal bevacizumab might maximize the therapeutic effects of PDT in patients with long-standing CCH with macular edema.

Retinal photoreceptor cell degeneration may occur as a result of longstanding exudative retinal detachment with foveal involvement. Following PDT treatment, visual acuity might not improve if patients have been symptomatic for more than a period of 30 months.^{4,9,13} In the current case, one month after PDT, OCT showed markedly decreased subretinal fluid retention, and the B-scan showed a noticeably shrunken tumor. We performed additional intravitreal injections of bevacizumab to treat the residual subretinal fluid retention and cystic macular edema. No tumor recurrence, residual subretinal fluid retention, or macular edema were noted during 12 months of follow-up examinations. However, the patient's visual acuity remained stable without further improvement due to the long-standing CCH and photoreceptor cell dysfunction.

In conclusion, longstanding circumscribed choroidal hemangioma can be treated with combination PDT and intravitreal bevacizumab. PDT can resolve subretinal fluid retention and shrink CCH tumors without damaging the overlying retinal structure. Bevacizumab is very useful for promoting the resorption of subretinal fluid and the regression of macular edema in patients with long-standing CCH. This combination therapy should be the first treatment choice for clinicians treating patients with CCH tumors. CCH patients, however, still require long-term follow-up examinations following PDT treatment.

Acknowledgments

This study was supported by grants from the National Science Council and Taipei Veterans General Hospital (V98C1-187, V99C1-009) of Taiwan.

References

- Gass JDM. *Differential diagnosis of intraocular tumors: a stereoscopic presentation*. St. Louis: CV Mosby; 1974. p.113–118.
- Scott IU, Gorskak J, Gass JD, Feuer WJ, Murray TG. Anatomic and visual acuity outcomes following thermal laser photocoagulation or photodynamic therapy for symptomatic circumscribed choroidal hemangioma with associated serous retinal detachment. *Ophthalmic Surg Laser Imag* 2004;**35**:281–91.
- Shields JA, Shields CL, Materin MA, Marr BP, Demirci H, Mashayekhi A. Changing concepts in management of circumscribed choroidal hemangioma: the 2003 J. Howard Stokes lecture, part 1. *Ophthalmic Surg Laser Imag* 2004;**35**:383–94.
- Shields CL, Honavar SG, Shields JA, Cater J, Demirci H. Circumscribed choroidal hemangioma: clinical manifestations and factors predictive of visual outcome in 200 consecutive cases. *Ophthalmology* 2001;**108**:2237–48.
- Schilling H, Sauerwein W, Lommatzsh A, Friedrichs W, Brylak S, Bornfeld N, et al. Long-term results after low dose ocular irradiation for choroidal hemangiomas. *Br J Ophthalmol* 1997;**81**:267–73.
- Ritland JS, Eide N, Tausjo J. External beam irradiation therapy for choroidal hemangiomas. Visual and anatomical results after a dose of 20 to 25 Gy. *Acta Ophthalmol Scand* 2001;**79**:184–6.
- Frau E, Rumen F, Noel G, Delacroix S, Habrand JL, Offret H. Low-dose proton beam therapy for circumscribed choroidal hemangiomas. *Arch Ophthalmol* 2004;**122**:1471–5.
- Barbazetto I, Schmidt-Erfurth U. Photodynamic therapy of choroidal hemangioma: two case reports. *Graefes Arch Clin Exp Ophthalmol* 2000;**238**:214–21.
- Jurklics B, Anastassiou G, Ortman S, Schüler A, Schilling H, Schmidt-Erfurth U, et al. Photodynamic therapy using verteporfin in circumscribed choroidal haemangioma. *Br J Ophthalmol* 2003;**87**:84–9.
- Gupta M, Singh AD, Rundle PA, Rennie IG. Efficacy of photodynamic therapy in circumscribed choroidal hemangioma. *Eye* 2004;**18**:139–42.
- Khuu T, Hoffman DJ. Circumscribed choroidal hemangioma: a case report and review of the literature. *Optometry* 2006;**77**:384–91.
- Boixadera A, García-Arumí J, Martínez-Castillo V, Encinas JL, Elizalde J, Blanco-Mateos G, et al. Prospective clinical trial evaluating the efficacy of photodynamic therapy for symptomatic circumscribed choroidal hemangioma. *Ophthalmology* 2009;**116**:100–5.
- Michels S, Michels R, Simader C, Schmidt-Erfurth U. Verteporfin therapy for choroidal hemangioma: a long-term follow-up. *Retina* 2005;**25**:697–703.
- Noma H, Funatsu H, Yamasaki M, Tsukamoto H, Mimura T, Sone T, et al. Pathogenesis of macular edema with branch retinal vein occlusion and intraocular levels of vascular endothelial growth factor and interleukin-6. *Am J Ophthalmol* 2005;**140**:256–61.
- Wang W, Dentler WL, Borchardt RT. VEGF increases BMEC monolayer permeability by affecting occludin expression and tight junction assembly. *Am J Physiol Heart Circ Physiol* 2001;**280**:H434–40.
- Hurwitz H, Fehrenbacher L, Novotny W, Cartwright T, Hainsworth J, Heim W, et al. Bevacizumab plus irinotecan, fluorouracil, and leucovorin for metastatic colorectal cancer. *N Engl J Med* 2004;**350**:2335–42.
- Sagong M, Lee J, Chang W. Application of intravitreal bevacizumab for circumscribed choroidal hemangioma. *Korean J Ophthalmol* 2009;**23**:127–31.