

CASE REPORT

Optic Neuritis Following Hepatitis B Vaccination in a 9-year-old Girl

Muferet Erguven¹, Sirin Guven^{2*}, Umit Akyuz³, Olcay Bilgiç¹, Fuat Laloglu¹

¹Goztepe Educational and Research Hospital, ²Umraniye Educational and Research Hospital, and ³Zeynep-Kamil Educational and Research Hospital, Istanbul, Turkey.

Hepatitis B vaccination can prevent hepatitis B virus infection and its serious consequences, including liver cancer and cirrhosis. Serious side effects reported after receiving hepatitis B vaccination are very uncommon. A majority of the ophthalmological complications seen following hepatitis B vaccination consist of vision loss, optic neuritis, papillary edema, uveitis, acute placoid pigment epitheliopathy and central vein occlusion. We present a 9-year-old girl who was referred to our hospital with decrease in vision and pain in the left eye a week after hepatitis B vaccination. A diagnosis of vaccine-induced optic neuritis was made. The clinical picture improved after systemic corticosteroid treatment. Acute optic neuritis might be a rare complication of hepatitis B vaccination. Parents should be aware of the potential serious side effects of the vaccine. [*J Chin Med Assoc* 2009;72(11):594–597]

Key Words: children, hepatitis B vaccine, hepatitis B virus, optic neuritis

Introduction

In 1992, the World Health Organization recommended that all countries should have universal infant and/or adolescent hepatitis B vaccination program.¹ Routine hepatitis B vaccination program for newborns was introduced into our national vaccination program in 1998. Hepatitis B vaccines are prepared from highly purified hepatitis B virus surface antigen (HBsAg). Minor side effects such as local pain, fever, asthenia, polymyalgia, headache, and chronic fatigue syndrome are frequently reported. The hepatitis B vaccine has been linked to immunological and neurological disorders, including rheumatoid arthritis, multiple sclerosis, Guillain-Barré syndrome, encephalomyelitis, diabetes, and optic neuritis.^{2–9} Optic neuritis is defined as inflammation of the optic nerve. Pain and temporary vision loss are common symptoms of optic neuritis. The most frequent cause of optic neuritis is multiple sclerosis; other reasons include viral and bacterial infections and medical reactions. Optic neuritis may develop after hepatitis B vaccination.^{7–10}

The mechanism of retrobulbar optic neuritis is uncertain, but autoimmune inflammation has been suggested.^{11,12} Treatment with systemic steroids leads

to regression of inflammation in the optic nerve. Only a few pediatric cases of optic neuritis as a complication after hepatitis B vaccination have been reported in the medical literature so far. Here, we report a case of this rare possible complication of hepatitis B immunization.

Case Report

A previously healthy 9-year-old girl was referred to our hospital with decrease in vision and pain in the left eye 1 week after hepatitis B vaccination. Systematic physical and neurological examinations were unremarkable. Fundus examination revealed optic disc edema and parapapillary hemorrhage. Visual acuity was established as 4/10 (Figure 1). A diagnosis of optic neuritis was considered. The patient did not have a history of lead exposure, and had not previously received radiotherapy or used any other agents that could have caused optic neuritis such as ethambutol, isoniazid, chloramphenicol, or vincristine.

Serological tests for the following were negative: *Treponema pallidum* agglutination reaction test, human immunodeficiency virus antibodies (anti-HIV: 0.20 S/CO), cytomegalovirus antibodies (anti-CMV),



*Correspondence to: Dr Sirin Guven, Umraniye Egitim ve Arastirma Hastanesi, Istanbul, Turkey.
E-mail: sirin2006@gmail.com • Received: May 29, 2009 • Accepted: September 22, 2009

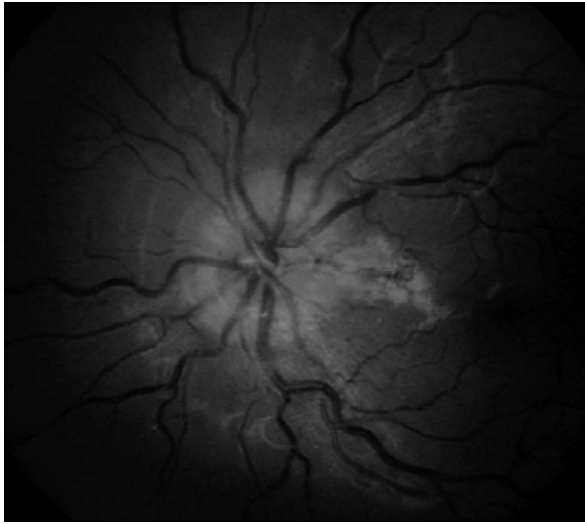


Figure 1. Optic disc with bilateral edema.

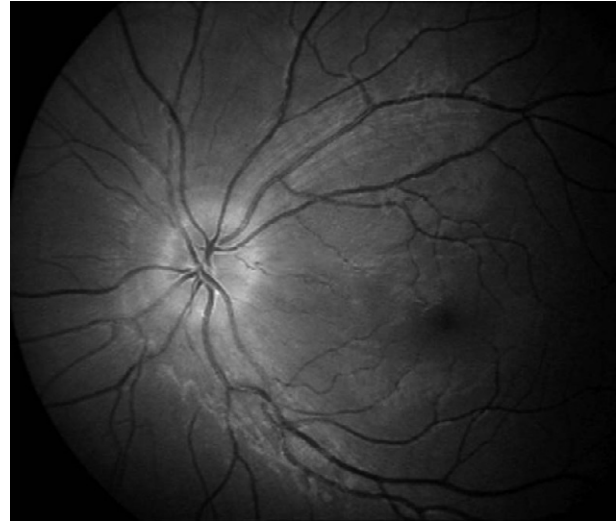


Figure 2. Improvement in optic disc edema following treatment.

hepatitis B surface antigen (HbsAg: 0.46 S/CO), IgM antibody to hepatitis B core antigen (anti-HBc IgM: 0.06 S/CO), IgM antibody to hepatitis A virus (anti-HAV IgM: 0.16 S/CO) and hepatitis C virus antibodies (anti-HCV: 0.21 S/CO). Hepatitis B surface antibody (anti-HBs) was positive: >100 mIU/mL. Antinuclear antibody (ANA: 1:20) and anti-double stranded DNA antibody (anti-dsDNA < 10 IU/mL) titers were negative.

Hematological and biochemical parameters were within normal limits. Examination of a cerebrospinal fluid (CSF) sample for presence of white blood cells, red blood cells, protein content, and glucose level was normal. Blood, CSF and tuberculosis cultures were negative. Computed tomography and magnetic resonance imaging of the brain were normal. We identified the differential diagnoses as multiple sclerosis, intracranial tumors, obstructive hydrocephaly, intracranial hemorrhage, edema secondary to trauma, meningoencephalitis, and toxic encephalopathy.

A diagnosis of vaccine-induced optic neuritis was made. The patient was treated with pulsed-dose steroid (30 mg/kg/day) for 4 days. Results of the visual acuity evaluation performed during these 4 days of treatment were 4/10, 7/10, 9/10 and 10/10, respectively. Visual acuity improved after 2 weeks of systemic corticosteroid treatment. We observed total recovery in the long-term follow-up (Figure 2).

Discussion

A vaccine against hepatitis B virus first became available in the United States in 1982. Hepatitis B vaccination has a key role in the control of hepatitis B. Mass

hepatitis B vaccination in children decreases the carriage of the virus and thus prevents the serious consequences of hepatitis B virus infection, including liver cancer and cirrhosis.² A study in Taiwan showed that 6–10 years after the initiation of the hepatitis B mass-vaccination program, the incidence of childhood hepatocellular carcinoma had declined significantly.³

Several local and systemic side effects such as myalgia, fatigue, transient fever, headache, dizziness, nausea, and vomiting, can be observed within 24–48 hours following hepatitis B vaccination. Serious adverse effects reported after receiving hepatitis B vaccine are very uncommon.^{4,6–8} Although many serious effects are claimed to be associated with hepatitis B vaccination, a causal association between hepatitis B vaccination and chronic fatigue syndrome, arthritis, diabetes and autoimmune disorders has not been established. The majority of ophthalmological complications following vaccination consists of vision loss, optic neuritis, papillary edema, uveitis, acute placoid pigment epitheliopathy, and central vein occlusion.^{9–11} Most of these side effects might be related to immune complexes. Three mechanisms—molecular mimicry, bystander activation, and superantigen stimulation—may play roles in the development of demyelinating diseases of the central and peripheral nervous systems.^{12,13} Vaccination could enhance the risk of autoimmunity in genetically-susceptible individuals.¹³ Shaw et al evaluated neurological events associated with hepatitis B vaccination. They investigated 850,000 individuals who received the plasma-derived hepatitis B vaccine. They found 10 cases of Bell's palsy, 9 cases of Guillain-Barré syndrome, 5 cases of lumbar radiculopathy, 3 cases of brachial plexus neuropathy, 5 cases of optic neuritis, and 4 cases of transverse myelitis.¹⁴ Plasma-derived hepatitis B vaccine

Table 1. Summary of cases with optic neuritis following hepatitis B vaccination

Optic neuritis after hepatitis B vaccine	Cases (n)	Median age (yr)	Median onset (d)
Reported in the scientific literature ¹⁵	4	43	7
Reported in the VAERS database ¹⁵	96	33	13
Mikaeloff et al ¹⁶	19	9.3 ± 4.6*	Not specified
Roussat et al ¹⁷	2	10.7	Not specified

*Mean ± standard deviation.

is not produced in the United States, but such vaccines are still being produced in other countries.

Recombinant hepatitis B vaccine may also induce serious side effects, including autoimmune diseases, vasculitis, demyelinating neurological diseases and ophthalmological diseases.³⁻⁹

Geier and Geier searched the Vaccine Adverse Event Reporting System (VAERS) database and the scientific literature for adverse events following hepatitis B vaccination.¹⁵ They found that post-vaccination serious adverse effects were primarily observed among adult hepatitis B vaccine recipients, with a female/male ratio of 2.2, and within a few days to weeks following immunization (Table 1). Our patient was female but younger (9 years old) than the patients evaluated by Geier and Geier. She presented to our hospital with decrease in vision and pain in the left eye a week after hepatitis B vaccination; the onset of clinical manifestations was similar with the median onset reported in this large study. We reviewed all available scientific and medical data about ophthalmological complications after hepatitis B vaccination in children; only a few pediatric cases of optic neuritis as a complication of hepatitis B vaccination have been reported. Mikaeloff et al¹⁶ evaluated the risk of acute central nervous system (CNS) inflammatory demyelination in childhood after hepatitis B vaccination. The mean age of the 349 cases included in the study was 9.3 ± 4.6 years; isolated optic neuritis was reported in 19 (9.6%) cases with a single episode of acute CNS inflammatory demyelination without relapse. This population-based case-control study reported that hepatitis B vaccine did not increase the risk of CNS inflammatory demyelination in childhood within a risk period of ≥ 3 years or considering the number of injections. Roussat et al analyzed the

clinical features and treatment of acute optic neuritis in children; they found only 2 cases after hepatitis B vaccination.¹⁷ The mean age of patients was 10.7 years. They reported that healing was accelerated with high-dose steroid treatment. We applied pulsed-dose steroid for 4 days at a dose of 30 mg/kg/day in our 9-year-old patient, and observed significant improvements in the visual acuity evaluations performed during treatment.

Structural changes of the disc (pseudopapillary edema, pseudoneuritis), hypertension, diabetes mellitus, bacterial and viral infections, intracranial tumors, cerebral edema secondary to trauma, meningoencephalitis, and some metabolic diseases should also be considered in the differential diagnoses of optic disc edema. In children, optic neuritis can be seen in conjunction with neuromyelitis optica (Devic's disease). This syndrome presents with rapid and severe bilateral vision loss, transverse myelitis, and paraplegia. Optic neuritis can also develop secondary to an exogenous toxin or medicine. Our patient did not have a history of drug use or exposure to toxic agents. No causes other than vaccination were found.

In conclusion, hepatitis B vaccine is safe and effective and can be used in newborns. Optic neuritis is a very rare complication of hepatitis B vaccination in childhood. Parents should be aware of the potential serious side effects of the vaccine. Since the vaccination provides protection against hepatitis B and its severe long-term complications, the risks of the vaccine are outweighed by the prophylactic benefits of vaccination. We conclude that the present universal hepatitis B vaccination program to eradicate hepatitis B should be continued.

References

1. World Health Organization. *WHO Vaccine Preventable Diseases Monitoring System: Global Summary*. Geneva, Switzerland: World Health Organization, 2002; document no. WHO/V&B/02.20.
2. Chen DS. Hepatitis B vaccination: the key towards elimination and eradication of hepatitis B. *J Hepatol* 2009;50:805-16.
3. Chang MH, Chen CJ, Lai MS, Hsu HM, Wu TC, Kong MS, Liang DC, et al. Universal hepatitis B vaccination in Taiwan and the incidence of hepatocellular carcinoma in children. Taiwan Childhood Hepatoma Study Group. *N Engl J Med* 1997; 336:1855-9.
4. Pope JE, Stevens A, Howson W, Bell DA. The development of rheumatoid arthritis after recombinant hepatitis B vaccination. *J Rheumatol* 1998;25:1687-93.
5. Mikaeloff Y, Caridade G, Rossier M, Suissa S, Tardieu M. Hepatitis B vaccination and the risk of childhood-onset multiple sclerosis. *Arch Pediatr Adolesc Med* 2007;161:1176-82.
6. DeStefano F, Verstraeten T, Jackson LA, Okoro CA, Benson P, Black SB, Shinefield HR, et al. Vaccine Safety Datalink Research Group, National Immunization Program, Centers for Disease Control and Prevention. Vaccinations and risk

- of central nervous system demyelinating diseases in adults. *Arch Neurol* 2003;60:504–9.
7. Zaas A, Scheel P, Venbrux A, Hellmann DB. Large artery vasculitis following recombinant hepatitis B vaccination: 2 cases. *J Rheumatol* 2001;28:1116–20.
 8. Classen JB. Childhood immunization and diabetes mellitus. *NZ Med J* 1996;109:195.
 9. Van De Geijn EJ, Tukkie R, Van Philips LA, Punt H. Bilateral optic neuritis with branch retinal artery occlusion associated with vaccination. *Documenta Ophthalmol* 1994;4:403–8.
 10. Stewart O, Chang B, Bradbury J. Simultaneous administration of hepatitis B and polio vaccines associated with bilateral optic neuritis. *Br J Ophthalmol* 1999;83:1200–1.
 11. Albitar S, Bourgeon B, Genin R, Fen-Chong M, N’Guyen P, Serveaux MO, Atchia H, et al. Bilateral retro bulbar optic neuritis with hepatitis B vaccination. *Nephrol Dial Transplant* 1997; 12:2169–70.
 12. Carmeli Y, De Medina T. Serious hepatitis B vaccine adverse reactions: are they immune-mediated? *Vaccine* 1993;11: 1358–9.
 13. Geier DA, Geier MR. A case-control study of serious autoimmune adverse events following hepatitis B immunization. *Autoimmunity* 2005;38:295–301.
 14. Shaw FE Jr, Graham DJ, Guess HA, Milstien JB, Johnson JM, Schatz GC, Hadler SC, et al. Post-marketing surveillance for neurologic adverse events reported after hepatitis B vaccination. Experience of the first three years. *Am J Epidemiol* 1988; 127:337–52.
 15. Geier MR, Geier DA. A case-series of adverse events, positive re-challenge of symptoms, and events in identical twins following hepatitis B vaccination: analysis of the Vaccine Adverse Event Reporting System (VAERS) database and literature review. *Clin Exp Rheumatol* 2004;22:749–55.
 16. Mikaeloff Y, Caridade G, Suissa S, Tardieu M. Hepatitis B vaccine and risk of CNS inflammatory demyelination in childhood. *Neurology* 2009;72:873–80.
 17. Roussat B, Gohier P, Doummar D, Iba-Zizen MT, Barbat V, Jarry D, Cabanis EA, et al. Acute optic neuritis in children: clinical features and treatment. A study of 28 eyes in 20 children. *J Fr Ophtalmol* 2001;24:36–44. [In French]