



REVISTA BRASILEIRA DE ANESTESIOLOGIA

Official Publication of the Brazilian Society of Anesthesiology
www.sba.com.br



SCIENTIFIC ARTICLE

Anesthetic Management and Complications of Percutaneous Aortic Valve Implantation

Tailur Alberto Grando* ¹, Rogério Sarmento-Leite ², Paulo Roberto Lunardi Prates ³,
Claudio Roberto Gomes ⁴, Fabiana Specht ⁵, Alessandra Sarturi Gheller ⁶,
Guilherme Bernardi ²

1. Responsible for the Center for Teaching and Training (CET), Society of Anesthesiology (SANE), Porto Alegre; Anesthesiologist, Institute of Cardiology/Fundação Universitária de Cardiologia de Porto Alegre, Brazil
 2. Interventional Cardiologist, Institute of Cardiology/Fundação Universitária de Cardiologia de Porto Alegre, Brazil
 3. Cardiovascular Surgeon, Institute of Cardiology/Fundação Universitária de Cardiologia de Porto Alegre, Brazil
 4. Anesthesiologist, SANE team, Porto Alegre, Brazil
 5. ME3, CET/SANE, Porto Alegre, Brazil
 6. ME2, CET/SANE, Porto Alegre, Brazil
- Received from Institute of Cardiology/Fundação Universitária de Cardiologia de Porto Alegre, Brazil.

Submitted on May 3, 2012. Approved on August 20, 2012.

KEYWORDS:

Aesthesia, General;
Cardiac Surgical
Procedures;
Aortic Valve Stenosis;
Aged.

Abstract

Background and objective: Aortic stenosis is a highly prevalent and life-threatening disease. In elderly patients with comorbidities, percutaneous valve implantation is an option. The aim of the study was to describe the anesthetic management and complications of general anesthesia.

Method: Case series with 30-day and 24-month follow-ups after implantation of the CoreValve device performed at the Institute of Cardiology/University Foundation of Cardiology between December 2008 and January 2012. The patients underwent general anesthesia monitored with mean arterial pressure (PAM), electrocardiogram (ECG), pulse oximetry, capnography, transesophageal echocardiography, thermometry, and transvenous pacemaker.

Results: Twenty-eight patients, mean age 82.46 years, 20.98% mean EuroSCORE, functional class III/IV, successfully underwent valve implantation. Nine patients required permanent pacemaker implantation. During follow-up, two patients died: one during surgery due to LV perforation and the other on the third day of unknown causes. At 24 months, one patient diagnosed with multiple myeloma died. This anesthetic technique proved to be safe.

Conclusion: The initial experience with percutaneous aortic valve implantation under general anesthesia has proven to be safe and effective, with no significant anesthetic complications during this procedure.

© 2013 Sociedade Brasileira de Anestesiologia. Published by Elsevier Editora Ltda.

Este é um artigo Open Access sob a licença de [CC BY-NC-ND](http://creativecommons.org/licenses/by-nc-nd/4.0/)

*Corresponding author: Avenida Princesa Isabel, 395, Santana, CEP 90 620-000, Porto Alegre, RS. Phone: +55-51- 3230-3600.

E-mail: tailurgrando@gmail.com

ISSN c 2013 Sociedade Brasileira de Anestesiologia. Published by Elsevier Editora Ltda. Este é um artigo Open Access sob a licença de [CC BY-NC-ND](http://creativecommons.org/licenses/by-nc-nd/4.0/)

Introduction

Aortic stenosis (AS) is the most common valvular heart disease. It is insidious, has a long period of latency, followed by rapid progression after the onset of symptoms, resulting in high mortality among untreated patients¹. Aortic valve replacement is the treatment of choice for symptomatic AS. However, according to the Euro Heart Survey on Valvular Disease², one third of these patients is aged over 75 years and has contraindications for conventional surgery. In recent years, percutaneous aortic valve implantation has emerged as a viable and promising treatment option. This new therapeutic approach is designed for patients who have no medical conditions to undergo the classical surgical approach due to the high or unacceptable risk of perioperative morbidity and mortality.

Aortic valve replacement via percutaneous route is a new treatment option for these patients, first used in humans by Cribier et al.³ in 2002. Since then, several clinical trials with different devices have been reported⁴.

There are currently two types of prostheses for clinical use: CoreValve (Medtronic Inc., Minneapolis, MN) and Edwards-Sapien (Edwards Life Sciences Inc., Irvine, CA)^{3,5-7}.

Ideally, these procedures would involve a multidisciplinary team and be performed in hybrid operating rooms. The hybrid room is a more appropriate space for this purpose because it is larger, has better monitoring, and facilitates migration to a surgical event requiring cardiopulmonary bypass.

The anesthetic technique for percutaneous valve implantation is yet to be decided between deep sedation and general anesthesia. To choose the best anesthetic technique, the patient's comfort and immobility at important times of the procedure, the physical area restriction, and the involvement of various professionals should all be considered.

The objective of this study was to describe the anesthetic technique and complications in patients undergoing percutaneous valve implantation under general anesthesia.

Method

Longitudinal descriptive study of 28 patients undergoing percutaneous valvular aortic implantation with the CoreValve device in the Institute of Cardiology of Rio Grande do Sul from December 2008 to January 2012. The institution's Ethics Committee approved the study.

All patients were visited the day before surgery. After receiving guidance and getting their doubts cleared, all participants signed an informed consent term. The patients underwent 8-hour fasting and received no premedication. Preoperatively, two units of blood cells, plasma, and platelets were reserved and adequate hydration prepared, especially for patients with chronic renal failure.

Monitoring was performed with two-lead ECG (II and V5), invasive blood pressure, central venous pressure, pulse oximetry, capnography, temporary pacemaker with electrode placement in right ventricle (RV) for maintaining a rapid rate at the time of angioplasty, bladder catheterization, transthoracic echocardiography (TEE), and thermometry.

As routine procedure, we used intravenous (IV) midazolam 2 mg and induced the anesthesia with etomidate 0.2 mg.kg⁻¹; tracheal intubation was preceded by neuromuscular blocking

agent (atracurium 0.5 mg.kg⁻¹ or rocuronium 0.5 mg.kg⁻¹); analgesia was performed with continuous intravenous remifentanyl 0.2 mcg.kg⁻¹.min⁻¹ and maintenance with sevoflurane. As inotropic and vasopressor, we used norepinephrine through infusion pump and/or araminol and adrenaline, if necessary. All patients underwent oral intubation and controlled mechanical ventilation.

After induction, catheterization of the right subclavian vein was performed with double-lumen catheter and right internal jugular vein with 7-French introducer, with endocavitary pacemaker electrode placed in the right ventricle.

Heparin 100 UI.kg⁻¹ was administered intravenously to maintain an activated clotting time between 200-250 seconds and protamine used for reversal at the end of the procedure.

Study design and selection criteria

All cases were evaluated by a multidisciplinary team composed of one interventional cardiologist, one clinical cardiologist, one cardiac surgeon, one anesthesiologist with experience in cardiology that considered the standard valvular replacement technique of high perioperative risk, with great potential for mortality and possible complications.

Inclusion criteria were: patients with severe aortic stenosis (valve area ≤ 1 cm²), age ≥ 75 years, Euro SCORE $\geq 20\%$, aorto-ventricular gradient ≥ 40 mm Hg, or with high surgical risk. Additionally, some of the following symptoms needed to be present: chest pain or limiting dyspnea, dizziness, presyncope or syncope, and ventricular arrhythmia. Exclusion criteria were: patients with unfavorable anatomy for implantation, impossibility of vascular access, blood dyscrasias, systemic disease with life expectancy less than one year, and those who refused to undergo the procedure⁸.

Screening of patients involved the assessment of anatomical and functional conditions favorable for valve implantation of CoreValve. We performed a transthoracic echocardiography (TEE) with color Doppler and cineangiography. We performed a multi-detector angiotomography when there was doubt about the measures provided by other tests. Clinical and angiographic data were included in forms according to the manufacturer's standard assessment protocol, which determined inclusion of patients in the study.

Procedure description

We used a third generation CoreValve aortic valve prosthesis, which consists of a bioprosthesis of three porcine pericardium leaflets mounted and sutured in a self-expanding nitinol stent (Figure 1). The smallest inner diameter of the valve is 21 mm and its structure (nitinol stent) is laser cut in a tube 50 mm long.

The prosthesis distal portion has high radial force, which allows its expansion and exclusion from the already calcified native valve leaflets, preventing its retraction after implantation. The middle portion carries the valve and its architecture allows the coronary ostia to be free and accessible. The proximal portion is enlarged, allowing its fixation and longitudinal stability. Before implantation, the valve is washed and cooled in cold saline solution, undergoes a

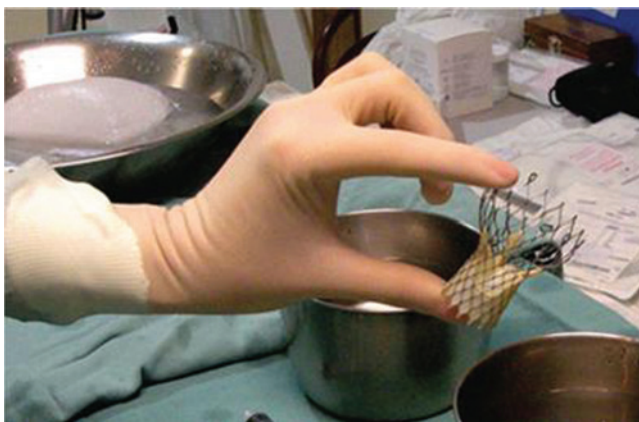

Figure 1 Bioprosthesis of three porcine pericardium leaflets mounted and sutured in a self-expanding nitinol stent.

series of vascular molds to reduce its profile and is fixed at an 18-French delivery system, releasing the prosthesis after balloon valvuloplasty (Figure 2).

All patients received AAS 500 mg and clopidogrel 300 mg the day before surgery. The vascular access for prosthesis introduction was made by puncture or dissection of the iliac or common femoral artery.

At the beginning of the procedure, a temporary pacemaker electrode was introduced into the RV through the right internal jugular and used to prevent bradycardia and increase heart rate (rapid pacing) to prevent balloon migration at the time of valvuloplasty, preceding the prosthesis release^{9,10}.

We continuously evaluated patients' clinical and hemodynamic parameters during the procedure. We took contrasted aortographies before, during, and after valve implantation to better aid prosthesis positioning and release and assess leakage or residual aortic regurgitation. Transesophageal echocardiography was used to see the immediate results and, if necessary, for reintervention to improve the adequacy of the prosthetic valve.

The puncture or dissection area was infiltrated with local anesthetic (bupivacaine 0.5% or ropivacaine 0.75%), as well as at the end of the procedure, to minimize postoperative pain. We kept the temporary pacemaker until discharge from the postoperative unit (POU).



Figure 2 18-French prosthesis delivery system.

We performed a transthoracic echocardiography before hospital discharge, and recommended the use of AAS 100 mg.day⁻¹ and clopidogrel 75 mg.day⁻¹ for at least six months.

Results

From December 2008 to January 2012, 28 patients with severe aortic stenosis who were not candidates for surgery underwent percutaneous aortic valve implantation. All patients were followed-up for up to 24 months.

As for transcatheter valve replacement, the VARC (Valve Academic Consortium Research) was created with the participation of experts, members of the Food and Drugs Administration (FDA), and industry representatives who established a table with the success rate in percutaneous valve implantation, which we used in our patients¹¹ (Table 1).

Table 1 VARC* Criteria: success and adverse events.

	n (%)
Number of patients	28
Implant success	23 (82.14%)
Death (CV)	3 (10.71%)
Death (any cause)	4 (14.29%)
AMI during procedure	1 (3.37%)
Spontaneous AMI	0
CVA	4 (14.29%)
Hemorrhagic complication	
Risk of death	1 (3.57%)
Major bleeding	6 (21.43%)
Minor bleeding	2 (7.14%)
ARF	
Stage I	3 (10.71%)
Stage II	2 (7.14%)
Stage III	0
Vascular complication	
Major	3 (10.71%)
Minor	2 (7.14%)
Bioprosthesis dysfunction	0
Complication associated with bioprostheses	
Contiguity	14 (50%)
Endocarditis	0
Hemolysis	0
Complications related to the implant	5 (17.86%)

*Valve Academic Research Consortium; CV: cardiovascular; AMI: acute myocardial infarction; CVA: cerebrovascular accident; ARF: acute renal failure.

Of all patients, 80% were admitted to the catheterization laboratory with hypertension and heart rate between 60-70 bpm. This hypertension upon arrival at the laboratory was probably due to their stress from the procedure and the absence of sedation pre-anesthesia. Anxiety was easily treated using intravenous midazolam. After anesthetic induction, tension decreased by about 20%, and patients remained stable throughout the procedure with low doses of vasopressors or noradrenaline. Noradrenaline (8 mg) was prepared with saline solution (192 mL). All patients received noradrenaline as tensional support at low doses of 0.03-0.05 $\mu\text{g}\cdot\text{kg}\cdot\text{min}^{-1}$. At the end of the procedure, no patient took noradrenaline for support.

The mean time of anesthesia was 162 minutes. Ninety percent of all patients were anemic, with mean hemoglobin of 9.2 g%. Total blood loss was minimal, but 18.80% of patients required transfusion at the end of the procedure (three patients received one red blood cell concentration [RBCC] and one patient received two RBCC). At the end of surgery, the patients underwent aspiration, decurarization if necessary, and extubation. They were taken awake and spontaneously breathing with oxygen catheter to the recovery room. The exception was one patient who underwent surgery with cardiopulmonary bypass and had ventricular perforation, evolving to death.

The anesthetic technique proved to be safe. Anesthesia was uneventful. We easily corrected initial hypotension with vasopressor, hemodynamic stability maintained throughout the procedure with continuous norepinephrine and extrasystoles, resulting from catheter handling inside the heart. There was no need for correction with drugs and the patient was discharged awake.

Table 2 shows the demographic characteristics, risk factors and logistic EuroSCORE of the patients in our case series.

After the transcatheter aortic valve implantation (TAVI), patients were assessed and showed immediate improvement in cardiac functional patterns, with decreased pressure gradient between the left ventricle and aorta. Table 3 shows the characteristics after implantation.

After implantation, the New York Heart Association (NYHA) classification of functional capacity changed to I and II in 90% of cases. Aortic-ventricular gradients decreased from 54.89 mm Hg to 9.3 mm Hg in the immediate postoperative period, 9.2 in 30 days, 10.3 in six months, and 12.8 in one year. The mean valve area, which preoperatively was 0.61 cm, changed to 1.53 in 30 days and 1.54 in six months and one year.

Among the 28 patients who received percutaneous aortic valve with the CoreValve device, three of them died: one during surgery due to left ventricle (LV) perforation, one in 72 hours of unknown cause, and one in 12 months with a diagnosis of multiple myeloma. All other patients were discharged without any complications from anesthesia.

Six patients were readmitted and treated for massive epistaxis, pneumonia, fully recovered cerebrovascular accident, endovascular repair of iliac laceration, and embolectomy of the right leg. They were subsequently released for follow-up. There were no other complications, and all patients progressed well, with improvement of symptoms and clinical stability.

Among evaluated patients, nine (45%) required a permanent pacemaker due to complete AV block (CAVB) and one due to chronic auricular fibrillation (CAF) with low ventricular response, implanted postoperatively between days 0 and 15.

When ECG changes occurred (CAVB) during the valve release, two-thirds of these patients progressed to a permanent pacemaker. The use of general anesthesia proved to be safe, with no neurological or hemodynamic consequences postoperatively.

During medium and long-term follow-up, the pressure gradients remained similar to that at hospital discharge. Ventricular function remained preserved with decreased muscle mass, and there was no significant aortic regurgitation.

Discussion

Percutaneous valve implantation with the CoreValve device proved to be an important option for reducing the transvalvular aortic gradient of patients undergoing this procedure (Figure 3). The anesthetic technique remains uncertain, as there are schools using the deep sedation technique, others using general anesthesia, and still another school using combined epidural anesthesia with sedation^{4,12-16}.

General anesthesia and deep sedation have been used in several studies with good results^{4,10,16-27}. In our case series, we used general anesthesia due to the need for prolonged immobilization of patients in uncomfortable tables, tendency for hypothermia, the team's learning curve, need for surgical repair of catheterized arteries, TEE use, possibility of neurological complications and surgical intervention with cardiopulmonary bypass (CPB), and little knowledge on the technique. Hemodynamic stability was the main goal of the anesthetic management - low heart rate (50-70 bpm) was preferable - and supraventricular and ventricular arrhythmias were managed aggressively and reversal achieved. Hypotension was quickly treated with araminol bolus or continuous noradrenaline.

Complications related to percutaneous implantation are mainly vascular and directly associated with the diameter of catheters used. Cerebrovascular accident (CVA) resulting from embolization of friable native valve material is an event occurring in approximately 18% of patients^{12,28,29}. Acute renal failure (ARF) occurs in 12-28% of cases³⁰⁻³². A limited clinical experiment suggests that the renal function often improves with the best cardiac output after AE correction. ARF is usually mild and easily reversed and less common than in surgical patients³³. Coronary obstruction rarely occurs and is a result of the native valve displacement of the left coronary ostium. This complication can be managed conservatively³⁰. Conduction system injury occurs in the interventricular septum below the aortic valve, causing a bundle branch block and/or complete AV block, with an incidence of permanent pacemaker implantation in 3-36%, with an additional risk factor for elderly patients with previous blocks^{12,34,35}. The result was superior those in the literature, with an incidence between 9-36% of patients^{12,36}. One reason for this is that the stent compresses the valve annulus and surrounding structures, including components of the electrical conduction system of the heart. The AV node and left branch of the His bundle travels inside the fibrous body near the aortic valve non-coronary cusp, and may be affected by the device or swelling structures^{12,37}. According to literature, left bundle

Table 2 Patients' Characteristics and Comorbidities.

Patient	Sex	Age	EuroScore	Comorbidity	Class F. NYHA	Prior MP
1	F	90	9	SAH	IV	N
2	F	80	19	IHD, CABG, SAH	III	N
3	F	85	20	Gastrectomy	IV	N
4	F	86	11	IHD + LBB	II	N
5	M	94	34	IHD, CVA, PAH	IV	N
6	F	99	33	IHD, DM, SAH	II	N
7	M	8	9	IHD, CRF, DM	III	N
8	F	76	9.8	IHD, SAH, CAVB	II	N
9	F	90	10.7	IHD, SAH, CABG, PAH	III	N
10	F	80	12	SAH, DSL	II	N
11	F	88	46	SAH	III	N
12	F	87	12	COPD, CAVB	II	N
13	F	79	26	IHD, CAVB, COPD	II	N
14	F	85	16.2	SAH	II	N
15	M	82	17.2	SAH, CRF, Myeloma	III	S
16	M	87	46	IHD, CABG, CAVB, HIV	III	S
17	F	83	13.8	IHD, SAH	IV	N
18	M	89	62.9	SAH, COPD	IV	S
19	M	79	32.8	COPD, IHD	III	N
20	M	62	8.9	IHD, CAVB, CRF, Hepat	III	S
21	M	65	32	IHD, COPD, CVA	II	N
22	M	64	8.1	IHD, SAH, CABG	II	N
23	M	83	6.6	IHD, Prostate cancer	II	N
24	F	92	16	CAVB, CR	III	N
25	F	80	21.3	COPD, DC, PVD	III	N
26	M	89	17.8	SAH, AAA, DLP	III	N
27	M	68	2.7	Esophageal cancer, QT, RTx	IV	S
28	F	85	10.7	SAH, Bronchitis	III	N

SAH: systemic arterial hypertension, IHD: ischemic heart disease, CABG: coronary artery bypass graft surgery; LBB: left bundle block, CVA: cerebrovascular accident; PAH: pulmonary arterial hypertension, DM: diabetes mellitus, CRF: chronic renal failure; CAAF: complete arrhythmia due to atrial fibrillation; COPD: chronic obstructive pulmonary disease; CAVB: complete AV block, AAA: abdominal aortic aneurysm, QT: chemotherapy; DSL: dyslipidemia; PVD: peripheral vascular disease.

block may occur in up to 33% of cases and is associated with worse prognosis. The need for permanent pacemaker varies between 3-40%. Our complications can be compared by VARC criteria (Table 2). One-third of patients undergoing CoreValve implantation requires permanent pacemaker in 30 days, compared to conventional surgery, which is < 10%.

Among the probable factors, we can mention atrio-ventricular block during the procedure, pre-dilatation with balloon, prosthesis size, interventricular septum increased diameter, prolonged QRS duration, and team experience³⁸⁻⁴⁰.

Table 3 Patients' Characteristics Pre- and Post-implantation.

Patient	Area (pre) (cm ²)	Area (post) (cm ²)	Transvalvular gradient (pre)	Transvalvular gradient (post)	Transvalvular gradient (post) 6m
1	0.46	1.54	88	9	9.7
2	0.63	ND	45	13.1	11
3	0.4	1.44	98	14.7	10.7
4	0.65	1.9	56	10.5	9
5	0.7	ND	53	6	6
6	0.5	1.41	65	11	15
7	0.7	ND	82	8.8	8
8	0.75	1.4	49	5.6	12
9	0.79	1.48	45	5.6	9
10	0.73	1.42	55	12.7	13
11	0.95		95		
12	0.47		47		
13	0.73	1.8	42	12.2	
14	0.45	1.8	62	9	
15	ND	1.7	40	11	
16	ND	ND	32	11	15
17	0.65	1.56	35		
18	0.85	2.1	44	5	
19	0.69	2.4	54	5.1	
20	0.6		32		
21	0.64		31		
22			40	8	
23	0.6	1.8	63	11	
24	0.94	1.81	51	3	
25	0.7	1.32	40	13	
26	0.7	1.5	55	5	

This study has some limitations such as having no control group, the sampling was small, highly selective with patients pertaining to a single center with no correlation to other types of anesthesia (e.g., deep sedation), which may represent a local reality.

One issue that should be considered for percutaneous aortic valve implantation, which remains open at the present stage of knowledge, is the CoreValve prosthesis durability over the years, as the natural history of the biological and metal prostheses implanted by conventional surgery is well known²⁸. Regarding analysis of gradients and valve area, several studies suggest that the percutaneous prostheses currently used have a performance

comparable to that of surgical prostheses¹². Therefore, a multidisciplinary team should evaluate patients TIVA indication.

New valves are emerging that provide greater safety and effectiveness for a procedure that has already been showing good results. Other valves are being clinically evaluated, which will incorporate other means to facilitate proper positioning and reduce paravalvular leaks. The new generation of valves with greater expansion force may dismiss the use of the balloon and favor valve fixation⁴¹. Although these valves are contributing to the treatment of aortic stenosis, discretion of information on effectiveness, durability, and results may lead to unexpected problems³⁰.

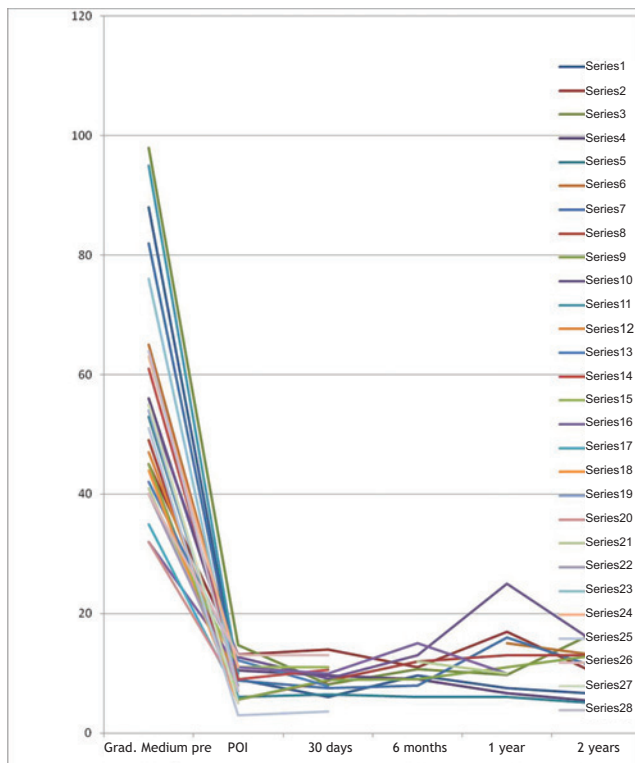


Figure 3 Mean transvalvular gradients.

Conclusion

Our initial experience with general anesthesia and invasive monitoring proved to be an effective and efficient option, allowing strict hemodynamic control and early identification of problems during the procedure. The anesthetic complications were minor and easily treated; however, the event of surgical complication is potentially serious^{10,19,22,38,40}. Valve duration is still an important consideration in selecting patients for this type of valve implantation, particularly younger patients. Additional studies, greater experience, and longer follow-up are still needed to define the best technique to be adopted.

References

1. Iung B, Baron G, Butchart EG, et al. - A prospective survey of patients with valvular heart disease in Europe: the euro heart survey on valvular heart disease. *Eur Heart J*. 2003;24:1231-1243.
2. Vahanian A, Alfieri O, Al-Attar N, et al. - Transcatheter valve implantation for patients with aortic stenosis: a position statement from the European Association of Cardio-Thoracic Surgery (EACTS) and the European Society of Cardiology (ESC), in collaboration with the European Association of Percutaneous Cardiovascular Interventions (EAPCI). *Eur Heart J*. 2008;29:1463-1470.
3. Cribier A, Eltchaninoff H, Bash A, et al. - Percutaneous transcatheter implantation of an aortic valve prosthesis for calcific aortic stenosis: first human case description. *Circulation*. 2002;106:3006-3008.
4. Grube E, Laborde JC, Gerckens U, et al. - Percutaneous implantation of the CoreValve self-expanding valve prosthesis in high-risk patients with aortic valve disease: the Siegburg first-in-man study. *Circulation*. 2006;114:1616-1624.
5. Cribier A, Zajarais A - Percutaneous valve replacement the future is here! *Rev Esp Cardiol*. 2009;61:1123-1125.
6. Bauer F, Eltchaninoff H, Tron C, et al. - Acute improvement in global and regional left ventricular systolic function after percutaneous heart valve implantation in patients with symptomatic aortic stenosis. *Circulation*. 2004;110:1473-1476.
7. Cribier A, Eltchaninoff N, Borestein N, et al. - Percutaneous transcatheter implantation of an aortic valve prosthesis for calcific aortic stenosis: first human case description. *Circulation*. 2002;106(24):3006-3008.
8. Wendt D, Oswald BR, Kayser K, et al. - Society of Thoracic Surgeons Score is superior to the Euroscore determining mortality in high risk patients undergoing isolated aortic valve replacement. *Ann Thorac Surg*. 2009;88:468-474.
9. Bonow RO, Carabello BA, Chatterjee K, et al. - 2008 focused up-to-date incorporated into the ACC/AHA 2006 guideline for management of patient with valvular heart disease: a report of the American College of Cardiology/American Heart Association Task Force on Practice Guideline. *Circulation*. 2008;118:523-661.
10. Covello RD, Ruggeli L, Landoni G, et al. - Transcatheter implantation of an aortic valve: anesthesiological management. *Minerva Anestesiol*. 2010;76:100-108.
11. Holmes DR Jr - Expert consensus document on transcatheter aortic valve replacement. *JACC*. 2012;01:1-63.
12. Heinze, Sier H, Schafer U, et al. - Percutaneous aortic valve replacement: overview and suggestions for anesthetic management. *J of Clinical Anesthesia*. 2010;22:373-378.
13. Eltchaninoff H, Prat A, Gillard M, et al. - Transcatheter aortic valve implantation: early results of the France (French Aortic National CoreValve and Edwards) registry. *Eur Heart J*. 2011;32:191-197.
14. Hernández-García JM, Muñoz-García AJ, Alonso-Briales JH, et al. - Experiência inicial em Málaga (Espanha) com prótese aórtica CoreValve para tratamento da estenose aórtica sintomática grave. *Rev Bras Cardiol Invasiva*. 2009;17(2):176-182.
15. Lichtenstein SV, Cheung A, Ye J, et al. - Transapical transcatheter aortic valve implantation in humans: initial clinical experience. *Circulation*. 2006;114:591-596.
16. Johansson M, Nozohoor S, Kimblad PO, et al. - Transapical versus transfemoral aortic valve implantation: a comparison of survival and safety. *Ann Thorac Surg*. 2011;91:57-73.
17. Sarmiento-Leite R, Quadros AS, Prates PR, et al. - Implante valvular aórtico percutâneo: experiência inicial do Sul do Brasil. *Rev Bras Cardiol Invas*. 2008;16:1-8.
18. Klein AA, Webb ST, Tsui S, et al. - Transcatheter aortic valve insertion: anaesthetic implications of emerging new technology. *Br J Anaesth*. 2009;103(6):792-799.
19. Fassi J, Augoustides JGT - Transcatheter aortic valve implantation - part 2: anesthesia management. *J Cardiothorac Vasc Anesth*. 2010;24:691-699.
20. Billings FT, Kodali SK, Shanewise JS - Transcatheter aortic valve implantation: anesthetic considerations. *Can J Anesth*. 2009;108:1453-1462.
21. Cook DJ, Rehfeldt K. - Catheter-based aortic valve replacement: editorial. *J Cardiothorac Vasc Anesth*. 2009;23:277-279.
22. Covello RD, Maj G, Landoni G, et al. - Anesthetic management of percutaneous aortic valve implantation: focus on challenges encountered and proposed solutions. *J Cardiothorac Vasc Anesth*. 2009;23:280-285.

23. Grube E, Beullensfeld L, Muller R, et al. - Progress and current status of percutaneous valve replacement. Results of three devices generations of the corevalve revalving system. *Circ Cardiovasc Intervent.* 2008;1:167-175.
24. Fagundes FES, Soares WB, Carvalho LAF, et al. - Implante valvular aórtico percutâneo no tratamento de estenose aórtica: visão do anestesiológista. CBA ID 00633-0001.
25. Behan M, Haworth P, Hutchinson N, et al. - Percutaneous aortic valve implantans under sedation: our inicial experience. *Catheter Cardiovasc Interv.* 2008;72:1012-1006.
26. Nielsen I, Andersen C - Transcatheter aortic valve replacement in high-risk patients with different anaesthesia techniques. *HSR Proced Intens Care Cardio Anesth.* 2010;2:273-277.
27. Leon M, Piazza N, Nikolki E, et al. - Standardized endpoint definitions for transcateter aortic valve implantation clinical trials: a consensus report from the Valve Academic Research Consortium. *Eur Heart J.* 2011;32:205-217.
28. Leon MB, Smith CR, Mack M, et al. - Transcatheter aortic-valve implantation for aortic stenosis in patients Who cannot undergo surgery. *N Engl J Med.* 2010;23:1-11.
29. Leon MB, Smith CR, Mack M, et al. - Transcatheter aortic valve implantation in inoperable patients with severe aortic stenosis. *N Engl J Med.* 2010;363:1597-1607.
30. Webb J, Cribier A - Percurtaneous transarterial aortic valve implantation: what do we know? *Eur Heart J.* 2011;32:140-147.
31. Webb JG, Pasupati S, Humphries K, et al. - Percutaneous transarterial aortic valve replacement in selected high-risk patients with aortic stenosis. *Circulation.* 2007;116:755-763.
32. Webb JG, Wood DA, Ye J, et al. - Transcatheter valve-in-valve implantation for failed bioprosthetic heart valves. *Circulation,* 2010;121:1848.
33. Bagur R, Webb JG, Nietspach F, et al. - Acute kidney injury following transcatheter aortic valve implantation predictive factors, prognostic value, and comparison with surgical aortic valve replacement. *Eur Heart J.* 2010;31:865-874.
34. Yan ID, Martens-Nielsen J, Padang R, et al. - Transcatheter aortic valve implantation for high-risk patients wich severe aortic stenosis a systematic review. *J Thorac Cardiovasc Surg.* 2010;139:1519-1528.
35. Coeytaux RR, Williams JW, Gray RN, et al. - Percutaneous heart valve replacement for aortic stenosis: state of the evidence. *Ann Intern Med.* 2010;153:314-324.
36. Lemos PA, Marzocchi A, Mariani Jr., et al. - Implante transcater de prótese valvular aórtica: perfil clínico e evolução de uma série consecutiva de 75 casos do registro conjunto Universidade de Bolonha/Hospital Sírio-Libanês. *Rev Bras Cardiol Invas.* 2011;19:24-27.
37. Dawkins S, Hobson AR, Kalra PR, et al. - Permanent pacemaker implantation after isolated aortic valve replacement: incidence, indications, and predictors. *Ann Thorac Surg.* 2008;85:108-112.
38. Bates M, Matthews I, Fazal I, et al. - Postoperative permanent pacemaker implantation in patients undergoing trans-catheter aortic valve implantation: what is the incidence and and there any predicting factors? *Inter Cardiovasc Thor Surg.* 2011;12:243-253.
39. Bernardi GLM, Sarmento-Leite R, Prates PR, et al. - Implante valvular aórtico percutâneo: dois anos de evolução da experiência inicial no Sul do Brasil. *Rev Bras Cardiol Invas.* 2011;19:28-33.
40. Khawaja MZ, Rajani R, Cook A, et al. - Permanent pacemaker insertion after corevalve transcatheter aortic valve implantation. *Circulation.* 2011;123:951-960.
41. Pibarot P, Dumesnil JG. Prosthetic heart valves: selection of the optimal prosthesis and long-term management. *Circulation.* 2009;119:1034-1048.