

From the Society for Vascular Surgery

# Contemporary management of wartime vascular trauma

Charles J. Fox, MD,<sup>a,b</sup> David L. Gillespie, MD,<sup>a,b</sup> Sean D. O'Donnell, MD,<sup>a,b</sup> Todd E. Rasmussen, MD,<sup>a,b</sup> James M. Goff, MD,<sup>a,b</sup> Chatt A. Johnson, MD,<sup>a,b</sup> Richard E. Galgon, MD,<sup>a</sup> Timur P. Sarac, MD,<sup>a</sup> and Norman M. Rich, MD,<sup>b</sup> *Washington, DC; and Bethesda, Md*

**Objective:** The treatment of wartime injuries has led to advances in the diagnosis and treatment of vascular trauma. Recent experience has stimulated a reappraisal of the management of such injuries, specifically assessing the effect of explosive devices on injury patterns and treatment strategies. The objective of this report is to provide a single-institution analysis of injury patterns and management strategies in the care of modern wartime vascular injuries.

**Methods:** From December 2001 through March 2004, all wartime evacuees evaluated at a single institution were prospectively entered into a database and retrospectively reviewed. Data collected included site, type, and mechanism of vascular injury; associated trauma; type of vascular repair; initial outcome; occult injury; amputation rate; and complication. Liberal application of arteriography was used to assess these injuries. The results of that diagnostic and therapeutic approach, particularly as it related to the care of the blast-injured patient, are reviewed.

**Results:** Of 3057 soldiers evacuated for medical evaluation, 1524 (50%) sustained battle injuries. Known or suspected vascular injuries occurred in 107 (7%) patients, and these patients comprised the study group. Sixty-eight (64%) patients were wounded by explosive devices, 27 (25%) were wounded by gunshots, and 12 (11%) experienced blunt traumatic injury. The majority of injuries (59/66 [88%]) occurred in the extremities. Nearly half (48/107) of the patients underwent vascular repair in a forward hospital in Iraq or Afghanistan. Twenty-eight (26%) required additional operative intervention on arrival in the United States. Vascular injuries were associated with bony fracture in 37% of soldiers. Twenty-one of the 107 had a primary amputation performed before evacuation. Amputation after vascular repair occurred in 8 patients. Of those, 5 had mangled extremities associated with contaminated wounds and infected grafts. Sixty-seven (63%) patients underwent diagnostic angiography. The most common indication was mechanism of injury (42%), followed by abnormal examination (33%), operative planning (18%), or evaluation of a repair (7%).

**Conclusions:** This interim report represents the largest analysis of US military vascular injuries in more than 30 years. Wounding patterns reflect past experience with a high percentage of extremity injuries. Management of arterial repair with autologous vein graft remains the treatment of choice. Repairs in contaminated wound beds should be avoided. An increase in injuries from improvised explosive devices in modern conflict warrants the more liberal application of contrast arteriography. Endovascular techniques have advanced the contemporary management and proved valuable in the treatment of select wartime vascular injuries. (*J Vasc Surg* 2005;41:638-44.)

From the time of Hippocrates, the field of vascular surgery has been advanced by the application of lessons learned from the care of the wounded during armed conflict. The management of military vascular trauma has changed considerably as a result of the wars of the 20th century and the significant contributions of DeBakey, Hughes, Rich, and others.<sup>1-4</sup> The global war on terrorism, with troops engaged in armed combat in Iraq and Afghanistan, challenges contemporary military surgeons to apply the lessons learned from our predecessors and to review our diagnostic and therapeutic approach to the care of the wounded soldier with a vascular injury.

From the Department of Surgery, Peripheral Vascular Surgery Service, Walter Reed Army Medical Center,<sup>a</sup> Washington, and the Department of Surgery, Uniformed University of the Health Sciences,<sup>b</sup> Bethesda.

Competition of interest: none.

Presented at the 2004 Joint Annual Meeting of the Society for Vascular Surgery/American Association for Vascular Surgery, Anaheim, California, June 3-6, 2004.

Reprint requests: Charles J. Fox, MD, Walter Reed Army Medical Center, Vascular Surgery, Bldg 2, Ward 64, 6900 Georgia Ave, NW, Washington, DC 20307 (e-mail: Charles.Fox@na.amedd.army.mil).

0741-5214/\$30.00

Copyright © 2005 by The Society for Vascular Surgery.

doi:10.1016/j.jvs.2005.01.010

The objective of this report is to provide a complete review of a single-institution experience on the observed injury patterns and contemporary management strategies used in the care of modern military vascular injuries. Coinciding with the end of the first year of sustained combat operations in Iraq, this interim report represents the largest analysis of US military vascular injuries in more than 30 years.<sup>5-8</sup>

## METHODS

From December 2001 through March 2004, all US military casualties evacuated to Walter Reed Army Medical Center were evaluated. Patients with a history of or a concern for a vascular injury were examined by a senior vascular surgeon. These patients were prospectively entered into a clinical database, and the data were then retrospectively reviewed. Basic demographic data collected included patient age, sex, country where injured, and date of injury.

Specific patterns of injury were documented, noting the mechanism of vascular injury, site and type of vessel injured, and the presence of any associated trauma. Vascular repairs were analyzed by the type of repair performed, and the use of autogenous vein grafting was compared with

**Table I.** Initial management of arterial injury in Iraq and Afghanistan

| Artery              | Thrombectomy | Ligation | Repair | Vein graft | PTFE | Total (%) |
|---------------------|--------------|----------|--------|------------|------|-----------|
| Axillary            |              |          | 1      |            | 1    | 12 (3.8)  |
| Brachial            | 1            |          | 3      | 7          | 1    | 12 (22.6) |
| Common femoral      |              |          |        | 1          |      | 1 (1.9)   |
| Tibial              | 1            |          |        | 1          |      | 2 (3.8)   |
| External carotid    |              | 2        |        |            |      | 2 (3.8)   |
| Ulnar               |              | 3        |        | 1          |      | 4 (7.5)   |
| Popliteal           |              |          |        | 5          |      | 5 (9.4)   |
| Radial              |              | 8        | 1      |            |      | 9 (17)    |
| Superficial femoral | 2            |          |        | 6          | 3    | 11 (20.7) |
| Temporal            |              | 1        |        |            |      | 1 (1.9)   |
| Deep femoral        |              | 2        |        | 1          |      | 3 (5.7)   |
| Hypogastric         |              | 1        |        |            |      | 1 (1.9)   |
| Total               | 4            | 17       | 5      | 22         | 5    | 53 (100)  |

PTFE, Polytetrafluoroethylene.

the use of prosthetic material. The initial outcome, including the need for amputation, was documented. Arteriographic findings, including the presence of occult arterial injury and the use of catheter-based techniques to treat selected vascular injuries, were documented. Complications and outcomes were reviewed.

## RESULTS

**Demographics.** During the study period, 3057 soldiers were evacuated to our institution for medical evaluation. Of those, 1524 (50%) had sustained direct combat-related battle injuries. Known or suspected vascular injuries occurred in 107 (7%) of these patients, and these patients comprised the study group. Ninety-two were injured during Operation Iraqi Freedom, and the remaining 15 patients were injured in Afghanistan during Operation Enduring Freedom. Of the 107 patients, 105 were male, and 2 were female. The average age was 29 years (range, 19-64 years).

Forty-eight of the 107 patients evaluated had arrived from Iraq with documentation of a recent vascular repair. Initial reports of how this was discovered are inconsistently reported. The remaining 59 patients were evaluated for suspected vascular injury.

**Injury pattern.** The majority of injuries (68 [64%]) were from explosive devices. This included rocket-propelled grenades, antipersonnel landmines, high-explosive mortars, and improvised explosive devices (IEDs). High-velocity gunshot wounds were associated with vascular injuries in 27 (25%) patients. The remaining vascular injuries occurred after motor vehicle accidents (5%) or traumatic crush-type injuries (4%), which were usually associated with mechanized vehicles and other heavy equipment and machinery. Additionally, one patient experienced a tiger bite, and 2 patients were returned for medical evaluation of vascular disease. The distribution of injuries was essentially confined to the upper (39%) or lower (51%) extremities, neck (7%), or pelvis (3%).

**Specific injuries.** Forty-eight patients underwent 64 vascular repairs that involved 53 arterial and 11 venous

injuries. Transections of the brachial artery (23%) were the most common vascular injuries. Injuries to the superficial femoral (21%), popliteal (9%), and radial (17%) arteries were also common. Table I shows the distribution of arterial injuries managed in Iraq and Afghanistan. Soft tissue defects, mostly from explosions, open long bone fractures, and multiple blast fragments, frequently were associated with vascular injury.

**Management of vascular injuries.** The initial 48 patients with vascular injuries were managed acutely in the combat support hospital or by a forward surgical team. Several patients underwent amputation or wound debridement in Landstuhl, Germany, during the medical evacuation to the continental United States. Nine additional vascular repairs were performed after evacuation to Walter Reed Army Medical Center, Washington, DC. The median time to arrival was 8.5 days.

Segmental arterial loss associated with massive soft tissue injury necessitated interposition graft repair in 27 (50%) injuries (Table I). The saphenous vein was used in 22, and polytetrafluoroethylene was used in 5. Lateral repair of arterial injuries was used in 5 patients. Thrombectomy with end-to-end repair was performed in 4 patients. Arterial ligation was used less commonly and mainly for tibial or forearm vascular injuries.

Eleven venous injuries are included with this report. One subclavian vein injury, 1 popliteal vein injury, and 1 jugular venous injury were managed by means of lateral suture repair. There were also 6 femoral and 2 iliac venous injuries. These venous injuries were ligated. Many other venous injuries were suspected but not reported.

**Amputations.** Of the 107 patients in this series, 21 (19.6%) had a primary amputation before arriving at our institution. Below-knee amputation (BKA) was most common (40%). One quarter of patients had an above-knee amputation. In addition, there were 4 upper extremity below-elbow amputations, 1 transmetatarsal amputation, and 1 ray amputation. Additionally, 4 patients had bilateral lower extremity amputations (above-knee amputation,

**Table II.** Distribution of amputation type

| <i>Amputation type</i> | <i>No.</i> |
|------------------------|------------|
| Below knee             | 9          |
| Above knee             | 5          |
| Upper extremity        | 4          |
| Hip disarticulation    | 1          |
| TMA-toe                | 2          |
| Total                  | 21         |

TMA, Transmetatarsal amputation.

BKA, or combination), and one had a combination BKA and hip disarticulation (Table II).

Of interest, 11 (52%) amputees had associated long bone fractures, tibial nerve injury, or a major sensory deficit. Eight were of the group of 48 patients who had a vascular injury requiring immediate repair in the battle area by a forward surgical team or combat support hospital, yielding an amputation rate of 16%. The primary reason for amputation in a forward hospital was an unsalvageable mangled extremity characterized by a combination of long bone fracture, nerve injury, and extensive soft tissue wounds. Five (62%) had a mangled extremity associated with graft infection or thrombosis. One had extensive rhabdomyolysis with wound sepsis leading to hip disarticulation, 1 had extensive soft tissue destruction, and 1 had a gangrenous forefoot from an IED. All amputations performed at Walter Reed had an infectious cause, despite the liberal use of perioperative antibiotics.

**Complications.** Of the 48 patients who had initial major vascular repairs in Iraq and Afghanistan, 21 (44%) patients had an associated complication (Fig). The most common complication was graft occlusion or infection. Of the 5 patients with a polytetrafluoroethylene graft, 4 of 5 became infected or thrombosed. These grafts were excised and replaced with an autologous vein graft.

Injuries to the superficial femoral artery (SFA) had the highest complication rate. Of 11 SFA repairs, 9 resulted in either graft removal or a wound complication. Two patients had compartment syndrome that was recognized early and treated with immediate fasciotomy. There were no complications associated with radial or external carotid ligation.

**Arteriography and occult arterial injury.** Two thirds of the patients evaluated in this series underwent arteriographic evaluation. Sixty-nine arteriograms were performed on 67 (63%) patients. Forty-five arteriograms were done initially to evaluate a suspected injury, and 22 arteriograms were performed on the 48-patient group with a previous vascular repair in Iraq. Forty-six arteriograms were performed on the lower extremity (66%), and 13 (19%) were performed on the upper extremity. The additional 15% comprised 9 carotid studies and 1 thoracic aortogram. Indications for arteriography included mechanism or extent of injury, abnormal physical examination, reconstructive operative planning, or evaluation of a previous vascular repair. The indication for arteriography and results are summarized in Table III.

Thirty-one (46.2%) of the 67 patients undergoing arteriographic evaluation had an abnormal finding. Arteriography permitted the detection of 40 occult injuries in 31 patients, 5 of whom were among the 48 patients with a previous repair. Nine (29%) of the 31 patients required a subsequent intervention (Table IV). The majority of the occult findings were asymptomatic occlusions of the ulnar, radial, or tibial vessels. Three arteriovenous fistulae and 4 pseudoaneurysms were also identified and treated.

The most common indication for arteriography was to evaluate patients with blast and multiple fragment injuries from explosive devices that involved the lower extremity (28/67 [42%]). One third (22/67) had an abnormal physical examination characterized by a decrease in ankle/brachial index, a change in pulse, or the presence of a bruit or thrill. When arteriograms were performed simply on the basis of the mechanism of injury alone, those with blast-associated injuries were positive 25% of the time (7/28), as shown in Table III. Moreover, two thirds of the discovered occult injuries were the result of explosive devices.

Overall, of the 31 patients with positive study results, 18 (58%) had a normal pulse examination; 10 (32%) had an abnormal examination to include a bruit, thrill, or diminished ankle/brachial index; and 3 (10%) were limited by bulky dressings or an external fixator when used to stabilize a fracture.

**Endovascular therapy.** Nearly one third (9/31) of patients with an abnormal arteriogram required some form of operation or procedure. Most interventions were performed for treatment of pseudoaneurysms or arteriovenous fistulae. One third (3/9) of these patients had a normal physical examination on presentation. More than half (5/9) had a catheter-based technique as part of their treatment. Two successful low-profile covered stents were placed for injuries to the axillary and brachial arteries. Three coil embolizations were performed for pseudoaneurysms or arteriovenous fistulae. Table IV describes the management of these 9 arterial injuries.

## DISCUSSION

Ongoing military conflicts in Iraq and Afghanistan have resulted in thousands of combat casualties. Diagnosis and management of occult injuries, the application of endovascular techniques, and complications related to the use of prosthetic grafts have prompted this preliminary report and contemporary review of wartime vascular trauma.

The majority of vascular injuries (64%) in this series resulted from IEDs, and 90% of these fragmentation injuries involved the extremities. Nearly all wounds occurred to the face, arms, and legs. A lack of body armor protection or nonsurvivable trunkal vascular trauma might account for the prevalence of extremity injuries observed. Current injury patterns reflect past experience with a large number of extremity-based fragmentation injuries caused by high-energy explosives. During World War II and the Korean and Vietnam wars, more than 60% of vascular injuries were the result of blast fragments<sup>2</sup> to the extremities. In this series gunshot wounds from high-velocity weapons ac-

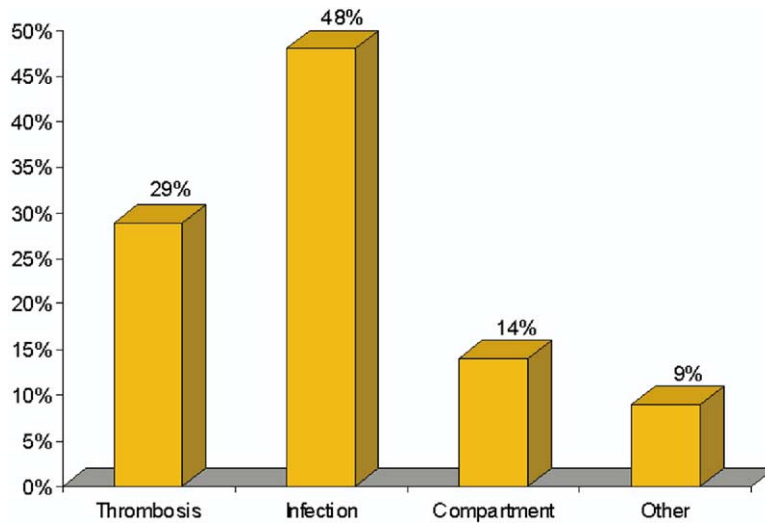


Fig. Complications of repair in 21 (44%) of 48 patients.

Table III. Arteriographic indications and findings

| Indication                    | No. of patients | No. of positive findings |
|-------------------------------|-----------------|--------------------------|
| Mechanism of injury           | 28              | 7                        |
| Abnormal physical examination | 22              | 16                       |
| Operative planning            | 12              | 8                        |
| Evaluate vascular repair      | 5               | 1                        |
| Total                         | 67              | 31                       |

counted for 25% of vascular injuries, producing deep cavitary wounds frequently associated with fracture and neurovascular injury.

Almost half (44%) of all vascular repairs involved the brachial or SFA. In the preliminary report of the Vietnam Vascular Registry, 60% of the major arterial injuries were in the lower extremity. The superficial femoral and brachial arteries were also the most common extremity-based vascular injury in that large series.<sup>4</sup> As in prior conflicts, reports of major thoracic or abdominal arteries represent less than 5% of all major injuries.

Forty-eight patients underwent repair of a vascular injury by a forward surgical team or at a combat support hospital. The majority of vascular repairs were performed within the first 6 hours after injury. Expeditious aeromedical evacuation, as demonstrated first in Korea and then Vietnam, has permitted patients to undergo emergency operations close to the point of injury and, as a result, has improved outcomes.<sup>9</sup> In contrast, only 81 (3%) of 2471 vascular injuries underwent an attempt at repair during World War II.<sup>10</sup>

Arterial repair with a reversed saphenous vein graft comprised the majority (42%) of vascular repairs in this series. Brachial (32%), superficial femoral (27%), and popliteal (23%) arteries were the most common sites for vein

graft interposition. In many cases a 2-team approach was used, with one team dedicated to saphenous vein harvest and the other to expeditious exploration and preparation of the injured vessel for repair. One third of the vascular injuries were associated with long bone fractures. Early placement of external fixators was performed to stabilize fractures and minimize damage to a fresh arterial repair. Vein grafts were covered by healthy tissue or routed around the zone of injury and not placed through a contaminated wound bed if possible. Several patent venous interposition grafts were excised on arrival to our treatment facility because they were placed in a contaminated wound bed and were at high risk for anastomotic rupture.

Primary repair of vascular injuries was rarely used in this review. Military explosives often produce a deep cavitary injury and segmental arterial loss, precluding such an option. For primary repair to be successful, it is essential to perform adequate debridement. In the case of stab wounds or isolated missile-fragment wounds, with which arterial laceration is more common, this method of management might be more feasible. Mobilization of the arterial ends in a young patient with nondiseased arteries often allows the construction of a tensionless primary arterial repair.<sup>11</sup>

In this series nearly all radial artery, ulnar artery, external carotid artery, and jugular venous injuries were ligated. Ligation of vascular injuries is an expedient and useful option for selected vessels. This strategy has been advocated previously and is associated with a low complication rate in these vascular beds.<sup>12</sup> Ligation within the zone of injury, however, should be avoided because it puts the vessel at risk for later rupture caused by bacterial infection. Therefore it is recommended to perform first an adequate debridement, followed by ligation out of the zone of injury, where the arterial stump can be covered with healthy uninjured tissue. Examination of the extremity after ligation with hand-held Doppler scanning is useful to confirm tissue perfusion and limb viability.

**Table IV.** Endovascular and open interventions on patients with positive arteriographic results

| <i>Artery</i>       | <i>Arteriogram</i>  | <i>Physical examination</i> | <i>Management</i>   |
|---------------------|---------------------|-----------------------------|---------------------|
| Brachial            | Pseudoaneurysm      | Painful mass                | Covered stent graft |
| Axillary            | Pseudoaneurysm      | Bruit, thrill               | Covered stent graft |
| Posterior tibial    | AV fistula          | Normal                      | Coil embolization   |
| Posterior tibial    | Pseudoaneurysm      | Pulsatile ankle mass        | Coil embolization   |
| Posterior tibial    | AV fistula          | Normal                      | Coil embolization   |
| Common femoral      | AV fistula          | Bruit, thrill               | Open ligation       |
| Profunda femoral    | Pseudoaneurysm      | Pulsatile mass              | Vein graft          |
| Superficial femoral | Vein graft occluded | Hemorrhage                  | Graft excision      |
| Brachial            | Vein graft stenosis | Normal                      | Patch angioplasty   |

AV, Arteriovenous.

The use of prosthetic graft material to treat arterial trauma remains controversial. During the Vietnam war, complications were reported in nearly all of the cases in which prosthetic grafts were used.<sup>4</sup> In this series 5 repairs were performed with prosthetic grafts, and 4 of the 5 resulted in failure caused by either infection or thrombosis. Moreover, when prosthetic grafts were associated with infection or a mangled extremity, a secondary amputation was usually performed. On the basis of this and previous reports, we feel strongly that using prosthetic grafts for combat injuries is uniformly associated with poor outcome, and their use is to be discouraged.<sup>4,11,13</sup>

In this series 25% of patients required additional operative interventions after medical evacuation from the war theater. Patients usually require serial wound irrigation and debridement, skin grafting, vascular graft revision, or management of occult injuries detected during subsequent evaluations. In Vietnam approximately 28% of major arterial repairs were initially inadequate, requiring multiple additional procedures to obtain a successful outcome.<sup>4</sup> All wounds should be considered contaminated, and coverage of the arterial repair with local tissue flaps was used to reduce the risk of arterial rupture. The majority of extremity soft tissue wounds were complex, involving combined vascular, orthopedic, and neurologic injury. The management of these wounds was facilitated by using an experienced multidisciplinary team of surgeons. Although wound closures from blast injury might require rotational flaps or split-thickness skin grafting, vacuum dressings have expedited closure. Nearly all wounds had vacuum-assisted closure dressings applied between washouts. This novel application was invaluable to the management of complex open wounds and has simplified the care of large soft tissue defects.

In this series complication rates were consistently associated with massive soft tissue destruction, damaged long arterial segments, and infection. One third of extremity wounds had associated tibial nerve injury, a major sensory deficit, or a concomitant long bone fracture. Complication rates have not differed substantially from the Vietnam experience.<sup>4,14</sup> Infection accounted for most of the graft failures and subsequent secondary amputations. Injuries to the SFA had the highest rate of associated postoperative complications. Of 11 repairs, 9 (82%) resulted in a wound

complication or graft infection. All infected grafts required excision and eventually resulted in amputation. Two patients reportedly had compartment syndrome. However, this type of detailed documentation is often lacking, and some might have had fasciotomy at stops along the evacuation chain before arriving at Walter Reed. Liberal fasciotomy is strongly advised at the time of initial surgery because close surveillance is often not practical during long aeromedical evacuation times. Eight amputations occurred among the 48 patients in this series who had vascular injuries requiring immediate repair in Iraq or Afghanistan. Although difficult to determine, it has been our perception that most amputations were the result of massive soft tissue trauma and infection. Arterial injury in itself did not represent the major factor for limb loss. An additional 8 (7.4%) of the 107 patients had a secondary amputation, all related to infectious complications after arriving at our institution. This is comparable with the wars of Korea and Vietnam, during which primary amputations decreased yet secondary amputations were highly influenced by late wound infections.<sup>15</sup>

Liberal arteriography was used in this series to look for occult injury in these extensive wounds. Civilian trauma experience has demonstrated that use of arteriography for asymptomatic blunt or penetrating injuries is not cost-effective and in most cases unwarranted.<sup>16-18</sup> In contrast, however, the large percentage (46%) of arteriographic abnormalities found in this series (Table III) suggests that blast injury from military munitions is a high-risk mechanism and likely to have occult vascular injury, especially when associated with long bone fractures or neurologic injury. Most arteriographic abnormalities were asymptomatic occlusions of tibial vessels; however, 7 (18%) of 40 were arteriovenous fistulas and pseudoaneurysms that required treatment. When asymptomatic patients with extremity blast injuries were evaluated for missile fragments in proximity to major vascular structures, 25% were positive. One third of these patients required intervention for abnormal arteriographic findings. Therefore the predictive accuracy of a normal vascular examination is uncertain when applied to military extremity trauma caused by IEDs and high-velocity weapons. Furthermore, many soldiers have duty stations remote from tertiary hospitals, and this presents a



challenge to careful follow-up. For this reason, others have advocated arteriography in this setting.<sup>15</sup>

Endovascular strategies were used to treat 5 occult arterial injuries found on arteriography in this series (Table IV). Three tibial arteriovenous fistulae were successfully coil embolized. Low-profile covered stents were used to treat 2 patients, one for a very proximal brachial artery pseudoaneurysm and one for an axillary artery pseudoaneurysm. Both injuries were associated with an arteriovenous fistula. Percutaneous placement of covered stents or coils has been reported in civilian trauma.<sup>19,20</sup> Endovascular strategies for military trauma have also been previously described and applied by our group for selected vascular trauma.<sup>21</sup> The delayed and stable nature of these lesions makes them particularly suitable for endovascular management. By 1 to 4 weeks after the initial injury, many of these wounds have already begun to heal, with significant scarring in these young patients. The complexity of the soft tissue and skeletal injuries make them hazardous lesions for intervention, and stents avoided a difficult dissection in a deep cavitary wound. All covered stents were placed percutaneously remote from the site of injury in nonbacteremic patients receiving intravenous antibiotics. The use of catheter-based treatments has had a profound effect on reducing the morbidity associated in managing these occult vascular injuries.

## CONCLUSION

Current patterns of military vascular injuries are similar to past experiences. Extremity vascular injuries to the brachial artery and SFA remain most common. In the current conflict, the majority of these are blast injuries caused by fragments from IEDs. The wounds are usually extensive, resulting in segmental arterial loss, and are often associated with bony fracture and nerve injury. Continuous assessment for fasciotomy, frequent and extensive wound debridement to healthy tissue in conjunction with serial irrigation, and careful wound surveillance is necessary for limb salvage. Autologous saphenous vein graft interposition remains the treatment of choice for the majority of vascular injuries. Although rarely used in this conflict, repair of vascular injuries with prosthetic grafts uniformly resulted in failure from infection or thrombosis and required secondary amputation. Vascular repairs should be covered by healthy tissue, and routing in contaminated wound beds should be avoided. Therefore these injuries are best managed by means of initial ligation and wound debridement with delayed closure, followed by autologous vein bypass out of the zone of injury. Complication rates remain high, with up to 25% of patients requiring additional operations or procedures on arrival to hospitals in the United States. Secondary management of extensive soft tissue wounds has been simplified with the use of vacuum dressings. The injury patterns observed during this conflict support the liberal application of contrast arteriography, particularly for patients wounded by IEDs with large soft tissue defects and

skeletal injury. Finally, catheter-based strategies have been useful in managing the late diagnosis of traumatic arteriovenous fistulae and false aneurysms associated with these extensive wounds. Endovascular management of these injuries in a complex healing wound might represent the single most significant difference in the management of vascular injuries from prior conflicts.

## REFERENCES

1. DeBakey ME. History, the torch that illuminates: lessons from military medicine. *Mil Med* 1996;161:711-6.
2. Rich NM. Vascular trauma in Vietnam. *J Cardiovasc Surg (Torino)* 1970;11:368-77.
3. Rich NM, Baugh JH, Hughes CW. Significance of complications associated with vascular repairs performed in Vietnam. *Arch Surg* 1970;100:646-51.
4. Rich NM, Hughes CW. Vietnam vascular registry: a preliminary report. *Surgery* 1969;65:218-26.
5. Bilski TR, Baker BC, Grove JR, Hinks RP, Harrison MJ, Sabra JP, et al. Battlefield casualties treated at Camp Rhino, Afghanistan: lessons learned. *J Trauma* 2003;54:814-21.
6. Carey ME. Analysis of wounds incurred by U.S. Army Seventh Corps personnel treated in Corps hospitals during Operation Desert Storm, February 20 to March 10, 1991. *J Trauma* 1996;40(suppl):S165-9.
7. Islinger RB, Kuklo TR, McHale KA. A review of orthopedic injuries in three recent U.S. military conflicts. *Mil Med* 2000;165:463-5.
8. Mabry RL, Holcomb JB, Baker AM, Cloonan CC, Uhorchak JM, Perkins DE, et al. United States Army Rangers in Somalia: an analysis of combat casualties on an urban battlefield. *J Trauma* 2000;49:515-28.
9. Rich NM. Vietnam missile wounds evaluated in 750 patients. *Mil Med* 1968;133:9-22.
10. Rich NM, Rhee P. An historical tour of vascular injury management: from its inception to the new millennium. *Surg Clin North Am* 2001;81:1199-215.
11. Rich NM, Hughes CW. The fate of prosthetic material used to repair vascular injuries in contaminated wounds. *J Trauma* 1972;12:459-67.
12. Aftabuddin M, Islam N, Jafar MA, Haque E, Alimuzzaman M. Management of isolated radial or ulnar arteries at the forearm. *J Trauma* 1995;38:149-51.
13. Wolf YG, Rivkind A. Vascular trauma in high-velocity gunshot wounds and shrapnel-blast injuries in Israel. *Surg Clin North Am* 2002;82:237-44.
14. Rich NM. Complications of vascular injury management. *Surg Clin North Am* 2002;82:143-74, xxi.
15. Hughes CW. The primary repair of wounds of major arteries; an analysis of experience in Korea in 1953. *Ann Surg* 1955;141:297-303.
16. Frykberg ER, Crump JM, Vines FS, et al. A reassessment of the role of arteriography in penetrating proximity extremity trauma: a prospective study. *J Trauma* 1989;29:1041-50.
17. Gillespie DL, Woodson J, Kaufman J, Parker J, Greenfield A, Menzoian JO. Role of arteriography for blunt or penetrating injuries in proximity to major vascular structures: an evolution in management. *Ann Vasc Surg* 1993;7:145-9.
18. Kaufman JA, Parker JE, Gillespie DL, Greenfield AJ, Woodson J, Menzoian JO. Arteriography for proximity of injury in penetrating extremity trauma. *J Vasc Interv Radiol* 1992;3:719-23.
19. McArthur CS, Marin ML. Endovascular therapy for the treatment of arterial trauma. *Mt Sinai J Med* 2004;71:4-11.
20. Lin PH, Koffron AJ, Guske PJ, et al. Penetrating injuries of the subclavian artery. *Am J Surg* 2003;185:580-4.
21. Rosa P, O'Donnell SD, Goff JM, Gillespie DL, Starnes B. Endovascular management of a peroneal artery injury due to a military fragment wound. *Ann Vasc Surg* 2003;17:678-81.

Submitted Oct 26, 2004; accepted Jan 11, 2005.

## DISCUSSION

**Dr Scott Berman** (Tucson, Arizona). I am honored to discuss the first systematic review of wartime vascular trauma since the landmark work of Dr Rich in the Vietnam Vascular Registry. The findings of the Vietnam Vascular Registry and its related publications have served as a benchmark for managing vascular trauma for the last quarter century.

Dr Fox and his colleagues at Walter Reed are in the process of collecting data on vascular injuries in the modern era of war, comprising Operations Enduring Freedom and Iraqi Freedom.

First and foremost, this experience should place into proper perspective the triviality of the turf wars that we are now engaged in on a daily basis with our own axis of evil, namely, cardiology, radiology and the payers, including CMS. Those of us who let these problems embroil our everyday lives must take a step back and realize what our military colleagues in combat zones must endure on a daily basis. Regardless of what side of the war debate we choose to align with, I'm certain there is uniform support for the members of our Armed Forces who regularly place their lives in jeopardy without regard for politics.

Dr Fox has presented the current experience with vascular trauma managed at Walter Reed in patients evacuated from the Middle East theatre. The observation that nearly half of these patients underwent initial vascular reconstruction prior to transfer to the continental United States is testimony to the ability of forward surgical teams and combat support hospitals to identify and treat complicated vascular injuries. However, it is interesting how over the last 30 years we have somewhat come full circle. Results with prosthetic reconstruction in the Vietnam Vascular Registry were poor then and are similarly poor in the modern series presented today.

This brings me to my first question. Why were prosthetic grafts used at all in this series? All the reconstructions reported were peripheral upper or lower extremity vessels, which lend themselves well to autologous repair.

The amputation rate is also similar to that seen in the Vietnam conflict. It would be interesting to know what the injury severity score was of the patients undergoing primary amputation. What was the difference between those patients undergoing reconstruction versus amputation in the combat zone? Were ligation and amputation done as part of a damage control regimen in more severely injured patients, or were the primary amputations a result of mangled extremities?

Another interesting observation is the contrast between the era of the Korean and Vietnam conflicts and the present. Surgical techniques that evolved out of wartime surgery from Korea and Vietnam subsequently found application in the civilian setting. By contrast, and likely the result of 20 years of relative peace, the current report highlights how endovascular techniques developed for chronic vascular problems, characteristics of civilians, have now been extrapolated to trauma and wartime injuries.

This brings me to my final question. What were the indications for endovascular intervention in this series? As with most of us, the ability to perform and the technical challenges posed by new technologies and techniques often drives the search for indications. However, we must avoid the tendency to let minimally invasive

become maximally intensive, and often expensive, in an effort not to make an incision.

I congratulate the authors for their presentation and thank them for their service. I thank the Society for the opportunity to discuss this paper, and remind us all to appreciate that, at least for the moment, cardiologist and radiologists are not shooting at us with rocket propelled grenades.

**Dr Charles J. Fox** (Washington, DC). With regard to prosthetic graft use, we eagerly await reports from anyone who can help us complete our registry and knowledge with respect to those patients. I would point out that Dr DeBakey, in his landmark paper during World War II said, "It's important to know all circumstances about a case before drawing conclusions". I can tell you that our deployed general surgeons are well trained and highly capable.

As you point out, prosthetic grafts are associated with a bad outcome and are to be avoided. Forward surgical teams are positioned directly on the forward edge of the battle area. I'm sure it's very chaotic and mass casualty situations or decisions of life over limb may be influencing some of those decisions in selected cases. In this series, we point out that there were five prosthetic grafts placed in a total of 64 repairs. We have noticed that since the start of the war, its use has dramatically declined.

On calculating scores, we're interested in looking into that as well. I suspect that in terms of the amputations performed in the battle area, that they were probably the result of mangled extremities. I have begun to look at injury severity scores, but the data are preliminary. I've currently looked at about one-third of the 107 patients. It looks like the median score is around 40, with a range of 16 to 75.

Certainly the decision whether to salvage or amputate a mangled extremity is very challenging, and requires a multidisciplinary team and recommendations from very experienced surgeons. Therefore, we're in the process of obtaining mangled extremity scores to get more data.

Last, with respect to endovascular interventions, we currently applied these techniques to about half of the occult injuries that required some intervention. That probably mimics our current vascular practice, where 50% of our practice is endovascular.

Civilian trauma centers have taught us that endovascular interventions have a role and are performed successfully. We also have one previously published report on coil embolization from a military fragment injury.

I think patient selection is key. In many cases, with a liberal application of arteriography for military munitions, you already are performing a diagnostic study. In that case, the sheath and catheter are already there and it's simply easier to fix the problem at that time.

In the case of the axillary pseudoaneurysm I presented. . . this was a sick patient with multiple injuries, where time and patient transport comes into play. A covered stent enabled us to have a percutaneous solution to someone who would otherwise have required a difficult surgical exposure, but these techniques are limited to tertiary medical centers.