



# Journal of Coloproctology

[www.jcol.org.br](http://www.jcol.org.br)



## Technical Note

# A necktie fashion vascular loop seton tie may simplify the treatment of perianal fistula

Nidal Issa<sup>a,b,\*</sup>, Ruben Weil<sup>a</sup>, Eldad Powsner<sup>a</sup>, Wisam Khoury<sup>c</sup>

<sup>a</sup> Rabin Medical Center, Petah Tikva, Israel

<sup>b</sup> Tel-Aviv University, Sackler School of Medicine, Petah Tikva, Israel

<sup>c</sup> Rambam Health Care Campus, Haifa, Israel

### ARTICLE INFO

#### Article history:

Received 2 September 2016

Accepted 5 September 2016

Available online xxx

#### Keywords:

Perianal fistula

Seton

Vascular loop

Necktie

### ABSTRACT

Seton for treatment of perianal fistula can be of the cutting or a loose type. We adopted a simple technique for tighten the seton by applying a necktie shape tie on the vascular loop, hence it can be used for drainage on the beginning, and for cutting purpose later on. In this retrospective study we report our experience on this seton tie method.

*Material and methods:* Patients operated for perianal fistula between 2012 and 2014 were reviewed.

*Results:* Of 63 patients operated, 23 (35%) had a necktie-tie seton. There were 15 (65%) men. Age  $34.1 \pm 10.6$ . Six (26%) had a recurrent fistula, 2 (9%) with loose seton in place. The external opening: anterior four (17%), lateral fifteen (65%), posterior three (13%), one patient (4%) had two opening. The internal opening was identified: posterior seventeen (74%), anterior four (17%) and right posterior two (8%). Nineteen (82%) had a trans-sphincteric tract, four (17%) females had an anterior location. Operative time was 32 min (range 22–55). The seton was tightened 4 times (range 2–5) with 2 weeks interval. Healing was achieved in 7 weeks (range 5–11). In 24 months (range 12–35) follow-up, no reported anal incontinence. Recurrence was observed in one patient (4%).

*Conclusion:* The necktie tightening of the vascular loop seton is a simple, safe, easily performed and may simplify the seton management of perianal fistulae.

© 2016 Sociedade Brasileira de Coloproctologia. Published by Elsevier Editora Ltda. This is an open access article under the CC BY-NC-ND license (<http://creativecommons.org/licenses/by-nc-nd/4.0/>).

## O seton para alça vascular com laçada em forma de nó de gravata pode simplificar o tratamento da fístula perianal

### R E S U M O

Setons para o tratamento de fístula perianal podem ser do tipo de corte ou do tipo frouxo. Adotamos uma técnica simples para apertar o seton, pela aplicação, na alça vascular, de uma laçada em forma de nó de gravata. Desse modo, inicialmente a laçada pode ser utilizada para

#### Palavras-chave:

Fístula perianal

Seton

\* Corresponding author.

E-mails: [nidaldrissa@hotmail.com](mailto:nidaldrissa@hotmail.com), [nidalissa@clalit.org.il](mailto:nidalissa@clalit.org.il) (N. Issa).

<http://dx.doi.org/10.1016/j.jcol.2016.09.001>

2237-9363/© 2016 Sociedade Brasileira de Coloproctologia. Published by Elsevier Editora Ltda. This is an open access article under the CC BY-NC-ND license (<http://creativecommons.org/licenses/by-nc-nd/4.0/>).

Alça vascular  
Gravata

drenagem e, subsequentemente, para as finalidades de corte. Neste estudo retrospectivo, relatamos nossa experiência com este método de aplicação da laçada do Seton em nó de gravata.

**Material e métodos:** Foram revisados pacientes operados para fístula perianal entre 2012–2014.

**Resultados:** Dos 63 pacientes operados, 23 (35%) receberam um Seton em nó de gravata. Desse total, 15 (65%) eram homens, com média de idade de  $34,1 \pm 10,6$  anos. Seis (26%) tiveram fístula recorrente, e dois (9%) tiveram afrouxamento do seton in loco. Foram identificadas aberturas externas: anteriores, quatro (17%); laterais, 15 (65%); posteriores, três (13%); e duas aberturas em um paciente (4%). Também foram identificadas aberturas internas: posteriores, 17 (74%); anteriores, quatro (17%); e posteriores direitas, duas (8%). Em 19 (82%) havia um trato trans-esfínctérico, e quatro pacientes mulheres (17%) tiveram localização anterior. O tempo de cirurgia foi de 32 minutos (variação, 22–55). O seton foi apertado 4 vezes (variação, 2–5) a intervalos de 2 semanas. A cicatrização ocorreu em sete semanas (variação, 5–11). Ao longo dos 24 meses (variação, 12–35) de seguimento dos pacientes, não houve relato de incontinência anal. Houve recorrência em um paciente (4%).

**Conclusão:** O aperto do Seton em alça vascular pela técnica do nó de gravata é método simples, seguro, de fácil realização e que pode simplificar o tratamento de fístulas perianais com Seton.

© 2016 Sociedade Brasileira de Coloproctologia. Publicado por Elsevier Editora Ltda. Este é um artigo Open Access sob uma licença CC BY-NC-ND (<http://creativecommons.org/licenses/by-nc-nd/4.0/>).

## Introduction

Perianal fistula is a common proctological disease with prevalence that reaches 2.8/10,000 in some western countries.<sup>1</sup> The classification of perianal fistula is based on the location of its tract in relation to anal sphincter muscle: submucosal, intersphincteric, transsphincteric, suprasphincteric, or extrasphincteric.<sup>2</sup> When the fistula tract crosses more than 30% of the external sphincter, has an anterior location in a woman, or there are multiple tracts the fistula is then considered complex.

Usually the treatment of complex fistula poses a high risk for impairment of continence.<sup>3</sup>

Surgical treatment of perianal fistula is dictated by the amount of sphincter involvement, for this reason there is no single appropriate technique for the treatment of fistulas, and the treatment must balance between the extent of sphincter division, postoperative healing rate, and functional loss.<sup>3</sup> Whatever the type and the extent of fistula are, the principles of anal fistula surgery are to eradicate the fistulous tract preserve sphincter function, and prevent recurrence. There are several alternative for fistula treatment, but most of the superficial or minimal sphincter involvement fistulas have been traditionally treated by either fistulotomy, or fistulectomy, which have been proven to be effective.<sup>4</sup> Seton has been used for treatment of perianal fistula for many years; however, it was commonly used only for complex and high anal fistula in order to avoid fecal incontinence.<sup>5</sup>

The seton is passed through the fistula tract to convert an inflammatory process to a foreign body reaction causing perisphincteric fibrosis. Setons may be of the cutting type, for which a slow division of the muscle allows for fibrosis and scarring with minimal separation of the cut ends, hence the integrity of the sphincter complex is maintained. The technique involves sequential tightening of the seton through the

fistula tract and this allows for faster cutting and induction of scarring over the course of weeks. Alternatively, a loose seton may be placed to promote drainage and avoidance of recurrent perineal sepsis, and may be left in place long-term or removed with ultimate cure.<sup>6</sup>

Different types of setons are used for this purpose like silastic tube, silk, braided silk, rubber band, braided polyester, vascular loop, nylon, cable tie, and so forth.<sup>7</sup> The reported incontinence and recurrence rate ranges from 0% to 62%<sup>7</sup> and from 0% to 16%,<sup>8</sup> respectively, with different materials used as seton.

The vascular loop seton has several advantages: it is easy to handle, easy to insert to the fistula tract, can be used for drainage of abscesses within the fistula, can be used also for cutting purpose, and it can maintain the tension when tightened. Vascular loop can be used for several actions: drainage at the beginning, and later on can be tightened around the sphincter and advanced through.

Tighten the setons in case of cutting seton can be painful and troublesome for the patients, and it may necessitate analgesia and even anesthesia.

We adopted a simple and a practical tightening technique for tighten the seton by applying a necktie shape tie on the vascular loop, hence it can be used for drainage on the beginning, and for cutting purpose later on, it can be advanced easily, and provides convenient tightening in a clinic setting without need of analgesia.

In this retrospective study we aimed to report our experience on necktie vascular loop seton tie method on complicated perianal fistula.

## Patients and methods

All patients with perianal fistula treated in the department of surgery B, at Hasharon Hospital Rabin Medical Center from

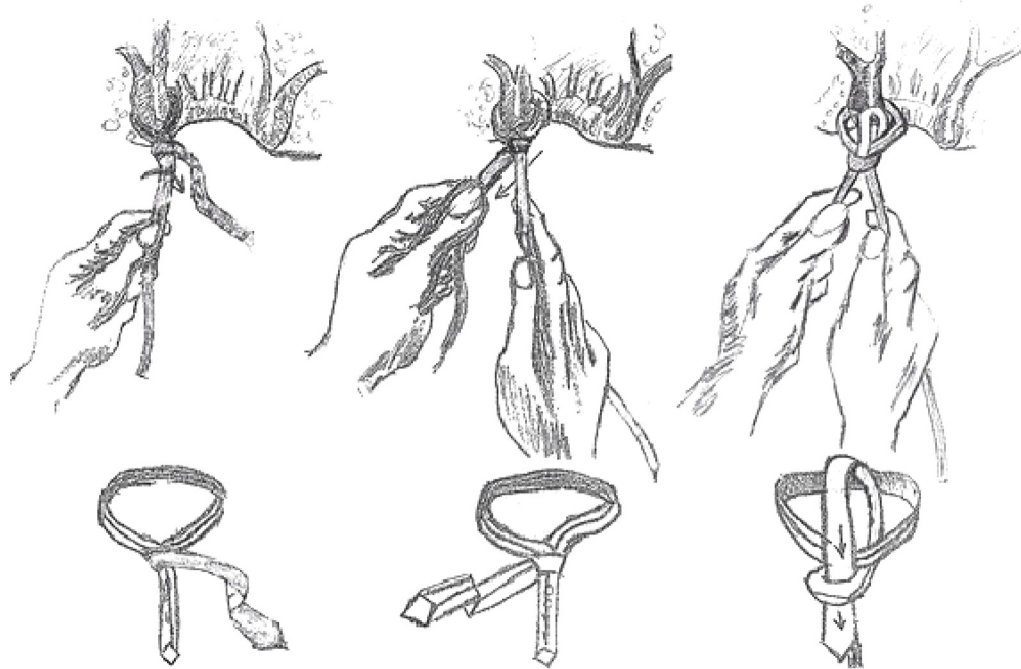


Fig. 1 – Necktie fashion of seton tie.

January 2012 and December 2014 were reviewed. Included were patients managed with necktie vascular loop seton. Patients with existing preoperative incontinence and inflammatory bowel disease were excluded.

The full medical records of the patients were obtained and collectively reviewed and recorded. Patients undergoing surgery for anal fistula were evaluated according to a standard protocol that included detailed medical and surgical history with regard to previous anorectal procedures, clinical examination with digital rectal examination and rigid proctoscopy for obtaining the localization of the external and internal openings, presence of localized tenderness or abscess, and previous scars. No effort was made to define the fistula tract by probing the openings on clinical examination. Endoanal ultrasound (EAS) or magnetic resonance imaging (MRI) was used for the tract investigation and sphincter involvement in some patients.

The procedure was performed under general or spinal anesthesia. The patients were placed in lithotomy or in a prone jackknife position depending on the location of the fistula.

The anus and the rectum were reexamined, the external opening of the fistula tract was gently probed using a standard blunt-tipped probe till the internal opening, and sometimes a hydrogen peroxide injection through the external opening is used for better visualization of the internal opening. The external fistula opening is usually widened and debrided of chronic granulation tissue. If the fistula tract is found to be deep and transphincteric location with involvement of large portion of the sphincter, then the anal mucosa and skin from the internal opening to the lateral portion of the tract was incised to allow the seton to settle onto the sphincter. A suture is then attached to the probe and pulled through. The other end is then tied to the vessel loop and then pulled through. The vessel loop

circling the sphincter complex is tied in a necktie fashion (Fig. 1) and tightened with its long end to make it sit loosely over the sphincter. A Vaseline gauze dressing was used to cover the wound.

Postoperative pain management for all patients included oral dipyrrone or paracetamol and oral narcotics (tramadol) on demand. Care at home consisted of hot soaks or Sitz bath and dry gauze covering.

Patients were seen in the clinic after 10 days to evaluate wound and to reinforce postoperative instructions. The patients were seen every other week and vascular loop was tightened simply by pulling the long end. On each visit, patients were asked about secretion, pains and incontinence. Also patients were taught how to pull the seton end. Complete advancement and spontaneous drop of tightened seton was considered as healing sign of the fistula. The patients were followed at a 3 months interval for re-evaluation.

## Results

We operated on 63 patients with perianal fistula between January 2012 and December 2014. Twenty three (35%) patients underwent the intervention with a necktie tie vascular loop seton. There were 15 (65%) men and 8 (35%) women. Their mean age was  $34.1 \pm 10.6$  years.

Twenty (87%) patients had a history of previous perianal abscess incision. Six (26%) patients had also a previous fistula surgery and presented with a recurrent fistula, two (9%) of them had a loose seton in place. Preoperative evaluation by EAS was performed in 6 patients and MRI in 3 patients. Table 1 summarizes the demographic data.

**Table 1 – Demographics and perioperative data.**

Male/female	15/8
Age (years)	34.1 ± 10.6
Previous drainage of perianal abscess (n)	20 (87%)
Recurrent fistula (n)	6 (26%)
Fistula with seton (n)	2 (9%)
<i>External opening location</i>	
Lateral	15(65%)
Anterior	4 (17%)
Posterior	3 (13%)
<i>Internal opening location</i>	
Posterior	17 (74%)
Anterior	4 (17%)
Right lateral	2 (9%)
Mean operation time (min)	32 (22–55)

The procedure was performed under general anesthesia in 18 (78%) patients and spinal anesthesia in 5 (22%) patients. The location of the external fistula opening was in the anterior perianal region in 4 (17%) patients, a lateral location in 15 (65%) patients, posteriorly in 3 (13%) patients, and another patient (4%) had two external openings; left lateral and posterior location. The internal fistula opening was identified in all the cases, however, in 14 (61%) patients the identification was permitted after the hydrogen peroxide injection through the external opening. The internal opening was identified to be in posterior location in 17 (74%) patients, anterior location in 4 (17%) and right posterior location in 2 (8%) patients.

In 19 (82%) patients a trans-sphincteric fistulous tract involving a large portion of the external sphincter was found, six (26%) of them had a recurrent fistula while two patients had a loose seton in place. Four (17%) female patients had an anterior location of fistulous tract. In 5 (22%) patients a cavity with residual abscess was found within the fistula tract beneath the perianal skin.

The vascular loop seton which was inserted in the fistula tract in all the cases, circling the sphincter complex loosely, was tied in a necktie fashion.

The mean operative time was 32 min (with a range of 22–55 min). All the patients were discharged the day after the intervention.

The vascular loop seton was tightened with a median of 4 times (range 2–5 times) with 2 weeks interval, 4 patients performed a self-tightening by pulling the long end of the vascular loop tie. All patients tolerated very well with no or minimal analgesia. Complete healing was achieved in 7 weeks (5–11). Patients were followed up for a median of 24 months (12–35).

Seven patients (20%) had a soiling or frequent secretion during the first 4 weeks of the healing process, which decreased gradually. None of the patients reported fecal or flatal incontinence.

None of the patients had bleeding, wound infection, premature dislodgement, or slippage of the seton.

Recurrence was observed in one male patient (4%) three months after the healing. At the re-operation a superficial fistula without sphincter involvement (a long skin bridge), was found, and a lying open fistulotomy was done.

## Discussion

While the diagnostic and surgical techniques advance rapidly, the role of setons in the treatment of perianal fistulas seems to be kept up over the time. Different seton materials has been used with different rates of recurrence and incontinence. But whatever the material is, recurrence and incontinence rate is mainly dependent on the experience and surgical precision and capability of the surgeon.<sup>7</sup>

The seton material used for fistula treatment should be durable, non-allergic, technically easy to tie even in clinic setting, and allows to tight repeatedly without causing pain and without anesthesia.<sup>9</sup> With these properties, vascular loop seems to be the appropriate seton. It is easy to handle, non toxic and can easily tighten; hence, when a necktie tie is performed, the tightening can be gradual and controlled. The necktie tie is very well known tie, easily performed by most of the surgeons, can maintain the tension propriety. Therefore, tightening the vascular loop seton can be easily performed in clinic setting by pulling on the long end of the loop, unlike other setons, for which the patient is taken to operating room repeatedly with the associated morbidity and costs. Also it can be self-tightened by the patient without even the need for surgical visit.

For subcutaneous, low inter-sphincteric fistulas or fistula with minimal involvement only of the subcutaneous part of external sphincter, a fistulotomy can be usually performed safely. And in our opinion all the other fistulas, the fistulotomy should be avoided and other surgical technique as seton would be more appropriate. The utility of setons have been well-established but in some large case series have been reported to use this procedure in 10% of the cases.<sup>10</sup>

In our study, we found 0% incontinence and 4.3% recurrence rate in 23 patients treated with the vascular loop seton for transphincteric and complicated fistulas.

A different published data on the use of setons in perianal fistula reported a 4–5% rate of recurrence<sup>8,11</sup> and a 0–5% rates of incontinence<sup>8,11</sup> that are in accordance of our present results.

The incontinence reported in different studies is usually of minor nature. The 0% incontinence rate in our study can be attributed to meticulous surgical technique whereby sphincter remains intact. Low recurrence rate in our study is due to proper identification of internal opening and the extensions of fistula tract.

Loose seton or draining seton for complicated perianal fistula, usually requires second procedure.<sup>12,13</sup> For high transsphincteric with abscess and local sepsis, a loose seton acts as drainage seton. Once the abscess has been resolved for a cryptoglandular fistula the treatment decision involves the use of sphincter-sparing versus sphincter-cutting options. Setons for such treatment can be considered either as a cutting or loose seton. A cutting seton can be used as a single- or multi-stage procedure, but in our study, in 5 (18%) patients the loose vascular loop was used initially for drainage of the residual abscess and later on for completion the definitive treatment of the fistula tract by converting it to cutting seton with a simple tightening the necktie tie by pulling on the long end of the loop.

Currently, the cutting setons are associated with pain, uncontrolled cutting of sphincter muscles and a higher rate of incontinence. If the patient is willing to try a prolonged treatment option then he can be offered the long-term loose seton with progressive migration but using the vascular loop tightened with a necktie fashion can permit the same seton for drainage when loose and for cutting purpose in one stage by simple tightening.

Once tightened by a necktie fashion tie, the vascular loop does not lose tension as in simple tie,<sup>6</sup> and has no bulky and imprecise tightening as faced in bunch of silk ties, or second procedure as in draining setons. The vascular loop does not absorb liquids and secretions hence, permits repeatedly and easily manageable tightening

After tightening, none of the patients had a significant pain for more than few minutes

The controlled and gradual tightening decreased the incidence of incontinence and recurrence; however, at the cost of relatively longer time of seton in place (5–11 weeks).

None of the patients reported any difficulty in carrying out routine activities. The vascular loop, once engaged, is retained in place without any irritation of the surrounding tissue.

Our results are probably also related to the intensive ambulatory follow-up that we offered to our patients. In fact they were followed every 2 weeks and seton tightening has been done at each visit, and this accurate postoperative management required a good cooperation of the patients.

A wide range of incontinence rates was reported in the literature after cutting seton treatment, and Ritchie et al.<sup>7</sup> have concluded that there was no relationship between incontinence and the frequency of tightening, type of seton, or classification of fistula. Hence, we further reinforce the importance of surgeon's experience and the use of a seton having additive qualities as stated above.

Other techniques of treatment have been reported including fibrin glue, ligation of intersphincteric fistula tract (LIFT) and collagen plug. Metanalysis of trials on fibrin glue did not report any statistically significant difference over other techniques for recurrence or incontinence.<sup>14</sup> Accumulated experience of LIFT is also promising and sounds good alternative<sup>15</sup>; however, besides a steep learning curve, it needs technical expertise especially for complex fistulae.

The low incontinence rate in patients can be attributed to a careful dissection of the fistula tract with a minimal or no damage to the anal sphincter muscle complex. Also the gradual cutting through of the sphincter caused by direct compression of the vascular loop allows fibrosis to occur with the resultant advancement of the loop within intact or non-distracted muscle.

The factors implicated in fistula recurrence include the complexity and level of the fistula, the presence or absence of a horseshoe extension, the degree of laterality of the external opening, failure by the surgeon to identify the internal opening at initial surgery, and the overall surgical experience of the operator in complicated proctologic practice.<sup>16</sup>

In our study, we were able to identify the internal opening in all the patients, which might contribute to the high success rate of treatment.

All the procedures were done by a single surgeon, eliminating the bias which could have occurred with multiple

surgeons. However, it is a single-arm study with no comparison group and lacking of randomization, so we think a larger and a randomized study may be needed.

## Conclusion

The necktie tightening of the vascular loop seton is a simple, safe, easily performed and may simplify the seton management of perianal fistulae. This technique may broaden the options and may add a practical tip to surgical repertoire of complex fistula surgery. It does not carry the disadvantage of repeated anesthesia and visits to the operating room, has a low morbidity and may be very convenience to the patient.

## Conflicts of interest

The authors declare no conflicts of interest.

## REFERENCES

- Zanotti C, Martinez-Puente C, Pascual I, Pascual M, Herreros D, Garcia-Olmo D. An assessment of the incidence of fistula-in-ano in four countries of the European Union. *Int J Colorectal Dis.* 2007;1459–62.
- Parks AG, Gordon PH, Hardcastle JD. A classification of fistula in ano. *Br J Surg.* 1976:1–12.
- Kodner IJ, Mazor A, Shemesh EI, Fry RD, Fleshman JW, Birnbaum EH. Endorectal advancement flap repair of rectovaginal and other complicated anorectal fistulas. *Surgery.* 1993:682–90.
- Seow-Choen F, Nicholls RJ. Anal fistula. *Br J Surg.* 1992:197–205.
- Pearl RK, Andrews JR, Orsay CP, Weisman RI, Prasad ML, Nelson RL, et al. Role of the seton in the management of anorectal fistulas. *Dis Colon Rectum.* 1993:573–9.
- Mentes BB, Oktemer S, Tezcaner T, Azih C, Leventoglu S, Oguz M. Elastic one-stage cutting seton for the treatment of high anal fistulas: preliminary results. *Tech Coloproctol.* 2004:159–62.
- Ritchie RD, Sackier JM, Hodde JP. Incontinence rates after cutting seton treatment for anal fistula. *Colorectal Dis.* 2009:564–71.
- Vial M, Parés D, Pera M, Grande L. Faecal incontinence after seton treatment for anal fistulae with and without surgical division of internal anal sphincter: a systematic review. *Colorectal Dis.* 2010:172–8.
- Gurer A, Ozlem N, Gokakin AK, Ozdogan M, Kulacoglu H, Aydin R. A novel material in seton treatment of fistula-in-ano. *Am J Surg.* 2007:794–6.
- Chuang-Wei C, Chang-Chieh W, Cheng-Wen H, Tsai-Yu L, Chun-Che F, Shu-Wen J. Cutting seton for complex anal fistulas. *Surgeon.* 2008:185–8.
- McCourtney JS, Finlay IG. Cutting seton without preliminary internal sphincterotomy in management of complex high fistula-in-ano. *Dis Colon Rectum.* 1996:55–8.
- Pearl RK, Andrews JR, Orsay CP, Weisman RL, Prasad ML, Nelson RL, et al. Role of the seton in the management of anorectal fistulas. *Dis Colon Rectum.* 1993:573–7.
- Garcia-Aguilar J, Belmonte C, Wong DW, Goldberg SM, Madoff RD. Cutting seton versus two-stage seton fistulotomy in the surgical management of high anal fistula. *Br J Surg.* 1998:243–5.

14. Cirocchi R, Santoro A, Trastulli S, Farunella E, Di Rocoo G, Vendettuali D, et al. Meta-analysis of fibrin glue versus surgery for treatment of fistula-in-ano. *Ann Ital Chir.* 2010;349–56.
15. Shanwani A, Nor AM, Amri N. Ligation of the intersphincteric fistula tract (lift): a sphincter-saving technique for fistula-in-ano. *Dis Colon Rectum.* 2010:39–42.
16. Zbar AP, Ramesh J, Beer-Gabel M, Salazar R, Pescatori M. Conventional cutting vs. internal anal sphincter preserving seton for high trans-sphincteric fistula: a prospective randomized manometric and clinical trial. *Tech Coloproctol.* 2003:89–94.