

# Central venous catheter fracture during pacemaker lead extraction



Jacques Rizkallah, MD, Glen Sumner, MD, FRCPC, Robert Sheldon, MD, PhD, FRCPC, FHRS

*From the Libin Cardiovascular Institute of Alberta, University of Calgary, Calgary, Alberta, Canada.*

## Introduction

In this case report, we present an unusual and potentially life-threatening complication of cardiac electronic device lead extraction during which a peripherally inserted central venous catheter (CVC) coursing ipsilaterally to the pacemaker leads was fractured with the use of mechanical extraction tools. Subsequently, a fragment of this catheter embolized distally into the right atrium. To our knowledge, such a complication of mechanical lead extraction has never before been reported in the scientific literature.

## Case report

A 52-year-old white man with hypertension, dyslipidemia, stable coronary artery disease, and refractory persistent atrial fibrillation underwent total atrioventricular node ablation and left pectoral dual-chamber pacemaker implantation in 1997. In 2014, he developed pain over the pacemaker site and was found to have skin erosion with purulent discharge. Coagulase-negative *Staphylococcus aureus* and yeast were subsequently isolated from the device pocket. Antibiotics and antifungals were administered via a peripherally inserted CVC in the left brachial vein, with the tip positioned in the superior vena cava and right atrial junction (Figure 1).

Because of this device infection, the patient underwent extraction of the pacemaker generator and leads. A temporary transvenous pacemaker was inserted via the right femoral vein for backup pacing, and the pacemaker pocket was subsequently opened and extensively debrided. The pacemaker generator was explanted, and the 2 active fixation transvenous pacemaker leads were prepared for extraction in the standard fashion. Extraction of both atrial and ventricular leads was very challenging because of significant scar formation along most of their course. This procedure required the use of a 16F laser sheath and an Evolution

11F mechanical sheath (Cook Medical, Bloomington, IN) interchangeably as extraction tools. Both leads were eventually completely removed and were found to have extensive scar tissue along their length. As the patient was pacemaker dependent, a temporary pacing lead was implanted for backup pacing pending the implant of a new dual-chamber pacemaker system (Figure 2). The temporary system was placed on the same side as the infection to avoid vascular injury and possible localized infection in the contralateral venous access site where the new permanent pacemaker system was to be implanted once the infection resolved.

Following the lead-extraction procedure, the patient was incidentally found to have fracture and embolization of the peripherally inserted CVC. This finding was demonstrated by radiographic examination of the site of lead extraction. The distal end of the catheter embolized and wedged in the right atrium. There were no clinically significant sequelae, and the embolized distal end of the catheter was safely removed with a 6F gooseneck-type snare (ONE snare Endovascular Snare System; Merit Medical Systems, South Jordan, UT) via right internal jugular venous access. The proximal end of the CVC was withdrawn from its brachial venous insertion site.

## Discussion

In this case report, we present an unusual and potentially life-threatening complication of lead extraction, in which a CVC coursing ipsilaterally to the pacemaker leads was fractured during the use of mechanical sheaths. The catheter embolized distally into the right atrium. The polyurethane catheter was likely damaged intraoperatively directly by the use of the laser and Evolution mechanical extraction sheaths. To our knowledge, such a complication has not been reported previously in the scientific literature. It is very important to identify this complication promptly, given its potential life-threatening implications. If embolized to the pulmonary venous circulation, the fractured catheter fragment could potentially trigger a localized inflammatory and procoagulant milieu because of direct vascular injury, which may result in hemodynamic compromise. In other cases, the diagnosis of a fractured CVC may be elusive if not suspected, and routine fluoroscopic evaluation of the central

**KEYWORDS** Catheter fracture; Device infection; Laser sheath; Lead extraction; Peripherally inserted central venous catheter

**ABBREVIATIONS** CVC = central venous catheter (Heart Rhythm Case Reports 2016;2:11–13)

Conflicts of interest: The authors report no conflicts of interest. **Address reprint requests and correspondence:** Dr Robert Sheldon, HRIC GAA06, 3280 Hospital Drive NW, Calgary AB T2N 4Z6, Canada. E-mail address: sheldon@ucalgary.ca.

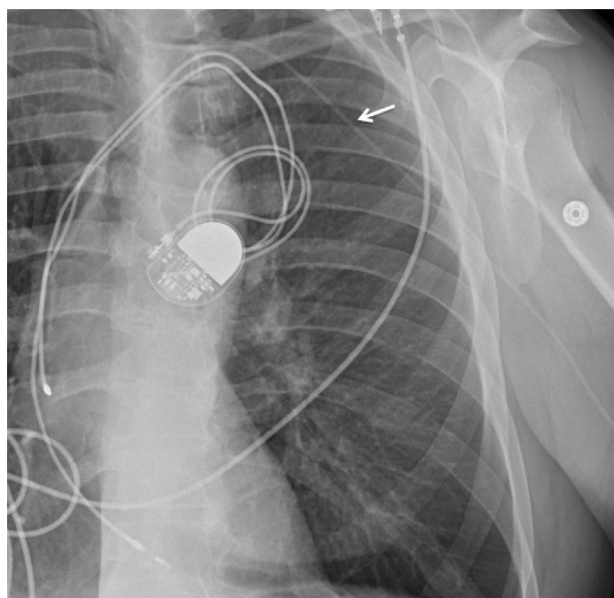
## KEY TEACHING POINTS

- Percutaneous lead extraction is not a low-risk procedure; it can be associated with life-threatening complications even among very experienced operators.
- Careful risk and benefit analysis is warranted for every patient to ensure lead extraction is appropriate and most ideal for a given clinical scenario.
- The integrity of peripherally inserted central venous catheters should be assessed fluoroscopically following the use of mechanical extraction sheaths to rule out any catheter damage or compromise.

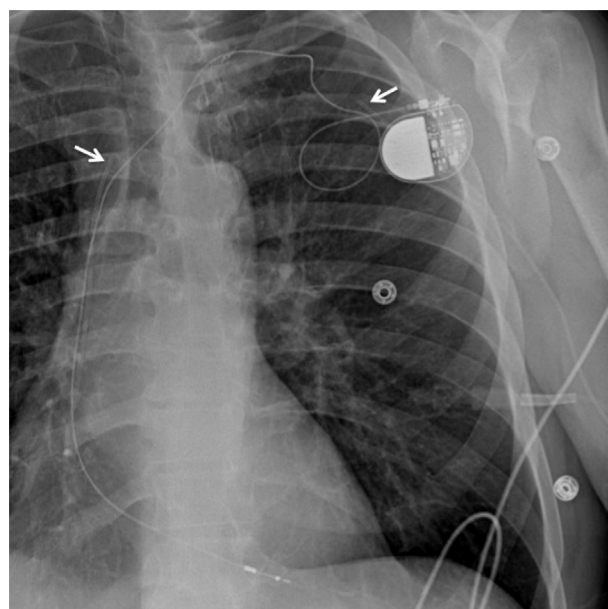
venous catheter integrity is warranted perioperatively to rule out any damage or compromise.

The use of cardiac implantable electronic devices such as pacemakers and defibrillators is increasing as more clinical indications are validated.<sup>1</sup> Advances in device technology and implantation techniques significantly reduce surgical risks, but about 10% of recipients continue to have complications related to device implantation.<sup>2</sup> Some of these complications necessitate complete system extraction of the leads and generator. Even among very experienced operators in high-volume centers, the risks associated with lead extraction can exceed 5%.<sup>3</sup>

In our case, the CVC might have been damaged or kinked during its insertion, rendering it susceptible to fracture from friction and traction along its length as the extraction tools were inserted over the adjacent pacing leads during the extraction process. Alternatively, the CVC might have been



**Figure 1** Chest radiograph depicting a peripherally inserted central venous catheter (white arrow) through the left brachial vein.



**Figure 2** Chest radiograph depicting the fractured peripherally inserted central venous catheter following lead extraction (white arrows identify the fractured catheter with the distal now embedded deep into the right atrium). Also visible in this radiograph is a new temporary pacing lead that was inserted via direct axillary venous puncture access in a location outside and above the infected pacemaker pocket; the temporary pacing lead was connected to the now-externalized old pacemaker generator that was secured to the skin outside of the infected pacemaker pocket. This temporary pacing lead was necessary for the duration of antibiotic therapy prior to the new system implant because the patient was pacemaker dependent; it was placed on the same side as the infection to avoid vascular injury and localized infection in the contralateral venous access site where the new permanent pacemaker system will be implanted when the infection resolves.

fractured with direct damage from the tip of the laser sheath or Evolution mechanical sheath, especially in scarred venous segments of limited luminal space. Mechanical extraction tools such as the Evolution power sheath need to be employed with caution because they are known to cause wrapping and cutting of adjacent structures. It is very unlikely that the CVC fracture was not directly related to the extraction process, especially considering that the site of fracture was near the venous insertion site of the extraction sheaths and that there was a close temporal relationship between the catheter embolization and the extraction procedure.

Over 200 cases of CVC fracture and embolization not related to the lead extraction process have been reported previously.<sup>4,5</sup> The most common etiology in most cases was the pinch-off syndrome followed by catheter injury during explantation, catheter disconnection, and catheter rupture;<sup>4</sup> a clear etiology could not be identified in almost 20% of cases. Most embolized catheter fragments can be removed percutaneously with a gooseneck-type snare, as was the case for our patient. However, depending on the location of catheter embolization and patient comorbidities, a small proportion of catheters can only be removed surgically via a thoracotomy. In some cases, the catheter may even be

abandoned in the vascular bed especially if the risks associated with an invasive extraction outweigh those of intravascular catheter retention.<sup>4</sup>

The diagnosis of CVC fracture and embolism may be elusive and remains incidental in up to 50% of cases.<sup>6</sup> Evidence of CVC malfunction may prompt radiographic imaging that results in the incidental identification of fracture and embolism.<sup>7</sup> Because it remains unclear which patients are likely to suffer significant complications from a fractured CVC, a prompt attempt at complete removal should be considered in all cases.

In our case, the infected device was previously implanted in the left pectoral region. The CVC was inserted in the ipsilateral venous system via the left brachial vein to avoid local infection and compromise of venous patency in the right-sided pectoral region, which was reserved for subsequent pacemaker insertion. Our preference is to implant the new device in the contralateral pectoral region to minimize the risk of a repeat device infection in the event that the initial local infection is not completely resolved. Axillary as opposed to subclavian venous access is preferred in the insertion of the CVC to avoid the “subclavian crush” syndrome whereby material fatigue due to pressure between the clavicle and first rib may lead to catheter fracture.<sup>8,9</sup> In retrospect, damage to the CVC during the extraction process highlights the importance of careful functional and radiographic evaluation of CVC integrity immediately post extraction.

## Conclusion

Percutaneous lead extraction may be associated with significant complications even among very experienced operators. Careful risk and benefit analysis is warranted for every patient, to ensure lead extraction is appropriate and most ideal for a given clinical scenario. In patients with a

peripherally inserted CVC coursing ipsilaterally to the device lead being extracted, careful intra- and postoperative fluoroscopic evaluation of the venous catheter integrity is essential following the use of mechanical extraction sheaths and tools to rule out any catheter damage and compromise.

## Consent

Written informed consent was obtained from the patient for publication of this case report and any accompanying images. A copy of the written consent is available for review by the Editor-in-Chief of this journal.

## References

1. Parkash R, Philippon F, Thibault B, et al. Canadian Cardiovascular Society guidelines on the use of cardiac resynchronization therapy: implementation. *Can J Cardiol* 2013;29(11):1346–1360.
2. Kirkfeldt RE, Johansen JB, Nohr EA, Jørgensen OD, Nielsen JC. Complications after cardiac implantable electronic device implantations: an analysis of a complete, nationwide cohort in Denmark. *Eur Heart J* 2014;35(18):1186–1194.
3. Brunner MP, Cronin EM, Duarte VE, et al. Clinical predictors of adverse patient outcomes in an experience of more than 5000 chronic endovascular pacemaker and defibrillator lead extractions. *Heart Rhythm* 2014;11(5):799–805.
4. Surov A, Wienke A, Carter JM, Stoevesandt D, Behrmann C, Spielmann RP, Werdan K, Buerke M. Intravascular embolization of venous catheter—causes, clinical signs, and management: a systematic review. *JPEN J Parenter Enteral Nutr* 2009;33(6):677–685.
5. van der Hem KG, Meijer S, Werter CJ, van Groeningen CJ. “Spontaneous” catheter fracture and embolization of a totally implanted venous access port. *Neth J Med* 1991;38(5–6):262–264.
6. Surov A, Buerke M, John E, Kosling S, Spielmann RP, Behrmann C. Intravenous port catheter embolization: mechanisms, clinical features, and management. *Angiology* 2008;59(1):90–97.
7. Surov A, Jordan K, Buerke M, Persing M, Wollschlaeger B, Behrmann C. Atypical pulmonary embolism of port catheter fragments in oncology patients. *Support Care Cancer* 2006;14(5):479–483.
8. Krause U, Doetsch N, Meusers P, Kock HJ. [Catheter break in an implantable central venous infusion system with embolization in the pulmonary artery]. *Dtsch Med Wochenschr* 1989;114(48):1882–1884.
9. Noyen J, Hoorntje J, de Langen Z, Leemslag JW, Sleijfer D. Spontaneous fracture of the catheter of a totally implantable venous access port: case report of a rare complication. *J Clin Oncol* 1987;5(8):1295–1299.