



Contents lists available at ScienceDirect

International Journal of Surgery Case Reports

journal homepage: www.casereports.com

Breast sarcoma. A case report and review of literature



Nuria Li*, Maria Teresa Cusidó, Beatriz Navarro, Francesc Tresserra, Sonia Baulies, Carmen Ara, Rafael Fabregas

Hospital Universitario Quirón Dexeus, Department of Gynaecology, Obstetrics and Reproductive Medicine, Salud de la Mujer Dexeus, Gran Via Carles III, 71-75, 08028 Barcelona, Spain

ARTICLE INFO

Article history:

Received 12 February 2016
Received in revised form 17 April 2016
Accepted 17 April 2016
Available online 6 May 2016

Keywords:

Breast sarcoma
Breast cancer
Mastectomy
Radiation therapy
Chronic lymphedema
Case report

ABSTRACT

INTRODUCTION: Breast sarcomas are rare with an annual incidence of 4.6 cases/1,000,000 women. They can appear as primary forms or secondary to radiation therapy or chronic lymphedema.

PRESENTATION OF CASE: A 41 year old woman attended our hospital after having noticed an increase in the size of her fibroadenoma. The examination revealed a 7 cm retroareolar nodule. Breast sonography described a hypoechoic bilobulated lesion and MRI showed a large size polinodular image, suggesting a Phyllodes tumor. A core needle biopsy was performed with a histological result of low-grade fusiform cells sarcoma on Phyllodes tumor so we proceeded to surgical treatment with a mastectomy.

After two years and a half she noticed a tough nodule over the mastectomy scar, which was resected with a histological result of fusiform cells sarcoma. Considering the diagnosis of recurrence of the disease, surgery was undertaken.

DISCUSSION: Breast sarcoma is a rare but aggressive entity. Core biopsy is the procedure of choice for the diagnosis. Lymphatic spread is uncommon so nodal status in breast sarcoma is less informative. Staging study differs from other breast tumors and chest computed tomography is helpful since lungs are the predominant metastatic sites. The use of radiotherapy or chemotherapy is controversial and will depend on the risk of tumor recurrence.

CONCLUSION: Surgery represents the only potentially curative therapy for breast sarcoma. Tumor size and adequate resection margin are the most important prognostic factors. Approximately 80% of recurrences appear in the first two years.

© 2016 Published by Elsevier Ltd on behalf of IJS Publishing Group Ltd. This is an open access article under the CC BY-NC-ND license (<http://creativecommons.org/licenses/by-nc-nd/4.0/>).

1. Introduction

Breast sarcomas, which develop from mesenchymal tissue, are rare and their annual incidence is approximately 4.6 cases/1,000,000 women, representing less than 1% of all breast malignancies. They can appear as primary forms (*de novo*) or secondary to chronic lymphedema or radiation therapy on the breast or chest wall, with the two forms presenting different features. The primary forms appear histologically as heterogenous subtypes and their mean age of diagnosis is around 40 years. In contrast, the secondary forms typically present later at around 45–50 years and the most common histological subtype is angiosarcoma.

Lymph node metastases are uncommon in breast sarcomas and surgery represents the only potentially curative therapy, always with an adequate resection margin.

They can share some clinical features with breast carcinomas but therapy and prognosis can differ substantially.

We present this case because of the low incidence of breast sarcomas with few cases being reported, especially of primary forms, and the clinical imagery obtained.

2. Presentation of case

A 41 year old woman, who had been diagnosed previously with a fibroadenoma on the left breast, attended our hospital after having noticed an increase in its size. Her personal history did not feature other important details. The examination revealed a 7 cm retroareolar nodule, well-defined and tough. Breast ultrasound described the previously known fibroadenoma and a hypoechoic bilobulated lesion with thick margins (Fig. 1) and the result of the cytology we obtained by fine needle aspiration was connective-adipose tissue. The MRI showed a large size polinodular image, without signs of necrosis or haemorrhage, suggesting a possible Phyllodes tumor (Fig. 2). The images revealed a low diffusion and a rapid contrast-enhancement with a posterior plateau. We decided to perform a core needle biopsy with a histological result of low-grade fusiform cells sarcoma on Phyllodes tumor. As a consequence of

* Corresponding author.

E-mail addresses: nurlia@dexeus.com (N. Li), maicus@dexeus.com (M.T. Cusidó), beanav@dexeus.com (B. Navarro), fratre@dexeus.com (F. Tresserra), sonbau@dexeus.com (S. Baulies), carara@dexeus.com (C. Ara), raffab@dexeus.com (R. Fabregas).

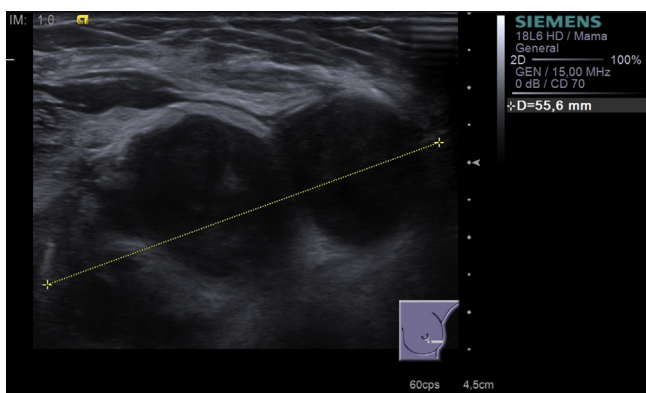


Fig. 1. A 55 mm hypoechoic bilobulated lesion with thick margin.

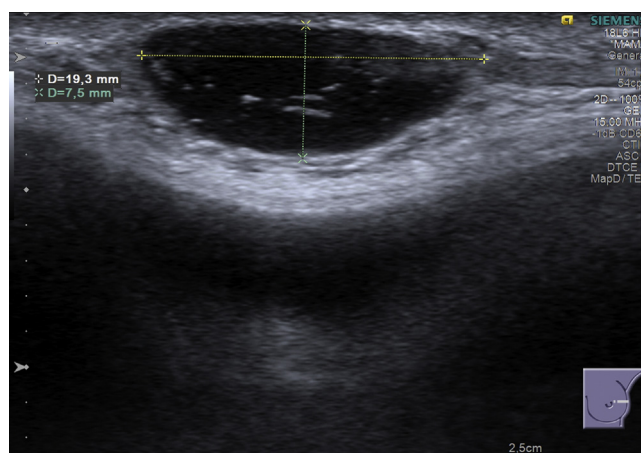


Fig. 4. Recurrence.

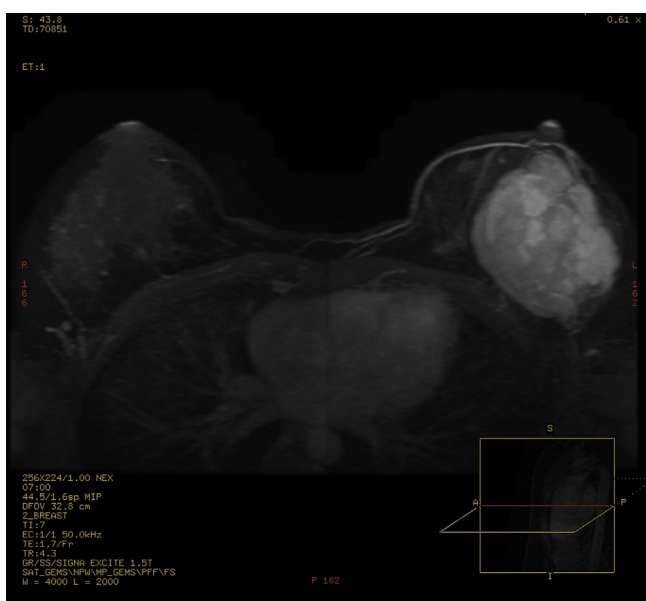

Fig. 2. MRI.

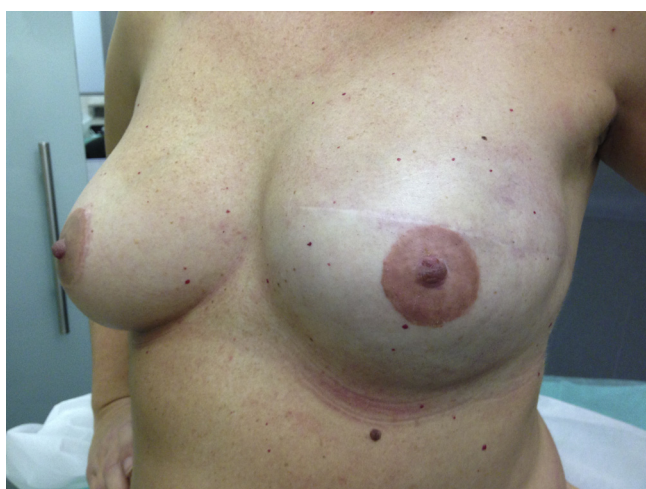

Fig. 3. Reconstruction.

After two and a half years of close monitoring, she came again to our hospital because of a tough nodule over the mastectomy scar and the breast ultrasound revealed a heterogeneous epidermic nodule of 19 mm (Fig. 4). It was resected and the histological result showed fusiform cell sarcoma. Considering the diagnosis of recurrence of the disease, surgical treatment was performed with an enlargement of tumor margins, resecting the pectoral muscle and removing the prosthesis.

3. Discussion

Breast sarcoma is a rare but aggressive entity. Due to its rarity, there have not been sufficient studies of its clinicopathological features and adequate treatment approach to achieve a consensus in terms of management of the disease, with published articles usually being small retrospective case reports and reviews.

In most cases, the etiology is unknown and although women who receive radiotherapy have an increased risk of presenting secondary breast sarcoma, the absolute incidence is small.

Clinically it appears as a unilateral, well-defined and large mass; it often grows faster than epithelial breast carcinoma. It can be suspected with a physical examination or through imaging tools, but core biopsy is required for diagnosis [1].

With regard to imaging, either breast ultrasound, mammography or MRI can be useful. The feature usually found in the imagery is the presence of a mass with irregular margins with or without calcifications. It appears to be frequently hypoechoic at ultrasound and T2 hyperintense at MRI [2,3].

Lymphatic spread is uncommon in this entity, and dissemination usually occurs haematogenously and the principal organs to be metastasized are lungs, bones and liver. This is why sentinel lymph node biopsy has not been studied in these cases, as it does not seem to offer sufficient benefit to the patient or to prompt a change in clinical management. Consequently, this means that staging studies will differ from other breast tumors due to the fact that nodal status in breast sarcoma is less informative, so in these cases chest computed tomography is helpful for staging since lungs are the predominant metastatic sites.

Surgery is the standard treatment. Tumor size and adequate resection margin are the most important prognostic factors; in fact, an adequate resection margin is the most important determinant of long-term survival. Rutinary lymphadenectomy does not seem to improve outcomes [4,5].

There is some controversy about the use of radiotherapy or chemotherapy in these patients, so there is no consensus as to the use of adjuvant therapy and it will depend mainly on the risk of tumor recurrence. Taking this into account, the use of radiotherapy

these results, we made a staging study on the disease extent by a thoracic and abdominal scanner without signs of disease spread, so we proceeded to surgical treatment with a mastectomy of the left breast and posterior reconstruction with prosthesis (Fig. 3).

seems to be recommended after positive margin resection due to the high risk of recurrence and those cases in which a R0 resection is achieved but tumors are larger than 5 cm or there is a high grade sarcoma. Prior to radiotherapy, chemotherapy is based on the Doxorubicin and Ifosfamide scheme, however there is no evidence supporting their use as response rates of breast sarcoma seem to be limited [1,4]. A close follow-up is recommendable during the first two years because approximately 80% of recurrences appear in this period.

In the present case, the initial surgery involving mastectomy and achieving negative resection margins (R0) in a low grade tumor led us to dismiss other adjuvant treatment because of the aforementioned controversy about these therapies. However, once the diagnosis of local recurrence of the disease was confirmed, we recommended completing the surgical treatment with an enlargement of tumor margins and undergoing postoperative radiation therapy despite there being little evidence confirming the latter's effectiveness in improving global survival rates.

4. Conclusion

Breast sarcoma is a rare but aggressive entity and core biopsy is required for diagnosis. Unlike with epithelial breast carcinoma, lymphatic spread is uncommon and staging studies differ from other breast tumors due to the fact that nodal status in breast sarcoma is less informative. Consequently chest computed tomography is helpful since lungs are the predominant metastatic sites. Surgery represents the only potentially curative therapy in these cases, and tumor size and adequate resection margin are the most important prognostic factors. Some controversy still exists about the use of radiotherapy or chemotherapy, which is why currently the use of adjuvant therapy is usually limited to cases with high risk of recurrence due to positive margin resection, tumors larger than 5 cm or a high grade sarcoma. A close follow-up is recommendable during the first two years, when approximately 80% of recurrences appear.

Conflicts of interest

There are no conflicts of interest.

Funding

There are no sources of funding.

Ethical approval

It is not a research study, it is a case report so it has not been required any ethic committee.

Consent

The patient provided written permission for publication of this case report.

Author contribution

Nuria Li: Writing the paper.

Maria Teresa Cusidó: Writing and reviewing the paper. Follow up the patient.

Beatriz Navarro: Interpretation and selection of radiological images.

Francesc Tresserra: Interpretation of the anatomical pathology result.

Sonia Baulies: Others.

Carmen Ara: Others.

Rafael Fabregas: Reviewing the paper.

Guarantor

Maria Teresa Cusidó.

References

- [1] S. Al-Benna, K. Poggemann, H.U. Steinau, L. Steintraesser, Diagnosis and management of primary breast sarcoma, *Breast Cancer Res. Treat.* 122 (August (3)) (2010) 619–626, <http://dx.doi.org/10.1007/s10549-010-0915-y>.
- [2] T.B. Smith, M.Z. Gilcrease, L. Santiago, K.K. Hunt, W.T. Yang, Imaging features of primary breast sarcoma, *AJR Am. J. Roentgenol.* 198 (April (4)) (2012) W386–393, <http://dx.doi.org/10.2214/AJR.11.7341>.
- [3] A. Surov, H.J. Holzhausen, K. Ruschke, R.P. Spielmann, Primary breast sarcoma: prevalence, clinical signs, and radiological features, *Acta Radiol.* 52 (July (6)) (2011) 597–601, <http://dx.doi.org/10.1258/ar.2011.100468>.
- [4] E. Nizri, O. Merimsky, G. Lahat, Optimal management of sarcomas of the breast: an update, *Expert Rev. Anticancer Ther.* 14 (June (6)) (2014) 705–710, <http://dx.doi.org/10.1586/14737140.2014.895667>.
- [5] T. Pencavel, C.P. Allan, J.M. Thomas, A.J. Hayes, Treatment for breast sarcoma: a large, single-centre series, *Eur. J. Surg. Oncol.* 37 (August (8)) (2011) 703–708, <http://dx.doi.org/10.1016/j.ejso.2011.04.006>.

Open Access

This article is published Open Access at sciedirect.com. It is distributed under the [IJSCR Supplemental terms and conditions](#), which permits unrestricted non commercial use, distribution, and reproduction in any medium, provided the original authors and source are credited.