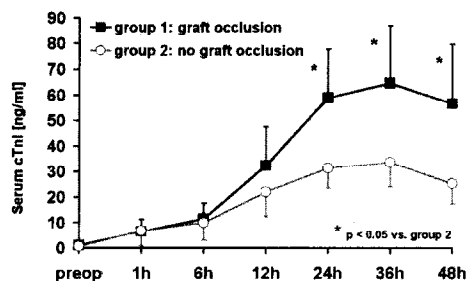


graft occlusion following CABG. All patients with early graft occlusion showed postoperative cTnI levels above 30 ng/ml at 24, 36, and 48 hours. In contrast, if cTnI levels were below 30 ng/ml early graft occlusion was unlikely.



1182-26

Myocardial Tissue Replacement With Extracellular Matrix Scaffolds

Keith A. Robinson, Robert G. Matheny, American Cardiovascular Research Institute, Norcross, GA, Cardiac Surgical Associates, Atlanta, GA

Background Heart failure from MI is a major health problem. Recent evidence suggests myocardial repair and recovery of LV function might be possible through tissue engineering such as autologous skeletal myoblast transplant. An alternative strategy is repair of infarcted regions with acellular biological matrix scaffolds. **Methods** We implanted porcine urinary bladder extracellular matrix scaffolds (UBM) as full-thickness RV outflow tract replacement patches in 4 pigs and 1 dog; 1 pig received glutaraldehyde-treated pericardium as control. At 6 wk gross and microscopic structure was studied; immunohistochemistry was performed to assess cellular recruitment. **Results** No postoperative signs of cardiac insufficiency were seen. Implant sites were pearly white at the epicardial aspect. Endocardial surfaces of UBM showed pearly white tissue interdigitated with abundant brown-colored tissue whereas GP showed mostly pearly white with sparse brown tissue. GP was a discrete foreign body in a fibrotic capsule with extensive inflammation including many giant cells. UBM was undiscernible and the site was mixed tissue including myocardium, fibrosis, and extensive neovascularization. UBM immunohistochemistry showed myeloid cells at the endocardial aspect. Cells expressing muscle actin, with two morphologies were seen in UBM sites: stellate/spindle-shaped resembling myofibroblasts, and striated cells resembling cardiomyocytes. Neovascularization with vWf- and smooth muscle actin-positive cells was abundant. Extensive replication was evident by PCNA immunostaining. The endocardium was vWf-positive endothelial cells. **Conclusions** UBM implants were incorporated into RV free wall by a tissue replacement process involving recruitment of circulating cells as well as appearance of muscle cells that may derive from adjacent myocardium. In contrast, GP was incorporated into a fibrotic capsule without a replacement process. Further research into potential utility of UBM for myocardial tissue repair and mechanisms of the replacement process is warranted.

POSTER SESSION

1204 Cardiac Surgical Research

Tuesday, April 01, 2003, 3:00 p.m.-5:00 p.m.
McCormick Place, Hall A
Presentation Hour: 3:00 p.m.-4:00 p.m.

1204-21

The Effect of Left Ventricular Surgical Remodeling on Three-Dimensional Myocyte Orientation Using Magnetic Resonance Diffusion Tensor Imaging

Joseph C. Walker, Julius M. Guccione, Edward W. Hsu, Jeremy R. Beitter, Peng Zhang, Mark B. Ratcliffe, University of California Berkeley/San Francisco Joint Bioengineering Graduate Group, San Francisco, CA, Duke University, Durham, NC

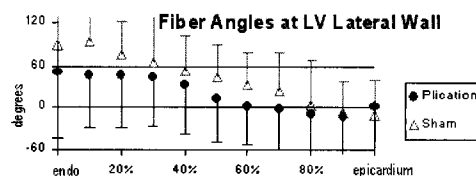
Background: It has been suggested that a beneficial left ventricle (LV) surgical remodeling should result in distributions of myocyte orientations comparable to healthy hearts. A new magnetic resonance (MR) imaging technique, MR Diffusion Tensor Imaging (MR-DTI), can quantify the fibrous LV architecture. Recently, validation with standard histology showed that MR-DTI can accurately reveal myocyte fiber angles in the heart. Using MR-DTI, the present study tested the hypothesis that LV surgical remodeling favorably corrects three-dimensional myocyte orientation.

Methods: Thirteen sheep underwent antero-apical myocardial infarction (25% of LV mass). Ten weeks later animals underwent either aneurysm plication (n = 8) or sham operations (n = 5). Six weeks after that, these hearts were perfusion-fixed in diastole and underwent MR-DTI. The vectors from MR-DTI were resolved into two components: tangent and normal to the epicardial surface. Transmural distributions of these two components were compared at the anterior and lateral LV walls 50% from base to apex.

Results: No significant differences were found between plicated and sham-operated

hearts in either component of the myocyte orientation. This was true in both the anterior and lateral LV walls (see figure; error bars indicate one circular standard deviation).

Conclusion: Our measurements suggest that LV surgical remodeling does not significantly affect myocyte orientation. However, this data will be valuable in mathematical models of the LV.



1204-22

Warm Blood Cardioplegia Induces Mitochondria-Initiated Myocyte Apoptosis Which Is Ameliorated by Overexpression of Endogenous Urocortin

Tiziano M. Scarabelli, Evasio Pasini, Gianna Ferrari, Mario Ferrari, Anastasis Stephanou, Paul Townsend, Kevin Lawrence, Carol Chen-Scarabelli, Richard Knight, David Latchman, Institute of Child Health, University College London, London, United Kingdom, Jackson Memorial Hospital, University of Miami, Miami, FL

Background. Previous reports showed that both crystalloid and cold blood cardioplegia induce functional and ultrastructural changes in myocytes (CM) and the coronary circulation. No data is instead available about warm blood cardioplegia (WBC), which nowadays seems to be the most effective technique of intraoperative myocardial protection. Here we evaluated in the human heart exposed to WBC the occurrence of apoptosis, the relative contribution of its signalling pathways and the potential involvement of the endogenous cardiac peptide urocortin (Ucn) as a salvage mechanism. **Methods.** 24 patients undergoing on-pump CABG surgery were classified into group A and B receiving 40-55 mins and 85-100 mins of cardioplegic arrest respectively. Two sequential biopsies were obtained from the right atrium at the start of CABG and 10 minutes after the release of the aortic cross-clamp. **Results and conclusions.** Our study shows for the first time that WBC induces CM apoptosis, identified as immunocytochemical colocalisation between TUNEL and caspase-3 positive staining. The proportion of TUNEL positive CM (<0.1% in control hearts) became 3.3±0.5% in group A, and further increased in group B (5.1±0.9%), exposed to a longer WBC (p<0.001). Processing of caspase-9 (C9) was more pronounced than that of caspase-8 both in group A and group B, providing evidence that this CM apoptosis is mainly sustained by the mitochondrial C9-mediated pathway. WBC induced also Ucn expression (17±2.3% and 29±3.5% in group A and B respectively. Control hearts: <3%; p<0.001) only in those CM, which were not apoptotic, suggesting that Ucn can effectively protect those CM in which it is produced. This is, to our knowledge, the first report showing apparent protection by Ucn at an individual cellular level. We finally observed that Ucn positive, TUNEL negative CM were surrounded by a cuff of Ucn negative, TUNEL negative cells, which gives indirect substantiation of the paracrine Ucn-induced cardioprotection. We conclude that WBC causes CM apoptosis but also induction of Ucn which ameliorates the CM damage associated with on-pump cardiac surgery.

1204-23

Up to Two Years' Performance Using a Tissue Engineered Pulmonary Graft During the Ross Procedure

Pascal M. Dohmen, Alexander Lembcke, Simon Dushe, Holge Hotz, Wolfgang Konertz, Charité Hospital, Humboldt University, Berlin, Germany

Background: This study was performed to collect prospective safety and effectiveness data of tissue engineered (TE) heart valves for reconstruction of the right ventricular outflow tract (RVOT) during Ross procedure. **Methods:** Since April 2000, eleven patients received TE heart valves for RVOT reconstruction. Four weeks before the valve replacement, a piece of forearm or saphenous vein was harvested. At the tissue laboratory, autologous viable endothelial cells (AVEC) were harvested, isolated, characterized and expanded. After a sufficient number of AVEC were available, a decellularized pulmonary allograft was coated with basal membrane glycoproteins, and seeded in a bioreactor. Postoperatively patients were evaluated for quality of life, clinically and hemodynamic performance by echocardiography, magnetic resonance imaging and multi-slice tomography. **Results:** Patient mean age was 39.6 ± 10.3 years. The internal diameter of the TE heart valve was 26.7 ± 0.7mm. The mean seeding percentage was 89.9 ± 7.7% with a AVEC viability of 93.2 ± 2.1%. All patients were in NYHA classification I. Clinical evaluation showed no temperature above 37.5°C or leucocytosis. At echocardiographic evaluations the flow velocity was at discharge, 3, 6, 12 and 24 months respectively 0.77±0.20, 0.71±0.22, 0.59±0.07, 0.71±0.15 and 0.68±0.10. There was no TE heart valve regurgitation seen during follow up. Magnetic resonance imaging showed pliable, smoothly moving cusps. Multi-slice tomography showed the absence of calcification in the tissue engineered heart valve up to two years postoperatively. **Conclusions:** The short term follow up showed high quality of life, no evidence of immunological reactions, and excellent hemodynamic behavior of the TE heart valves without calcification or pattern of accelerated flow in the pulmonary artery up to two years of follow up.