

From the Western Vascular Society

Carbon dioxide digital subtraction angiography–assisted endovascular aortic aneurysm repair in the azotemic patient

Alex Chao, MD, Kevin Major, MD, Subramanyan Ram Kumar, MD, Kevin Patel, MD, Israel Trujillo, BS, Douglas B. Hood, MD, Vincent L. Rowe, MD, and Fred A. Weaver, MD, *Los Angeles, Calif*

Objective: This report analyzes the safety and efficacy of carbon dioxide digital subtraction angiography (CO₂-DSA) for EVAR in a group of patients with renal insufficiency compared with a concurrent group of patients with normal renal function undergoing EVAR with iodinated contrast angiography (ICA).

Methods: Between 2003 and 2005, 100 consecutive patients who underwent EVAR using ICA, CO₂-DSA, or both were retrospectively reviewed, and preoperative, intraoperative, postoperative, and follow-up variables were collected. Patients were divided into two groups depending on renal function and contrast used. Group I comprised patients with normal renal function in whom ICA was used exclusively, and group II patients had a serum creatinine ≥ 1.5 mg/dL, and CO₂-DSA was used preferentially and supplemented with ICA, when necessary. The two groups were compared for the outcomes of successful graft placement, renal function, endoleak type, and frequency, and the need for graft revision. Comparisons were made using χ^2 analysis, Student t test, and the Fisher exact test.

Results: A total of 84 EVARs were performed in group I and 16 in group II. Patient demographics and risk factors were similar between groups with the exception of serum creatinine, which was significantly increased in group II (1.8 mg/dL vs 1.0 mg/dL $P < .0005$). All 100 endografts were successfully implanted. Patients in group II had longer fluoroscopy times, longer operative times, and increased radiation exposure, and 13 of 16 patients required supplemental ICA. Mean iodinated contrast use was 27 mL for group II vs 148 mL in group I ($P < .0005$). Mean postoperative serum creatinine was unchanged from baseline, and 30-day morbidity was similar for both groups. No patient required dialysis. No patients died. Perioperatively, and at 1 and 6 months, the endoleak type and incidence and need for endograft revision was no different between groups.

Conclusions: CO₂-DSA is safe, can be used to guide EVAR, and provides outcomes similar to ICA-guided EVAR. CO₂-DSA protects renal function in the azotemic patient by lessening the need for iodinated contrast and associated nephrotoxicity, but with the tradeoff of longer fluoroscopy and operating room times and increased radiation exposure. (*J Vasc Surg* 2007;45:451-60.)

Endovascular aortic aneurysm repair (EVAR) has emerged as the treatment of choice for many patients with an abdominal aortic aneurysm (AAA). Recent prospective studies have documented that short-term morbidity and mortality are improved with EVAR compared with open repair.^{1,2} One potential limitation to the use of EVAR in the medically compromised patient, for whom EVAR is of particular advantage, is the existence of renal dysfunction (serum creatinine, ≥ 1.5 mg/dL). The need for significant volumes of nephrotoxic iodinated contrast for preoperative assessment and endograft placement may aggravate pre-existing renal dysfunction and accelerate the appearance of end-stage renal disease in selected patients. In addition, there is evidence to suggest that the nephrotoxic effects of

iodinated contrast on the renal parenchyma are not transient but rather permanent and cumulative.³

An alternative contrast approach for EVAR is the use of carbon dioxide (CO₂) and CO₂ digital subtraction angiography (CO₂-DSA), which was first described for diagnostic purposes by Hawkins.⁴ Although the use and value of CO₂-DSA in the diagnostic setting is well established,⁵ its safety and efficacy in guiding endovascular interventions and EVAR in particular has not been carefully studied or conclusively established.

We have extensive experience with CO₂-DSA.⁶⁻⁹ Since 2003, our group has used it as the preferential imaging technique for EVAR candidates who have pre-existing renal dysfunction. This report analyzes the safety and efficacy of CO₂-DSA for EVAR in a group of patients with renal insufficiency compared with a concurrent group of patients with normal renal function undergoing EVAR with iodinated contrast (ICA).

PATIENTS AND METHODS

This is a retrospective cohort study of 100 consecutive patients treated by EVAR at the University of Southern California University Hospital between 2003 and 2005. The chart of each patient was retrospectively reviewed and data recorded in an investigational database. The research

From the Department Surgery, Division of Vascular Surgery and Endovascular Therapy, Keck School of Medicine, University of Southern California.

Competition of interest: none.

Presented at the Twenty-First Annual Meeting of the Western Vascular Society, La Jolla, Calif, Sept 16-19, 2006.

Correspondence: Fred A Weaver, MD, MMM, Professor and Chief, Vascular Surgery and Endovascular Therapy, 1510 San Pablo St, Suite 514, Los Angeles, CA 90033 (e-mail: fweaver@surgery.usc.edu).

CME article

0741-5214/\$32.00

Copyright © 2007 by The Society for Vascular Surgery.

doi:10.1016/j.jvs.2006.11.017

protocol was reviewed and approved by the Institutional Review Board.

Among the preoperative variables recorded were demographics and risk factors (diabetes mellitus, hypertension, coronary artery disease, and tobacco use), body mass index, and serum creatinine concentration. Estimated glomerular filtration rate (eGFR) was calculated using the Cockcroft and Gault formula: $GFR = [(140 - \text{age}) \times \text{weight in kg}] / [72 \times \text{serum Cr in mg/dL}] \times f(P)$, where $f(P) = 1$ for males and 0.85 for females. EVAR intraoperative variables of graft type, fluoroscopy time, total radiation exposure (dose-area product), operative time, iodinated contrast volume, use of CO₂, use of gadolinium and volume, presence of endoleak, and type and number of graft extenders were recorded.

Postoperative variables included serum creatinine concentration and eGFR on postoperative day 1 and at discharge, intensive care unit stay, hospital length of stay, postoperative morbidity, and mortality. Results of postoperative endograft imaging by computed tomography (CT), ultrasonography, or both, and the need for endograft revision at 1 and 6 months were recorded.

For purposes of analysis, preoperative renal function was used to categorize patients into one of two groups. Group I patients had normal renal function as evidenced by a serum creatinine <1.5 mg/dL and the EVAR was performed exclusively with iodinated contrast (ISOVUE 300, Bracco Diagnostics, Princeton, NJ). Group II patients had chronic renal insufficiency as defined by a serum creatinine ≥ 1.5 mg/dL and the primary intravascular contrast agent was CO₂. When suboptimal imaging with CO₂-DSA occurred, CO₂-DSA was supplemented with gadolinium or iodinated contrast.

The primary end points of successful graft placement, renal function, and the need for graft revision were compared between the two groups. Other secondary end points for comparison included endoleak type and frequency and perioperative morbidity and mortality.

The technique of CO₂-DSA involves the following (Fig 1)^{6,7}: A sterile bag (Angioflush 3 fluid collection bag, Angiodynamics, Queensbury, NY) with attached tubing (Connecting tube, Boston Scientific, Natick, Mass) with a stopcock is inflated with CO₂. The bag is purged and inflated with CO₂ three times to eliminate the possibility of room air contamination. The attached stopcock is closed, the inflated bag disconnected, and then connected to tubing (Angioflush fluid management system tubing, Angiodynamics) with one-way valves and a sidearm. The end of the catheter contains a three-way stopcock and is connected to the intra-arterial injection catheter. The sidearm of the tubing is connected to a 60 mL Luer lock syringe. With the three-way stopcock open to air and closed to the injection catheter, the syringe is filled and purged at least three times to rid the syringe and tubing of room air. After the final filling, the stopcock is closed to air and open to the injection catheter, creating a closed CO₂ system.

Hand injection of 50 mL using digital subtraction imaging is used for angiography. Because CO₂ is rapidly

soluble in blood and disappears quickly, high frame rates of 3 to 6 frames per second are necessary. Stacking technology is used to combine frames and produce a single image for viewing, if necessary. Multiple injections in various imaging planes, rotation of the patient, or both, are sometimes necessary to demonstrate the relevant anatomy and to remove the vessel from overlying bowel gas or bone.

Indications for EVAR included patients with infrarenal AAA ≥ 5.0 cm with favorable endovascular anatomy. Imaging evaluation included spiral CT angiography (CTA) with axial and coronal reconstructions to evaluate anatomy. For group II patients, preoperative planning and postoperative endograft surveillance were done with a combination of imaging techniques that included noncontrast CT, aortic duplex imaging, and magnetic resonance imaging (MRI).

In all patients, hydration was initiated preoperatively, and group II patients received either pretreatment with *N*-acetylcysteine, intravenous bicarbonate, or a combination of the two. EVAR was performed with Ancure (Guidant, Indianapolis, Ind), Excluder (W.L. Gore & Assoc, Flagstaff, Ariz), AneurX (Medtronic, Sunrise, Fla), or Zenith (Cook, Bloomington, Ind) endografts. All cases were performed under general anesthesia in a dedicated operating suite with fixed angiographic equipment (Phillips Allua 2001, Bothell, Wa).

The EVAR procedure consisted of bilateral groin access and initial angiography for localization of the renal and hypogastric arteries and definitive sizing of graft length. The main body of the graft was deployed in the infrarenal position after one or two angiograms with magnified views were performed of the perirenal aorta. After deployment, placement of the contralateral limb, and the ipsilateral limb in cases of the Zenith graft, was completed by using angiograms for localization of the hypogastric arteries. A final angiogram was used to evaluate for endoleaks and final graft position. Additional angiographic runs were used if an endoleak was detected that required additional intervention or placement of additional graft extensions. All type I and III endoleaks were addressed. Detected type II endoleaks were observed.

Statistical comparison of preoperative, intraoperative, and postoperative variables for groups I and II was performed using χ^2 analysis for random ordinal variables, the Fisher exact test for nonrandom variables, and the Student two-tailed *t* test for comparison of continuous variables. A value of $P < .05$ was considered significant.

RESULTS

Between 2003 and 2005, 100 patients (84 in group I and 16 in group II) underwent EVAR. The average patient age was 76 years, and 67% were men. The groups had similar preoperative demographics and risk factors, although a trend was noted towards an increased incidence of coronary artery disease in group II (30% group I vs 60% group II, $P = .06$; Table I). Patients in group II had a mean preoperative serum creatinine of 1.8 mg/dL and eGFR of 36 mL/(min \cdot 1.73 m²) and group I patients had a mean creatinine of 1.0 mg/dL and eGFR of 81 mL/(min \cdot 1.73

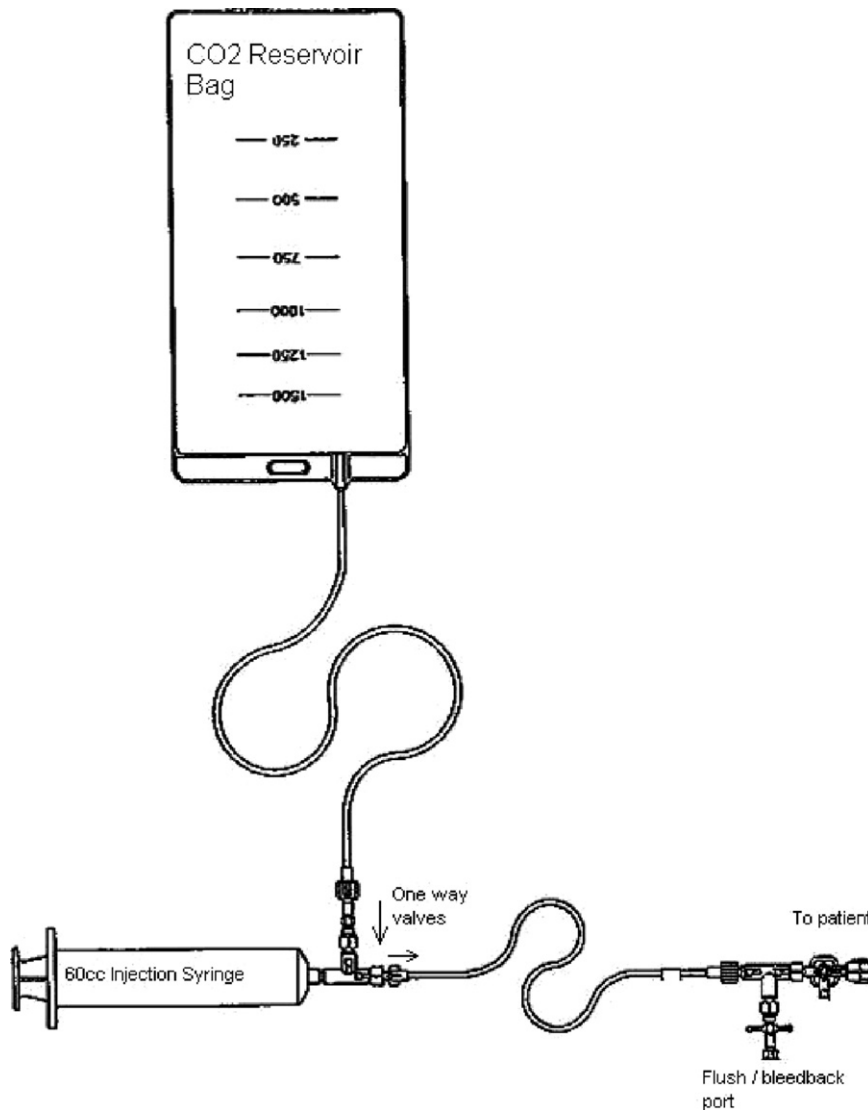


Fig 1. Line drawing shows carbon dioxide (CO_2) delivery system.

m^2). Table II tabulates the breakdown of eGFR in the two groups by the National Kidney Foundation classification for chronic kidney disease. No patient in either group was on dialysis.

Endografts placed included 8 Ancure, 2 Aneurx, 81 Excluder, and 9 Zenith. The amount of iodinated contrast necessary for endograft placement differed significantly at 148 mL in group I vs 27 mL in group II ($P \leq .005$). Thirteen (80%) patients in group II received either supplemental gadolinium (40 mL in a single patient) or iodinated contrast (mean volume, 23 mL in 12 patients). Operative time was shorter in group I (140 minutes vs 180 minutes, $P = .05$) as was fluoroscopy time (24 minutes vs 46 minutes, $P = .01$). Total radiation exposure was lower in group I at 529 Gy/cm² vs group II at 925 Gy/cm² ($P = .04$). There was no difference in the other intraoperative variables examined (Table III).

A total of 66 intraoperative endoleaks were detected in 56 patients: Ia in 28, Ib in 6, II in 31, and III in 1. All but two type I endoleaks were successfully managed intraoperatively by either redo balloon angioplasty at the attachment site or placement of additional components. There was no significant difference between groups in the total or types of endoleaks detected (Table IV). When used in group II, the use of supplemental iodinated or gadolinium contrast angiograms did not demonstrate endoleaks not previously seen with CO_2 -DSA.

Overall mean postoperative serum creatinine and eGFR were unchanged from preoperative levels in both groups both on postoperative day 1 and at discharge. One patient in group 2 had a significant increase (>20%) in serum creatinine. This patient received 40 mLs of gadolinium, but no iodinated contrast. The serum creatinine level increased from a preoperative value of 2.2 to 3.0 mg/dL on the first

Table I. Preoperative variables

Characteristic*	Group I n = 84 (%)	Group II n = 16 (%)	P
Male (n)	69 (82)	15 (94)	NS
Age (years)	76 (54-93)	77 (59-89)	NS
CAD	25 (30)	10 (60)	NS
Hypertension	50 (60)	11 (70)	NS
Tobacco use	67 (80)	13 (80)	NS
COPD	8 (10)	3 (20)	NS
Diabetes mellitus	10 (12%)	3 (20%)	NS
Aneurysm size (cm)	5.8 (4.5-7.5)	6.4 (4.7-11)	NS
Serum creatinine	1.0 (0.5-1.6) [†]	1.8 (1.5-3.2)	<.05
Estimated GFR	81 (22-167)	36 (15-63)	<.05

CAD, Coronary artery disease; COPD, chronic obstructive pulmonary disease; GFR, glomerular filtration rate.

*Categoric data are presented with percentages; continuous variables are presented as means (range).

[†]One patient had an admission creatinine of 1.6 mg/dL, all prior <1.5 so the procedure was done with iodinated contrast only and included in group I.

Table II. Chronic kidney disease stage for patients in groups I and II

GFR	CKD stage*	Group I n = 84 (%)	Group II n = 16 (%)
90	1	29 (35)	1 (6)
60-89	2	27 (32)	1 (6)
30-59	3	25 (30)	10 (63)
15-29	4	3 (4)	4 (25)
<15	5	0	0

GFR, glomerular filtration rate; CKD, chronic kidney disease.

*Stages CKD as defined by the National Kidney Foundation (www.kidney.org).

Table III. Intraoperative variables

Characteristic*	Group I (n = 84)	Group II (n = 16)	P
Iodinated contrast dose (mL)	148 ± 20	27 ± 5	<.005
Fluoroscopy time (min)	24 ± 1.5	46 ± 7	.01
Total radiation (Gy/cm ²)	529 ± 44	925 ± 138	.04
Endoleak detected	43 (51%)	10 (63%)	NS
Operative time (hours)	2.3 ± 0.2	3.0 ± 0.3	.05
Graft extenders	0.4 ± 0.05	0.5 ± 0.13	NS
Hypogastric embolization	0.18 ± 0.04	0.38 ± 0.11	NS

*Continuous variables are expressed as mean ± standard error of the mean.

postoperative day, but returned to the preoperative baseline by discharge. Serum creatinine values recorded in this patient 3 months before EVAR were from 2.2 to 3.5 mg/dL. No patient in either group required dialysis postoperatively or during follow-up.

Group I and group II were not significantly different in mean hospital length of stay (2.0 vs 3.9 days), mean length of intensive care unit stay (0.64 vs 0.86 days), and postoperative morbidity (6% vs 12%). Specific postoperative complications in group I were one patient each with unplanned

Table IV. Intraoperative endoleaks by specific type

Type	Group I*	Group II [†]	OR (95% CI)	P
Type Ia	24 (29%)	4 (25%)	1.2 (0.4-4.1)	NS
Type Ib	4 (5%)	2 (13%)	0.4 (0.1-2.1)	NS
Type II	26 (31%)	6 (24%)	0.7 (0.2-2.3)	NS
Type III	1 (1.2%)	0 (0%)	N/A	NS

OR, Odds ratio; CI, confidence interval; N/A, not applicable.

*Group 1: 53 endoleaks detected in 43 patients.

[†]Group 2: 12 endoleaks detected in 10 patients.

Table V. Postoperative variables

Characteristic	Group I	Group II	P
LOS	2 ± 0.2	3.9 ± 1	NS
ICU LOS	0.9 ± 0.1	.64 ± 0.3	NS
Post-op creatinine (mg/dL)	0.9 ± 0.03	1.8 ± 0.14	<.0002
Creatinine change (mg/dL)*	-0.06 ± 0.02	0.01 ± 0.07	NS
Morbidity	6%	12%	NS
Mortality	0	0	NS

LOS, Length of stay; ICU, intensive care unit stay length.

*Creatinine change is difference between admission and discharge serum creatinine level.

hypogastric artery coverage, myocardial infarction, urinary retention, femoral arterial-venous fistula, and retroperitoneal bleed requiring transfusion; and in group 2, one patient each with iliac artery dissection, paraplegia, and femoral pseudoaneurysm. No deaths occurred in either group (Table V).

At 1 month postoperatively, the incidence of endoleaks detected by imaging was 13% in group I vs 18% in group II ($P = NS$). Five type II endoleaks (four in group I and one in group II) not seen intraoperatively were detected at 1 month. Endoleak incidence was unchanged on 6-month endograft imaging studies (group I, 10% vs group II, 18%; $P = NS$). Diagnostic angiograms for possible type I endoleaks that were determined to be type II endoleaks were performed in two group I patients. No remedial procedures were required in either cohort at 6 months.

DISCUSSION

Pre-existing chronic kidney disease occurs in approximately 7% to 25% of patients undergoing EVAR.^{10,11} The reported incidence of acute renal failure after EVAR varies owing to differences in reporting standards but is between 2% and 16%, and recent studies confirm an associated mortality of 30% to 50%.^{3,12,13} Although pre-existing renal insufficiency carries the highest risk of post-EVAR renal failure, patients with normal preoperative serum creatinine values are not immune, and in a standard-risk group showed a 2.5% incidence of renal dysfunction when defined as a serum creatinine increase of 30%. Notably, when followed out to 1 year, the incidence of renal dysfunction increased to 16% in this same cohort.³

Part of the explanation for this observation in standard-risk patients, particularly those in the geriatric age group who have diminished muscle mass because of aging, is that the serum creatinine level can be a very inaccurate indicator of overall renal function. Our observation that a mean serum creatinine of <2 mg/dL was associated with a critically reduced mean eGFR of $36 \text{ mL}/(\text{min} \cdot 1.73 \text{ m}^2)$ supports this explanation and argues that any reported clinical assessment of renal function should, at the very least, be indexed by body mass.

From open surgical data, it has been reported that patients with pre-existing renal dysfunction have a disproportionately high risk of perioperative morbidity (30% vs 13%) and acute renal failure.¹⁴ Whether EVAR might lessen the morbidity and incidence of renal decompensation in this particular patient population is unknown. Greenberg et al³ analyzed 279 patients undergoing open and EVAR with suprarenal fixation and saw an early renal benefit in renal function in the endovascular group. When the open group who required suprarenal cross-clamping was eliminated, however, the incidence of acute renal failure was equivalent.

Acute renal decompensation after endovascular or open repair has a number of causes.^{15,16} Common reasons attributed to open surgery are renal or suprarenal cross-clamping, blood loss, hypotension, ischemia-reperfusion injury, and manipulation of thrombus, with renal parenchyma microembolization leading to activation of vasoactive components, endothelial damage, and cytokine release. Although many of these same factors can occur with EVAR, endovascular aortic procedures add the additional renal insult of iodinated contrast. With both intraoperative placement and postoperative surveillance by CT of aortic endografts contrast, the cumulative dose of nephrotoxic contrast becomes significant over time. Greenberg et al³ have stated that this repetitive use of iodinated contrast and the nephrotoxic insult incurred may be responsible for the observed deterioration in renal function after endograft replacement.

Previous studies have documented the risks of renal failure after diagnostic ICA. Moore reported an 11% rate of acute renal failure in 400 patients who underwent aortography. In the group with pre-existing renal dysfunction, acute renal decompensation developed in 42%, and 8% required dialysis.¹⁷ In a series of 164 patients undergoing EVAR, Walker et al¹³ documented a mortality of 47% in the 15 patients with preoperative renal impairment and 2.7% in those with normal renal function. More recent reports suggest that acute renal decompensation after diagnostic angiography is currently less common owing to a more judicious use of iodinated contrast as well as a combination of strategies aimed at reducing the risk of post contrast nephropathy.

These proposed strategies include the use *N*-acetylcysteine (Mucomyst, Roberts Pharmaceuticals, Eatontown, NJ), dilution of iodinated contrast, intravenous bicarbonate infusions, mannitol, fenoldopam, robust preprocedure and postprocedure hydration, and in selected circumstance, the

use of gadolinium. We have found all these modalities empirically useful in selected patients but each with intrinsic limitations. For example, the contrast agent gadolinium appears to be a simple and reasonable alternative to iodinated contrast. In practice, however, the recommended dosage of 0.3 to 0.4 mmol/kg calculates to only 30 mL, and when doubled to its maximum, allows for only 60 mL. Although adequate for MRI, this dose is inadequate as a stand-alone agent for EVAR. In addition, those who have tried dilute gadolinium have been disappointed with its attenuating ability.¹⁸ Other limitations include hyperosmolarity and cost, and recent reports suggest that gadolinium may be nephrotoxic as well.¹⁹⁻²¹ This may have been the cause of the transient rise in serum creatinine in one patient who underwent CO₂-DSA supplemented only with gadolinium.

Several groups have reported CO₂-DSA to be safe and useful.⁵⁻⁹ Its mechanism is the transient displacement of arterial blood, providing a contrast image. Because of its buoyancy, visualization of dependent vasculature may be limited. Operators have circumvented this shortcoming by changing the patient position to place the area of interest in a nondependent position. In an experience with >800 cases of CO₂-DSA, we have found these maneuvers to be rarely necessary. In most cases, simple repositioning of the injection catheter and reinjection of CO₂ in different projection planes yields adequate views. Others have described the importance of using a specialized injector to achieve optimal angiography and avoid inadvertent introduction of air. We use a simple hand-injection method and closed system that includes a 60 mL syringe, three-way stopcock, and a bag of CO₂.

Although some question the safety of CO₂-DSA, we have found it to be a safe and valuable technique. In a recent review of 605 CO₂-DSA procedures performed at our institution for a variety of endovascular interventions, adverse events occurred in 5.1% (31/605) and included abdominal pain in 8, puncture site hematoma in 11, transient hypotension in 4, nausea in 3, and 1 patient each with renal failure, chest pain, localized aortic dissection, hives, and paresthesia. Two patients had persistent abdominal pain after aortography associated with hyperamylasemia and clinical evidence of pancreatitis. One died, for a mortality rate of 0.17%; however, the role of CO₂-DSA in that death is uncertain because microvascular cholesterol emboli were found at autopsy (Hood DB, Hua HT, Weaver FA. Carbon dioxide digital subtraction angiography: is it safe? Personal communication.)

The application of CO₂-DSA for EVAR has previously been suggested by Gahlen et al,²² who reported its use in three patients. Our report adds 16 patients and compares them with a concurrent group undergoing EVAR. The use of CO₂-DSA permitted a significant reduction in iodinated contrast use and minimized post-EVAR deterioration in renal function in patients with pre-existing azotemia. In three patients, EVAR was performed exclusively with CO₂. Successful endograft placement was possible in all 16 pa-

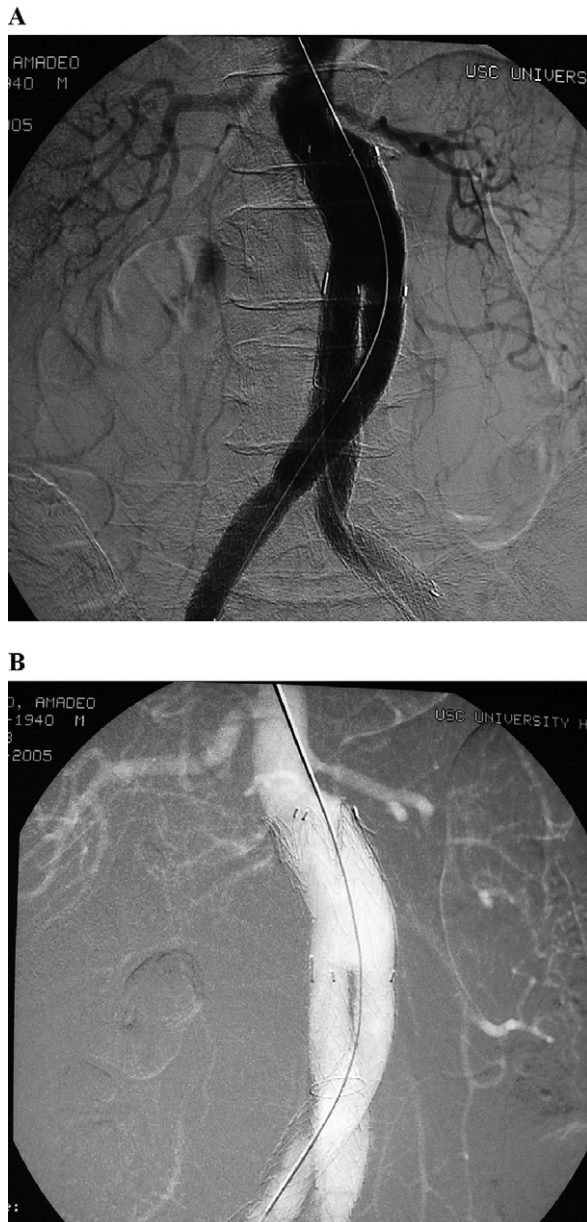


Fig 2. A, Iodinated contrast angiogram of completed EVAR. B, Comparison study using carbon dioxide digital subtraction angiography.

tients in group II, and the incidence of intraoperative endoleaks in groups I and II was similar. Of interest is our observation that CO_2 , because of its lower viscosity, is actually more sensitive in documenting intraoperative endoleaks than iodinated contrast. A prospective trial at our institution to further investigate this clinical observation is in progress.

Subsequent 6-month clinical follow-up and graft surveillance documents equivalency for endoleak incidence and the need for endograft revision. One caveat to this observation is that postoperative imaging for group II did

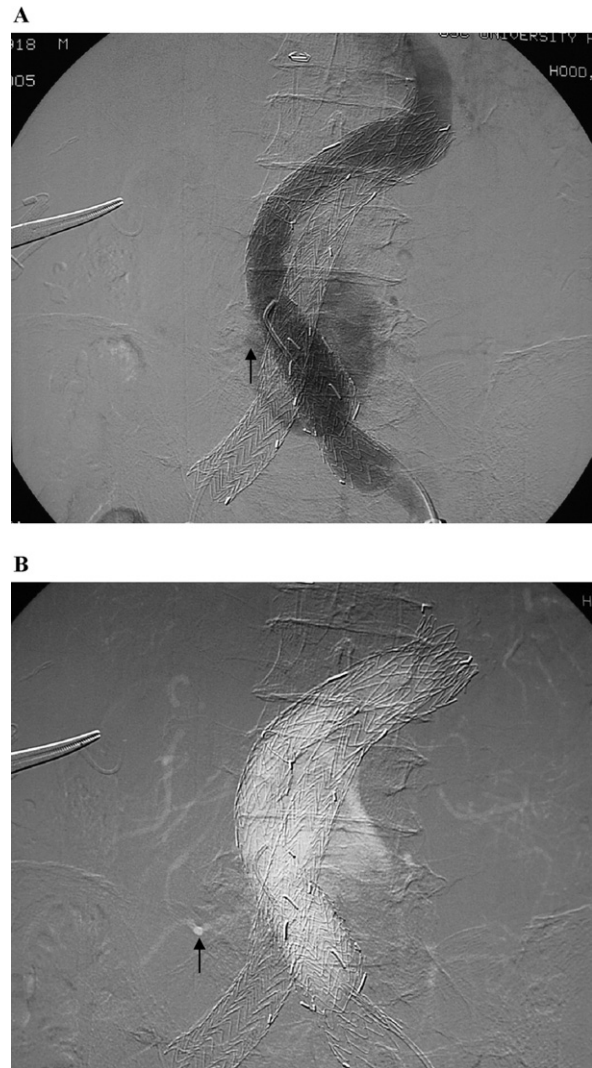


Fig 3. Type II endoleak intraoperatively documented by (A) iodinated contrast and (B) carbon dioxide digital subtraction angiography. Arrows point to feeding lumbar arteries.

not include the use of iodinated contrast CT, but relied on duplex, noncontrast CT, and MRI. As a consequence, some endoleaks, particularly small low-flow type II endoleaks, could have been missed in group II.

An observation not previously noted concerning CO_2 -DSA for EVAR is the significant increase in radiation exposure documented in group II patients. There are a number of possible explanations for this finding.

First, adequate CO_2 -DSA imaging does require an increase in frame rate from the customary two frames per second for iodinated contrast to six frames per second. This more than doubles the radiation exposure for each CO_2 -DSA run compared with iodinated contrast. In addition, we also documented that total fluoroscopy time was approximately doubled in group II cases. This could have been due to increased technical complexity in

the CO₂-DSA-directed EVAR cases. The finding of numeric but not statistically significant increases in the average number of graft extenders and the requirement for hypogastric artery embolization in group II cases lends support to this possibility. That total operative time was also significantly increased in group II lends additional support.

An alternative explanation however, includes either difficulty with CO₂ delivery or, more likely, poor image resolution with CO₂-DSA necessitating the use of iodinated contrast and a “repeat run” of the same area of interest. This was certainly the case in 13 patients in group II in which some iodinated contrast or gadolinium was necessary.

The significance of this finding must be considered in the context of lifetime diagnostic and therapeutic radiation exposure. The difference of approximately 400 Gy/cm² in average dose-area product between group I and II is roughly equivalent to 6,000 mrem. A standard abdominal CT angiogram exposes the patient to 144 Gy/cm² (2000 mrem).^{23,24} Consequently, the incremental increase in radiation exposure in group II is roughly equivalent to three additional CT scans over the life of the patient.

The effects of increased exposure to the operating team should also be commented on. The average radiology technician in our institution receives about 20 to 30 mrem a month (with detectors worn on the outside of lead shielding), with a maximum allowable exposure of 5000 mrem a year. As a point of reference, the average American is exposed to 360 mrem a year, mostly from terrestrial causes. It is estimated that the chance of cancer increases 10% after a total exposure of 250,000 mrem. The contribution of CO₂-DSA in this context appears to be negligible, particularly if appropriate shielding and wearing of lead aprons is followed.

CONCLUSION

This experience documents CO₂-DSA-directed EVAR to be a safe and effective strategy for reduction of contrast nephrotoxicity in the azotemic patient. The reduction in iodinated contrast use is accompanied by post-EVAR stability in renal function that is superior to the 2% to 16% incidence of renal deterioration that is reported in the literature. This salutary short-term outcome is accompanied by a late endoleak incidence and endograft revision rate that is equivalent to patients undergoing EVAR with iodinated contrast. These positive outcomes are tempered by the finding that CO₂-DSA for EVAR does prolong fluoroscopy times and increases radiation exposure to both patient and operating room personnel (Figs 2 and 3).

AUTHOR CONTRIBUTIONS

Conception and design: AC, KM, DBH, VLR, FAW
Analysis and interpretation: AC, KM, KP, DBH, VLR, RKB, FAW
Data collection: IT, AC, KM, KP, RKB

Writing the article: AC, IT, KM, DBH, FAW

Critical revision of the article: AC, FAW

Final approval of the article: AC, FAW

Statistical analysis: RKB

Obtained funding: Not applicable

Overall responsibility: FAW

REFERENCES

1. Prinssen M, Verhoeven ELG, Buth J, Cuypers PWM, van Sambeek MRHM, Balm R, Buskens E, et al; for the Dutch Randomized Endovascular Aneurysm Management (DREAM) Trial Group. A randomized trial comparing conventional and endovascular repair of abdominal aortic aneurysms. *New Engl J Med* 2004;351:1607-18.
2. Blankensteijn JD, deJohg SE, Prinssen M, van der Ham AC, Buth J, van Sterkenburg SM, et al; for the Dutch Randomized Endovascular Aneurysm Management (DREAM) Trial Group. Two-year outcomes after conventional or endovascular repair of abdominal aortic aneurysms. *New Engl J Med* 2005;352:2398-405.
3. Greenberg RK, Chuter TAM, Lawrence-Brown M, Haulon S, Nolte L; Zenith Investigators. Analysis of renal function after aneurysm repair with a device using suprarenal fixation (Zenith AAA endovascular graft) in contrast to open surgical repair. *J Vasc Surg* 2004;39:1219-28.
4. Hawkins IF. Carbon dioxide digital subtraction arteriography. *AJR Am J Roentgenol* 1982;139:19-24.
5. Back MR, Caridi JG, Hawkins Jr IF, Seeger JM. Nonoperative management of lower-extremity arterial disease, part ii. Angiography with carbon dioxide (CO₂). *Surg Clin North Am* 1998;78:575-91.
6. Weaver FA, Pentecost MJ, Yellin AE. Carbon dioxide digital subtraction arteriography: a pilot study. *Ann Vasc Surg* 1990;4:437-41.
7. Weaver FA, Pentecost MJ, Yellin AE. Clinical applications of carbon dioxide/digital subtraction arteriography. *J Vasc Surg* 1991;13:266-73.
8. Frankhouse JH, Ryan MG, Papanicolaou G, Yellin AE, Weaver FA. Carbon dioxide/digital subtraction arteriography-assisted transluminal angioplasty. *Ann Vasc Surg* 1995;9:448-52.
9. Schreiber DZ, Weaver FA, Frankhouse J, Papanicolaou G, Shore E, Yellin AE, et al. A prospective study of carbon dioxide-digital subtraction vs standard contrast arteriography in the evaluation of the renal arteries. *Arch Surg* 1996;131:503-8.
10. Chuter AM, Reilly LM, Faruqi RM, Kerlan RB, Sawhney R, Canto CJ, et al. Endovascular aneurysm repair in high-risk patients. *J Vasc Surg* 2000;31:122-33.
11. Wald R, Waikar SS, Liangos O, Pereira BJB, Chertow GM, Jaber BL. Acute renal failure after endovascular vs open repair of abdominal aortic aneurysm. *J Vasc Surg* 2006;43:460-6.
12. Mehta M, Veith FJ, Lipsitz EC, Ohki T, Russwurm G, Cayne NS, et al. Is elevated creatinine level a contraindication to endovascular aneurysm repair? *J Vasc Surg* 2004;39:118-23.
13. Walker SR, Yusuf W, Wenham PW, Hopkinson BR. Renal complications following endovascular repair of abdominal aortic aneurysms. *J Endovasc Surg* 1998;5:318-22.
14. Sugawara Y, Sato O, Miyata T, Deguchi J, Kimura H, Namba T, et al. Surgical results of abdominal aortic aneurysm repair in patients with chronic renal dysfunction. *Jpn Circ J* 1997;61:762-6.
15. Wijnen MHWA, Cuypers P, Buth J, Vader HL, Roumen RMH. Differences in renal response between endovascular and open repair of abdominal aortic aneurysms. *Eur J Vasc Endovasc Surg* 2001;21:171-4.
16. Brown MJ, Norwood MGA, Sayers RD. The management of abdominal aortic aneurysms in patients with concurrent renal impairment. *Eur J Vasc Endovasc Surg* 2005;30:1-11.
17. Martin-Paredero V, Dixon SM, Baker JK, Takiff H, Gomes AS, Busuttill RW, et al. Risk of renal failure after Major angiography. *Arch Surg* 1983;118:1417-20.
18. Rieger J, Sitter T, Toepfer M. Gadolinium as an alternative contrast agent for diagnostic and interventional angiographic procedures in patients with impaired renal function. *Nephrol Dial Transplant* 2002;17:824-8.

19. Akgun H, Gonlusen G, Cartwright J Jr, Suki WN, Truong LD. Are gadolinium-based contrast media nephrotoxic? A renal biopsy study. *Arch Pathol Lab Med* 2006;130:1354-7.
20. Briguori C, Colombo A, Airoidi F, Melzi G, Michev I, Carlino M, et al. Gadolinium-based contrast agents and nephrotoxicity in patients undergoing coronary artery procedures. *Catheter Cardiovasc Interv* 2006;67:175-80.
21. Remy-Jardin M, Dequiedt P, Ertzbischoff O, Tillie-Leblond I, Bruzzi J, Duhamel A, et al. Safety and effectiveness of gadolinium-enhanced multi detector row spiral CT angiography of the chest: preliminary results in 37 patients with contraindications to iodinated contrast agents. *Radiology* 2005;235:819-26.
22. Gahlen J, Hansmann J, Schumacher H, Seelos R, Richter GM, Allenberg JR. Carbon dioxide angiography for endovascular grafting in high-risk patients with infrarenal abdominal aortic aneurysms. *J Vasc Surg* 2001;33:646-9.
23. Kemerink GJ, De Haan MW, Vasbinder GBC, Frantzen MJ, Schultz FW, Zoetelief J, et al. The effect of equipment set upon patient radiation dose in conventional and CT angiography of the renal arteries. *Brit J Rad* 2003;76:625-30.
24. Zorzetto M, Bernardi G, Morocutti G, Fontanelli A. Radiation exposure to patients and operators during diagnostic catheterization and coronary angioplasty. *Cathet Cardiovasc Diagn* 1998;40:348-51.

Submitted Sep 18, 2005; accepted Nov 3, 2006.

DISCUSSION

Dr Roy Fujitani (Orange, Calif). Good morning, members and guests. Alex, that was a very well presented paper. The USC vascular surgery group has very nicely reported their continued experience with the use of carbon dioxide as an alternative to iodinated contrast material. Their experience dates back to 1991 when it was first reported by Fred Weaver and the authors at USC who had published their clinical applications of CO₂ angiography in the *Journal of Vascular Surgery*. In this series, the authors report contemporary utility of CO₂ digital subtraction angiography in imaging 16 of 100 patients who underwent endovascular aortic aneurysm repair with associated renal insufficiency over a 2-year period of time. The use of CO₂ DSA helped protect renal function by lessening the need for iodinated contrast material with effective imaging quality but resulted in longer fluoroscopic and operating times.

Now Dr Chao, as part of my discussion, I will intersperse four questions for you to consider. Since carbon dioxide is approximately 20 times more soluble than oxygen, the carbon dioxide bubbles completely dissolve within 2 to 3 minutes after being injected into the vessel and it is eliminated through the respiratory system, but I would be concerned that in using carbon dioxide in patients with very advanced pulmonary compromise or insufficiency, such as someone with COPD who is a carbon dioxide retainer or those patients who have pulmonary hypertension, the diagnostic doses of CO₂ may increase pulmonary arterial pressure. Additionally, patients with right-to-left shunts may be at risk for paradoxical gas embolism. This leads to my first question. Are there any absolute contraindications in the use of carbon dioxide as a contrast agent?

As you alluded, the incorrect technique may result in contamination of CO₂ gas with atmospheric air and this will result in very serious complications since atmospheric air is much less soluble in the blood than carbon dioxide. Additionally, even without contamination, if enough carbon dioxide gas is trapped within a large abdominal aortic aneurysm and it persists, it may allow gas exchange between the carbon dioxide and nitrogen within the blood. This exchange may result in visceral ischemia due to vacuum locking within the mesenteric arteries. In your manuscript, you alluded to one patient having developed pancreatitis, and I wonder if this may not have been the mechanism that had occurred due to ischemia of the visceral circulation.

There is need to be very careful in timing of consecutive injections of carbon dioxide—and I think you mentioned 2 minutes—to prevent the localized accumulation of gas bubbles, which may produce a clinically significant gas embolism. My next question, therefore is, is there a maximum volume in a single injection that prevents gas accumulation that may result in nitrogen dissolution and/or vapor locking?

Since carbon dioxide is lighter than blood plasma and floats on the surface of the blood, once injected into large vessels such as the aorta or inferior vena cava, carbon dioxide bubbles flow along the anterior surface of the vessel with incomplete blood disbursement

along the posterior portion. Because of the anterior origin the celiac vessels, the superior mesenteric arteries may be very well visualized even with smaller volumes. It has been reported that perhaps vessels that are smaller than 10 mm are best imaged with CO₂ angiography because then it disperses within 80% of the volume of blood. My next question therefore would be, is there a critical maximal diameter of the vessel or aneurysm where the buoyancy of carbon dioxide gas can be problematic, not allowing complete visualization of the lumen and, therefore, having a deterioration in the quality of the imaging?

All in all, carbon dioxide seems to have very notable advantages compared to iodinated contrast material. It has no allergic reactions. There is no renal toxicity. There does not appear to be any hepatic toxicity, and you can go on to inject unlimited amounts of carbon dioxide in vascular imaging because the gas is effectively eliminated by means of respiration. Finally, compared to nonionic contrast agents and gadolinium-based types of agents, it is relatively cheap. I checked with our purchasing department and contrast agents tend to be a little over \$1 per cc, whereas CO₂ is less than a penny.

My final question: with so many advantages of CO₂ DSA, has your group at USC considered performing all of its angiographic studies using this agent instead of iodinated contrast?

I want to thank the program committee for the privilege and opportunity to presents questions on this paper. Thank you.

Dr Alexander Chao. Thank you, Dr Fujitani, for your comments. In regards to your first question regarding any absolute contraindications to the use of CO₂: although there are contraindications to its use in certain procedures such as cerebral angiography, we have not found CO₂ to be contraindicated in any single patient population. As you mentioned, there are descriptions of concern with use of CO₂ in patients with severe COPD. Although we did not look at the severity of the COPD or any associated pulmonary hypertension, we have not found it to be a problem either in this study or in our previous experience.

Your second question concerned the maximum volume of CO₂ in a single injection that prevents accumulation. We currently use a 50-cc syringe bolus injection by hand with 2-minute intervals between injections. I am not aware of any human studies, but there were many dog studies that looked at volume. Rapid intravenous and intra-arterial injections of 7.5 milliliters per kilogram repetitively and continuous infusions of 100 milliliters per kilogram intravenous for up to 10 L of CO₂ were safe. Even injections of 7 milliliters per kilogram directly injected into canine renal arteries caused no complications in the supine position.

You talked about the vapor lock. Yes, there have been sporadic reports in the literature of complications that are thought due to vapor lock, with the greatest number of cases seen in the smaller series. I think these reports may play a large part in preventing wider use of CO₂. I do not really have an

explanation why there are sporadic reports. My impression is that it may be due to accidental contamination of room air into the injection. There are many different injection techniques currently in use. Notably, one group has described relying on automated injectors to prevent contamination by room air. We continue to have confidence in hand injection with attention to frequent purging. It is also important to ensure proper tightening of the seals on the lure-locks to, again, avoid unintentional withdrawal of air into the system.

Is there a critical maximum diameter of an aneurysm? I think that is going to be a hard one to answer. Your description of the physiology of CO₂ gas in the vascular system was most thorough. Unfortunately, my answer is much less impressive. We routinely image large aortic aneurysms well over 5 cm in diameter, while on the other end of the spectrum, we have reported in our experience with studying renal arteries as well as distal tibials with CO₂.

I think a large determinant of image quality depends on the injection catheter positioning and imaging angle. Initially, we frequently tried patient repositioning in regards to the buoyancy you mentioned, but we really have abandoned that recently, and find that with proper catheter positioning, you can get excellent contrast imaging in large as well as smaller vessels.

Your final question, with the many advantages of the CO₂ we purport, should we consider using it in all patients? I think that is a very good question. We have currently at USC initiated a prospective nonrandomized study looking at CO₂ versus iodinated contrast in each patient in attempt to get a better idea of the exact sensitivity of CO₂ gas in detecting endoleak during EVAR. We are considering increasing our use of CO₂ in the elderly patient population where the creatinine level may not be as sensitive an indicator of true renal function. We are trying to more consistently use the calculated estimated GFR.

Dr Willis Wagner (Los Angeles, Calif). A very nice presentation. Based on the leadership role that Fred Weaver and Doug Hood have shown us in the use of CO₂, we actually have a large experience with using CO₂ in patients with renal insufficiency. However, 2 years ago, I did have a case that has tempered our enthusiasm, and I would like to get some feedback from you. We had a patient who was having a CO₂ angiogram for occlusive disease who developed massive fatal emboli to everything below the diaphragm, unlike anything I had ever seen with patients having standard contrast angiograms. Due to lack of autopsy, we were unable to identify the cause of the embolization, but I am just wondering whether you have seen this and whether this was in fact related to the CO₂ or just the fact that the patient had the angiogram.

Dr Chao. What you describe is actually very similar to a case report in the literature attributed to CO₂ aortic angiography. This is something we thought about, but obviously, I cannot answer that definitively. We did not have any problems during this study, but our previous series of 600 CO₂ angiograms in patients from 1985 to 1995 did have one fatality that was due to what was initially thought to be small bowel vapor lock. That patient actually had an autopsy and was found to have multiple severe cholesterol microemboli in the small bowel. Similar to the risks of high-pressure injection during regular iodinated contrast angiography, the power injection of the CO₂ may also cause fragmentation of unstable aortic debris.

This brings up a technical point I failed to mention. Due to the compressible nature of the CO₂ gas, during a rapid 60-cc manual injection the majority of the CO₂ is not actually expelled until the syringe is nearly empty. It is a good idea to ease off a little at the end of the injection to avoid too high a pressure at the delivery end. Others have suggested that all injections be done with an automated injector to prevent overpressurization, but once again, we do not really find that to be a problem currently.

Dr J. Dennis Baker (Los Angeles, Calif). Why did you have such a substantial increase in your fluoroscopy time and radiation?

Can you explain why it takes so much more radiation to complete the task with carbon dioxide?

Dr Chao. That was something that was a little bit of a surprise when we sat down and looked at the data, but the total radiation as measured by DAP is easy to explain. Normally for angiography we use either two or three frames per second, usually two frames per second. For the CO₂, we really have found it necessary to go to six frames per second. As you know, the runs really count for most of the patient radiation exposure. The fluoroscopy time was also increased significantly, here almost doubled by number, and I do not really have a good explanation of that. When we looked, we did have—I think it was—38% in group 2 requiring hypogastric artery embolization and a smaller percentage in group 1. Group 2 patients I think overall tended to be somewhat more complicated. We saw a trend in a greater number of graft components used and the longer operative times. The CO₂ itself does not increase the operative time at all, so I think it may have just been part of the patient population that explains the increase in fluoroscopy time.

Dr Benjamin Starnes (Seattle, Wash). Alex, that was a very nice presentation. I have a couple of questions. In my experience with CO₂ angiography, especially with the patient awake, one injects the CO₂ and the patient complains of severe abdominal pain and then moves all over the place and that certainly affects the imaging quality substantially. If you are doing these under local or regional anesthesia, perhaps that is an explanation as to why you have increased your fluoroscopy time. Are you having to put every single patient under general anesthesia to use this technique? One would think that this would add to the morbidity profile.

The second question is, why not use IVUS to precisely locate your pelvic vessels and be able to precisely place your graft? I use IVUS quite often for this purpose and I think that it is an attractive alternative over CO₂.

Dr Chao. We have had some experience with IVUS use in the past and again recently for thoracic endograft placement but have not enough experience to become proficient or have a personal opinion on its utility. Additionally, for routine EVAR, the acquisition cost versus patient benefit is somewhat prohibitive. All the patients in this series received general anesthesia. In regards to lower extremity CO₂ angiography, we have found the DS to be no more or less than with iodinated contrast.

Dr Timothy Chuter (San Francisco, Calif). I notice you use on average 27 milliliters of contrast. We have been able to use even lower volumes of contrast without using CO₂. We perform selective angiograms of the renal arteries using bright-tip catheters and little puffs of half-strength contrast. In fact, we have inserted multibranched stent grafts for TAAA using as little as 25 milliliters of contrast. Have you tried selective angiography as an alternative to CO₂ angiography, which seems to involve intubating the patients and spending a lot of extra time in the OR?

Dr Chao. That is very impressive and I have heard descriptions from your institution regarding very low volumes of contrast.

Dr George Andros (Los Angeles, Calif). Under Fred's goading and Nick Nelken's persistence, we instituted a CO₂ angiography program many years ago. Because we have a lot of diabetics in our practice, we use it very commonly for bilateral renal stenting and all sorts of infrainguinal work, but not for aneurysms so far. And it's cheap!

Isn't it a little disingenuous to say you only use 27 cc of contrast when nearly all patients are evaluated with followup CT angiography? Is this your imaging policy, or are you doing followup studies with duplex? We heard earlier today that, on average, patients treated with EVAR will have a measurable decline in renal function when checked 1 year postoperatively. If you are economical with iodinated contrast as you suggest, have you also observed this deterioration in kidney function or are the patients spared this complication by using CO₂ and duplex?

Dr Chao. Those are excellent points, and I am glad we have an opportunity to discuss the importance of cumulative contrast toxicity. Greenberg's recent data suggest a cumulative effect on the kidneys. Going by our protocol, in any patient with baseline renal insufficiency, we avoid contrast during preoperative or postoperative CTs unless absolutely necessary. We have previously demonstrated excellent correlation in our institution between duplex imaging and CT, so we either obtain duplex preoperatively or MR angiography. Preoperatively we follow by duplex only on these patients so there is no other cumulative contrast insult.

As far as the BUN and creatinine, it is a problem. In this day and age, it is difficult to get follow-up labs on patients. We only had post-op inpatient and discharge labs; however, we do know that no patient required dialysis at any point for contrast-induced renal failure.

Dr Chuter. I have to respond to the word disingenuous. I do not think anybody would advocate using CO₂ outside of the setting of the stent graft implantation, so that is where I was focusing my comments and that is what the 25 milliliters refers to.