


Contents lists available at ScienceDirect IF: 0.926

Asian Pacific Journal of Tropical Medicine

journal homepage: www.elsevier.com/locate/apjtm

Document heading doi: 10.1016/S1995-7645(14)60156-5

Effect of recombinant human bone morphogenetic protein 2/poly-lactide-co-glycolic acid (rhBMP-2/PLGA) with core decompression on repair of rabbit femoral head necrosis

Zhao-Xun Pan*, Hong-Xin Zhang, Ye-Xin Wang, Long-Di Zhai, Wei Du

Department of Joint Surgery, No 89 Hospital of People's Liberation Army, Weifang 261021, China

ARTICLE INFO

Article history:

Received 24 August 2014

Received in revised form 10 September 2014

Accepted 15 October 2014

Available online 20 November 2014

Keywords:

rhBMP-2

Microsphere

Core decompression

Femoral head necrosis

ABSTRACT

Objective: To observe the effect of recombinant human bone morphogenetic protein 2/poly-lactide-co-glycolic acid (rhBMP-2/PLGA) with core decompression on repair of rabbit femoral head necrosis. **Methods:** Bilateral femoral head necrosis models of rabbit were established by steroid injection. A total of 48 rabbits (96 femoral head necrosis) were randomly divided into 4 groups: Group A, control group with 12 rabbits, 24 femoral head necrosis; Group B, treated with rhBMP-2/PLGA implantation after core depression, with 12 rabbits, 24 femoral head necrosis; Group C, treated with rhBMP-2 implantation after core depression, with 12 rabbits, 24 femoral head necrosis; Group D treated with core depression group without implantation, with 12 rabbits, 24 femoral head necrosis. All animals were sacrificed after 12 weeks. The ability of repairing bone defect was evaluated by X-ray radiograph. Bone mineral density analysis of the defect regions were used to evaluate the level of ossification. The morphologic change and bone formation was assessed by HE staining. The angiogenesis was evaluated by VEGF immunohistochemistry. **Results:** The osteogenetic ability and quality of femoral head necrosis in group B were better than those of other groups after 12 weeks by X-ray radiograph and morphologic investigation. And the angiogenesis in group B was better than other groups. Group C had similar osteogenetic quality of femoral head necrosis and angiogenesis with group D. **Conclusions:** The treatment of rhBMP-2/PLGA implantation after core depression can promote the repair of rabbit femoral head necrosis. It is a promising and efficient synthetic bone material to treat the femoral head necrosis.

1. Introduction

Osteonecrosis of the femoral head (ONFH) is one of the commonest osteoarthropathies around the world, which is primarily the destruction of blood supply of adjacent articular surfaces around the femoral head caused by several diseases, thus lead to osteonecrosis of the weight-bearing areas. The challenge is filling in the defects of osteonecrosis area and the recovery of local blood supply^[1,2]. Currently, one of the most common treatments is surgery and but there are many problems such as post-operative complications,

short life of prosthesis. To find a better treatment for osteonecrosis has been the common interest. Poor local blood supply of femur head and lack of bone growth factors are important causes of ONFH. The recombinant human bone morphogenetic protein 2 (rhBMP-2) has higher purity than bone morphogenetic protein (BMP). It has potential in inducing undifferentiated mesenchymal cells to cartilage or osteocyte, but its effectiveness is unsatisfactory because drugs cannot continuously stimulate target cells in the surrounding defect areas on the basis of its property as acidic peptides and short half-life period^[3,4]. The present research focus is to establish stable rhBMP-2 sustained release system and reduce its leakage by loading rhBMP-2 to the carriers, thus local rhBMP-2 concentrations of implant site can be improved and the effectiveness of rhBMP-2 can be optimized. Poly-lactide-co-glycolic acid

*Corresponding author: Zhao-Xun Pan, Department of Joint Surgery, No 89 Hospital of People's Liberation Army, Weifang 261021, China.

E-mail: guke89@126.com

Foundation project: It is supported by Shandong Province Natural Science Foundation of China: sd2018762872.

(PLGA) featured by low immunity, good biocompatibility and regulated degradability is a microsphere matrix, where rhBMP-2 loaded microsphere of PLGA has superior sustained release properties. In our experiment, the model of aseptic necrosis of rabbit femoral head was established and rhBMP-2/PLGA sustained release microsphere carrier system was injected to bone defect of rabbit femoral head, thus its actual possibility of application and availability was explored.

2. Materials and methods

2.1. Experimental animals and major reagents & instruments

A total of 50 healthy New Zealand white rabbit were provided by the Animal Center of Zhejiang University Medical College, with average weight of 2.8 kg. rhBMP-2/PLGA drug-loaded microsphere was generously donated by Zhi-Heng Ling, the First Affiliated Hospital of Zhejiang University. The entrapment efficiency of PLGA microspheres was $(37.52 \pm 4.31)\%$ and drug loading efficiency was $(5.12 \pm 1.32)\%$ [5]. Chitin gel was from Shanghai Qisheng Biological Agent Co., Ltd. Methylprednisolone sodium succinate was purchased from Nanjing Deepth Chemical Co., Ltd. Horse serum was obtained from Guangzhou Rui Special Biological Technology Co., Ltd. Ready-to-use immunohistochemical ultra-sensitive UltraSensitive™ SP KIT-9701 and mouse anti-human vascular endothelial growth factor (VEGF) monoclonal antibody were from Fujian Maixin Biotechnology Co., Ltd. Optical microscope (Olympus, Japan). DAKO AutostainerPlus Automated Immuno-Histo Stainer (DAKO, USA). X-ray apparatus (Radiology Department, the First Affiliated Hospital of Medical College, Zhejiang University). Microsphere composite was prepared by mixing rhBMP-2/PLGA and chitin gel together and centrifuged. 3 microgram of rhBMP-2 was included in the mixture of gel and microsphere per milliliter, which was freshly prepared immediately before use.

2.2. Animal model preparation and randomization

After adaptive feeding for about one week, 10 mL/kg horse serum was firstly injected into the marginal auricular vein of rabbits and the same horse serum was injected again three weeks later with the amount changed to 6 mL/kg; at a time interval of 2 weeks, methylprednisolone sodium succinate 45 mg/kg was injected into the same site, once daily for 3 days. Since methylprednisolone sodium succinate injections started, each rabbit was intraperitoneally injected with

penicillin 10 million units/day for continuously 7 days; at the last injection, 2 rabbits were sacrificed randomly to retrieve the femoral head specimens, fixed with 4% formaldehydum polymerisatum, decalcified, embedded in paraffin and routine HE staining was conducted on serial sections. Rabbit modeling was observed by histological methods and the criteria for successful modeling in each rabbit were avascular necrosis (AVN) of the femoral head. Successful modeling rabbits were randomly divided into four groups. Group A, blank control group (12 rabbits, 24 sides) without treatment after modeling. Group B, rhBMP-2/PLGA group (12 rabbits, 24 sides), rhBMP-2/PLGA bearing microsphere and chitin gel mixture were injected into orifice after core decompression. Group C, rhBMP-2 group (12 rabbits, 24 sides), rhBMP-2 powder and chitin gel mixture were injected into orifice after core decompression. Group D, (12 rabbits, 24 sides) received only core decompression therapy. The bone wax was used to pack small bone cavities and sutured of incisions were performed carefully layer by layer after intervention in group B, C and D. Routine use of antibiotics was carried out after operation.

2.3. X-ray examination

Anteroposterior view of hip joints obtained by X-ray examinations were conducted in animals in each group 12 weeks after operation. Treatment outcomes of ONFH of animals in each group were observed.

2.4. Histomorphological observation

The femoral head specimens were retrieved from animals in each group 12 weeks after surgery, fixed with 4% formaldehydum polymerisatum, decalcified, embedded in paraffin and routine HE staining was conducted on serial sections. Osteogenesis in the femoral head, material degradation, morphological change and bone growth status were observed under optical microscope and empty lacunae in 5 high-power fields of each specimen were counted.

2.5. Immunohistochemistry (IHC) evaluation for VEGF

The femoral head specimens were obtained as mentioned in 1.4, which was fixed with 4% formaldehydum polymerisatum, decalcified, embedded in paraffin and S-P immunohistochemical staining (Ready-to-use immunohistochemical ultra-sensitive UltraSensitive™ SP KIT-9701, Fujian Maixin Biotechnology Co., Ltd.) of VEGF (mouse anti-human VEGF monoclonal antibody MAB-324, Fujian Maixin Biotechnology Co., Ltd.) was conducted on

serial sections. Negative control group were treated with PBS as primary antibody. VEGF staining was considered positive in positive control group. DAB color development (DAB-1031, Fujian Maixin Biotechnology Co., Ltd.) and hematoxylin redyeing was conducted. Image analysis software MetaMorph 7.6 was adopted. Five randomly-selected fields in 400 times microscope field of view were used to observe the average optical density.

2.6. Statistical analysis

SPSS 13.0 was used in data analysis. All data were expressed as mean±standard error. One-way ANOVA was used to compare normal distribution data between two groups and SNK test was used for pairwise comparisons.

3. Results

3.1. X-ray results

12 weeks after operation, X-ray results were obtained. A: Blank control group was featured by blurred articular surface of rabbit femoral head, unclear bone structure, osteosclerosis formation and decreased bone density of diaphyseal and metaphyseal regions. B: rhBMP-2/PLGA implantation group after core decompression was featured by clear articular surface, bone structure approached normal group, no osteosclerosis formation and bone density closed to normal level. C: rhBMP-2 implantation group after core decompression was characterized by slightly blurred articular surface, bone structure was much more clear than group A, its sclerosis rim was less than group A but more than group B and decreased bone density of diaphyseal and metaphyseal regions was higher than those of group A. D: Core decompression group was featured by slightly blurred articular surface, bone structure much more clear than group A, its sclerosis rim was less than group A and the bone density of diaphyseal and metaphyseal regions was similar to those of group C (Figure 1).

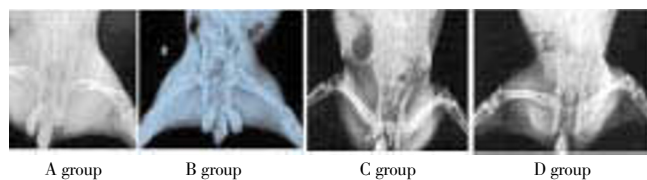


Figure 1. Anteroposterior X-ray film of rabbit femoral head in all groups 12 weeks after operation.

3.2. Histological observation

Histological observations were conducted on all the groups 12 weeks after surgery. A: Blank control group, significantly thinner cartilaginous layers and plenty of necrotic cartilage cells of regular arrangement were observed. Crescent-shaped defects could be seen in subchondral bone and increased numbers of empty bone (19.76 ± 1.02) lacunae than those of group B (11.63 ± 1.35), C (14.32 ± 2.01) and D (15.79 ± 1.42) ($P<0.05$). Group B: Thickened articular cartilage and subchondral bone and regular arrangement of chondrocyte were observed. Adipose cells were rarely seen. There was much denser distribution of bone trabecular observed, which was manifested with fragility. The empty bone lacunae in bone trabecular were rare and the number of empty bone lacunae in group B was significantly less than those in group A, C and D ($P<0.05$). A large number of osteoblasts were surrounding the bone trabecular. Group C: Thinner articular cartilage and cartilage cells of irregular arrangement could be observed. Subchondral bone was thinner in group C compared to group B. Attenuation and partial interruption in trabeculae of bone was much more likely than group B. The number of empty bone lacunae in bone trabecular was more than this in group B, but less than this in group A ($P<0.05$). The number of osteoblasts surrounding the bone trabecular decreased. Group D: A few osteoid and new bone trabecular were formed around the drilled holes. A few blood vessels were formed. The surface layer of articular cartilage of group D was similar to group C. The number of empty bone lacunae in group D had no significantly differences from this of group C ($P>0.05$) (Figure 2, 3).

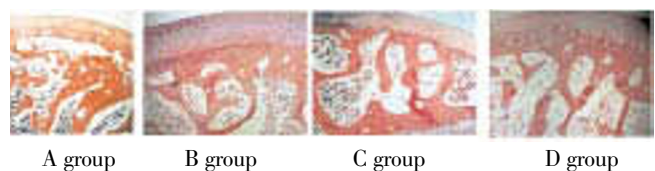


Figure 2. Histological observations on rabbit femoral head in all groups 12 weeks after operation (HE staining, $\times 40$).

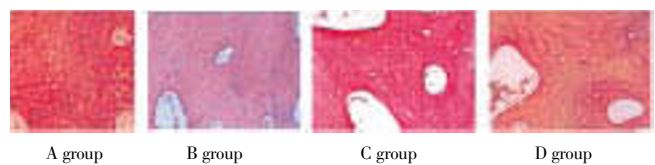


Figure 3. Histological observations on rabbit femoral head in all groups 12 weeks after operation (HE staining, $\times 200$).

3.3. VEGF staining results

Particles of VEGF proteins with positive reaction were

positioned in cytoplasm of osteocytes and cartilage cells (Figure 4). The average optical densities of all the 4 groups with positive staining were 0.23 ± 0.12 , 0.78 ± 0.09 , 0.40 ± 0.11 and 0.42 ± 0.14 , respectively. The optical density of group B was significantly higher than those of group A, C and D. In addition, the optical density of group C and D were significantly higher than the value of group A, while there was no significant difference between group C and group D ($P>0.05$).




Figure 4. IHC observations on the local VEGF expression of rabbit femoral head in all groups 12 weeks after operation (HE staining, $\times 200$).

4. Discussion

Femoral head is important weight-bearing and sports parts, which supports the weight of body and bears much more physiological stress than any other joints. Once ONFH has occurred, joint mobility and walking function are gradually lost, accompanied by continuous hip pain. ONFH is one of the orthopedics refractory disorders that is common in clinical practices. In the early phase of ONFH, internal hip joint is in a state of aseptic inflammation status without associated infection, where congestive exudation, increased intracapsular pressure and femoral head ischemia were observed. Besides, there were no clear signs of trabeculae fractured, femoral head collapse and deformity, inflammatory change and necrotic tissues reparable without any deformities. Therefore, filling in the defects of osteonecrosis area by bone cement or bone graft substitutes or recovering the local blood supply has been the focus[6]. Core decompression could eliminate necrotic bone and decrease intraosseous pressure, improve venous return and stimulate angiogenesis, thus associated symptoms can be relieved and course of disease was shortened. 12 weeks after successful establishment of aseptic necrosis of rabbit femoral head, compared with blank control group, general status of laboratory animals, macroscopic observation, osteogenesis and neovascularization were superior in core decompression group. Israelite has reported that, after long term follow-up visits, the short term and long term efficacy of core decompression is satisfactory, which may

effectively delay the natural progression of osteonecrosis at the early stage. Its major disadvantages is that it can't thoroughly repair the defect of articular cartilage of femoral head, mainly attribute to greater defects within the femoral head and can't improve osteogenesis in bone defects, especially when there are extensive femoral head necrosis. Furthermore, lacking sufficient osteogenesis factors and mechanical support structure was another disadvantage of core decompression[7].

As one of the signaling proteins which has the greatest potential for bone induction, rhBMP-2's bone induction properties. It can regulate extracellular matrix not only to stimulate chemotaxis of osteoblasts but also to adjust the expressions of integrin, thus faster cell proliferation may lead to the integration of osteoblasts into extracellular matrix and formation of normal, healthy bone tissue[8]. In recent years, with the fast development of tissue engineering, the treatment strategy of implanting rhBMP-2 into necrotic area of femoral head after core decompression could increase bone repair in local area, enhance necrotic bone repairing and improve the capability of recovery of femoral head necrosis. However, it is characterized by short half-life period, easy to break down and can't continuously stimulate target cells to give full play to its osteoinductive activity. In our study, general status of experimental animals in rhBMP-2 implantation combined with core decompression group is slightly superior to core decompression group 12 weeks after operation. However, there are no significant differences in regarding macroscopic observation, osteogenesis and new blood vessel formation, which may correlate with short half-life period *in vivo*, local application and improve local blood circulation after core decompression. Therefore it is urgently needed to find a kind of suitable carrier to play a maximum role in inducing osteoblastic activity as rhBMP-2 can be easily washed away by the blood. As an ideal biodegradable scaffolds for tissue engineering, PLGA has been widely used in the controlled-release drug carriers with good biocompatibility, degradability and no immunogenicity, which can be used as a promising scaffold for osteogenesis factors. PLGA characterized by good biocompatibility and without immunoreaction *in vivo*, could release drugs by surface erosion and internal erosion mechanisms in slower release rate. As one of the clinically used biodegradable materials, PLGA has been approved by FDA to be widely used as controlled drug release carriers[9,10]. Surprising achievements have been obtained of the application of rhBMP-2/PLGA microsphere in controlled drug releasing[5]. It is used for local injection after dissolution and is easy to operate, thus surgical injuries can be reduced to the

minimum extent. Besides, bone formation in the defective areas can be enhanced by continuously release rhBMP-2. In our study, 12 weeks after operation, the general status of laboratory animals, macroscopic observation, bone formation and neovascularization of rhBMP-2/PLGA group after core decompression treatment were superior to those of any other group. The research of Kakudo *et al* focusing on rhBMP-2 inducing mice ectopic endochondral ossification shows that there are VEGF expressions in all stages of rhBMP-2, which induces bone formation and rhBMP-2 may induce undifferentiated stem cells to bone cells and cartilage cells. Therefore, the VEGF expression by differentiated cells creates favorable blood circulation that is beneficial for bone tissue formation^[11]. Akeel is in favor of the idea that rhBMP-2 increased the expression of VEGF by reactive oxygen species^[12]. We find that 12 weeks after surgery, rhBMP-2/PLGA microsphere implantation group after core decompression treatment shows higher VEGF expression than any other group, the mechanism of which may be the continuously release of rhBMP-2 to induce VEGF expressions in the process of bone formation by the aid of PLGA microsphere scaffolds. Therefore, expected therapeutic efficacy can be achieved by creating favorable blood circulation for the recovery of rabbits femoral head necrosis.

In conclusion, the treatment of rhBMP-2/PLGA sustained release microsphere implantation in local area is effective in recovering rabbits femoral head necrosis and increases the local blood supply to normal level without bone formation in defective area after medullary cavity decompression. It provides new thoughts for the recovery of femoral head necrosis. However, still further studies are needed before the clinical application of rhBMP-2/PLGA sustained release microsphere.

Conflict of interest statement

We declare that we have no conflict of interest.

References

- [1] Dimitroulias A, Tsironi E, Hadjigeorgiou G, Scarmeas N, Rountas Ch, Zibis A, et al. White matter lesions in femoral head osteonecrosis patients: Manifestation of vascular disease or not. *Hippokratia* 2011; **15**: 265–268.
- [2] Vulpiani MC, Vetrano M, Trischitta D, Scarcello L, Chizzi F, Argento G, et al. Extracorporeal shock wave therapy in early osteonecrosis of the femoral head: prospective clinical study with long-term follow-up. *Arch Orthop Trauma Surg* 2012; **132**: 499–508.
- [3] Davis HE, Leach JK. Designing bioactive delivery systems for tissue regeneration. *Ann Biomed Eng* 2011; **39**: 1–13.
- [4] Kashi TS, Eskandarion S, Esfandyari-Manesh M, Marashi SM, Samadi N, Fatemi SM, et al. Improved drug loading and antibacterial activity of minocycline-loaded PLGA nanoparticles prepared by solid/oil/water ion pairing method. *Int J Nanomed* 2012; **7**: 221–234.
- [5] Yao Q, Zhang LH, Huang P. Morphogenesis protein fibrin glue compound restructuring bones and evaluation of the synthesis of 2. *China Tissue Eng Res Clin Reh* 2009; **10**: 10028–10032.
- [6] Wu CL, Mao Q, Jin HT. Study on the effect of Youguiyin on regulating gene expression profile of the rats with femoral head necrosis induced by steroid. *Chin J Integr Med* 2012; **18**: 269–275.
- [7] Israelite C, Nelson CL, Ziarani C, Abboud JA, Landa J, Steinberg ME. Bilateral core decompression for osteonecrosis of the femoral head. *Clin Orthop Relat Res* 2005; **441**: 285–290.
- [8] Lee J, Decker JF, Polimeni G, Cortella CA, Rohrer MD, Wozney JM, et al. Evaluation of implants coated with rhBMP-2 using two different coating strategies: a critical-size supraalveolar peri-implant defect study in dogs. *J Clin Periodontol* 2010; **37**: 582–590.
- [9] Zhang X, Sun M, Zheng A. Preparation and characterization of insulin-loaded bioadhesive PLGA nanoparticles for oral administration. *Eur J Pharm Sci* 2012; **45**: 632–638.
- [10] Zhang Y, Yang F, Liu K, Shen H, Zhu Y, Zhang W, et al. The impact of PLGA scaffold orientation on *in vitro* cartilage regeneration. *Biomaterials* 2012; **33**: 2926–2935.
- [11] Kakudo N, Kusumoto K, Wang YB, guchi Y, Ogawa Y. Immunolocalization of vascular endothelial growth factor on intramuscular ectopic osteoinduction by bone morphogenetic protein-2. *Life Sci* 2006; **79**: 1847–1855.
- [12] Akeel S, El-Awady A, Hussein K, El-Refaey M, Elsalanty M, Sharawy M, et al. Recombinant bone morphogenetic protein-2 induces up-regulation of vascular endothelial growth factor and interleukin 6 in human pre-osteoblasts: Role of reactive oxygen species. *Arch Oral Biol* 2012; **57**: 445–452.