

Contents lists available at ScienceDirect

IDCases

journal homepage: www.elsevier.com/locate/idcr

Case Report

Severe malaria in immigrant haematological patient



R. Vázquez-Sánchez*, M.E. Martínez-Núñez, T. Molina-García

Pharmacy Department, Hospital Universitario de Getafe, Madrid, Spain

ARTICLE INFO

Article history:

Received 22 April 2015

Received in revised form 11 July 2015

Accepted 28 July 2015

Keywords:

Malaria

Falciparum

Leukaemia

Immigrant

ABSTRACT

Severe malaria is a life-threatening condition caused by *Plasmodium falciparum*. Rupture of red blood cells when merozoites release to the bloodstream is responsible for the clinical manifestations, febrile fever reaching 39 °C, and other unspecific symptoms. *P. falciparum* is considered as the worst form of malaria. Moreover, this species has cytoadherence to red blood cells. This can lead to an organic dysfunction. People coming from hyper endemic areas have developed a partial immunity, but immunodepressed people are a group with a greater risk. Due to the high mortality rate associated to this disease, early diagnosis and a prompt treatment implementation are essential. However, the missed or delayed diagnosis is one of the major reasons of reaching a severe malaria disease. This case reflects the complexity of the diagnosis in an immigrant and immunodepressed patient with a haematological neoplasm with a severe infection by *P. falciparum* due to the unspecific symptoms and the overlapping of the same.

© 2015 The Authors. Published by Elsevier Ltd. This is an open access article under the CC BY-NC-ND license (<http://creativecommons.org/licenses/by-nc-nd/4.0/>).

Introduction

Malaria is a serious infectious disease caused by a parasite of the *Plasmodium* spp.

The clinical manifestations of malaria differ with the geographic distribution, *Plasmodium* species, epidemiology, age and immunity. In areas where malaria is hyper endemic, youngsters and adults may develop a partial immunity after repeated contact with the parasite, and they are at relatively low risk of severe disease [1].

The incubation period varies between 12 and 15 days, whereas individuals are asymptomatic, but on patients with partial immunity this period can increase up to 30 days after returning from the malaria endemic area [2].

The initial symptoms of malaria are nonspecific [1,2], and may include fever, tachycardia, tachypnea, chills, anaemia, myalgia, malaise, and other unspecific symptoms, secondary to the red blood cells (RBC) lysis and the release of pro-inflammatory cytokines to the bloodstream.

Plasmodium falciparum is responsible for the most severe form of malaria. Cytoadherence of *P. falciparum* infected-RBC to the endothelium of microvessels is thought to be the key mechanism involved in pathogenesis of severe malaria. Cytoadherence leads to microvascular sequestration of parasitized erythrocytes in different vital organs, developing partial blood flow obstruction, endothelial

barrier breakdown and finally multiorgan failure and death [3,4]. Increasing parasitemia is associated with increasing disease severity. The World Health Organization (WHO) establishes a cutoff of 5 percent of parasitized-RBCs in low transmission areas, and 10 percent in hyper endemic areas to define hyperparasitemia for the diagnosis of severe malaria [1]. Semi-immune patients may have substantial parasitemia with no clinical manifestations. Nevertheless, individuals with higher risk of complicated malaria include young children, nonimmune patients, pregnant women, and immunocompromised patients [1].

Due to the high mortality rate associated to this disease, up to 15–20 percent [1] in complicated cases, early diagnosis and a prompt treatment implementation are essential. The main problem lies in countries with a low prevalence of malaria, where the lack of clinic suspicion due to the unspecific symptoms can delay the diagnosis and treatment.

The next description is a case of a patient with a haematological neoplasm and associated immunodepression who was diagnosed with a severe infection by *P. falciparum*. It reflects the complexity of the diagnosis due to the unspecific and overlapped symptoms with the patient's leukaemia, reflecting the importance of a prompt initiating highly active treatment in a very severe immunodepressed patient.

Case report

A 38-year-old Nigerian woman, living in Spain 7 years, went back to Nigeria. In Nigeria, she attended to a regional hospital

* Corresponding author. Tel.: +34 916247265.

E-mail address: rocio.vazquez@salud.madrid.org (R. Vázquez-Sánchez).

presenting leucocytosis and severe lymphocytosis compatible with an acute lymph proliferative syndrome. In addition, the patient had severe anaemia; therefore, she needed blood transfusions (BT). Due to the severity of the signs and symptoms (fatigue for 3–5 months, weight loss, analgesic non-responsive headache and lumbar pain), the patient decided to return to a Spanish Emergency Department. The patient was admitted at hospital for further study. After obtaining a marrow biopsy and cytogenetic studies, the patient was diagnosed with Myeloid Chronic Leukaemia (MCL) bcr/abl positive in novo blast crisis and she started a quimiotherapy treatment with a suitable response.

Coincidentally with the severe aplasic phase, the patient was febrile (39 °C) and had severe low RBC counts which required BT. In the first place these symptoms were associated with febrile neutropenia and tumoral lysis syndrome. Despite the antimicrobial and antifungal wide spectrum treatment, it was detected lack of response and all blood and urine test were negative. In addition, the patient suffered severe undernourishment, mucositis and mainly nocturnal anxiety, confusion, agitation and disorientation episodes which required tranquilizers and sedative treatment.

Ten days after the hospital admission, the patient suffered a sudden loss on consciousness which was, in first place, associated with the sedatives. Due to an acute respiratory distress syndrome with tachycardia, dysnea, taquipnea, hipoxemia and respiratory distress, the patient required endotracheal intubation and mechanic ventilation in the Intensive Care Unit (ICU). Cardiovascular dysfunction, renal failure and hepatomegaly were also presented. During the first 24 h the patient also suffered a generalized tonic clonic seizure with horizontal nistagmus to the left. Despite all the above signs, neuroimaging was normal. The study of the cerebrospinal fluid (CSF) showed a slight increase in glucose (87 mg/dL), proteins (47 mg/dL) and cells (27 cells/M). Because a leukemic infiltration was suspected regarding the patients basal disease, an intrathecal triple chemotherapy (ITC) was initiated. Subsequent CSF showed no blastic cells and ITC was discontinued.

After 1 month a routine blood frotis was performed and parasite *P. falciparum* forms were observed, and a 10 percent of parasitemia was detected. With these findings the Pharmacy Department was consulted for a recommended antimalarial treatment. Due to the high parasitemia percentage, the organic dysfunction, the severe immunodeficiency, the probable cloroquin resistance related to the geographic origin of the infection and the oral intolerance related with the mucositis, intravenous artesunate treatment was initiated (2.4 mg/kg × 3 initial dosing every 12 h, completed with 2.4 mg/kg every 24 h until the 4th day of treatment).

After 24 h from the beginning of the treatment, the parasitic forms were almost eradicated with a major clinical improvement. The antimalarial treatment was completed with an oral combination of atovaquone and proguanil for 3 days which eradicated the infection completely. A close monitoring for artesunate haemolysis for 4 weeks after treatment was recommended [2].

Finally the patient was discharged on the 29th day of the chemotherapy treatment with an increase in neutrophils count and the disappearance of the mucositis and the neurologic manifestations.

Discussion

We have faced a severe case of malaria produced by *P. falciparum* with a high parasitemia in a context of severe immunodeficiency due to the myelosuppressor chemotherapy treatment. Additionally, the patient comes from an endemic area of malaria which provides a partial immunity against the parasite as a protective factor [1,2].

Regarding malaria transmission, although the mosquito bite is the main course of transmission, there are cases of vertical transmission, through BT and organ transplants [1,2]. The malaria transmission through BT from asymptomatic carriers is a major problem in tropical Africa (the patient received BT in a country where safety and quality controls are uncertain).

Regarding the symptoms, the patient suffered febrile peaks reaching 39 °C which were impossible to relate to a focus of infection. Moreover, the patient suffered a systemic dysfunction involving the main organs affected by the cytoadherence of *P. falciparum* [3]. In the course of malaria, a regular fever pattern is not always present, especially the *falciparum* malaria [2]. Nevertheless there was a clear overlapping between the febrile peaks and the acute haemoglobin reduction which could be related to the RBC cells when merozoites escape to the bloodstream (Fig. 1).

Cerebral malaria should be considered in anyone with impaired consciousness who have recently travelled in a endemic area, especially people with no neurologic focus and with normal CSF [5]. The main risk factors for cerebral malaria are: age, undernourishment, high parasitemia and immunosuppression [5]; most of these risk factors were present in our patient, in addition, her cerebral manifestations could not be associated with tumoral infiltration.

One of the main aspects of this case was the lack of suspicion and the delay on the diagnosis due to the overlapping between malaria and basal leukaemia symptoms. The diagnosis was achieved by a routine blood control test a month after hospital admission. This delay was possibly explained by the fact that the patient received several blood transfusions which could have cleared the parasitemia.

High effective treatment that could reduce the parasitemia as fast as possible was totally necessary. This treatment consisted in the administration of intravenous anti-malaria drugs; at present, there are two alternatives: quinine gluconate associated with tetracyclines/clindamicin or artesunate [6]. Artesunate was the

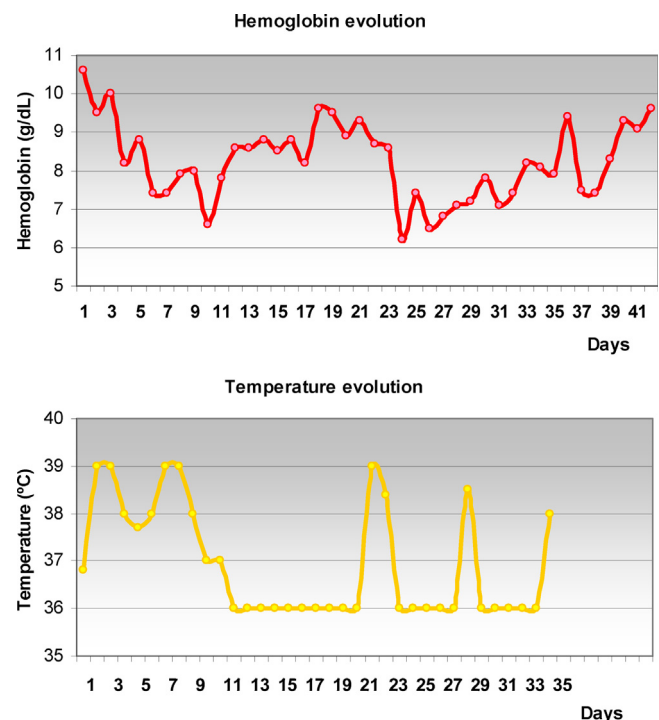


Fig. 1. Haemoglobin levels and temperature evolution.

option chosen for our patient essentially because it has a more favourable risk/benefit profile and effectiveness than quinine when treating patients with high parasitemia [7]. The superiority of artesunate is probably associated to its unique mechanism with an antiparasite activity based on the removal of immature trophozoites in the blood stream (ring-shaped), reducing the parasitemia quickly and preventing cytoadherence, which is the main physiopathologic mechanism of severe malaria due to *P. falciparum* [8]. The treatment was completed with oral administration of the combination of atovaquone with proguanil according to the North American Institute for Public Health and the Centers for Disease Control and Prevention (CDC) [9]. Another possibility, as recommended by the WHO, could be oral artemisinines [1]. The atovaquone and proguanil coformulation was chosen due to its excellent tolerance with a simple dosage and the clinical experience.

We concluded that it is mandatory to consider malaria in all febrile patients coming from endemic areas (imported malaria) [2], regardless of other comorbidities. Rapid diagnostic tests for malaria such as Test BinaxNOW [10] Malaria allow accurate diagnosis and prompt and effective treatment [11].

Conflict of interest

Nothing to disclose.

References

- [1] WHO. Guidelines for the treatment of malaria. 2nd ed. 2010, Disponible en: http://whqlibdoc.who.int/publications/2010/9789241547925_eng.pdf?ua=1 [Consultado el 01.10.20].
- [2] Askling HH, Bruneel F, Buchard G, Castelli F, Chiodini PL, Grobusch MP. Management of imported malaria in Europe. *Malar J* 2012;11:328.
- [3] No authors listed. Severe malaria. *Trop Med Int Health* 2014;19(Suppl. 1): 7–131.
- [4] Storm J, Craig AG. Pathogenesis of cerebral malaria-inflammation and cytoadherence. *Front Cell Infect Microbiol* 2014;4:100.
- [5] Idro R, Jenkins NE, Newton CR. Pathogenesis, clinical features and neurological outcome of cerebral malaria. *Lancet Neurol* 2005;4(12):827–40.
- [6] Karbwang J1, Na-Bangchang K, Thanavibul A, Bunnag D, Chongsuphajaisiddhi T, Harinasuta T. Comparison of oral artesunate and quinine plus tetracycline in acute uncomplicated falciparum malaria. *Bull World Health Organ* 1994;72(2):233–8.
- [7] Dondorp AM, Fanello CI, Hendriksen IC, Gomes E, Seni A, Chhaganlal KD, et al. Artesunate versus quinine in the treatment of severe falciparum malaria in African children (aquamat): an open-label randomised trial. *Lancet* 2010;376: 1647–57.
- [8] White NJ, Pukrittayakamee S, Hien TT, Faiz MA, Mokuolu OA, Dondorp AM. Malaria. *Lancet* 2014;383(9918):723–35.
- [9] Centers for the Disease Control and Prevention.. Guidelines for the treatment of malaria in the United States; 2013, Disponible en: <http://www.cdc.gov/malaria/resources/pdf/treatmenttable.pdf> [Consultado el 01.10.13].
- [10] Farcas GA, Zhong KJ, Lovegrove FE, Graham CM, Kain KC. Evaluation of the Binax NOW ICT test versus polymerase chain reaction and microscopy for the detection of malaria in returned travelers. *Am J Trop Med Hyg* 2003;69(6): 589–92.
- [11] Rossi I, D'Acremont V, Prod'Hom G, Genton B. Safety of falciparum malaria diagnostic strategy based on rapid diagnostic tests in returning travellers and migrants: a retrospective study. *Malar J* 2012;11:377.