




ELSEVIER

Contents lists available at [ScienceDirect](http://ScienceDirect.com)

## Urology Case Reports

journal homepage: [www.elsevier.com/locate/eucr](http://www.elsevier.com/locate/eucr)

Andrology and Fertility

## Paradidymis – Fact/Fiction and its Significance

M. Raghavendran <sup>a,\*</sup>, A. Venugopal <sup>b</sup>, V. Ranjit <sup>a</sup>, Vinay N. Kaushik <sup>a</sup><sup>a</sup> Department of Urology, Apollo BGS Hospitals, Adichunchunagiri Road, Kuvempunagar, Mysore 570009, Karnataka, India<sup>b</sup> Apollo BGS Hospitals, Mysore, Karnataka, India

## ARTICLE INFO

## Article history:

Received 23 March 2016

Accepted 30 March 2016

## Keywords:

Paradidymis

Vas deferens

Varicocele

Varicocelectomy

Mesonephric duct

Testicular and epididymal appendages

## ABSTRACT

A 30-year old infertile male was admitted for microsurgical sub inguinal varicocelectomy. Intra-operatively, two tubular structures of the caliber of neighboring veins were noted. They were distinct from the vas, which was carefully preserved. Histopathology revealed varicose veins along with two convoluted tubular structures lined by ciliated pseudo-stratified epithelium. There was an incomplete thin muscle coat. The lumina were irregular and contained no spermatozoa (Fig. 1). These structures were identified as paradidymis based on the location in the cord and microscopic morphology. We have tried to analyze the medico-legal significance of these benign lesions in our every day practice.

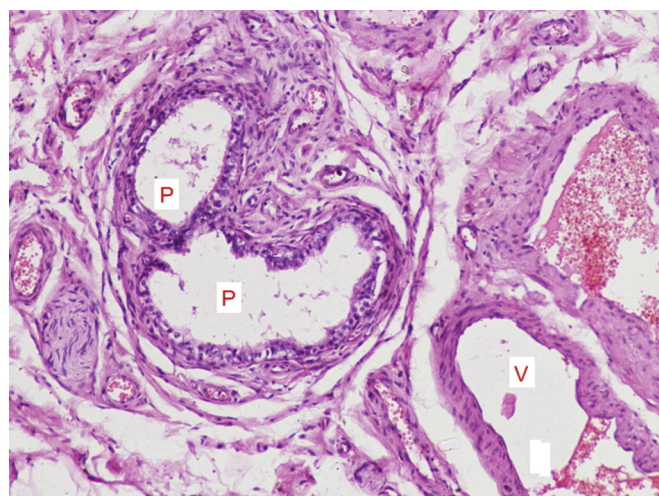
© 2016 The Authors. Published by Elsevier Inc. This is an open access article under the CC BY-NC-ND license (<http://creativecommons.org/licenses/by-nc-nd/4.0/>).

## Discussion

Testicular/epididymal appendages were once seen only in anatomical books, but are now known to exist in normal individuals (Fig. 1).<sup>1,2</sup> Five appendages are described, namely Appendix Testis, Appendix Epididymis, Cranial and Caudal Haller's organs and Paradidymis or Giralde's organs. Paradidymis are located in the distal portion of spermatic cord. The Appendix Testis is of paramesonephric (Mullerian) duct origin while all other appendages are of mesonephric (Wolffian) duct origin.

The commonly reported problems in the appendages are torsion with a single additional case of tumor reported.<sup>3</sup> As of date, Paradidymis and Haller's organs have not been described to the best of our knowledge. This may be because these structures are usually seen in the cord while the literature is from studies of orchidectomy specimens.<sup>1,2</sup> Hence, paradidymis is an organ of unknown clinical significance.

Epididymal appendages are blind ending pedunculated tubular structures with connection to vas. The present case highlights the fact that these can also be seen as completely distinct tubular structures. Hence, identification of paradidymis in surgical specimens (varicocelectomy) is important as it can be mistaken for Vas deferens. Proper identification will help urologists avoid major



**Figure 1.** Microscopic appearance of paradidymis (P) in the spermatic cord, amidst the dilated veins (V).

medico-legal problems in the increasingly commercial and litigant world.

## Conflicts of interest

None.

\* Corresponding author. Tel.: +91 9900144173, +91 821 2341940; fax: +91 821 2460870.

E-mail address: [maniyurr@yahoo.com](mailto:maniyurr@yahoo.com) (M. Raghavendran).

## References

1. Favarito AL, Cavalcante AGL, Babinski MA. Study on the incidence of testicular and epididymal appendages in patients with cryptorchidism. *Int Braz J Urol.* 2004;30:49–52.
2. Sahni D, Jit I, Joshi K, Sanjeev. Incidence and structure of the appendices of the testis and epididymis. *J Anat.* 1996;189:341–348.
3. Van Glabeke E, Khairouni A, Larroquet M, et al. Acute scrotal pain in children: results of 543 surgical explorations. *Pediatr Surg Int.* 1999;189:353–357.