




ELSEVIER

Contents lists available at ScienceDirect

Urology Case Reports

journal homepage: www.elsevier.com/locate/eucr

Inflammation and Infection

Isolated Renal Hydatidosis Presenting as Renal Mass: A Diagnostic Dilemma

Datteswar Hota^a, Sujata Pujari^b, Sanjay Choudhuri^a, Sabyasachi Panda^{a,*}^a Department of Urology & Renal Transplantation, SCB Medical College, Cuttack, India^b Department of Pathology, SCB Medical College, Cuttack, India

ARTICLE INFO

Article history:

Received 19 February 2014

Accepted 3 March 2014

Available online 27 April 2015

Keywords:

Renal hydatid cyst

Renal mass

Laparoscopic nephrectomy

ABSTRACT

Hydatid disease is a parasitic infestation by larval form of *Echinococcus granulosus*. Isolated renal involvement is extremely rare. There are no specific signs and symptoms of renal hydatidosis. However it may present as palpable mass, flank pain, hematuria, malaise, fever, and hydatiduria or as a complication of it such as infection, abscess, hemorrhage, necrosis and pelviureteric junction obstruction, renal failure etc. Except hydatiduria, none are pathognomonic for renal hydatidosis. There is no literature on renal hydatidosis presenting as renal mass we report 2 cases of isolated renal hydatidosis, which mimicked a renal mass on imaging study.

© 2015 The Authors. Published by Elsevier Inc. This is an open access article under the CC BY-NC-ND license (<http://creativecommons.org/licenses/by-nc-nd/4.0/>).

Introduction

Cystic hydatid disease is a cyclozoonotic parasitic infestation caused by the larval form of cestode *Echinococcus granulosus*. It is endemic in sheep raising countries like Africa, Latin America, Iran, and Turkey.¹ Humans are the intermediate hosts for the disease. It mainly involves the liver and spleen. Urinary tract involvement is uncommon, accounts only 2%–3% of all cases and often associated with disseminated hydatidosis.² Isolated renal involvement is extremely rare and only few cases have been reported in the literature. But there is no data on isolated renal hydatidosis presenting as renal mass.

Surgery remains the mainstay of treatment for renal hydatidosis. Total or partial nephrectomy is the treatment of choice. Adequate precaution must be taken during surgery as spillage of cyst contents may cause anaphylaxis. So, operating on a renal hydatid cyst without preoperative diagnosis may produce devastating results. We report 2 cases of isolated renal hydatid cysts which presented as heterogeneous renal mass on imaging studies.

Case 1

A 20-year-old girl presented with a dull aching pain over the left flank for the last 4 years. Physical examination was normal. Ultrasonography of the abdomen revealed a well-defined hypoechoic lesion measuring 64 × 34 mm in the upper pole of left kidney with multiple cysts within (Fig. 1). Computerized tomography (CT) scan

of the abdomen revealed a heterogeneous, enhancing mass lesion measuring 68 × 4 mm in the upper and mid pole of left kidney with no other abnormal findings (Fig. 2).

Case 2

A 33-year-old woman presented with an intermittent dull aching right flank pain for 3 years. Physical examination was normal. Ultrasonography of the abdomen revealed well-defined hypoechoic exophytic lesion measuring 65 × 55 mm anteriorly in the mid pole of right kidney. CT scan of the abdomen revealed a mixed-density enhancing mass of 70 × 58 mm in mid pole of right kidney.

Chest X-ray and routine blood examinations were normal in both the cases. With these, a clinical diagnosis of a renal tumor was made.

Both patients underwent laparoscopic transperitoneal radical nephrectomy under general anesthesia. Four ports (two 10 mm and two 5 mm) were placed. No adhesions were present around the renal hilum and over the mass. Hilar vessels were secured with hem-o-lock clips. The specimen was retrieved intact without breach in Gerota's fascia. Post-operative recovery was uneventful.

Gross cut section of both specimens revealed multiple cysts and daughter cysts surrounded by a brood capsule and filled with hydatid sand in a whitish fluid (Fig. 3). Histopathology revealed a multilocular cyst with a pericyst, a germinal layer, and multiple daughter cysts (Fig. 4).

Discussion

Isolated renal hydatidosis may remain asymptomatic for a long period. It may present with flank pain, palpable mass, malaise,

* Corresponding author. Tel.: +91-8895181900.

E-mail address: dr_spanda@rediffmail.com (S. Panda).

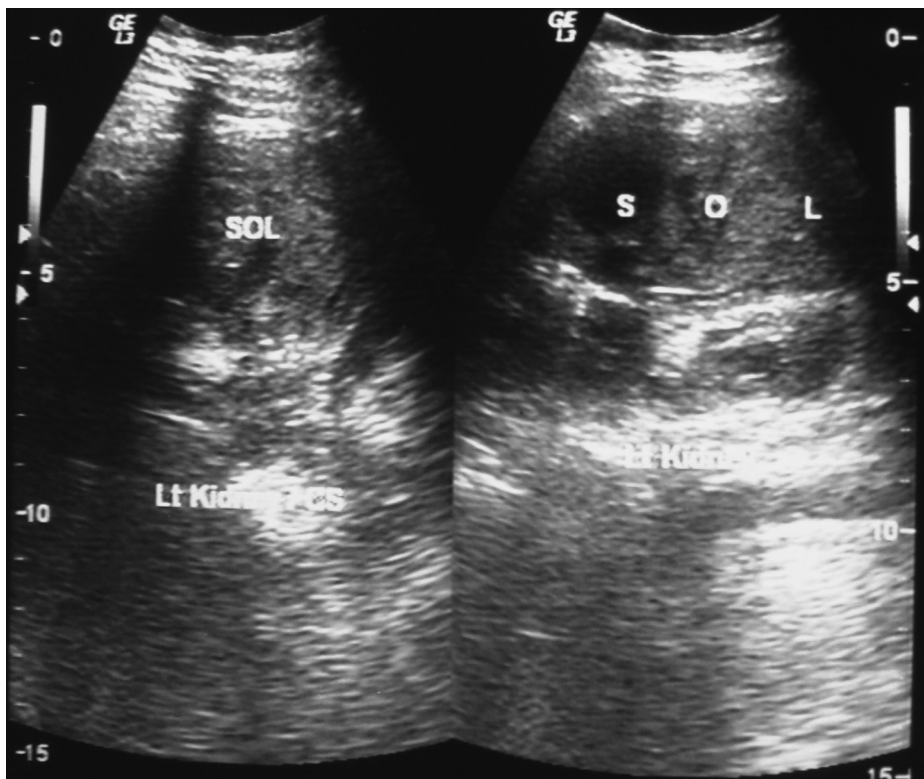


Figure 1. Ultrasonography showing a well-defined hypoechoic lesion in the upper pole of left kidney with multiple cysts within.

fever, hematuria and hydatiduria. Hydatiduria, a specific sign, is seen only in 5%-25% of renal hydatidosis.³ None of the serologic or immunologic test is pathognomonic of renal hydatidosis. Imaging studies play a major role in the preoperative diagnosis of hydatid disease. Ultrasonography, primary imaging modality, usually

demonstrates a unilocular or multilocular cyst. Daughter cysts, which are characteristic of hydatid disease sometimes detected by ultrasonography alone.⁴ CT is more accurate and sensitive than ultrasonography to detect calcification and daughter cysts. Magnetic resonance imaging has no added advantage over CT. Gogus et al⁵ from Turkey in their 20 cases of isolated renal hydatidosis reported that even ultrasonography and CT may miss the characteristic findings.

Surgical options for renal hydatid cysts mostly require total or partial nephrectomy. Nephron sparing surgery like partial cystectomy with capitonnage is possible only when the disease is known preoperatively.

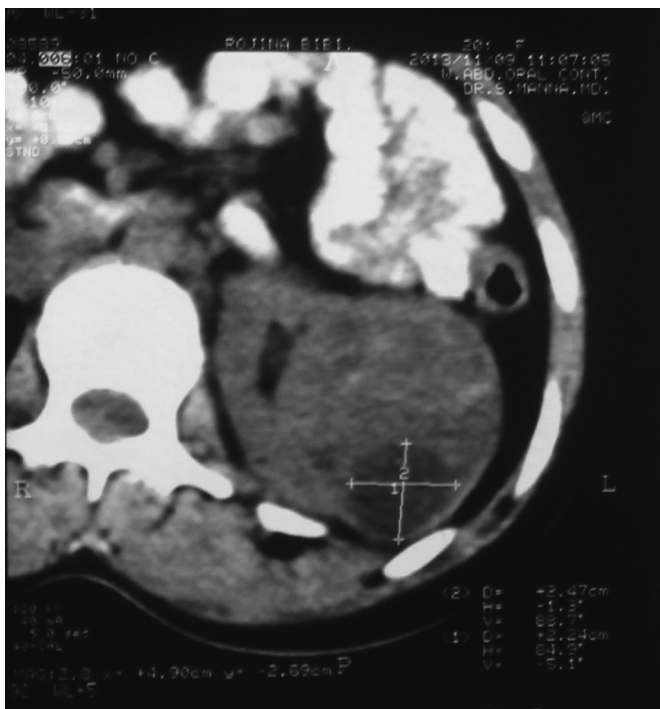


Figure 2. CT scan of the abdomen showing a heterogeneous enhancing mass lesion in the upper and mid pole of left kidney.

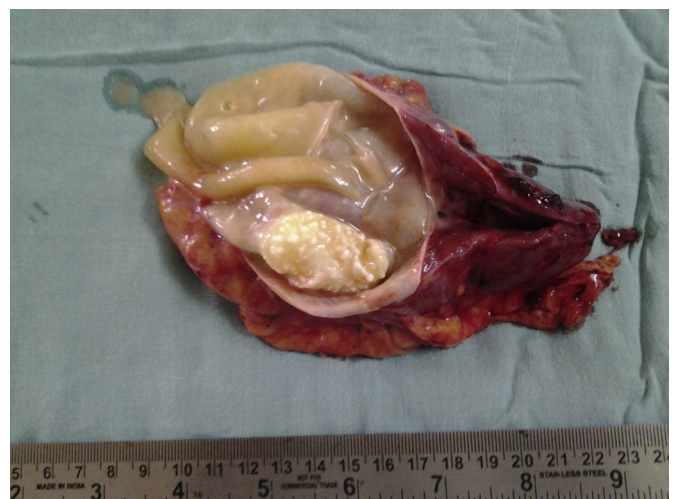

Figure 3. Cut section showing multiple cysts and daughter cysts surrounded by a brood capsule and filled with hydatid sand.

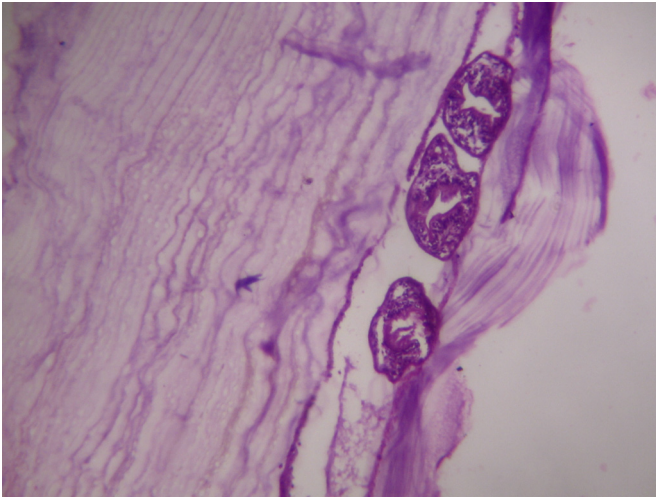


Figure 4. Histopathology showing multilocular cyst with pericyst, germinal layer and multiple daughter cysts.

Intraoperative spillage of the cyst may cause many serious complications such as allergic reactions, anaphylaxis, and even death. In that case, kidney should be packed with betadine-soaked sponges and the cyst cavity should be filled with scolicedal agents

like hypertonic saline, 2% formalin, 1% iodine, or 0.5% silver nitrate. Preoperative and post-operative albendazole therapy can be administered to prevent recurrence of suspicious spillage.

In our case, we remained outside Gerota's fascia during laparoscopic nephrectomy; thereby, we could prevent the spillage of cyst contents. It came to our surprise when gross section of the resected specimen revealed hydatid cyst.

Conclusion

Though isolated renal hydatidosis is very rare, it should be considered as a differential diagnosis while evaluating for a renal mass, so that adequate precautions can be taken during surgery to prevent accidental rupture and devastating complications.

References

1. Horchani A, Yassine N, Kbaier I, Attyaoui F, Zribi AS. Hydatid cyst of the kidney. A report of 147 controlled cases. *Eur Urol.* 2000;38:461.
2. Sarah JM, Christopher WJ, Warren Jr DJ. Parasitic diseases of the genitourinary system. In: Wein AJ, Kavoussi LR, Novick AC, et al., eds. *Campbell-Walsh Urology*. 9th ed. Saunders; 2007:458–459.
3. Angulo JC, Sanchez-Chapado M, Diego A, et al. Renal echinococcosis: clinical study of 34 cases. *J Urol.* 1997;157:787.
4. Odev K, Kilinc M, Arslan A, et al. Renal hydatid cysts and the evaluation of their radiologic images. *Eur Urol.* 1996;30:40.
5. Gogus C, Safak M, Baltaci S, Turkolmez K. Isolated renal hydatidosis: experience with 20 cases. *J Urol.* 2003;169:186–189.